

CASE REPORT

Myeloid metaplasia in the gall bladder: a case report

N Sahasrabudhe, A Davenport

J Clin Pathol 2005;58:998–999. doi: 10.1136/jcp.2005.025973

Idiopathic myelofibrosis is often associated with myeloid metaplasia (extramedullary haemopoiesis) in the spleen and liver. However, the gall bladder is an extremely unusual site for it to occur. A 59 year old man with myelofibrosis, who underwent cholecystectomy for chronic cholecystitis, showed myeloid metaplasia in his gall bladder. Pathologically, this may lead to diagnostic difficulties.

Idiopathic myelofibrosis is commonly associated with myeloid metaplasia in the spleen and liver, but the gall bladder is a rare site. We report a case of myeloid metaplasia incidentally found in a chronically inflamed gall bladder from a patient with myelofibrosis.

CASE REPORT

A 59 year old man was admitted in April 2004 with right upper quadrant abdominal pain, which was “colicky” and intermittent and of mild to moderate intensity. This was associated with obstructive jaundice.

On clinical examination, the patient had tenderness in the right hypochondrium. There was massive splenomegaly (supraumbilical) and the liver edge was 2 cm palpable.

Concentrations of γ glutamyl transferase (756 U/litre) and alkaline phosphatase (1741 U/litre) were greatly raised. The full blood count showed a haemoglobin concentration of 110 g/litre, a leucocyte count of 15.2×10^9 /litre, and a platelet count of 299×10^9 /litre.

Ultrasound examination of the abdomen showed gallstones in the gall bladder and dilatation of the common bile duct, which also contained a stone. The gall bladder was acutely distended and compressing the common hepatic duct, causing intrahepatic duct dilatation.

Endoscopic retrograde cholangiopancreatography showed a dilated bile duct with a stone. The pancreatogram was normal. The stone was successfully removed at the time of endoscopic retrograde cholangiopancreatography. After this, the patient’s liver function tests improved.

The patient’s past medical history included diabetes mellitus (treated by insulin) and hypertension. In addition, the patient was diagnosed with myelofibrosis four years previously, which would explain his hepatosplenomegaly. The bone marrow trephine at that time showed a pronounced increase in megakaryocyte numbers, many of which were present in clusters, and increased reticulin fibres.

The patient underwent a laproscopic cholecystectomy in November 2004, about seven months after his initial admission. He was clinically well with no abdominal pain in the intervening period.

PATHOLOGY

On pathological examination, the gall bladder was thick walled and measured $65 \times 30 \times 25$ mm. The mucosal surface showed no abnormality. The gall stones had been removed before receipt of the specimen in the laboratory.

Histologically, the gall bladder showed transmural chronic inflammation and fibrosis, in keeping with chronic

cholecystitis. In addition, there were multiple foci of extramedullary haemopoiesis (fig 1). These were present beneath the mucosa and extended through the muscle layer. The extramedullary haemopoiesis comprised mainly pleomorphic megakaryocytes and groups of immature myeloid cells. Immunohistochemistry was performed for factor VIII and myeloperoxidase, and confirmed the nature of these cells.

DISCUSSION

Idiopathic myelofibrosis is a chronic clonal stem cell disorder that leads to ineffective erythropoiesis, dysplastic megakaryocyte hyperplasia, and an increase in the ratio of

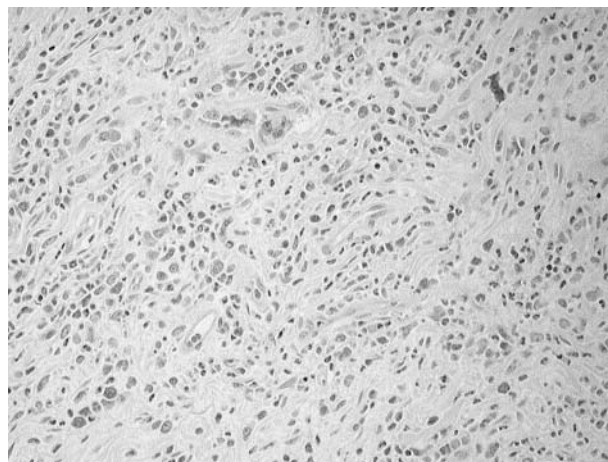


Figure 1 High power view of a focus of extramedullary haemopoiesis including a megakaryocyte.

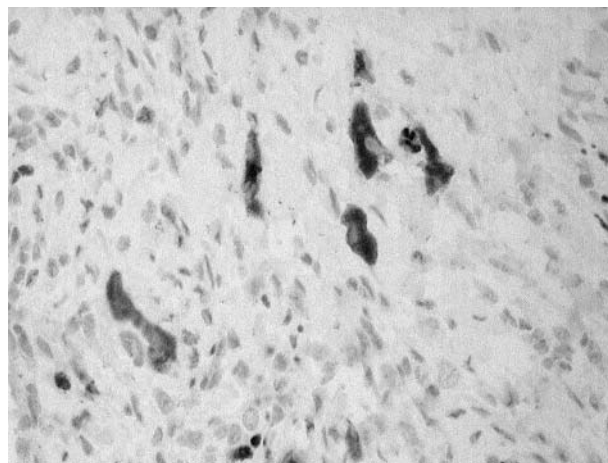


Figure 2 High power view of megakaryocytes showing positive factor VIII immunostaining.

Take home messages

- Idiopathic myelofibrosis is often associated with myeloid metaplasia (extramedullary haemopoiesis) in the spleen and liver, but it rarely occurs in the gall bladder
- We describe a 59 year old man with myelofibrosis, who underwent cholecystectomy for chronic cholecystitis and who showed myeloid metaplasia in his gall bladder
- Pathologically, this may lead to diagnostic difficulties

immature granulocytes to total granulocytes. This is accompanied by reactive bone marrow fibrosis and by extramedullary haemopoiesis.¹ The terms “myeloid metaplasia” and “extramedullary haemopoiesis” are used interchangeably to describe a pathological process of ectopic haemopoietic activity that affects primarily the spleen and liver. However, it has also been reported in other organs, including lymph nodes, gastrointestinal tract, skin, lungs, pleura, pericardium, peritoneum, central nervous system, and the genitourinary tract.² Myeloid metaplasia is very rare in the gall bladder and, to the best of our knowledge, there are only three previously documented cases in the literature.^{3–5}

In our case, the history of myelofibrosis was known. Without this knowledge, the presence of a pleomorphic infiltrate containing large atypical cells could lead to an incorrect diagnosis of malignancy. However, small foci of myeloid metaplasia with only a few megakaryocytes may not

be conspicuous among the other histological abnormalities of chronic cholecystitis and could potentially be missed. The recognition of myeloid metaplasia is important, especially in the absence of a previous diagnosis of myelofibrosis. Immunohistochemical stains help to confirm the correct diagnosis.

We report our case because myeloid metaplasia in the gall bladder is extremely unusual in idiopathic myelofibrosis and risks being misdiagnosed if the pathologist is unaware of the possibility.

Authors' affiliations

N Sahasrabudhe, A Davenport, Clinical Sciences Building, Wythenshawe Hospital, Southmoor Road, Wythenshawe, Manchester M23 9LT, UK

Correspondence to: Dr A Davenport, Clinical Sciences Building, Wythenshawe Hospital, Southmoor Road, Wythenshawe, Manchester M23 9LT, UK; portanna@hotmail.com

Accepted for publication 15 February 2005

REFERENCES

- 1 **Tefferi A**. Myelofibrosis with myeloid metaplasia. *N Engl J Med* 2000;**342**:1255–65.
- 2 **Mak YK**, Chan CH, So CC, *et al*. Idiopathic myelofibrosis with extramedullary haemopoiesis involving the urinary bladder in a Chinese lady. *Clin Lab Haematol* 2002;**24**:55–9.
- 3 **Thorns C**, Rohrmoser B, Feller Ac, *et al*. Chronic cholecystitis and myeloid metaplasia. *Histopathology* 2002;**41**:273–4.
- 4 **Geddy PM**, Wedgwood KR. Myelofibrosis presenting as chronic cholecystitis. *J Clin Pathol* 1996;**49**:428–9.
- 5 **Payan HM**, Grossman IW, Pelaez M. Acute surgical abdomen and myelofibrosis. *Mod Pathol* 1989;**2**:270–2.



Myeloid metaplasia in the gall bladder: a case report

N Sahasrabudhe and A Davenport

J Clin Pathol 2005 58: 998-999
doi: 10.1136/jcp.2005.025973

Updated information and services can be found at:
<http://jcp.bmj.com/content/58/9/998.full.html>

These include:

References

This article cites 5 articles, 1 of which can be accessed free at:
<http://jcp.bmj.com/content/58/9/998.full.html#ref-list-1>

Email alerting service

Receive free email alerts when new articles cite this article. Sign up in the box at the top right corner of the online article.

Topic Collections

Articles on similar topics can be found in the following collections

[Pancreas and biliary tract](#) (114 articles)
[Immunology \(including allergy\)](#) (1279 articles)

Notes

To request permissions go to:
<http://group.bmj.com/group/rights-licensing/permissions>

To order reprints go to:
<http://journals.bmj.com/cgi/reprintform>

To subscribe to BMJ go to:
<http://group.bmj.com/subscribe/>