

# PostScript

## CORRESPONDENCE

If you have a burning desire to respond to a paper published in the *Journal of Clinical Pathology*, why not make use of our "rapid response" option?

Log on to our website ([www.jclinpath.com](http://www.jclinpath.com)), find the paper that interests you, and send your response via email by clicking on the "eLetters" option in the box at the top right hand corner.

Providing it isn't libellous or obscene, it will be posted within seven days. You can retrieve it by clicking on "read eletters" on our homepage.

The editors will decide as before whether to also publish it in a future paper issue.

### Large vessel arteritis: a diagnostic challenge in the elderly

Takayasu arteritis is a rare form of chronic inflammatory arteritis affecting large vessels, predominantly the aorta and its main branches. Those at highest risk are adolescent girls and women in their 2nd and 3rd decade of life, and this disease is most frequently seen in Japan, Southeast Asia, India, and Mexico.<sup>1</sup> An elderly woman with Takayasu arteritis of late onset, an extremely unusual disorder in the Western world, is described.

A 67 year old woman presented with a two month history of bilateral forearm pain associated with coldness, numbness, and stiffness. She had claudication symptoms in the upper extremities, asthenia, and loss of 6–8 kg of body weight. She was hypertense. Physical examination revealed the absence of a bilateral radial pulse and arterial pressure in the upper extremities. Subclavian and axillary artery bruits were audible. Redness of the forearms and hands with trophic changes to the nails were seen. Retinopathy and

**Table 1** American College of Rheumatology criteria for the classification of Takayasu arteritis (1990)

- Age at disease onset  $\leq 40$  years
- Claudication of extremities
- Decreased brachial artery pulse
- Blood pressure difference  $>10$  mm Hg
- Bruit over subclavian arteries or aorta
- Arteriogram abnormality

At least three of the six criteria are required for the diagnosis of Takayasu arteritis.

temporal arterial tenderness or nodularity were not seen. Laboratory data showed an erythrocyte sedimentation rate of 101 mm/hour, and a C reactive protein of 61.9 mg/litre (normal range, 0–5). Doppler ultrasonography of the renal arteries and an echocardiogram were normal. Magnetic resonance angiography of the aortic arch and its branches (fig 1) showed total stenosis of both the subclavian arteries and a significant filiform stenosis of the right vertebral artery, which had an inverted flow. Bilateral temporal artery biopsy results were negative. Treatment with 0.5 mg/kg/day of prednisone was started, and significant clinical and laboratory improvement was seen. The corticosteroid dose was progressively reduced, and the patient was well one year later.

The differential diagnosis of Takayasu arteritis includes other causes of aortitis and large vessels arteritis but, because of the age of our patient, giant cell arteritis is the most likely.<sup>2</sup> These disorders are not mutually exclusive, but are overlapping, because they are histologically similar and share the same pathogenicity.<sup>3</sup> In addition, giant cell arteritis involves the aorta and its large branches in up to 15% of cases, and approximately 50% of these have a negative temporal artery biopsy result. Normally both diseases can be differentiated on clinical grounds. The most

discriminatory factors that led to the correct diagnosis in 95% of patients are age of 40 years at disease onset, ethnic background, clinical signs of upper limb vascular insufficiency, shoulder stiffness, and scalp tenderness.<sup>4</sup> The diagnosis is made by vascular imaging findings (proximal stenotic lesions predominate and tend to be bilateral) and American College of Rheumatology criteria (table 1).<sup>5</sup> This patient fulfilled five of the six American College of Rheumatology specific diagnostic criteria. Vascular imaging is crucial in making the correct diagnosis in patients with large vessel giant cell arteritis. Aortitis does not lead to arterial obstruction, but leads to arterial dilatation and aneurysm formation, and most often affects the distal subclavian artery.<sup>3</sup> A real diagnostic dilemma appears when, as in this patient, the clinical presentation is similar (aortic arch syndrome without cranial symptoms), laboratory findings are non-specific, temporal biopsy results are negative, and age is a confusing feature. In such cases, giant cell arteritis with large artery involvement and Takayasu arteritis of late onset have to be considered.<sup>1–3</sup>

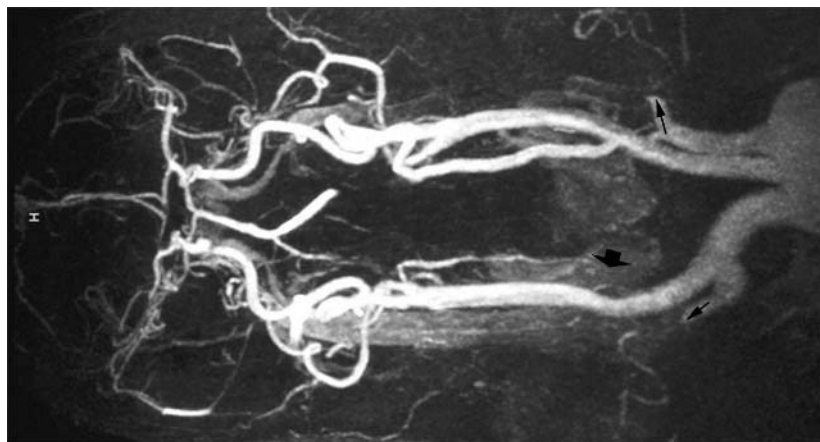
This case suggests that Takayasu arteritis may be underdiagnosed in the elderly in the Western world.

**E Antón**

Department of Internal Medicine, Hospital of Zumárraga, 20700-Zumárraga, Guipúzcoa, Spain; [ejaranda@hotmail.com](mailto:ejaranda@hotmail.com)

### References

- 1 Johnston SL, Lock RJ, Gompels MM. Takayasu arteritis: a review. *J Clin Pathol* 2002;55:481–6.
- 2 Ninet JP, Bachel P, Dumontet CM, et al. Subclavian and axillary involvement in temporal arteritis and polymyalgia rheumatica. *Am J Med* 1990;88:13–20.
- 3 Weyand CM, Gorazny JJ. Medium and large-vessel vasculitis. *N Engl J Med* 2003;349:160–9.
- 4 Michel BA, Arend WP, Hunder GG. Clinical differentiation between giant cell (temporal) arteritis and Takayasu's arteritis. *J Rheumatol* 1996;23:106–11.
- 5 Arend WP, Michel BA, Bloch DA, et al. The American College of Rheumatology 1990 criteria for the classification of Takayasu arteritis. *Arthritis Rheum* 1990;33:1129–34.

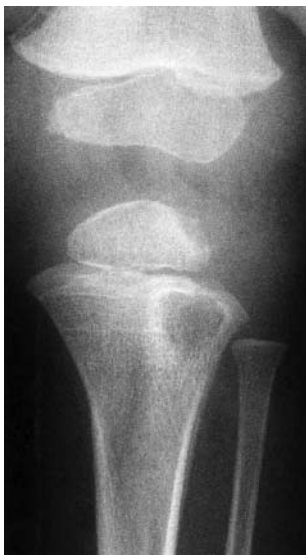

**Figure 1** Magnetic resonance angiography of the aortic arch showing total stenosis of both subclavian arteries (small arrows), and a significant filiform stenosis of the right vertebral artery, which had an inverted flow (large arrow).

### Fibrocartilagenous mesenchymoma of bone: the youngest reported case in a patient aged 1 year and 7 months

We report the youngest recorded example of a fibrocartilagenous mesenchymoma of bone, with an age at presentation of 1 year and 7 months. The youngest previously recorded cases have been in 9 year old patients.

A male infant aged 1 year and 10 months originally presented to the orthopaedic clinic with a three month history of limping and pain in the left leg. There was no history of trauma and there were no localising signs in the left leg. An x ray showed a lucent area with surrounding sclerosis involving the proximal left tibial metaphysis. He had originally been brought to the accident and emergency unit two days after the initial



**Figure 1** Follow up radiograph at 12 weeks. The lytic unilocular metaphyseal lesion is larger, better defined, and has developed a partly sclerotic margin. There is no definite cortical breach and no expansion.

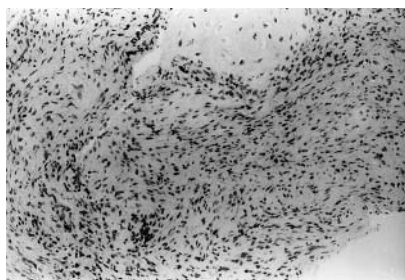onset of symptoms (aged 1 year and 7 months) and radiographs taken at that time had shown no significant abnormalities. Therefore, the lesion had progressed rapidly over three months (fig 1).

Because of the presence of symptoms and the rapid progression radiologically, open biopsy and curettage of the lesion were carried out. At surgery the cavity contained reddish brown fluid. Microbiological examination of the tissue removed showed no subsequent bacterial growth. After surgery the child's symptoms resolved, and radiographs taken four months later showed a decrease in the size of the lucent area.

The specimen received consisted of multiple small fragments of tissue, which included bone.

Histologically, it contained bland but quite cellular fibrous tissue within which there were islands of hyaline cartilage, some of which were possibly metaplastic. Most of the cartilage had large nuclei and it was neither reactive nor part of the growth plate. A tiny focus of growth plate-like tissue was seen. The histological features were those of a fibrocartilagenous mesenchymoma of bone (fig 2).

The term fibrocartilagenous mesenchymoma with low grade malignancy was first described by Dahlin *et al* for a rare bone



**Figure 2** Photomicrograph showing the histological features of fibrocartilagenous mesenchymoma of bone.

tumour that had a specific clinical behaviour, radiological features, and morphological features.<sup>1</sup> The differential diagnosis of this lesion involves several entities, including chest wall hamartoma (mesenchymoma) and dedifferentiated chondrosarcoma.<sup>2,3</sup> The most important differential diagnosis is fibrous dysplasia with cartilaginous differentiation. The tumour usually occurs in the metaphyses of the long bones and commonly presents with pain. Other sites have been documented, such as the metatarsal bones, vertebrae, and the pubis.<sup>4</sup>

Radiologically, this tumour often abuts an open growth plate. These tumours are predominantly radiolucent, although some mineralisation is often seen. Cortical destruction is an additional common finding.<sup>1</sup>

This lesion is generally treated by surgical resection. Local recurrences have been recorded. On review of the current limited literature, no distant spread has been recorded and there is no associated mortality. This entity is thought to represent a true neoplasm rather than a hamartoma.

There have been four previously published series describing fibrocartilagenous mesenchymoma of bone comprising, in total, 20 patients. Our patient is more than 7 years younger than the youngest previously recorded case. The light microscopic features together with the clinical presentation and radiological appearance are characteristic. The most important histological feature is cartilage with the appearance of epiphyseal plates.

Some cases recur locally, but no metastasis or death was caused by these lesions. Dahlin thought that this lesion was of low grade malignancy.<sup>1</sup> A more recent series suggests that the term malignant is not warranted.<sup>5</sup>

In summary, the average age of occurrence of this tumour in previous published series is calculated to be 14 years and 10 months. The youngest previously recorded cases were in 9 year old patients.<sup>1,4</sup> Therefore, our patient, who is more than 7 years younger than these individuals, is the youngest patient to be recorded with this diagnosis.

#### S J Hayes

Department of Histopathology, Hope Hospital, Stott Lane, Salford M6 8HD, UK; [steve.hayes8@btopenworld.com](mailto:steve.hayes8@btopenworld.com)

#### S Wells

Department of Histopathology, Royal Bolton Hospital, Farnworth, Bolton BL4 0JR, UK

#### J Harake

Department of Radiology, Royal Bolton Hospital

#### J J Henderson

Department of Orthopaedic Surgery, Royal Bolton Hospital

#### A J Malcolm

Department of Histopathology, Royal Shrewsbury Hospital, Shrewsbury SY3 8XQ, UK

Consent was given for the details of this case report to be published.

## References

- 1 Dahlin DC, Bertoni F, Beabout JW, *et al*. Fibrocartilagenous mesenchymoma with low-grade malignancy. *Skeletal Radiol* 1984;12:263-9.
- 2 Cozzuto C, Cornaglia-Ferraris P. Fibrocartilagenous mesenchymoma of bone. *Pathol Res Pract* 1991;187:279-83.

3 McLeod RA, Dahlin, DC. Hamartoma (mesenchymoma) of the chest wall in infancy. *Radiology* 1979;131:657-61.

4 Bulychova IV, Krishnan Unni K, Bertoni F, *et al*. Fibrocartilagenous mesenchymoma of bone. *Am J Surg Pathol* 1993;17:830-6.

## $\gamma$ -Glutamyltransferase decreases in patients with the chronic form of schistosomiasis mansoni treated with ursodeoxycholic acid

Schistosomiasis mansoni is a chronic parasitic liver disease characterised by a relative preservation of hepatic function, but there are early alterations in laboratory test results.<sup>1-4</sup> The rise in serum  $\gamma$ -glutamyltransferase ( $\gamma$ GT) activity in patients with schistosomiasis does not correlate with either parasite load or ultrasonographic alterations.<sup>5,6</sup> We now report the effect of ursodeoxycholic acid in these patients.

Eleven adults (nine men) with raised serum  $\gamma$ GT activity and the "pure" form of schistosomiasis participated in the prospective study (eutrophic patients; body mass index > 20 and < 30 kg/m<sup>2</sup>; abstemious or with alcohol ingestion less than 160 g/week; non-users of hepatotoxic and/or cholestatic drugs; and hepatitis B surface antigen, anti-hepatitis B core antigen, and anti-hepatitis C negative). All patients were previously treated for the parasitosis. Echographic examinations were interpreted as described previously.<sup>7</sup> Upper digestive endoscopy revealed the presence of oesophageal and/or oesophagogastric varices and/or hypertensive gastropathy. The patients were treated with ursodeoxycholic acid at a dose of 10 mg/kg/day, divided into two daily portions for a period of six weeks. Before treatment, during treatment, and 30-45 days after drug discontinuation, the patients underwent clinical and laboratory evaluation.

At the beginning of the treatment  $\gamma$ GT was 3.1 (SEM, 0.4) times the upper normal limit, whereas alkaline phosphatase was normal (mean, 1.1 times the upper normal limit; SEM, 0.2). There was a progressive and significant decrease in  $\gamma$ GT to near normal values at the end of treatment and an increase again after drug discontinuation, whereas alkaline phosphatase remained unaltered. Aminotransferases also decreased during treatment and increased again after drug discontinuation (table 1). Prothrombin index (mean international normalised ratio at the beginning, 1.2; SEM, 0.1) and platelet count (mean,  $96 \times 10^9$ /litre at the beginning; SEM, 23) remained unaltered.

Ursodeoxycholic acid is widely used for the treatment of primary biliary cirrhosis and other chronic cholestatic liver diseases.<sup>8,9</sup> We now report that the increased serum  $\gamma$ GT activity seen in patients with the chronic form of schistosomiasis is ursodeoxycholic sensitive. The mechanism of this increase in  $\gamma$ GT seems to be different from that which occurs in alcoholism, and is compatible with the existence of changes in the biliary tree.<sup>6,10</sup>

Further studies are required to understand the role of ursodeoxycholic acid in the molecular and cellular mechanisms of bile secretion and its ability to reduce  $\gamma$ GT activity in schistosomiasis mansoni (for example whether it acts on the evolutionary stage of the disease), and to determine whether  $\gamma$ GT could be used as a prognostic marker for this disease.

**Table 1** Laboratory parameters in patients with schistosomiasis mansoni at the beginning and end of treatment with ursodeoxycholic acid and 30–45 days after discontinuation of the drug

Treatment period	Total bilirubin (mg/l)	AST (U/l)	ALT (U/l)	AP (U/l)	$\gamma$ GT (U/l)
Before	13 (1)	46 (5)	44 (4)	290 (47)	155 (19)
End	12 (1)	34 (2)	30 (4)	302 (46)	66 (8)
After	13 (1)	41 (6)	38 (4)	240 (42)	157 (27)
Paired <i>t</i> test ( $p=1 \times 2$ )	0.245	0.036	0.004	0.889	0.0003
Paired <i>t</i> test ( $p=1 \times 3$ )	0.755	0.402	0.810	0.093	0.649

Values are mean (SEM).

ALT, alanine aminotransferase; AP, alkaline phosphatase; AST, aspartate aminotransferase;  $\gamma$ GT,  $\gamma$ -glutamyltransferase.

## Acknowledgements

This research was supported by FAPESP Fundação de Amparo à Pesquisa do Estado de São Paulo, Proc. 02/0562.

**P de J Ribeiro, J L Narciso, C F de Toledo,  
D R Borges**

Gastroenterology Division, Department of Medicine, Universidade Federal de São Paulo, São Paulo, 04023-900 Brazil; [durval@gastro.epm.br](mailto:durval@gastro.epm.br)

## References

- Borges DR, Manoukian N, Toledo CF. Protein C deficiency in the compensated form of hepatosplenic schistosomiasis. *Braz J Med Biol Res* 1987;20:557–60.
- Camacho-Lobato L, Borges DR. Early liver dysfunction in schistosomiasis. *J Hepatol* 1998;29:233–40.
- Gammal SH, Borges DR, Maciel RMB, et al. High T4 syndrome in schistosomiasis [abstract]. *Dig Dis Sci* 1986;31:269S.
- Köpke-Aguiar LA, Martins JRM, Passerotti CC, et al. Serum hyaluronic acid as a comprehensive marker to assess severity of liver disease in schistosomiasis. *Acta Trop* 2002;84:117–26.
- Amaral ACC, Köpke-Aguiar LA, Souza MRA, et al. Elevação da  $\gamma$ -glutamyltransferase sérica na hepatopatia esquistossomótica não se correlaciona com a carga parasitária e precede alterações ultra-sonográficas. *Arq Gastroenterol* 2002;39:27–31.
- Martins RD, Borges DR. Ethanol challenge in non-alcoholic patients with schistosomiasis. *J Clin Pathol* 1993;46:250–3.
- WHO Report. *Ultrasound in schistosomiasis. A practical guide to the standardized use of ultrasonography for the assessment of schistosomiasis-related morbidity, 2000*, Report of a WHO expert committee. Geneva: World Health Organization (Report TDR/STR/SCH/00, 1), 2000.

- Paumgartner G, Beuers U. Ursodeoxycholic acid in cholestatic liver disease: mechanisms of action and therapeutic use revisited. *Hepatology* 2002;36:525–31.
- Pelleter G, Roulot D, Davion T, et al. Randomized controlled trial of ursodeoxycholic acid in patients with alcohol-induced cirrhosis and jaundice. *Hepatology* 2003;37:887–92.
- Vianna MR, Gayotto LC, Telma R, et al. Intrahepatic bile duct changes in human hepatosplenic schistosomiasis mansoni. *Liver* 1989;9:100–9.

## BOOK REVIEW

### Embryo and Fetal Pathology. Color Atlas with Ultrasound Correlation

Edited by E Gilbert-Barness, D Debich-Spicer. Cambridge: Published by Cambridge University Press, 2004, £195.00 (hardback), pp 720. ISBN 0 52182 529 6

This is a comprehensive and extremely well illustrated atlas with good quality colour photographs. The information provided is up to date and well presented.

It has an excellent well illustrated section on embryonic development and good photos of growth disorganised embryos. Dating and staging of embryos should be straightforward using this atlas.

There are helpful tables throughout the book that make for easy quick reference.

Errors of morphogenesis are followed by malformation syndromes, dysplasia, and disruption. The chapter on malformation syndromes is well set out with practical tables of syndromes that refer to a specific malformation—for example, unilateral renal agenesis.

Both dysplasias and disruptions are well discussed and illustrated.

A novel addition is the provision of colour diagrams of each operative procedure performed for the correction of congenital heart disease. A good list of likely complications for each operation is provided.

The juxtaposition of macroscopic photos with the ultrasound images is helpful for interpretation and correlation of the findings.

A strange concept provided under congenital tumours (page 548) is that Castleman disease and Takayasu disease are malformation syndromes with haemangiomas.

In addition, several typographical errors were noted.

This book adds a new dimension to the currently available fetal and neonatal pathology books.

H C Wainwright

## CORRECTION

Afazali B, Goldsmith DJ. Beneficial effects of statins on the kidney. *J Clin Pathol* 2004;57:673–4. The first author's name was misprinted as Af azali B when it should have been Afzali B.

## CALENDAR OF EVENTS

Full details of events to be included should be sent to Maggie Butler, Technical Editor JCP, The Cedars, 36 Queen Street, Castle Hedingham, Essex CO9 3HA, UK; email: [maggie.butler2@btopenworld.com](mailto:maggie.butler2@btopenworld.com)

### Practical Pulmonary Pathology

26–29 July 2005, Royal Brompton Hospital, London, UK

Further details: Professor B Corrin, Brompton Hospital, London SW3 6NP, UK. (Fax +44 (0)20 7 351 8293; e-mail [b.corrin@ic.ac.uk](mailto:b.corrin@ic.ac.uk))

### Breast Diagnostic Histopathology Update

22–23 September 2005, Hammersmith Hospital and Imperial College, London, UK

Further details: Wolfson Conference Centre, Hammersmith Hospital, Du Cane Road, London W12 ONN, UK. (Tel +44 (0)20 8383 3117/3227/3245; Fax +44 (0)20 8383 2428; e-mail [wcc@ic.ac.uk](mailto:wcc@ic.ac.uk))



## Large vessel arteritis: a diagnostic challenge in the elderly

E Antón

*J Clin Pathol* 2005 58: 782

---

Updated information and services can be found at:

<http://jcp.bmj.com/content/58/7/782.1.full.html>

---

*These include:*

### References

This article cites 5 articles, 1 of which can be accessed free at:

<http://jcp.bmj.com/content/58/7/782.1.full.html#ref-list-1>

### Email alerting service

Receive free email alerts when new articles cite this article. Sign up in the box at the top right corner of the online article.

---

### Notes

---

To request permissions go to:

<http://group.bmj.com/group/rights-licensing/permissions>

To order reprints go to:

<http://journals.bmj.com/cgi/reprintform>

To subscribe to BMJ go to:

<http://group.bmj.com/subscribe/>