

ORIGINAL ARTICLE

The presence of benign prostatic glandular tissue at surgical margins does not predict PSA recurrence

K M Kernek, M O Koch, J K Daggy, B E Juliar, L Cheng

J Clin Pathol 2005;58:725–728. doi: 10.1136/jcp.2004.024182

See end of article for authors' affiliations

Correspondence to:
Dr L Cheng, Department of Pathology and Laboratory Medicine, Indiana University Medical Center, University Hospital 3465, 550 North University Blvd, Indianapolis, IN 46202, USA; lcheng@iupui.edu

Accepted for publication
19 November 2004

Background: Serum prostate specific antigen (PSA) increases after radical prostatectomy are thought to indicate recurrent disease, although some suggest they result from benign prostatic epithelial tissue left at surgical margins.

Aims: To investigate whether presence, location, and extent of benign prostatic tissue at radical prostatectomy surgical margins influence patient outcome.

Methods: One hundred and ninety nine patients with prostate cancer and negative surgical margins were studied. The prostatectomy specimens were totally embedded using the whole mount technique. The apex and bladder neck, dissected as a cone from the specimen, were serially sectioned. The total length of benign prostatic tissue at the margins, measured for each location using an ocular micrometer, was obtained by summing the length of all positive sites. The presence, anatomical location, and extent of benign prostatic tissue at the margin were correlated with clinicopathological characteristics and postoperative PSA increases.

Results: Fifty five cases had benign prostatic glandular tissue at the surgical margin. The mean length was 2.19 mm (0.1–14.7). The most frequent location of benign prostatic tissue was the apex (40 patients). Presence, anatomical location, and length of benign prostatic tissue at the margin were not significantly associated with age, preoperative PSA, prostate weight, pathological stage, tumour volume, largest tumour dimension, Gleason score, extraprostatic extension, seminal vesical invasion, tumour multifocality, perineural invasion, or PSA recurrence.

Conclusions: Benign prostatic tissue was frequently found in margins of apex and bladder base, but uncommon in the anterior or posterior prostate. The presence of benign prostatic tissue at surgical margins had no prognostic relevance.

Some studies show that 27–53% of patients undergoing radical prostatectomy will have a detectable rise in prostate specific antigen (PSA) within 10 years.¹ Rises in serum PSA after radical prostatectomy, when initially undetectable, are usually thought to be a marker for recurrent disease. Recurrent PSA rises are considered to be “biochemical failure”, although some studies question whether this equates to clinical failure.² Some have suggested that increases in PSA may occur as a result of benign prostatic epithelial tissue, which remains at the surgical margins after radical prostatectomy. We sought to determine whether the presence, location, and extent of benign prostatic tissue at the inked surgical margins of radical prostatectomy specimens influence PSA recurrence and patient outcome.

“Some have suggested that increases in prostate specific antigen may occur as a result of benign prostatic epithelial tissue, which remains at the surgical margins after radical prostatectomy”

MATERIALS AND METHODS

We analysed the radical prostatectomy specimens of 245 consecutive patients with prostate cancer, who were operated on by a single surgeon (MOK) between 1999 and 2003 at the Indiana University School of Medicine, USA. None received hormone therapy or radiotherapy before surgery. We excluded 46 patients (18%) with tumour at surgical margins, yielding a final study population of 199 patients. The prostatectomy specimens were totally embedded using the whole mount

technique, as described previously.^{3–9} During initial processing of the specimen, the prostate was weighed, measured, and inked with two colours. The specimen was then fixed in 10% formalin. After fixation, the specimen was step sectioned, and submitted in entire cross sections from apex to base. The apex and bladder neck were coned and serially sectioned. The specimens were then analysed for the presence of tumour, Gleason grade, tumour stage, margin status, tumour volume, and the presence or absence of benign epithelial tissue at the surgical margin. Grading was performed according to the Gleason grading system,¹⁰ and the final score was obtained by summing the primary and secondary Gleason pattern grades, based upon assessment of the entire specimen. The 1997 TNM system was used for pathological staging.¹¹ The greatest diameter of the largest single focus of tumour was obtained by marking both ends of the tumour on the glass slide and measuring this distance with a ruler marked with millimetres. If the tumour size was < 0.5 cm, an ocular micrometer was used. The volume of carcinoma in the entire prostate was determined by the grid method and was the sum of the volumes of individual foci of tumour.^{12 13}

The presence of benign tissue at the surgical margin was determined by identifying glandular tissue at the inked margin (fig 1). Using an ocular micrometer, the length of benign prostatic tissue at the inked margins was measured (in millimetres) for each specific location, and the total length was obtained by adding the measured length of all positive sites. The total length of benign tissue, and the length at each anatomical location, were documented.

Abbreviations: PSA, prostate specific antigen

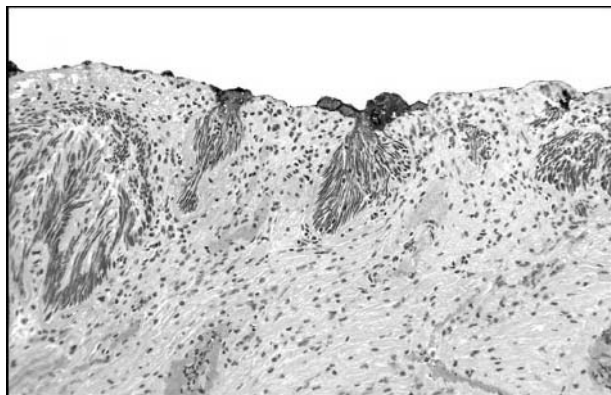


Figure 1 Benign prostatic glands at the inked surgical margins.

Serum PSA was measured using the Immulite® PSA assay (Diagnostics Products Corporation, Los Angeles, California, USA). Biochemical recurrence was defined as a PSA value of at least 0.1 ng/ml after surgery.^{14 15} The patients were followed at one, three, six, 12, 18, and 24 months during the first two years. Thereafter, follow up was adjusted according to the clinical situation but was at least annually. The mean follow up was 14 months (median, 12; range, 1.5–48). This research was approved by the Indiana University institutional review board.

The results were analysed using SAS V8.2 (Cary, North Carolina, USA), with two sided tests and $p < 0.05$ implying significance. Fisher's exact test was used to compare postoperative PSA recurrence with the presence or absence of benign epithelial tissue at surgical margins and location of the benign tissue. The association of PSA recurrence with presence or absence of benign tissue at surgical margins was also tested within each margin location. Fisher's exact test was also used to test for differences in all categorical patient characteristics by the presence or absence of benign tissue at surgical margins and anatomical location. The Wilcoxon rank sum test was used to test for differences in continuous measures between subjects with and without benign tissue at surgical margins. The Wilcoxon rank sum test was also used to test for differences in patient measures by anatomical location.

In the 55 subjects with benign tissue at surgical margins, the correlation of length of benign tissue at surgical margins with various clinicopathological characteristics was assessed using Spearman's correlation coefficient. Because the number of subjects with benign tissue at surgical margins in whom PSA recurred was small, a Monte Carlo estimate for the exact Wilcoxon rank sum test was also used to test for differences in length of the benign tissue at surgical margins grouped by postoperative PSA value.

RESULTS

Of the 199 patients in our study, 17 (8.5%) had a raised postoperative PSA value and two patients had lymph node metastasis. The overall distribution of pathological stage was T2a (31 patients), T2b (128 patients), T3a (34 patients), and T3b (six patients). Gleason scores were 5 (39 patients), 6 (70 patients), 7 (70 patients), 8 (seven patients), and 9 (13 patients). The mean tumour volume was 2.02 cc (range, 0.03–13.6 cc).

In our study, 55 of 199 (28%) cases had benign prostatic glandular tissue at the surgical margin. Table 1 shows the patient characteristics for subjects categorised by whether they had benign tissue at the surgical margin. The presence of benign tissue was not significantly associated with patient characteristics (age, preoperative PSA value, prostate weight, pathological stage, tumour volume, largest tumour dimension, Gleason score, extraprostatic extension, seminal vesical invasion, tumour multifocality, and perineural invasion) or PSA recurrence (all $p > 0.05$; table 1). The odds ratio (LogXact version 2.1 software) of PSA recurrence for presence

Table 2 Anatomical distribution of benign prostatic tissue at the surgical margins (N = 55)

Location	Number of cases (%)
Apex only	22 (40%)
Bladder base only	14 (25.5%)
Anterior only	5 (9.1%)
Posterior only	0
Apex and other	40 (73%)
Bladder base and other	28 (50.9%)
Apex and bladder base	14 (25.5%)

Table 1 Patient characteristics according to the presence or absence of benign prostatic glands at the inked margins

Characteristics	Benign glands at inked margin		p Value
	Present (N = 55)	Absent (N = 144)	
Age (years)	59 (46–76)	61.5 (41–77)	0.13
Preoperative PSA value (ng/ml)	6.3 (1.2–20)	5.6 (1.3–48.7)	0.42
Prostate weight (g)	36.3 (18–104.6)	39 (14–122)	0.30
Pathological stage			0.70
T2a	7 (12.7%)	24 (16.7%)	
T2b	36 (65.5%)	92 (63.9%)	
T3a	10 (18.2%)	24 (16.7%)	
T3b	2 (3.6%)	4 (2.8%)	
Tumour volume (cc)	1.6 (0.08–6.5)	1.3 (0.03–13.6)	0.30
Largest tumour dimension (cm)	1.8 (0.3–4.1)	1.4 (0.02–3.8)	0.20
Gleason score	7 (5–9)	6 (5–9)	0.09
Extraprostatic extension	12 (21.8%)	26 (18.1%)	0.55
Seminal vesical invasion	2 (3.6%)	4 (2.8%)	
Multifocality	48 (87.3%)	122 (84.7%)	0.83
Perineural invasion	44 (80%)	107 (74.3%)	0.46
High grade PIN	53 (98.2)	144 (100%)	
PSA recurrence	6 (10.9%)	11 (7.6%)	0.57

Values are median (range), with p values assessed by the Wilcoxon rank sum test or N (%) and p values assessed by Fisher's exact test. PIN, prostatic intraepithelial neoplasia; PSA, prostate specific antigen.

Table 3 Extent of margin involvement according to benign prostatic tissue location

Location	N	Length of margin involvement (mm)
Apex	40	0.83 (0.1–2.95)
Bladder base	28	1.25 (0.2–12.25)
Anterior	5	0.75 (0.4–1.7)

Values are median (range).

of benign tissue was 1.48 (95% confidence interval, 0.0856 to 1.535).

Table 2 summarises the number of cases with benign tissue at each anatomical location. The most frequent location of benign prostatic glandular tissue at the surgical margin was the apex and bladder base. Forty of 55 patients had benign prostatic tissue involving the apex and 22 of 55 had only apex involvement. Benign prostatic tissue at the base was found in 28 of 55 patients and bladder base involvement alone was seen in 14 of 55 patients. Benign prostatic tissue at the inked margins was also seen in the anterior prostate in five cases. None of the cases in our study showed involvement of the posterior prostate with benign prostate epithelial tissue at the resection margin. There were no significant associations between anatomical location and PSA recurrence using Fisher’s exact test. In addition, the anatomical location of the benign tissue was not significantly associated with patient characteristics.

Table 3 summarises the extent of margin involvement according to anatomical location. The mean length of the benign tissue was 2.19 mm, ranging from 0.1 mm to 14.7 mm. The length of the benign tissue at the inked margins (extent) was also tested for an association with patient characteristics and PSA recurrence. There was no significant association between the extent of benign prostatic tissue at the inked margin and PSA recurrence or patient characteristics.

DISCUSSION

The measurement of serum PSA values is useful for the postoperative evaluation of patients with prostate cancer. However, some have proposed that PSA recurrence may result from benign prostatic tissue left within the patient after radical prostatectomy. We undertook our study to determine whether the presence, location, and extent of benign prostatic tissue at the inked surgical margins of radical prostatectomy specimens have an influence on patient outcome. We found that the presence, anatomical location, and extent of benign prostatic tissue at the inked margin did not correlate with clinicopathological characteristics or postoperative PSA rises.

There are a limited number of previous studies that have addressed this topic. A previous study following 86 patients after radical prostatectomy showed similar findings.¹⁶ The study followed the postoperative PSA values of patients, with a median follow up time of 63 days. Only two patients showed postoperative PSA rises within this time frame, neither of whom had benign glands present at the surgical margins. Only nine of the 86 patients (11%) in this earlier study showed benign prostatic epithelium at the inked surgical margin, in contrast to our finding of 28%.¹⁶ Other studies have reported higher incidences of benign prostatic epithelium at the surgical margins, ranging from 37% to 90%.^{17 18} An earlier study by Ravery concluded that capsular incision (benign tissue at margin) was not associated with postoperative PSA increases, or biochemical failure.¹⁹ In addition, Barocas *et al* showed no significant difference in disease recurrence in patients with “isolated capsular incision”.²⁰ An additional study by Ravery concluded that

postoperative PSA rises are caused by the presence of unconfined tumour, which was probably overlooked on initial microscopic examination.¹⁹ That study involved re-analysing and reprocessing, if needed, seven patients in whom the disease had initially been classified as organ confined, but who subsequently developed recurrent disease. Of these patients, three of seven were upstaged after re-evaluation of the original slides. Of the remaining four, additional levels were cut, three of which resulted in positive margins. Only one of seven remained negative after the more detailed evaluation.¹⁹ Taken together, these findings indicate that benign epithelial tissue at the surgical margin is not associated with postoperative PSA rises. We conclude that the presence of benign prostatic tissue at the surgical margins is not associated with adverse prognostic features and does not have prognostic relevance; therefore, we do not advocate reporting the presence of benign prostatic tissue at the inked margins as a standard part of the surgical pathology report on prostatectomy specimens.

One possible explanation for why benign epithelium is not correlated with postoperative PSA increases could be the relatively small volume of glandular tissue left behind. Most often, the benign tissue forms only a small area, located in the apex. In addition, this area may be devitalised as a result of surgical procedures, and it is possible that no true vital glandular tissue remains. However, this does not entirely exclude the possibility of isolated cases of PSA recurrence as a result of large amounts of benign prostate epithelium remaining within the patient postoperatively. In our study, benign prostatic epithelium was most often seen in the apex and base, with the apex being the most frequent location, similar to previous studies.¹⁶ The higher occurrence of benign epithelial tissue at the apex margin reflects the difficulty of visualising the apex adequately at the time of resection. A small proportion of the cases demonstrated benign epithelial tissue in the anterior part of the prostate. The main limitation of our study is short follow up. A strength of our current study is the large patient population, with all the specimens processed using the whole mount technique.

“We do not advocate reporting the presence of benign prostatic tissue at the inked margins as a standard part of the surgical pathology report on prostatectomy specimens”

Postoperative PSA measurement remains a powerful tool for the follow up of patients with prostate cancer after radical prostatectomy. A study by Pound *et al* showed that with longterm follow up, 15% of patients with prostate cancer

Take home messages

- Benign prostatic glandular tissue was frequently found at the inked margins of the apex and was uncommon in the anterior or posterior prostate
- The presence, anatomical location, and length of benign prostatic tissue at the inked margin were not significantly associated with age, preoperative prostate specific antigen (PSA) value, prostate weight, pathological stage, tumour volume, largest tumour dimension, Gleason score, extraprostatic extension, seminal vesical invasion, tumour multifocality, perineural invasion, or PSA recurrence
- The presence of benign prostatic epithelial tissue at the inked surgical margins had no prognostic relevance

eventually developed postoperative PSA increases.¹ Of these, 34% developed metastatic disease within the study period, with a median time to metastasis of eight years from the first detectable postoperative PSA increase.¹ Because benign epithelium at surgical margins is not correlated with postoperative PSA rises, postoperative PSA increases should in most cases continue to be considered “biochemical failure”. Additional longterm follow up would be needed to evaluate what percentage of these patients will progress to metastatic disease or clinical failure.

In summary, benign prostatic tissue was frequently found at the inked margins of the apex and bladder base. It was unusual in the anterior or posterior prostate. The presence of benign prostatic epithelial tissue at the inked surgical margins had no prognostic relevance, and was not associated with postoperative PSA recurrence.

Authors' affiliations

K M Kernek, L Cheng, Department of Pathology and Laboratory Medicine, Indiana University School of Medicine, University Hospital 3465, 550 North University Blvd, Indianapolis, IN 46202, Indiana, USA
M O Koch, Department of Urology, Indiana University School of Medicine

J K Daggy, B E Juliar, Division of Biostatistics, Indiana University School of Medicine

REFERENCES

- 1 **Pound CR**, Partin AW, Eisenberger MA, *et al*. Natural history of progression after PSA elevation following radical prostatectomy. *JAMA* 1999;**281**:1591-7.
- 2 **Frazier HA**, Robertson JE, Humphrey PA, *et al*. Is prostate specific antigen of clinical importance in evaluating outcome after radical prostatectomy? *J Urol* 1993;**149**:516-18.
- 3 **Cheng L**, Darson MF, Bergstralh EJ, *et al*. Correlation of margin status and extraprostatic extension with progression of prostate carcinoma. *Cancer* 1999;**86**:1775-82.
- 4 **Cheng L**, Slezak J, Bergstralh EJ, *et al*. Preoperative prediction of surgical margin status in prostate cancer patients treated by radical prostatectomy. *J Clin Oncol* 2000;**18**:2862-8.
- 5 **Emerson RE**, Koch MO, Daggy J, *et al*. Closest distance between tumor and resection margin in radical prostatectomy specimens: lack of prognostic significance. *Am J Surg Pathol* 2005;**29**:225-9.
- 6 **Eichelberger LE**, Cheng L. Does pT2b prostate carcinoma exist? Critical appraisal of the 2002 TNM classification of prostate carcinoma. *Cancer* 2004;**100**:2573-6.
- 7 **Poulos CK**, Daggy JK, Cheng L. Prostate needle biopsies: multiple variables are predictive of final tumor volume in radical prostatectomy specimens. *Cancer* 2004;**101**:527-32.
- 8 **Poulos CK**, Koch MO, Eble JN, *et al*. Bladder neck invasion is an independent predictor of prostate-specific antigen recurrence. *Cancer* 2004;**101**:1563-8.
- 9 **Hong H**, Koch MO, Foster RS, *et al*. Anatomic distribution of periprostatic adipose tissue: a mapping study of 100 radical prostatectomy specimens. *Cancer* 2003;**97**:1639-43.
- 10 **Gleason DF**, Mellinger GT. Prediction of prognosis for prostatic adenocarcinoma by combined histological grading and clinical staging. Veterans' administration cooperative urologic research group. *J Urol* 1974;**111**:58-64.
- 11 **Fleming ID**, Cooper JS, Henson DE, *et al*. *AJCC cancer staging manual*. Philadelphia: Lippincott Raven, 1997.
- 12 **Humphrey PA**, Vollmer RT. Intraglandular tumor extent and prognosis in prostatic carcinoma: application of a grid method to prostatectomy specimens. *Hum Pathol* 1990;**21**:799-804.
- 13 **Eichelberger LE**, Koch MO, Daggy JK, *et al*. Predicting tumor volume in radical prostatectomy specimens from patients with prostate cancer. *Am J Clin Pathol* 2003;**120**:386-91.
- 14 **Koch MO**, Foster RS, Bell B, *et al*. Characterization and predictors of prostate specific antigen progression rates after radical retropubic prostatectomy. *J Urol* 2000;**164**:749-53.
- 15 **Babaian RJ**, Troncso P, Bhadkamkar VA, *et al*. Analysis of clinicopathologic factors predicting outcome after radical prostatectomy. *Cancer* 2001;**91**:1414-22.
- 16 **Shah R**, Bassily N, Wei J, *et al*. Benign prostatic glands at surgical margins of radical prostatectomy specimens: frequency and associated risk factors. *Urology* 2000;**56**:721-5.
- 17 **Boccon-Gibod L**, Ravary V, Vordos D, *et al*. Radical prostatectomy for prostate cancer: the perineal approach increases the risk of surgically induced positive margins and capsular incisions. *J Urol* 1998;**160**:1383-5.
- 18 **Allsbrook WC**, Wade ZK, Scott PA, *et al*. Benign prostatic epithelium is commonly present at the surgical margins of radical prostatectomy. *Mod Pathol* 2002;**15**:632A.
- 19 **Ravary V**. The significance of recurrent PSA after radical prostatectomy: benign versus malignant sources. *Semin Urol Oncol* 1999;**17**:127-9.
- 20 **Barocas DA**, Han M, Epstein JI, *et al*. Does capsular incision at radical retropubic prostatectomy affect disease-free survival in otherwise organ-confined prostate cancer? *Urology* 2001;**58**:746-51.



The presence of benign prostatic glandular tissue at surgical margins does not predict PSA recurrence

K M Kernek, M O Koch, J K Daggy, et al.

J Clin Pathol 2005 58: 725-728
doi: 10.1136/jcp.2004.024182

Updated information and services can be found at:
<http://jcp.bmj.com/content/58/7/725.full.html>

These include:

References

This article cites 19 articles, 2 of which can be accessed free at:
<http://jcp.bmj.com/content/58/7/725.full.html#ref-list-1>

Email alerting service

Receive free email alerts when new articles cite this article. Sign up in the box at the top right corner of the online article.

Topic Collections

Articles on similar topics can be found in the following collections

[Prostate cancer](#) (49 articles)
[Urological cancer](#) (117 articles)

Notes

To request permissions go to:
<http://group.bmj.com/group/rights-licensing/permissions>

To order reprints go to:
<http://journals.bmj.com/cgi/reprintform>

To subscribe to BMJ go to:
<http://group.bmj.com/subscribe/>