

PostScript

CORRESPONDENCE

If you have a burning desire to respond to a paper published in the *Journal of Clinical Pathology*, why not make use of our "rapid response" option?

Log on to our website (www.jclinpath.com), find the paper that interests you, and send your response via email by clicking on the "eLetters" option in the box at the top right hand corner.

Providing it isn't libellous or obscene, it will be posted within seven days. You can retrieve it by clicking on "read eLetters" on our homepage.

The editors will decide as before whether to also publish it in a future paper issue.

Ectopic supernumerary kidney presenting as inguinal hernia

Supernumerary kidney is one of the least common forms of congenital renal abnormality and is usually discovered when it presents complications.^{1,2} The diagnosis of supernumerary kidney is confined to a mass of renal tissue that has no parenchymatous connection with the definitive kidney.³ The published literature on supernumerary kidney is scarce. Here, we report a case that presented as indirect inguinal hernia.

A 36 year old man suffering from chronic asthma presented with a painful swelling in the left inguinal region, which he first noticed one month previously. The swelling measured 5.0 × 4.0 cm, was situated on the medial aspect of the inguinal ligament, and was reducible with positive cough impulse. The scrotum on the left side was empty. An abdominal scan showed normal organs, including two normal kidneys. A diagnosis of indirect inguinal hernia with undescended left testis was made and the patient underwent surgery. The hernial sac included an atrophic testis (2.0 × 1.5 × 1.0 cm) and another small bean shaped mass (3.0 × 2.0 × 2.0 cm), which was studied histopathologically.

The testis showed a positive string sign on the cut surface. The other mass had a grey white cut surface, with an intact capsule. Sections of the testis showed seminiferous tubules with thickened basement membranes

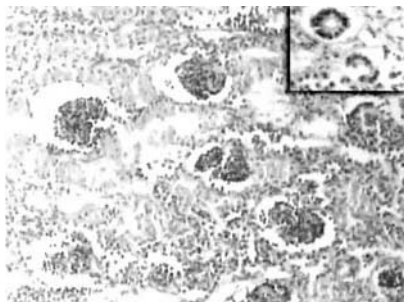

Figure 1 Microphotograph showing primitive glomeruli and tubules (inset).

containing inactive germ cells and some having only Sertoli cells. These features were consistent with cryptorchid testis. Sections from the bean shaped mass showed a kidney-type structure, with cortex and medulla. The glomeruli and tubules were seen in their developmental stages, with immature mesenchymal tissue interspersed in between (fig 1). These features were consistent with a diagnosis of supernumerary kidney because the patient had two normal kidneys in the abdomen.

A supernumerary kidney is a rare congenital anomaly. About 70 such cases have been reported in the international literature.⁴ However, to the best of our knowledge, this is the first reported case of a supernumerary kidney in a hernial sac. A supernumerary kidney usually lies within the renal fascia, caudal to the normal organ. Because the kidney was located below the second lumbar vertebra in this case, we prefer to classify it as an ectopic supernumerary kidney.²

In humans, the metanephros or permanent kidney begins to develop early in the 5th week of intrauterine life. It arises from two different sources. The collecting tubules, renal pelvis, and ureter develop from the lower end of the Wolffian duct, whereas the glomeruli and tubules differentiate from the caudal end of the nephrogenic cord (metanephric mesoderm).³ The lesion is thought to be caused by the formation of two ureteric buds arising from different positions in the Wolffian duct, which reach the metanephric blastema at such divergent positions that aberrant divisions result in two kidneys on one side. The supernumerary kidney is smaller, can be hypoplastic, and is usually not well organised histologically.³ This case has been reported for its rarity and also because of its unusual presentation with cryptorchid testis as inguinal hernia.

V Kusuma, M Hemalata, B V Suguna

Department of Pathology, Kempegowda Institute of Medical Sciences (KIMS), VV Puram, Bangalore 560004, India; jreddy@nimhans.kar.nic.in

References

- 1 Jira H, Ghadouane M, Kasmaoui EH, *et al*. A supernumerary kidney. Apropos of a case. *Ann Urol (Paris)* 2002;**36**:236-9.
- 2 Bernik TR, Ravnich DJ, Bernik SF, *et al*. Ectopic supernumerary kidney, a cause of para-aortic mass: case report and review. *Am Surg* 2001;**67**:657-9.
- 3 Porter KA. Development and congenital malformations of the kidneys. In: Symmers W St C, eds. *The kidneys and the urinary tract*, 3rd ed, Vol. 8. Edinburgh: Churchill Livingstone, 1992:47-72.
- 4 Gonzalvo Perez V, Ramada Benlloch F, Blasco Alfonso JE, *et al*. Supernumerary kidney with ectopic ureteral opening. *Actas Urol Esp* 1992;**16**:796-8.
- 5 Flyer MA. Ectopic supernumerary kidney, another cause of a pelvic mass. *Abdom Imaging* 1994;**19**:374-5.

Oncocytic carcinoid tumour of the bladder

We report the case of a 77 year old man who underwent an ultrasound scan for lower abdominal pain. He had no significant medical history. The scan identified a small inguinal hernia, explaining his discomfort. A

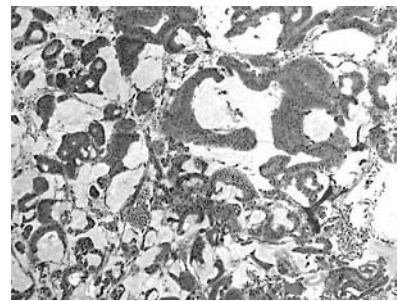


Figure 1 Haematoxylin and eosin stain of the neoplastic tissue (original magnification, ×50).

small filling defect in the bladder was also incidentally reported. Urinalysis revealed no abnormality. A rigid cystoscopy was performed. This revealed a raised swelling with normal appearance of the overlying mucosa, superior to the midpoint of the interureteric ridge. The lesion was approximately 1 × 1.5 cm in diameter. This was completely resected to muscle and sent for histology.

Histopathological examination revealed a neoplasm composed of large cuboidal and columnar cells, with abundant granular eosinophilic cytoplasm and large nuclei, with occasional macronucleoli (fig 1), which formed tubules, cords, and cribriform areas. The stroma was oedematous and contained lakes of mucin. The tissue stained negatively for prostate specific antigen and cytokeratin 20. Positive staining was seen for cytokeratin 7, synaptophysin (fig 2) and chromogranin. Therefore, the tumour was classified as a carcinoid tumour of the oncocytic variety.

The patient underwent a subsequent computed tomography scan of his chest and abdomen, and no other tumour sites were found. A 24 hour urine collection for 5-hydroxyindoleacetic acid did not suggest residual tumour.

Oncocytic carcinoid tumours are rare. They are a variant of carcinoid tumour whose appearance has ultrastructural similarities to an oncocytoma and are recognised by their abundant eosinophilic and granular cytoplasm. Oncocytic changes are often seen in the salivary and thyroid glands; they are thought to be of a degenerative nature. It has been suggested that the change within a carcinoid tumour may result from local environmental changes, possibly ischaemia.¹

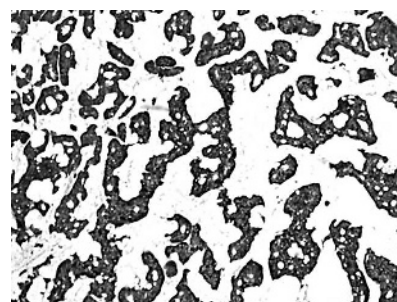


Figure 2 Tissue stained positive for synaptophysin (original magnification, ×50).

Previous reports of these tumours have been in the lung,² nasopharynx, thymus, and in one report, the kidney.³ The tumours are malignant and capable of metastatic spread. They can also result in a carcinoid syndrome, so that full resection is recommended.

This case is worthy of note in view of its rarity. Carcinoid tumours of the bladder have been reported sporadically, but this is the first report of an oncocyctic type. The appearance of the tumour was somewhat innocuous, but early excision biopsy averted potentially more serious consequences later on.

Acknowledgement

Dr P Harnden (St James University Hospital, Leeds, UK) reviewed the pathological findings.

J E McCabe, S Das

Department of Urology, Countess of Chester Hospital, Liverpool Road, Chester, CH2 1UL UK; johnemccabe@lineone.net

P Dowling, B N Hamid

Department of Pathology, Countess of Chester Hospital

B A Pettersson

Department of Urology, Countess of Chester Hospital

References

- 1 Bonilos DS, Bensch KG, Watt T, *et al.* Pulmonary oncocytes in prolonged hypoxia. *Exp Mol Pathol* 1977;**26**:92–102.
- 2 Matsumoto S, Muranaka T, Hanada K, *et al.* Oncocytic carcinoid of the lung. *Radiat Med* 1993;**11**:63–5.
- 3 Hannah J, Lippe B, Lai-Goldman M, *et al.* Oncocytic carcinoid of the kidney associated with periodic Cushing's syndrome. *Cancer* 1988;**61**:2136–40.
- 4 Dome B, Paku S, Somlai B, *et al.* Vascularization of cutaneous melanoma involves vessel co-option and has clinical significance. *J Pathol* 2002;**197**:355–62.
- 5 Sood AK, Hendrix MJ. The complexity of tumor vascularity. *Cancer Biol Ther* 2003;**2**:257–8.
- 6 Rafii S, Lyden D, Benezra R, *et al.* Vascular and haematopoietic stem cells: novel targets for anti-angiogenesis therapy? *Nat Rev Cancer* 2002;**2**:826–35.
- 7 Hristov M, Erl W, Weber PC. Endothelial progenitor cells: mobilization, differentiation, and homing. *Arterioscler Thromb Vasc Biol* 2003;**23**:1185–9.
- 8 Jiang Y, Jahagirdar BN, Reinhardt RL, *et al.* Pluripotency of mesenchymal stem cells derived from adult marrow. *Nature* 2002;**418**:41–9.
- 9 Corbeil D, Roper K, Hellwig A, *et al.* The human AC133 hematopoietic stem cell antigen is also expressed in epithelial cells and targeted to plasma membrane protrusions. *J Biol Chem* 2000;**275**:5512–20.
- 10 Asahara T, Kawamoto A. Endothelial progenitor cells for postnatal vasculogenesis. *Am J Physiol* 2004;**287**:C572–9.

Monckeberg medial calcific sclerosis mimicking malignant calcification pattern at mammography

Monckeberg medial calcific sclerosis (MCS) is a ring-like calcification of the vascular media of small to medium sized vessels without associated intimal thickening. Almost exclusively, MCS is the underlying condition in what is referred to as breast arterial calcification (BAC) detected at mammography. BAC is a relatively common finding. The classic radiographic pattern of BAC is the "railroad track" pattern, which appears as linear parallel calcifications, and is a reflection of the circumferential pattern of calcification in MCS¹; it is easily interpreted as benign.

We recently encountered an atypical microcalcification pattern of MCS mimicking malignancy in a 64 year old woman discovered at routine mammography. She had no risk factors for breast cancer. There was no history of breast trauma or surgery, renal disease, or parathyroid problems. The patient had non-insulin dependent diabetes mellitus. Coronary artery disease was present as identified by an episode of retrosternal chest pain and a stress test showed ST segment elevation in the electrocardiogram. No palpable abnormalities were present in the breast or axilla.

This atypical pattern was present together with popcorn-like calcification of a hyalinised fibroadenoma and typical benign microcalcifications. The atypical calcification was present as medium to high density clustered calcifications in a curved and branching pattern. This pattern is usually caused by calcium phosphate, and is typically associated with malignancy, compared with low density amorphous calcifications, which are caused by calcium oxalate, and are associated with benign conditions.¹

Wire localised excision of the clustered calcifications was performed and the specimen radiographs showed that suspicious microcalcification clusters were included in a block. Sections corresponding to suspicious microcalcifications had Monckeberg medial calcific sclerosis in small to medium sized vessels. These were both ring-like classic circumferential areas of calcification and discontinuous calcification foci in arterial media.

Endothelial progenitor cells in non-small cell lung cancer

We read with interest the article by Hilbe *et al* concerning the contribution of endothelial progenitor cells (EPCs) to the vasculature in non-small cell lung cancer (NSCLC).¹ In their study, the authors conclude that "increased numbers of CD133 positive EPCs can be found in NSCLC tissue and these cells seem to contribute to the formation of capillaries". Although it is interesting and worthy of further study, in our view, the evidence presented in their paper is unconvincing. However, the problems are not apparent to readers unfamiliar with the background or pitfalls of this specialised topic.

The development of a vascular network plays a crucial role in the development and function of normal tissues and organs, in addition to tumour growth and metastasis. Understanding how tumours acquire their vasculature is indispensable for developing novel therapeutic approaches. However, the vascularisation of tumours is very complex, consisting of sprouting, vessel cooption, glomeruloid angiogenesis, mosaic vessel formation, vascular mimicry, and intussusceptive angiogenesis.^{2–5} Furthermore, there is emerging evidence that putative angioblasts, also known as EPCs, might persist in adult life and contribute to the vascularisation of tumours.⁶

EPCs have been isolated from peripheral blood and bone marrow. Similar to embryonic angioblasts, EPCs have the capacity to proliferate and differentiate into mature endothelial cells (ECs). To date, no clear definition exists as to when an EPC turns into a mature, fully differentiated endothelial cell in vivo. Early EPCs (localised in the bone marrow or immediately after migration into

the circulation) are CD133+/CD34+/VEGFR-2+ (vascular endothelial growth factor receptor 2 positive) cells, whereas circulating EPCs are positive for CD34/VEGFR-2/CD31/VE-cadherin, lose CD133, and begin to express von Willebrandt factor. In general, it is widely accepted that the loss of CD133 reflects the transformation of early circulating EPCs into more mature endothelial-like cells.⁷

Hilbe *et al* identified early EPCs by CD133 labelling not in peripheral blood or bone marrow, but in the endothelial tubes of NSCLC tissue. The key evidence for their identity came from immunohistochemical studies.¹

In our view, there are three problems with the arguments put forward by Hilbe *et al*.¹ First, the presumed localisation of EPCs on serial frozen sections is not convincing because neither multiple microvessel labelling for CD133 and EC markers nor immunoelectron microscopical examination was performed. Because the cellular boundaries cannot be seen in the figures provided, it is unclear what types of cells are CD133+.

Second, CD133 is not exclusively expressed on early—but not circulating or committed—EPCs. In addition to being expressed on haemopoietic stem cells, CD133 also serves as a marker for non-haemopoietic progenitor cells, such as neural stem cells, embryonic stem cell lines, and adult stem cells with a pluripotent differentiation capacity.⁸ Furthermore, CD133 was found to be expressed on tumour cells of epithelial origin.⁹ The possibility that the CD133+ cells in the NSCLC tissue are not ECs was not explored.

Third, a convincing argument for the presence of EPCs in the NSCLC tissue depends on the unequivocal identification of this cell type. It is not clear why Hilbe *et al* did not use more than one early stem cell marker to detect EPCs.¹ Their method differs from several earlier studies that used different antibody combinations.¹⁰

The involvement of alternative vascularisation mechanisms—including vasculogenesis—in the tumour blood supply has broad biological and medical importance. We found the message emerging from the Hilbe study a valuable contribution to our knowledge of the vasculogenesis in tumour tissue. Our critical comments are intended simply as a reminder that the extent of these phenomena is still unclear, and can only be determined by rigorous examination.

B Dome

Department of Pulmonary Oncology, National Institute of Pulmonology, Pihenó u 1–3, Budapest, H-1529, Hungary; domeb@yahoo.com

J Timar

National Institute of Oncology, H-1122, Ráth Gy. u. 7–9, Budapest, Hungary

G Ostoros

Department of Pulmonary Oncology, National Institute of Pulmonology

S Paku

First Institute of Pathology and Experimental Cancer Research, Semmelweis University, H-1085, Ulloi út 26, Budapest, Hungary

References

- 1 Hilbe W, Dirnhofer S, Oberwasserlechner F, *et al.* CD133 positive endothelial progenitor cells contribute to the tumour vasculature in non-small cell lung cancer. *J Clin Pathol* 2004;**57**:965–9.
- 2 Paku S, Paweletz N. First steps of tumor-related angiogenesis. *Lab Invest* 1991;**65**:334–46.

This atypical pattern posing a diagnostic dilemma requires excision for histopathological assessment. It has been reported earlier,^{2,3} and is probably caused by non-circumferential and discontinuous foci of calcification in the vascular media; these calcific microliths are probably seen in the early stages of development of MCS,² and may mimic linear, curved, or branching patterns of microcalcification clusters indicating malignancy.⁴

The pathogenesis of MCS/BAC is thought to be related to several factors, including age related change, diabetes mellitus, chronic renal failure, and coronary artery disease.

Pecchi *et al* showed that the presence and severity of BAC strongly correlated with the extent of coronary atherosclerosis, as determined by the amount of coronary calcium detected by multislice computed tomography,³ and BAC may indeed be a surrogate marker of coronary artery disease. Although coronary artery disease is almost always the result of intimal atherosclerosis, a disease different from MCS, the association may be reflective of shared pathways of calcium deposition.

In summary, this report highlights the atypical calcification pattern of Monckeberg medial calcific sclerosis mimicking malignant calcifications in breast requiring excision for diagnosis. This benign vascular calcification may also be a marker of coronary artery disease.

A Saxena

Department of Pathology, Royal University Hospital,
103 Hospital Drive, Saskatoon, SK, S7N 0W8
Canada; saxena@sask.usask.ca

I C Waddell

Department of Radiology, Victoria Hospital, Prince
Albert, Saskatchewan, S6V ST4 Canada

R W Friesen

Department of Surgery, Victoria Hospital

R T Michalski

Department of Pathology, Victoria Hospital

References

- 1 Bassett LW. Mammographic analysis of calcifications. *Radiol Clin North Am* 1992;**30**:93–105.
- 2 Kragel PJ, Aquino MO, Fiorella R, *et al*. Clinical, radiographic, and pathologic features of medial calcific sclerosis in the breast. *South Med J* 1997;**90**:518–21.
- 3 Kim H, Greenberg JS, Javitt MC. Breast calcifications due to Monckeberg medical calcific sclerosis. *Radiographics* 1999;**19**:1401–3.
- 4 Knutzen AM, Givold JJ. Likelihood of malignant disease for various categories of mammographically detected, nonpalpable breast lesions. *Mayo Clin Proc* 1993;**68**:454–60.
- 5 Pecchi A, Rossi R, Coppi F, *et al*. Association of breast arterial calcifications detected by mammography and coronary artery calcifications quantified by multislice CT in a population of post-menopausal women. *Radiol Med (Torino)* 2003;**106**:305–12.

Extramedullary haemopoiesis

Extramedullary haemopoiesis usually occurs in association with haematological disorders—in particular, myelofibrosis—and normally occurs in the reticulo-endothelial system, involving the liver, spleen, and lymph nodes. The kidneys and other organs are less often affected. In addition, single lineage haemopoiesis may occur, although it does not usually form mass-like lesions. This report

describes a focus of erythropoiesis occurring in a renal cell carcinoma.

A 55 year old woman underwent a right radical nephrectomy and the specimen measured 10 × 6 × 6 cm. A 2.5 × 2.0 × 2.0 cm circumscribed nodule was present. Microscopic examination showed a clear cell renal carcinoma, nuclear grade 2, with central cystic degeneration. A single, extremely small focus of erythropoiesis was present within a central small capillary, consisting of approximately 20 nucleated red blood cells (fig 1). A preoperative haemoglobin concentration was normal, at 132 g/litre (normal range, 115–185).

Extramedullary haemopoiesis has been reported in the kidneys, usually associated with idiopathic myelofibrosis.^{1,2} A renal cell carcinoma associated with a perirenal liposarcoma and extramedullary haemopoiesis has been documented.³ A superficial, spindle cell lipoma from the neck with extramedullary erythropoiesis has also been reported.⁴ Extramedullary haemopoiesis also occurs in hepatic angiomyolipoma (but not in renal angiomyolipoma) and in other hepatic tumours, an occurrence thought to be related to the hepatic sinusoidal endothelium.⁵ Foci of haemopoiesis or erythropoiesis have been described adjacent to recent, acute myocardial infarcts, thought to be a manifestation of altered cytokine production.⁶ Isolated megakaryocytes are a normal occurrence in the capillaries of the lung.⁷ They have been cited to occur in sentinel lymph nodes,⁸ although in lymph nodes they are usually present as part of microscopic foci of erythropoiesis and granulopoiesis. Extramedullary haemopoiesis usually occurs in tissues with a milieu that supports the proliferation of primitive haemopoietic bone marrow elements. Filtration of clonogenic bone marrow cells within supportive tissues is one pathogenetic mechanism considered in the pathogenesis of extramedullary haemopoiesis, whereas the migratory nature of megakaryocytes may explain their presence in aberrant sites in the absence of extramedullary haemopoiesis. Although this case may represent a transitory erythropoietic focus, a rare erythropoietin induced occurrence of erythropoiesis within

a renal cell carcinoma is perhaps a more plausible explanation. Although it has been reported that 74% of renal cell carcinomas show strong erythropoietin immunolocalisation,⁹ foci of associated erythropoiesis appear to be unusual.

J D Coyne

Wythenshawe Hospital, Wythenshawe, Manchester
M208LR, UK; johncoyne@doctors.org.uk

References

- 1 Schnuelle P, Waldherr R, Lehmann KJ, *et al*. Idiopathic myelofibrosis with extramedullary haematopoiesis in the kidneys. *Clin Nephrol* 1999;**52**:256–62.
- 2 Woodward N, Ancliffe P, Griffiths MH, *et al*. Renal myelofibrosis: an unusual cause of renal impairment. *Nephrol Dial Transplant* 2000;**15**:257–8.
- 3 Lewis DJ, Moul JW, Williams SC, *et al*. Perirenal liposarcoma containing extramedullary haematopoiesis associated with renal cell carcinoma. *Urology* 1994;**43**:106–9.
- 4 Sciot R, Bekaert J. Spindle cell lipoma with extramedullary haematopoiesis. *Histopathology* 2001;**39**:215–16.
- 5 Tsui WMS, Colombari R, Portman BC, *et al*. Hepatic angiomyolipoma: a clinicopathologic study of 30 cases and delineation of unusual morphologic variants. *Am J Surg Pathol* 1999;**23**:34–48.
- 6 Goldman BI, Wurzel J. Haematopoiesis/erythropoiesis in myocardial infarcts. *Mod Pathol* 2001;**14**:589–94.
- 7 Zucker-Franklin D, Philipp CS. Platelet production in the pulmonary capillary bed: new ultrastructural evidence for an old concept. *Am J Pathol* 2000;**157**:69–74.
- 8 Hoda SA, Reselkova E, Yusuf Y, *et al*. Megakaryocytes mimicking metastatic breast carcinoma. A potential trap in the interpretation of sentinel lymph nodes. *Arch Pathol Lab Med* 2002;**126**:618–20.
- 9 Clark D, Kersting R, Rogiani AM. Erythropoietin immunolocalisation in renal cell carcinoma. *Mod Pathol* 1998;**11**:24–8.

CALENDAR OF EVENTS

Full details of events to be included should be sent to Maggie Butler, Technical Editor JCP, The Cedars, 36 Queen Street, Castle Hedingham, Essex CO9 3HA, UK; email: maggie.butler2@btopenworld.com

Diagnostic Histopathology of Breast Disease

9–13 May 2005, Hammersmith Hospital and Imperial College, London, UK

Further details: Wolfson Conference Centre, Hammersmith Hospital, Du Cane Road, London W12 0NN, UK. (Tel +44 (0)20 8383 3117/3227/3245; Fax +44 (0)20 8383 2428; e-mail wcc@ic.ac.uk)

Practical Pulmonary Pathology

26–29 July 2005, Royal Brompton Hospital, London, UK

Further details: Professor B Corrin, Brompton Hospital, London SW3 6NP, UK. (Fax +44 (0)20 7 351 8293; e-mail b.corrin@ic.ac.uk)

Association of Clinical Pathologists' National Scientific Meeting

16–17 June 2005, Royal College of Physicians, London, UK

Further details: ACP Central Office, 189 Dyke Road, Hove BN3 1TL, UK. (Tel +44 (0)1273 775700; e-mail info@pathologists.org.uk)

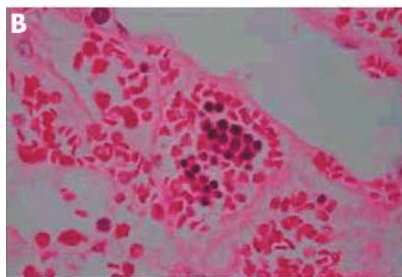
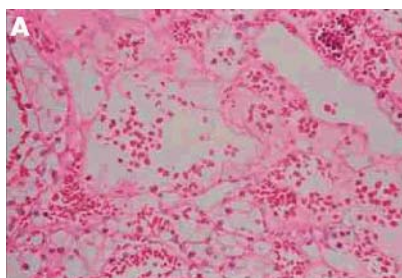


Figure 1 (A) Low power appearance of renal cell carcinoma with focus of erythropoiesis. (B) Intracapillary erythropoiesis.



Extramedullary haemopoiesis

J D Coyne

J Clin Pathol 2005 58: 448

Updated information and services can be found at:
<http://jcp.bmj.com/content/58/4/448.full.html>

These include:

References

This article cites 9 articles, 1 of which can be accessed free at:
<http://jcp.bmj.com/content/58/4/448.full.html#ref-list-1>

Article cited in:
<http://jcp.bmj.com/content/58/4/448.full.html#related-urls>

Email alerting service

Receive free email alerts when new articles cite this article. Sign up in the box at the top right corner of the online article.

Notes

To request permissions go to:
<http://group.bmj.com/group/rights-licensing/permissions>

To order reprints go to:
<http://journals.bmj.com/cgi/reprintform>

To subscribe to BMJ go to:
<http://group.bmj.com/subscribe/>