

CASE REPORT

Initial diagnosis of small lymphocytic lymphoma in parotidectomy for Warthin tumour, a rare collision tumour

A Saxena, B Memauri, W Hasegawa

J Clin Pathol 2005;58:331–333. doi: 10.1136/jcp.2004.019760

Warthin tumours (WT) and malignant lymphomas are only rarely associated, and most are examples of involvement of the lymphoid stroma of WT by a disseminated lymphoma. This report describes a case where excision of a parotid mass led to the initial diagnosis of WT and small lymphocytic lymphoma (SLL). The diagnosis of SLL was confirmed by immunohistochemistry and molecular studies. The patient had stage IV A disease and is currently in chemotherapy induced complete remission. This case highlights the extremely rare association of SLL with WT and the importance of evaluation of the WT stroma, where the pale proliferation centres of SLL may mimic germinal centres of reactive lymphoid nodules.

Warthin tumour (WT) is thought to be a benign neoplasm of the salivary gland epithelium with a proliferative epithelial component associated with a variably prominent lymphoid stroma.¹ The lymphoid stroma is reactive in most cases, often with prominent secondary lymphoid follicles.² Although uncommon, the lymphoid stroma in WT may be involved by disseminated non-Hodgkin lymphoma (NHL).^{2–11} The diagnosis of lymphoma may already be known in these patients.^{2–7}

“Warthin tumour is thought to be a benign neoplasm of the salivary gland epithelium”

The first time diagnosis of NHL at the time of histopathological assessment of a WT excision specimen is extremely rare, with 14 cases in the English language literature.^{8–17} Staging procedures usually identify disseminated disease in these patients,^{8 10 11 15} although there are reports of the disease being localised to the parotid region.^{9 11 17} Follicular lymphoma is the most common lymphoma presenting as a collision tumour with WT.^{8–13 15 16}

We are aware of only one other case of small lymphocytic lymphoma (SLL) in WT in the English language literature,¹⁴ and report a second case of SLL detected in the diagnostic WT specimen. The diagnosis was confirmed by immunohistochemistry and molecular studies, and staging procedures immediately after diagnosis demonstrated disseminated disease.

CASE REPORT

This 60 year old man was seen for a swelling in the left parotid region of three to four years' duration. On examination, the mass was firm, mobile, and non-tender. There were no systemic symptoms. He underwent excision of the mass. He also had chronic obstructive pulmonary disease, type II diabetes mellitus, obstructive sleep apnoea, and a past history of myocardial infarction.

Pathological findings

The superficial parotidectomy specimen was 6.5 × 4.0 × 3.0 cm, with a 2.3 cm diameter tan grey lesion close to one of the resection margins. There were satellite nodules measuring 0.6 to 1.0 cm in diameter adjacent to the main lesion.

In the histological sections of the largest lesion, classic findings of Warthin tumour were present; these included oncocytic epithelium—tall columnar cells with eosinophilic granular cytoplasm—present as papillary proliferations and lining the cystic areas, which were filled with pale eosinophilic fluid admixed with little cell debris (fig 1A).

The intervening stroma had a diffuse infiltrate of small lymphoid cells with no necrotic areas. There were interspersed small pale poorly defined nodular areas, the proliferation centres of which were composed primarily of large lymphoid cells with prominent nucleoli, the “para-immunoblasts” (fig 1B). Both large and small lymphoid cells expressed CD20, CD5, and CD23; these cells were immunonegative for CD3 and CD10 (fig 2). The proliferative fraction of the lymphoid neoplasm was less than 5%, mostly in the proliferation centres. There was a small background population of T cells.

The immunoglobulin heavy chain gene rearrangement was clonal, as identified by single step polymerase chain reaction using consensus primers against the VDJ region. There was no molecular evidence of the t(14, 18) or t(11, 14) translocations.

Staging and clinical course

The total leucocyte and the absolute lymphocyte counts were within the reference ranges at the time of diagnosis. Small superficial cervical and axillary lymphadenopathy was detected after the diagnosis. Radiographic staging procedures identified mediastinal and para-aortic lymphadenopathy, although there was no hepatosplenomegaly. The bone marrow was involved: 75% lymphocytes with a nodular and interstitial pattern of involvement. There were no B symptoms. The disease was considered to be in stage IV A.

The patient was treated with intermittent chlorambucil and the disease was stable for six years. He then developed generalised lymphadenopathy and was treated with six cycles of fludarabine and is currently in complete remission.

DISCUSSION

The lymphoid stroma of WT is part of the systemic lymphoid tissue and therefore is likely to be involved in disseminated lymphoma. Indeed, most patients with lymphomatous involvement of the WT lymphoid stroma had disseminated disease, either in the form of an already established diagnosis or disease that is discovered at staging after initial diagnosis in a WT specimen.^{2–7 8 10 11 15} In this last situation,

Abbreviations: SLL, small lymphocytic lymphoma; NHL, non-Hodgkin lymphoma; WT, Warthin tumour

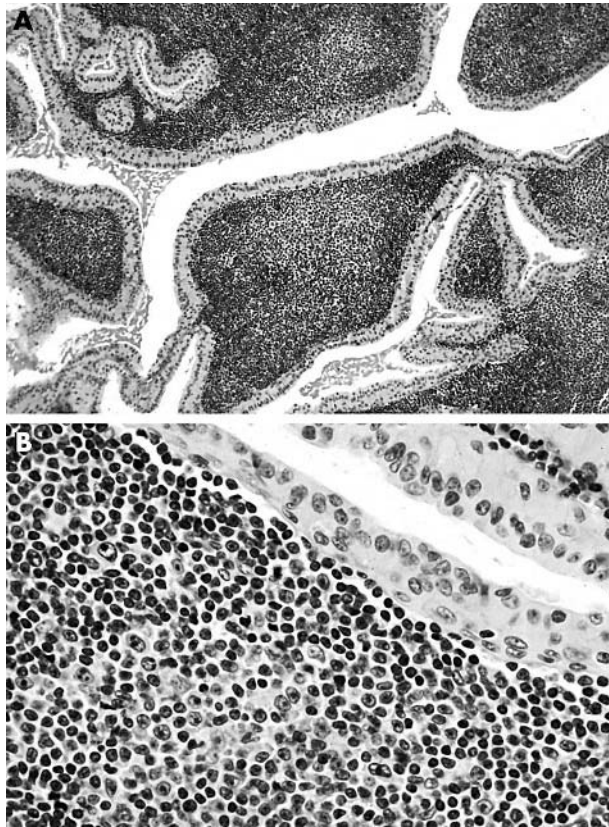


Figure 1 Warthin tumour and small lymphocytic lymphoma. (A) Oncocytic epithelium and pale proliferation centres of small lymphocytic lymphoma (haematoxylin and eosin (H&E); original magnification, $\times 50$). (B) Large paraimmunoblasts in a proliferation centre (H&E; original magnification, $\times 200$).

NHL is usually brought to clinical attention by the superficial nature of the parotid gland mass.¹⁵ Inadequate staging information in some reports^{8 12 14} does not permit the distinction between initial parotid presentation of systemic disease and lymphoma primarily arising in and restricted to WT.

“Disease localised to the parotid region for a variable period of time before dissemination has been offered as an argument supporting the parotid origin of lymphoma”

We were able to find 20 cases of coexisting WT and lymphoma in the English language literature.²⁻¹⁷ Of these, 14 were first diagnosed in the WT excision specimen,⁸⁻¹⁷ and most (10) were follicular lymphomas.^{8-13 15 16} Single cases of diffuse large B cell lymphoma,¹⁰ diffuse mixed small and large cell lymphoma,¹⁷ and SLL¹⁴ have also been reported. As in our case, staging soon after diagnosis identified disseminated disease in six of the 14 cases,^{8 10 11 12 15 16} whereas systemic disease developed in four additional cases within three months to seven years.^{9 11 13 17} Disease localised to the parotid region for a variable period of time before dissemination has been offered as an argument supporting the parotid origin of lymphoma.¹¹

The coexistence of two separate primary tumours without substantial histological admixture at the interface is referred to as a collision tumour.¹⁸ This may be coincidental or the pathogenesis may be related. In this second instance, one single agent may interact with different tissues, inducing different tumours,¹⁹ or one tumour may induce the formation of the other. It has also been proposed that lymphoma localised to WT may result from persistent antigenic stimulation provided by WT epithelial elements.²⁰ Most lymphomas in WT have been reported to be follicular and the WT antigenic stimulation theory is indeed plausible. It is also possible that the WT microenvironment expresses

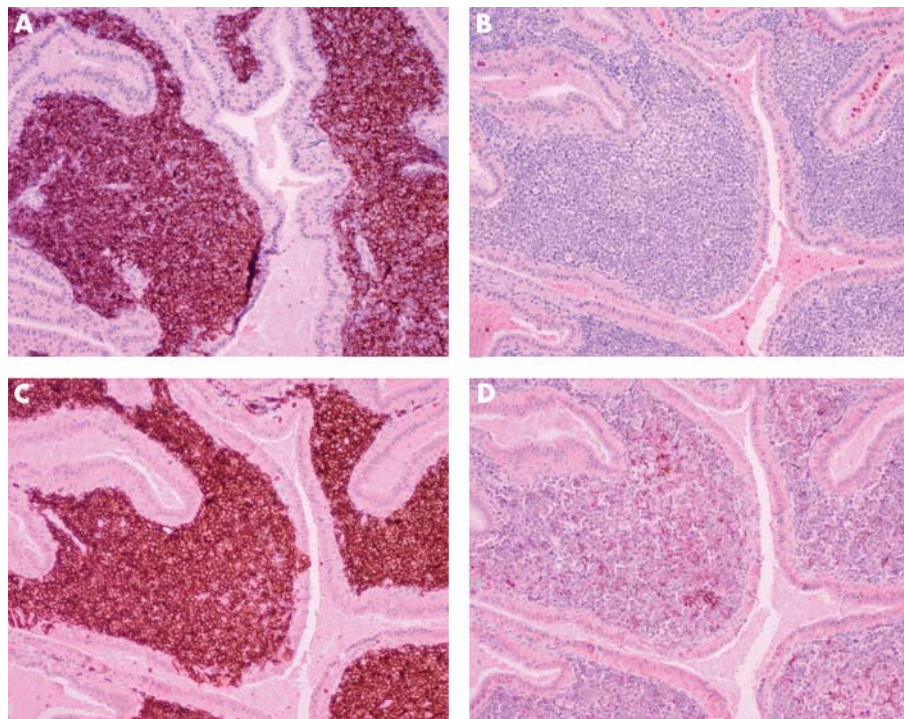


Figure 2 Small lymphocytic lymphoma tumour cells positive for (A) CD20, (C) CD5, and (D) CD23, but negative for (B) CD10 (immunoperoxidase with haematoxylin counterstain; original magnification, $\times 75$).

Take home messages

- We report the second case of an initial diagnosis of Warthin tumour (WT) and small lymphocytic lymphoma (SLL) in a parotid gland
- This case highlights the extremely rare association of SLL with WT and the importance of evaluation of WT stroma, where the pale proliferation centres of SLL may mimic germinal centres of reactive lymphoid nodules.

APRIL/BlyS, a B cell survival factor shown to be of importance in SLL/chronic lymphocytic lymphoma.²¹

There is also some controversy about whether the lymphoid stroma is acquired in response to WT, is part of an epithelial-lymphoid hamartoma, or whether the epithelial element arises from heterotopic salivary gland epithelial remnants in "parotid" lymph nodes.²² Because no marginal zone lymphomas have been reported in WT, it is possible that secondary mucosa associated lymphoid tissue is not acquired in WT, and that the lymphoid stroma is indeed part of the pre-existing lymph node. This concept is further supported by the occurrence of approximately 8% of WT in cervical lymph nodes.²²

At scanning magnification, the pale nodular areas of secondary germinal centres and proliferation centres in SLL may appear similar to an untrained eye. In our case, the SLL nature of the lymphomatous infiltrate was missed by some of the first year pathology residents.

In summary, this case is the second example of collision of SLL and WT where SLL was initially diagnosed in the WT excision specimen. It also highlights the importance of carefully evaluating the lymphoid stroma because the pale proliferation centres may mimic "pale" secondary follicles in a reactive stroma.

ACKNOWLEDGEMENTS

We thank Mr T Reichert and Ms M Hesson for photographic assistance.

Authors' affiliations

A Saxena, Department of Pathology, Royal University Hospital, 103 Hospital Drive, Saskatoon, SK, Canada, S7N 0W8

W Hasegawa, Department of Medical Oncology, Saskatoon Cancer Centre, Saskatoon, SK, Canada, S7N 4H4

B Memauri, Department of Radiology, University of Manitoba, Winnipeg, MB, Canada, R3E 0W3

The patient gave permission for the details of this case report to be published

Correspondence to: Professor A Saxena, Department of Pathology, Royal University Hospital, 103 Hospital Drive, Saskatoon, SK, Canada, S7N 0W8; saxena@sask.usask.ca

Accepted for publication 10 June 2004

REFERENCES

- 1 **Warthin AS**. Papillary cystadenoma lymphomatousum: rare teratoid of parotid region. *J Cancer Res* 1929;**13**:116-25.
- 2 **Seifert G**, Bull HG, Donath K. Histologic subclassification of the cystadenolymphoma of the parotid gland. *Virchows Arch A Pathol Anat Histol* 1980;**388**:13-38.
- 3 **Rekers PE**. Papillary cystadenoma lymphomatousum of the parotid gland, associated with chronic lymphocytic lymphoblastoma. *Ann West Med Surg* 1952;**6**:226-8.
- 4 **Reiner M**, Goldhirsch A, Lusciati PR, *et al*. Warthin's tumor with Sjögren's syndrome and non-Hodgkin's lymphoma. *Ear Nose Throat J* 1979;**58**:41-6.
- 5 **Melato M**, Falconieri G, Fanin R, *et al*. Hodgkin's disease occurring in a Warthin's tumor: first case report. *Pathol Res Pract* 1986;**181**:615-18.
- 6 **Badve S**, Evans G, Mady S, *et al*. A case of Warthin's tumor with coexistent Hodgkin's disease. *Histopathology* 1993;**22**:280-1.
- 7 **Martin H**, Ehrlich HE. Papillary cystadenoma lymphomatousum (Warthin's tumor) of the parotid salivary gland. *Surg Gynecol Obstet* 1944;**79**:611-23.
- 8 **Banik S**, Howell JS, Wright DH. Non-Hodgkin's lymphoma arising in adenolymphoma: a report of two cases. *J Pathol* 1985;**146**:167-77.
- 9 **Hall G**, Tesluk H, Baron S. Lymphoma arising in an adenolymphoma. *Hum Pathol* 1985;**16**:424-7.
- 10 **Griesser GH**, Hansmann ML, Bogman MJ, *et al*. Germinal center derived malignant lymphoma in cystenolymphoma. *Virchows Arch A Pathol Anat Histopathol* 1986;**408**:491-6.
- 11 **Park C-K**, Manning JT, Battifora H, *et al*. Follicle centre lymphoma and Warthin tumor involving the same anatomic site. *Am J Clin Pathol* 2000;**113**:113-19.
- 12 **Colby TV**, Dorfman RF. Malignant lymphomas involving the salivary glands. *Pathol Annu* 1979;**14**:307-24.
- 13 **Miller R**, Yanagihara ET, Dubrow AA, *et al*. Malignant lymphoma in a Warthin's tumor: report of a case. *Cancer* 1982;**50**:2948-50.
- 14 **Bunker M**, Locker J. Warthin's tumor with malignant lymphoma: DNA analysis of paraffin-embedded tissue. *Am J Clin Pathol* 1989;**91**:341-4.
- 15 **Medeiros LJ**, Rizzi R, Lardelli P, *et al*. Malignant lymphoma involving a Warthin's tumor: a case with immunophenotypic and gene rearrangement analysis. *Hum Pathol* 1990;**21**:974-7.
- 16 **Giardini R**, Mastore M. Follicular non Hodgkin's lymphoma in adenolymphoma: report of a case. *Tumori* 1990;**76**:212-15.
- 17 **Shikhani AH**, Shikhani LT, Kuhajda FP, *et al*. Warthin's tumor-associated neoplasms: report of two cases and review of the literature. *Ear Nose Throat J* 1993;**72**:264-73.
- 18 **Nirenberg A**, Ostor AG, Quinn MA. Collision tumor: serous adenocarcinoma and steroid cell tumor of the ovary. *Pathology* 1992;**24**:60-2.
- 19 **Cohen A**, Geller SA, Horowitz I, *et al*. Experimental models for gastric leiomyosarcoma: the effects of N-methyl-N'-nitro-N-nitrosoguanidine in combination with stress, aspirin, or sodium taurocholate. *Cancer* 1984;**53**:1088-92.
- 20 **Isaacson PG**, Norton AJ. *Extranodal lymphomas*. New York, NY: Churchill Livingstone, 1994.
- 21 **Novak AJ**, Bram RJ, Kay NE, *et al*. Aberrant expression of B-lymphocyte stimulator by B chronic lymphocytic mechanism for survival. *Blood* 2002;**100**:2973-9.
- 22 **Ellis GL**, Auclair PL. Tumors of the major salivary glands. In: *Atlas of tumor pathology*, 3rd Series, Fascicle 17. Washington, DC: Armed Forces Institute of Pathology, 1995:68-79.



Initial diagnosis of small lymphocytic lymphoma in parotidectomy for Warthin tumour, a rare collision tumour

A Saxena, B Memauri and W Hasegawa

J Clin Pathol 2005 58: 331-333
doi: 10.1136/jcp.2004.019760

Updated information and services can be found at:
<http://jcp.bmj.com/content/58/3/331.full.html>

These include:

References

This article cites 18 articles, 2 of which can be accessed free at:
<http://jcp.bmj.com/content/58/3/331.full.html#ref-list-1>

Email alerting service

Receive free email alerts when new articles cite this article. Sign up in the box at the top right corner of the online article.

Topic Collections

Articles on similar topics can be found in the following collections

[Immunology \(including allergy\)](#) (1279 articles)

Notes

To request permissions go to:
<http://group.bmj.com/group/rights-licensing/permissions>

To order reprints go to:
<http://journals.bmj.com/cgi/reprintform>

To subscribe to BMJ go to:
<http://group.bmj.com/subscribe/>