



BEST PRACTICE No 182

Complex head and neck specimens and neck dissections. How to handle them

P J Slootweg

J Clin Pathol 2005;58:243–248. doi: 10.1136/jcp.2003.014787

Dissecting surgical specimens from the upper aerodigestive tract is often difficult because of their complicated anatomy. The local environment dictates the routes of tumour spread and surgical margins at risk, and these features differ for various subsites within this part of the body. The examination of surgical specimens of the upper aerodigestive tract should disclose whether postoperative adjuvant treatment is needed and allow the evaluation of preoperatively performed diagnostic imaging. The aim of this article is to provide a concise guideline for the dissection of specimens from this part of the body.

Standard drawings or checklists¹ can also be used for this purpose. Moreover, because head and neck specimens often contain bone or teeth, technical equipment to allow the slicing of specimens should be available. For the larynx, a commercially available slicing machine is indispensable.² For maxillofacial specimens, a water cooled diamond grinding blade is mandatory. These pieces of apparatus allow slicing without separating the soft tissues from either bone or cartilage, and thus enable a cut surface to be obtained that clearly shows how the tumour involves the relevant anatomical structures. Immersing a whole specimen in decalcification solution only allows further processing after a prolonged time and leads to unacceptable loss in quality of gross and microscopical features.

Specimens from the head and neck area are anatomically complicated, with many different structures and tissue types confined within a limited area. Features of interest for the surgeon are not only the histological diagnosis, which is usually already known, but also which structures are invaded by tumour, whether the margins are free, and whether preoperative diagnostic imaging has given a true picture of tumour size and extension. It is the purpose of this article to discuss the way in which surgical specimens from the head and neck area should be handled to retrieve this information.

Subsequent microscopical examination should provide the following data: tumour diagnosis and grade, margin status, growth pattern, vascular invasion, perineural growth, and stromal inflammatory infiltrate.³ Because this article concerns the gross handling of head and neck specimens, microscopy will not be the subject of further discussion.

“Because head and neck specimens often contain bone or teeth, technical equipment to allow the slicing of specimens should be available”

ANATOMY

Specimens may come from the oral cavity, larynx, pharynx, (sino)nasal cavities, or nose and are often accompanied by a neck dissection. For each location, the approach that is needed to obtain insight into the gross features mentioned above will be discussed without enumerating these parameters for each separate location unless they are unique for a particular site.

For each specimen, it is mandatory to recognise the anatomical components, the structures that form the surgical margins, and natural surfaces. If a neck dissection is included, this part should be separated from the tumour specimen through an anatomical plane; thereafter, the neck can be investigated as a separate specimen.

ORAL CAVITY

The oral cavity comprises the upper and lower lip, maxilla, mandible, retromolar trigone, floor of the mouth, tongue, and cheek.

During dissection of the specimen, one should assess classic parameters such as the thickness of the lesion, the structures that are involved, the resection margin that is closest to the lesion, and the anatomical area that this closest margin belongs to. Photographs or drawings of the specimen and the cut slices are useful to indicate

Resections from the lip consist of a wedge shaped, or more rectangular shaped excision with a muscular core, covered by skin, mucosa, and vermilion border. These specimens are cut from left to right perpendicular to the free edge of the lip. In this way, slices are obtained that disclose a full thickness view of the lip and the lesion.

A maxillectomy specimen has an oral and a nasal mucosal surface, surgical margins lying cranially and crossing the bony walls of nasal

Correspondence to:
Dr P J Slootweg, UMC St
Radboud, Huispost 437,
PO Box 9101, 6500 HB
Nijmegen, The
Netherlands; [p.slootweg@
pathol.umcn.nl](mailto:p.slootweg@pathol.umcn.nl)

Accepted for publication
15 July 2004

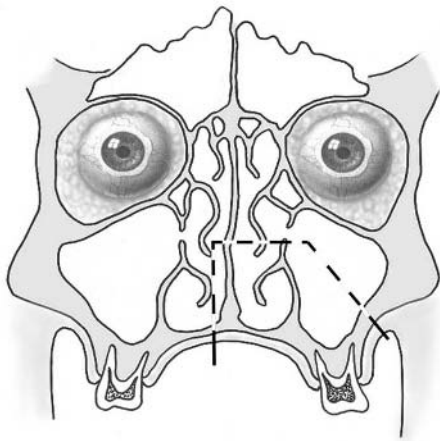


Figure 1 Frontal view indicating the surgical margins of a hemimaxillectomy specimen running through the bony palate, nasal septum, lateral nasal wall (which is the same as the medial wall of the maxillary sinus), and lateral wall of the maxillary sinus (which is the same as the zygomatic arch).

and paranasal sinuses anteriorly and laterally and the pterygoid plates dorsally (fig 1; all figures taken from Slootweg and de Groot,⁴ with permission). These specimens should be sawed in mediolateral parallel slices, which allows comparison with computed tomography scans or magnetic resonance imaging scans that are made in the same direction (fig 2). In addition to assessment of the common features listed above, spread into the nasal cavity or maxillary sinus should be evaluated.

Resections of the mandible can grossly be divided in two main groups: those in which the continuity of the mandible is sacrificed and those in which parts of the mandible are removed while saving the lower border (figs 3 and 4). In so called "through and through" resections, both a ventral and a dorsal bone margin must be assessed, whereas in mandibular resections that save the lower border by only removing parts of the mandibular body and the alveolar ridge, the caudal horizontal bone margin should be investigated.

"In squamous cell cancer of the oral mucosa, one should assess the relation between the tumour and the underlying mandibular bone, which may be resorbed away over a broad front or show diffuse penetration into the bone marrow"

Mandibular specimens are sawed perpendicular to the long axis of the mandibular body. In the case of intraosseous lesions, one should record whether the lesion has caused expansion and/or attenuation of adjacent cortical bone or whether the tumour perforates the cortical bone. In squamous cell cancer of the oral mucosa, one should assess the relation between the tumour and the underlying mandibular bone, which may be resorbed away over a broad front or show diffuse penetration into the bone marrow (fig 5). Surgeons pay much attention to the preoperative assessment of bone involvement by tumour to know whether bone saving surgery can be done, and the pathologist should dissect the specimen in such a way that the preoperative findings concerning bone involvement can be evaluated.⁹

Tumour spread alongside the lower alveolar nerve should also be a point of attention. In the case of complete resection of the mandibular body, the cut surface of the nerve in the posterior bone margin should be examined. When the dorsal osteotomy line lies dorsal to the mandibular foramen, the

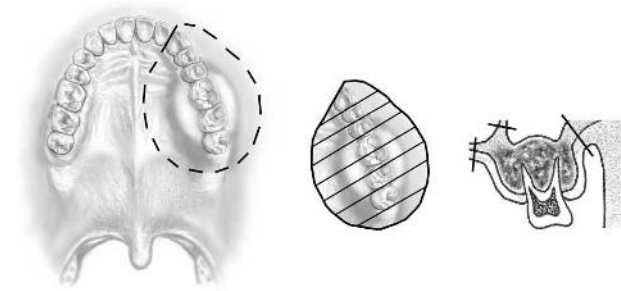


Figure 2 Oral view of a hemimaxillectomy specimen indicating the plane of cutting and showing the frontal view of a slice with intrabony tumour. The surgical margins go through the bony palate and the medial and lateral walls of the maxillary sinus.

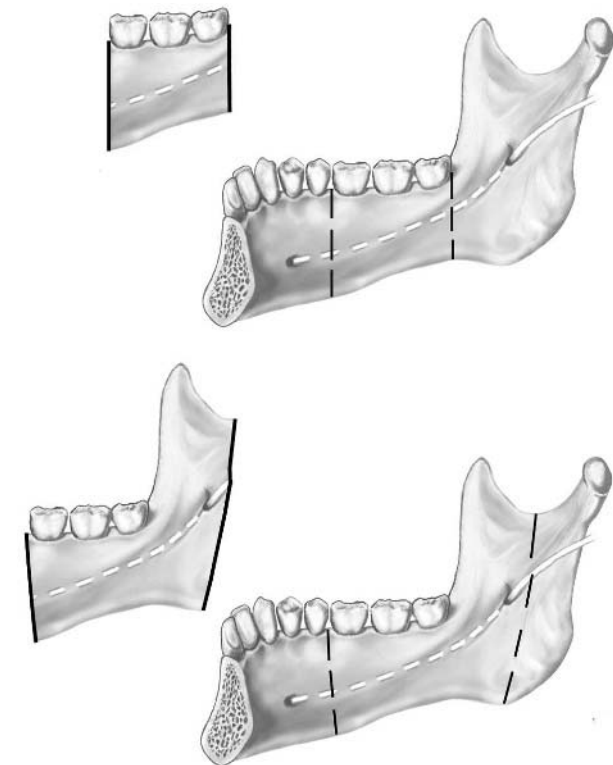


Figure 3 Medial view of a mandible with the dashed lines indicating the surgical margins in a case of through and through mandibulectomy. The course of the mandibular nerve is also indicated. The dorsal osteotomy can lie either ventrally or dorsally to the coronoid process. In this second case, the specimen includes the entrance site of the mandibular nerve into the bone.

nerve should also be identified at this entrance site and subsequently dissected cranially to sample its extrasosseous cranial cut surface (fig 3). When the lower mandibular border is saved, one should assess whether the nerve is contained within the removed specimen, in which case the rules as mentioned above apply. When the nerve lies below the horizontal osteotomy margin, it is left in situ and thus does not form part of the specimen (fig 4).

The retromolar trigone or retromolar area consists of a triangular mucosal surface that lines the ventral surface of the ascending mandibular ramus. Ventrocaudally, it is bordered by the mandibular gingiva, and ventrocranially by the mucosa covering the maxillary tuberosity; its lateral and medial borders are the buccal mucosa and the anterior faucial pillar, respectively. The best way to dissect specimens from

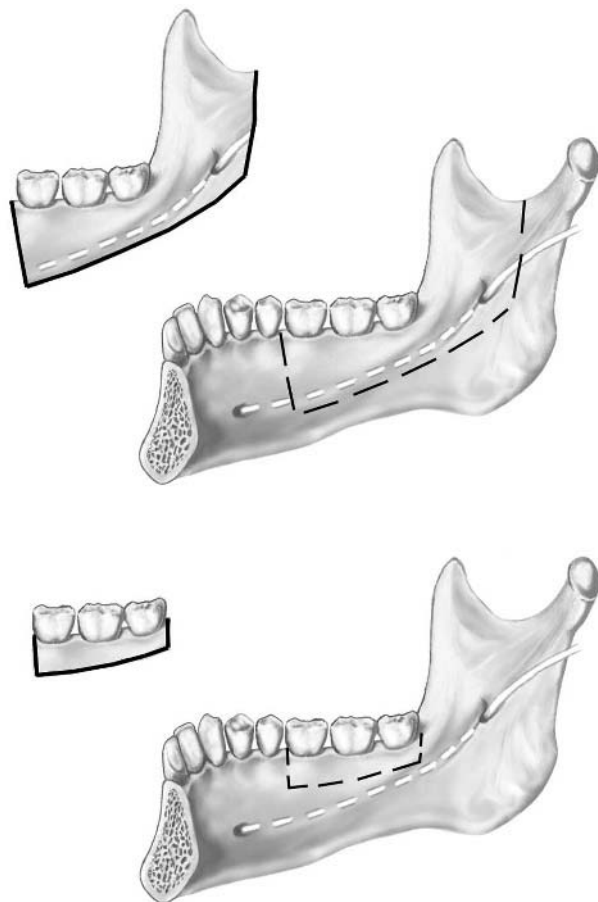


Figure 4 Medial view of mandible with dashed lines indicating the surgical margins in the case of a mandibulectomy in which the continuity of the bone is saved. The course of the mandibular nerve is also indicated. The dorsal osteotomy can lie either ventrally or dorsally to the coronoid process. In this second case, the specimen includes the entrance site of the mandibular nerve into the bone.

this region is by cutting slices craniodorsally to caudoven- trally, parallel to the dorsocranial margin that usually goes through the maxillary tuberosity. The slices thus obtained allow assessment of the common anatomopathological parameters.

Specimens from the floor of the mouth are cut in parallel slices perpendicular to their long axis. In the anterior part of the floor of the mouth, the openings of the ducts of both the left and the right submandibular gland have to be sampled for histological examination to evaluate whether there is intraductal tumour spread.

Tongue resections are cut in parallel slices perpendicular to the lateral border of the tongue. They usually pose no specific problems. In the case of dorsally located tongue tumours, one should identify and sample the margin through the lingual nerve for the analysis of perineural tumour spread into this surgical margin. This nerve can be found at the dorsolateral surgical margin.

Cheek resections are sliced in a horizontal plane, which allows assessment of the conventional anatomopathological parameters. Sometimes, the cheek resection includes the corner of the mouth. In that case, slicing should be done horizontally.

OROPHARYNX

Cranially, the oropharynx ends at the level of the hard palate; the lower border lies at the horizontal plane through the

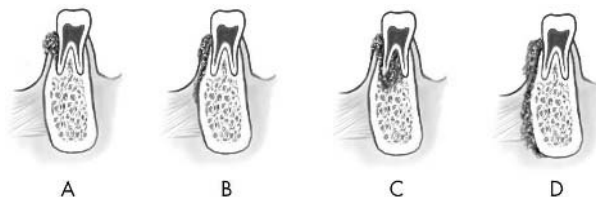


Figure 5 Scheme indicating the various ways in which a gingival cancer may involve the underlying mandibular bone. (A) Vertical resorption, (B) horizontal resorption, (C) diffuse growth along the periodontal ligament space and surrounding the roots of the involved teeth, and (D) resorption involving the periosteum only, without bone destruction.

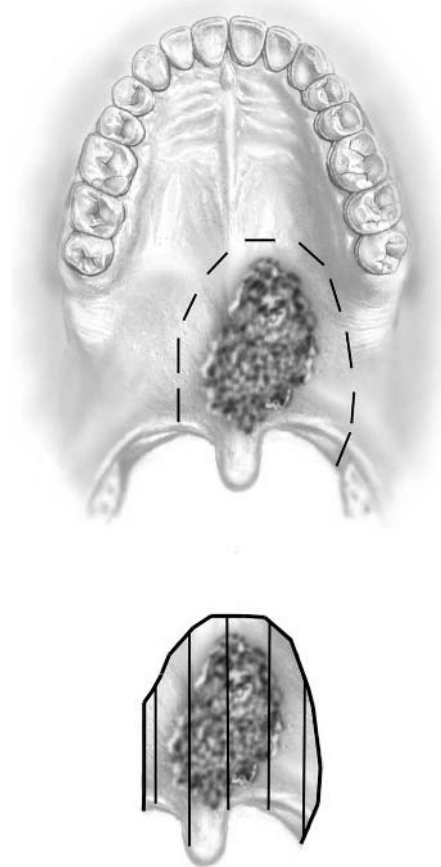


Figure 6 Squamous cell carcinoma of the soft palate. The resection specimen includes the dorsal free margin of the soft palate. Such specimens are cut in slices parallel to the sagittal plane.

vallecula. The anterior wall is formed by the base of the tongue and the vallecula. The lateral walls are the tonsils with their surrounding sulci. The inferior surface of the soft palate and the uvula form the upper wall and the posterior wall lies anteriorly to the second and third cervical vertebrae.

Resections that contain parts of the base of the tongue are cut in slices parallel to the anterior margin that usually goes through the mobile tongue, just anterior to the circumvallate papillae. These slices give a good insight into tumour size and extent.

With regard to the soft palate, there are two types of resections, those including the free dorsal margin and those in which this part of the palate has been left in situ. When the specimen includes the free margin, it is cut in parallel

slices perpendicularly to this free margin (fig 6). When the specimen only contains the more anterior part of the soft palate, then it is cut in parallel slices in a mediolateral direction parallel to either the anterior or the posterior surgical margin.

“The presence of tonsillar tissue hampers the evaluation of tumour thickness and the depth of penetration because the firm and white tonsillar tissue closely mimicks invading squamous cell cancer”

Specimens of the tonsillar fossa also contain parts of adjacent regions: the base of the tongue, the retromolar trigone, and the soft palate. They are cut in slices parallel to the dorsocranial margin, craniodorsally to caudoventrally. The presence of tonsillar tissue hampers the evaluation of tumour thickness and the depth of penetration because the firm and white tonsillar tissue closely mimicks invading squamous cell cancer. Therefore, all slices containing tonsillar tissue should be processed for histological examination, not only to distinguish between tonsillar tissue and invading cancer, but also to analyse whether there is cancer involving tonsillar crypts that is not visible with the naked eye.

Resections of the posterior pharyngeal wall are cut in slices parallel to the cranial surgical margin.

HYPOPHARYNX AND LARYNX

In general, laryngohypopharyngectomies consist of the larynx, dorsally covered by a horseshoe shaped mucosal strip representing left and right pyriform sinus, and in the midline connected by the postcricoid area. Cranially, the specimen may include parts of the base of the tongue. Caudally, the specimen may contain a varying number of tracheal rings. If a tracheostoma has been made beforehand, this usually is removed together with the larynx. In the case of pyriform sinus cancers, the homolateral half of the thyroid gland is included in the resection.

Endolaryngeally, one needs to distinguish between (1) supraglottic tumours involving the false vocal cord, the sinus Morgagni, and the epiglottis; (2) glottic tumours that arise from the true vocal cords; (3) subglottic tumours that involve the true vocal cord with a subglottic extension of more than 1 cm; and (4) tumours that are entirely limited to the subglottic area. Tumours extending from the supraglottic area into the glottic or even the subglottic region are known as translottic tumours. To examine endolaryngeal tumour

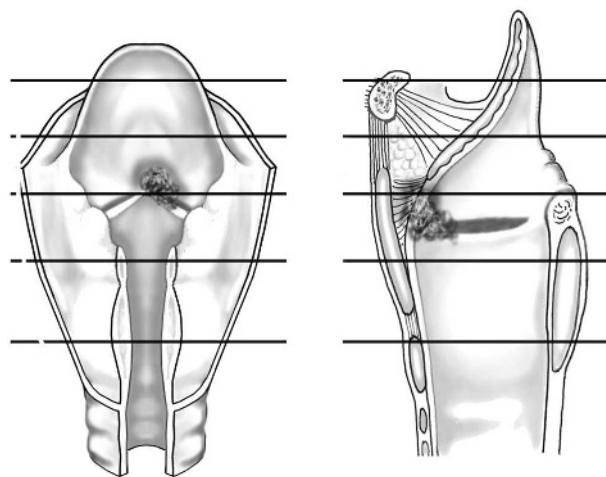


Figure 7 Cancer of the vocal cord. Slices of the larynx are cut perpendicular to its long axis.

position and extension, the larynx has to be opened through a median vertical dorsal incision.

Hypopharyngeal tumours may lie in the pyriform sinus, the postcricoid area, or both. Postcricoid cancers may extend into the adjacent cervical oesophagus. Pyriform sinus cancers may extend cranially into the oropharynx or craniomedially into the supraglottic larynx. Specimens containing the larynx and hypopharynx are cut into horizontal slices (figs 7 and 8),² although the hyoid bone has to be removed by sharp dissection from the ventrocranial external laryngeal surface before this can be done. This bone should initially be put aside so that if histological examination of underlying parts indicates tumour spread into this area it can be investigated histologically.

The slices show the extent of tumour expansion and whether there is perforation of laryngeal cartilages with extralaryngeal soft tissue spread. If present, extralaryngeal spread necessitates sampling of these areas for the assessment of the involved soft tissue dissection plane. Vice versa, caudal endolaryngeal extension of a hypopharyngeal tumour may involve the tracheal margin, and thus necessitate sampling of this area. Hypopharyngeal cancers may also spread submucosally into the caudal surgical margin, which may remain unnoticed if only thin mucosal margins are taken out; therefore, samples from these margins should also contain adequate submucosal tissue. Dorsally growing glottic cancers may spread into the submucosal soft tissues of the postcricoid area, so that this area also deserves special attention.

If a laryngectomy specimen contains a tracheostoma, the relation between the stoma and the tumour should be recorded. Moreover, the margins through the skin surface of the stoma should be sampled for histology.

PARANASAL SINUSES

Among the paranasal cavities—maxillary, frontal, ethmoidal, and sphenoidal—anatomy only allows the formal resection of tumours of the maxillary cavity. Usually, this is a hemimaxillectomy or a hemimaxillectomy, with orbital exenteration if the orbital floor is involved.

The investigation is done in the same way as for maxillectomies (see above). The specimen is sawed in slices parallel to the frontal plane and thus perpendicular to the palatal bone and the orbital floor (figs 9 and 10). These slices also contain pieces of the eye if this is also taken out. The slices allow assessment of the site of the tumour in the maxillary sinus, determination of whether there is destruction of the bony walls, and analysis of the spread into

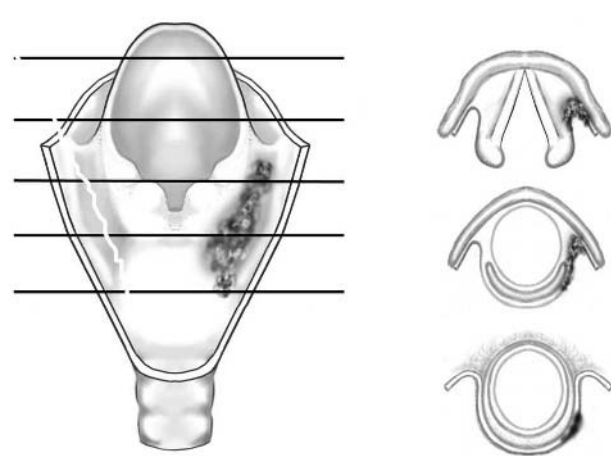


Figure 8 Cancer of the right pyriform sinus. Slices cut perpendicular to its long axis allow the assessment of tumour expansion and the involvement of adjacent laryngeal structures.

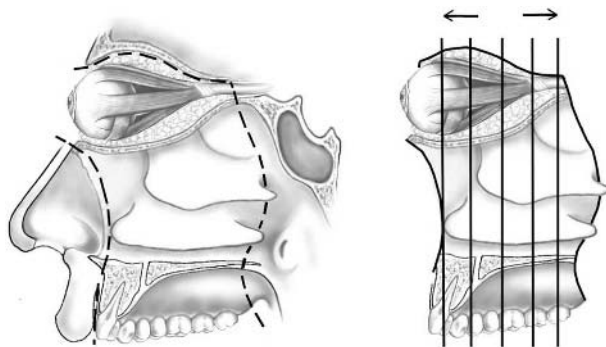


Figure 9 View of medial nasal wall with the nasal conchae. The outline of a hemimaxillectomy including orbital exenteration for treatment of maxillary sinus tumours is shown. Vertical lines indicate planes of slicing.

adjacent soft tissues. The pterygopalatine space should be sampled for the assessment of tumour spread in this area. In addition, the optic nerve and the infraorbital nerve should be examined for perineural tumour spread. Specific attention should also be paid to the status of the orbital floor. Preoperatively, there is often much discussion about if and how the tumour involves this bony structure, and careful analysis of this bone plate will allow the evaluation of pre-diagnostic imaging.⁶

EXTERNAL NOSE

Specimens of the external nose are cut in slices parallel to the dorsal surface of the specimen. This contains three surgical margins: right and left nasal wing and nasal septum. Slices thus obtained allow the visualisation of tumour thickness, depth of penetration, and spread into adjacent structures. For specimens containing nose with the upper lip, right and left lip margins are taken out by cutting vertical slices perpendicular to the vermilion border. Thereafter, the specimen can be sliced conforming to the guidelines for specimens of the nose proper.

NECK DISSECTIONS

Neck dissections contain the cervical lymphatics. The lymph nodes in this area are divided into six different compartments, the so called levels. For a description of these levels and the types of neck dissections the reader is referred to the pertinent report.⁷

The examination of a neck dissection should be done with the following questions in mind: (1) does the specimen contain lymph nodes with metastatic deposits? (2) If so, how

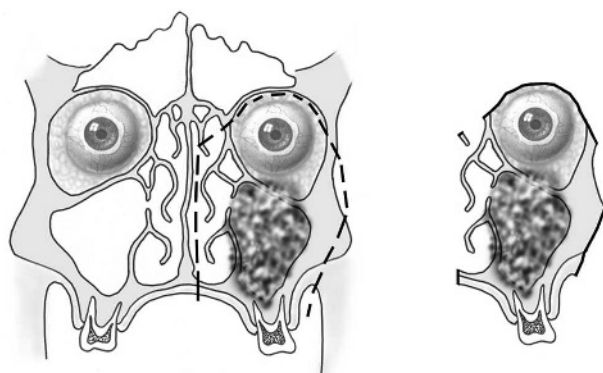


Figure 10 Frontal view of a maxillary sinus tumour involving the orbital floor and the outlines of the corresponding surgical specimen. This view is obtained by slicing as shown in fig 9.

many lymph nodes with metastasis are present, specified for each level? (3) Is there gross extracapsular tumour spread?

“In a radical neck dissection, four anatomical landmarks can be identified, namely: the submandibular gland, the tendon between the posterior and anterior belly of the digastric muscle, the sternocleidomastoid muscle, and the internal jugular vein”

Dissection starts with determination of the type of neck dissection and the identification of the levels that form part of it. Optimally, this requires surgical marks such as coloured beads and/or suture marks because the anatomical boundaries that define the various levels are not present in the specimen. If there are no marks, the pathologist has to rely on the anatomical features of the specimen itself.

In a radical neck dissection, four anatomical landmarks can be identified, namely: the submandibular gland, the tendon between the posterior and anterior belly of the digastric muscle, the sternocleidomastoid muscle, and the internal jugular vein. The submandibular gland identifies the ventrocranial side of the specimen and, together with the surrounding fatty tissue, forms level I. The digastric tendon forms the separation between level I and level II. The internal jugular vein lies medially to the sternocleidomastoid muscle; it identifies levels II, III, and IV by division into three equal parts from the cranial to caudal. Level V lies dorsal to the caudal half of the sternocleidomastoid muscle (fig 11). To facilitate this examination, it may be helpful to compare the radical neck dissection with a capital Z, its upper horizontal line representing level I, its lower horizontal line being level V, and levels II, III, and IV forming three equal parts of the oblique connecting line.

In the case of a modified radical neck dissection, identification of the levels comprising the specimen may be more complicated if the surgeon has not indicated the boundaries. Level I can still be recognised by its association with the submandibular gland, but the other levels in this type of neck dissection merely consist of a mass of fatty tissue without anatomical landmarks, which can be roughly divided in cranial, caudal, and dorsal, but without further details.

In supraomohyoid neck dissections, again the submandibular gland allows the identification of level I, whereas levels

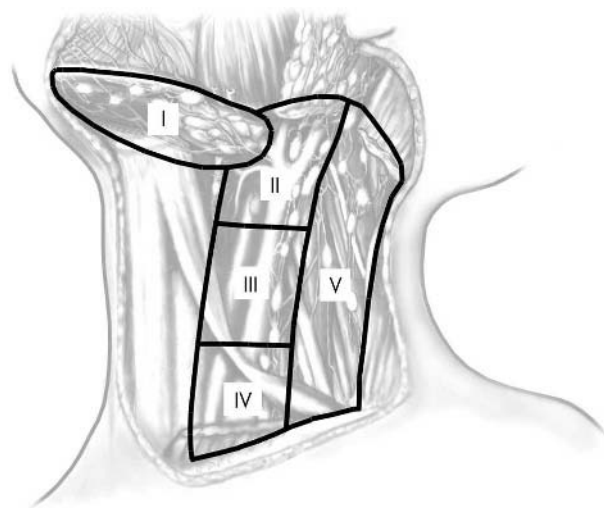


Figure 11 Schematic view of the neck with the levels of the lymph nodes: level I, submental/submandibular; level II, upper cervical; level III, middle cervical; level IV, lower cervical; and level V, supraclavicular.

II and III can be defined by dividing the fatty tissue mass dorsal to the submandibular gland into two equal halves, with cranial being level II and caudal being level III. The upper border of level II sometimes contains a small portion of the caudal part of the parotid gland, which helps in the determination of which part of the fatty tissue dorsal to the submandibular gland is cranial and which is caudal.

Next, one should record whether there are any enlarged lymph nodes and, if so, in which level they lie. These nodes should be measured and sampled for histology; it is wise to ink their outer surface beforehand to allow the evaluation of extracapsular spread into the surface of the specimen. Then, if present, the internal jugular vein should be opened and the blood clot in it removed. This enables inspection of the luminal surface for tumour spread across the venous wall. Thereafter, the neck dissection should be cut in thin parallel slices: vertically for levels I and V and horizontally for levels II–IV. For levels II–V, this cutting should be done from medial to lateral, thus saving the most lateral part of the sternocleidomastoid muscle and in this way saving the integrity of the specimen. All nodes from each level should be sampled for histology. The macroscopical description of the specimen should include the number of nodes from each level, irrespective of their status. Moreover, the sizes of the nodes should be recorded. In the case of gross

extracapsular tumour spread approaching the surface of the specimen, the outer surface of the slice with the minimum distance between tumour and surface should be inked to evaluate whether there is tumour growth into the surface in this area.

REFERENCES

- 1 **Association of Directors of Anatomic and Surgical Pathology.** Recommendations for the reporting of specimens containing oral cavity and oropharynx neoplasms. *Am J Clin Pathol* 2000;**114**:336–8.
- 2 **Michaels L, Gregor RT.** Examination of the larynx in the histopathology laboratory. *J Clin Pathol* 1980;**33**:705–10.
- 3 **Slootweg PJ, Richardson M.** Squamous cell carcinoma of the upper aerodigestive system. In: Gnepp DR, ed. *Diagnostic surgical pathology of the head and neck*. Philadelphia: Saunders, 2001:19–78.
- 4 **Slootweg PJ, Groot JAM de.** *Surgical pathological anatomy of head and neck specimens. A manual for the dissection of surgical specimens from the upper aerodigestive tract*. London: Springer, 1999.
- 5 **Schimming R, Juengling FD, Lauer G, et al.** Computer-aided 3-D ^{99m}Tc-DPD-SPECT reconstruction to assess mandibular invasion by intraoral squamous cell carcinoma: diagnostic improvement or not? *J Craniomaxillofac Surg* 2000;**28**:325–30.
- 6 **Graamans K, Slootweg PJ.** Orbital exenteration in surgery of malignant neoplasms of the paranasal sinuses. The value of preoperative computed tomography. *Arch Otolaryngol Head Neck Surg* 1989;**115**:977–80.
- 7 **Robbins KT, Clayman G, Levine PA, et al.** Neck dissection classification update. Revisions proposed by the American Head and Neck Society and the American Academy of Otolaryngology—Head and Neck Surgery. *Arch Otolaryngol Head Neck Surg* 2002;**128**:751–8.

Committee on Publication Ethics Seminar 2005 Friday 11 March 2005, 9.30 am – 5 pm, BMA House, London

This year's seminar will focus on COPE's new Code of Conduct for Editors and interactive workshops on common ethical and editorial dilemmas. The seminar is for editors, authors, and all those interested in increasing the standard of publication ethics.

The Code aims to set a new basic standard for the ethical conduct of editors and sets out guidelines for quality and correcting the record, standing by decisions made, ethics committee approval, consent for publication confidentiality of submitted material, guidance to authors, pursuing misconduct, relationship to publishers, owners, and advertisers, and conflict of interest. The code also creates a mechanism to refer a complaint to COPE if an editor has breached the code.

The seminar will include:

- The new Code of Conduct for Editors
- Dr Iona Heath, Chair BMJ Ethics Committee—research, audit, and ethics committee approval
- COPE's new website—full text and keyword searching for COPE's advice on specific issues, for example research misconduct, conflict of interest, and deception
- Interactive workshops—common ethical and editorial dilemmas for editors
- Opportunities to network with other editors and share your experiences and challenges

The seminar is free for COPE members and £30.00 for non-members. Numbers are limited and early booking is advisable. For registrations or more information please contact Sam Knottenbelt at cope@bmjgroup.com or call 020 7383 6602. For more information on COPE see www.publicationethics.org.uk/



Complex head and neck specimens and neck dissections. How to handle them

P J Slootweg

J Clin Pathol 2005 58: 243-248
doi: 10.1136/jcp.2003.014787

Updated information and services can be found at:
<http://jcp.bmj.com/content/58/3/243.full.html>

References

These include:

This article cites 5 articles, 4 of which can be accessed free at:
<http://jcp.bmj.com/content/58/3/243.full.html#ref-list-1>

Email alerting service

Receive free email alerts when new articles cite this article. Sign up in the box at the top right corner of the online article.

Notes

To request permissions go to:
<http://group.bmj.com/group/rights-licensing/permissions>

To order reprints go to:
<http://journals.bmj.com/cgi/reprintform>

To subscribe to BMJ go to:
<http://group.bmj.com/subscribe/>