

LETTER TO THE EDITOR

Nestin as a diagnostic and prognostic marker: immunohistochemical analysis of its expression in different tumours

J Ehrmann, Z Kolář, J Mokřý

J Clin Pathol 2005;58:222–223. doi: 10.1136/jcp.2004.021238

The designation NESTIN refers to a member of the family of intermediate filaments and comes from the fact that this protein is expressed mainly in neuroepithelial stem cells. However, nestin is not expressed in mature elements and terminal cell differentiation is associated with loss of immunoreactivity to this protein. Therefore, immunohistochemical assessment of nestin expression might be useful to differentiate between mature and immature elements. The aim of this study was to analyse nestin expression in various tumours of neuroectodermal and vascular origin and to determine whether its detection has practical relevance. The results indicate that the immunohistochemical detection of nestin expression could be useful in astrocytomas and malignant melanomas, where it could be used as an auxiliary indicator of dedifferentiation and progression. Because of the weak and heterogeneous expression of nestin in neurinomas, phaeochromocytomas, and carcinoids, nestin detection in these lesions is of little practical use.

The designation NESTIN refers to a member of the family of intermediate filaments and comes from the fact that this protein is expressed mainly in neuroepithelial stem cells.^{1–3} However, nestin is not expressed in mature elements and terminal cell differentiation is associated with loss of immunoreactivity to this protein. Therefore, immunohistochemical assessment of nestin expression might be useful to differentiate between mature and immature elements. The aim of our study was to analyse nestin expression in various tumours of neuroectodermal and vascular origin, and to determine whether its detection has practical relevance.

MATERIALS AND METHODS

Formalin fixed, paraffin wax embedded specimens from 30 cases of low grade astrocytoma (LGA) and 40 cases of high grade astrocytoma (HGA) were used (table 1). Moreover, 16 cases of benign melanocytic naevi, nine malignant melanomas, 11 capillary and 12 cavernous haemangiomas, 10 schwannomas, 11 phaeochromocytomas, and nine carcinoid tumours were included. We used an indirect immunohistochemical technique with primary anti-nestin antibody (clone 5326; Chemicon, Chandler's Ford, Hampshire, UK). The results of staining were assessed semiquantitatively by estimation of the "histoscore" (percentage of positive cells × intensity of staining).

RESULTS

We found significantly higher expression of nestin in the cytoplasm of neoplastic cells in HGA compared with LGA.

Table 1 Low grade and high grade astrocytomas

Type of astrocytoma (no of cases)	Grade	Group
Subependymal (1)	I	LGA: mean age, 39.7 (range, 11–71) years
Piloctic (3)	I	
Fibrillar (18)	II	
Oligoastrocytoma (6)	II	HGA: mean age, 52.1 (range, 28–84) years
Anaplastic (8)	III	
Glioblastoma (32)	IV	

HGA, high grade astrocytoma; LGA, low grade astrocytoma.

The mean histoscores were 1.6 in LGA and 3.9 in HGA ($p \leq 0.001$; fig 1). Nestin expression was also seen in tumour endothelial cells, but there was no significant difference between the two grades of tumour. In contrast to benign melanocytic naevi, which were negative for nestin, strong positivity for nestin was seen in all cases of malignant melanoma ($p \leq 0.0001$). We also found nestin expression in endothelial cells and pericytes in capillary haemangiomas; however, these cells were nestin negative in cavernous haemangiomas and also in cavernous parts of capillary haemangiomas ($p \leq 0.003$). The expression of nestin in neurinomas, phaeochromocytomas, and carcinoids was weak and heterogeneous.

DISCUSSION

Based on our results, we anticipate that the immunohistochemical detection of nestin expression may be a useful tool for the grading of astroglial tumours.⁴ The presence of nestin in HGA is probably a sign of immaturity. Similarly, nestin positive cells in LGA may be a sign of later dedifferentiation/progression to HGA.

The pattern of nestin expression in pigmented lesions was similar to that seen in astroglomas. Nestin positivity was seen in immature malignant cells in malignant melanomas, whereas differentiated melanocytes in benign melanocytic naevi were nestin negative. Therefore, the presence of nestin may indicate dedifferentiation in these tumours also.⁵

We have no explanation for the difference between nestin expression in capillary and cavernous haemangiomas. It is possible that endothelial cells in cavernous haemangiomas are in a differentiated, mature state and are therefore nestin negative. Obviously, further research is necessary in this field.

Because of the weak and heterogeneous expression of nestin in neurinomas, phaeochromocytomas, and carcinoids, nestin detection in these lesions is of little practical use.

Abbreviations: HGA, high grade astrocytoma; LGA, low grade astrocytoma

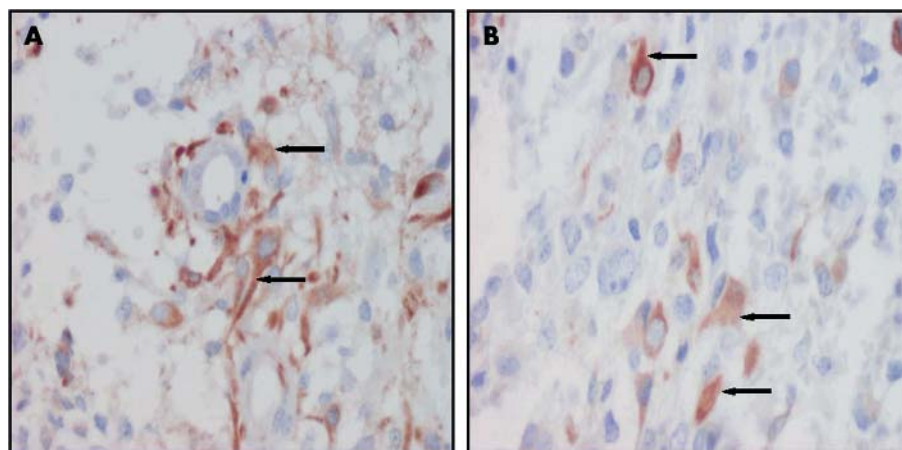


Figure 1 (A, B) Positive nestin expression in the cytoplasm of glioblastoma grade IV tumour cells (arrows).

Take home messages

- The immunohistochemical detection of nestin expression could be useful in astrocytomas and malignant melanomas, where it could be used as an auxiliary indicator of dedifferentiation and progression
- Because of the weak and heterogeneous expression of nestin in neurinomas, phaeochromocytomas, and carcinoids, nestin detection in these lesions is of little practical use

Taken together, the results of our study indicate that the immunohistochemical detection of nestin expression has significant value in astrocytomas and malignant melanomas, where it could be used as an auxiliary indicator of dedifferentiation and progression.

ACKNOWLEDGEMENTS

This study was supported by grants MSM 1510001 and IGA MZ CR NK/6727-3

Authors' affiliations

J Ehrmann, Z Kolář, Department of Pathology and Laboratory of Molecular Pathology, Faculty of Medicine, Palacký University, Hněvotínská 3, Olomouc, CZ 77515, Czech Republic

J Mokry, Department of Histology and Embryology, Faculty of Medicine, Charles University, Šimkova 870, Hradec Králové CZ 50001, Czech Republic

Correspondence to: Dr J Ehrmann, Department of Pathology and Laboratory of Molecular Pathology, Faculty of Medicine, Palacký University, Hněvotínská 3, Olomouc, CZ 77515, Czech Republic; jiri.ehrmann@tiscali.cz

Accepted for publication 18 July 2004

REFERENCES

- 1 **Dahlstrand J**, Zimmerman LB, McKay RD, *et al*. Characterization of the human nestin gene reveals a close evolutionary relationship to neurofilaments. *J Cell Sci* 1992;**103**:589–97.
- 2 **Lendahl U**, Zimmerman LB, McKay RD. CNS stem cells express a new class of intermediate filament protein. *Cell* 1990;**60**:585–95.
- 3 **Nagle RB**. Intermediate filaments: a review of the basic biology. *Am J Surg Pathol* 1988;**12**(suppl 1):4–16.
- 4 **Sugawara K**, Kurihara H, Negishi M, *et al*. Nestin as a marker for proliferative endothelium in gliomas. *Lab Invest* 2002;**82**:345–51.
- 5 **Florenes VA**, Holm R, Myklebost O, *et al*. Expression of the neuroectodermal intermediate filament nestin in human melanomas. *Cancer Res* 1994;**54**:354–6.



Nestin as a diagnostic and prognostic marker: immunohistochemical analysis of its expression in different tumours

J Ehrmann, Z Kolár and J Mokry

J Clin Pathol 2005 58: 222-223
doi: 10.1136/jcp.2004.021238

Updated information and services can be found at:
<http://jcp.bmj.com/content/58/2/222.full.html>

-
- These include:*
- References** This article cites 4 articles, 2 of which can be accessed free at:
<http://jcp.bmj.com/content/58/2/222.full.html#ref-list-1>
- Article cited in:
<http://jcp.bmj.com/content/58/2/222.full.html#related-urls>
- Email alerting service** Receive free email alerts when new articles cite this article. Sign up in the box at the top right corner of the online article.

-
- Topic Collections** Articles on similar topics can be found in the following collections
- [Cancer: dermatological](#) (87 articles)
 - [Dermatology](#) (185 articles)
 - [Immunology \(including allergy\)](#) (1279 articles)
 - [Neurooncology](#) (50 articles)
 - [Peripheral nerve disease](#) (24 articles)

Notes

To request permissions go to:
<http://group.bmj.com/group/rights-licensing/permissions>

To order reprints go to:
<http://journals.bmj.com/cgi/reprintform>

To subscribe to BMJ go to:
<http://group.bmj.com/subscribe/>