

## SHORT REPORT

# Postmortem diagnosis of chronic granulomatous disease: how worthwhile is it?

R Lakshman, S Bruce, D A Spencer, D Crawford, A Galloway, P N Cooper, D Barge, D Roos, T J Flood, M Abinun

A previously healthy 11 year old boy died unexpectedly after a rapid course of progressive pneumonia. Postmortem microbiology and histopathology suggested an underlying diagnosis of chronic granulomatous disease. This was confirmed by neutrophil oxidative burst and gene mutation analysis of other family members, one of whom benefited from early bone marrow transplantation.

**A**n 11 year old boy was admitted to hospital with right upper lobe pneumonia. Two weeks earlier he presented to his general practitioner with several days' history of fever, cough, and malaise. He was prescribed amoxicillin, followed after a week by erythromycin.

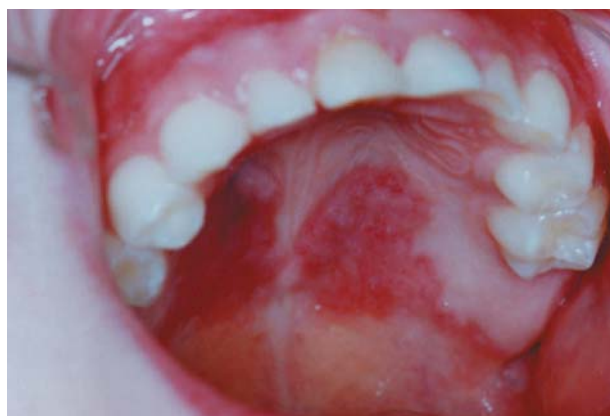Previous to this he had been healthy, except for an unusual, butterfly shaped, pigmented, indolent palatal lesion present for many years (fig 1). Because of this his dentist referred him at the age of 6 years to the oral surgeons who had noticed "somewhat hyperplastic palatal tissue that looked like a chronic candidiasis but with peculiar distribution". However, no swabs were taken and no biopsy was performed at the time.

After admission to hospital, he was started on intravenous penicillin and erythromycin but remained febrile and unwell. By day 4 he became lethargic, developed diarrhoea, progressive liver failure, leucopenia, and thrombocytopenia. Repeat chest radiography showed extension of pneumonia to the entire right lung, and ultrasound demonstrated pleural and pericardial effusions. Antibiotics were changed to ciprofloxacin and cefuroxime and he was transferred to a paediatric intensive care unit. Despite aggressive supportive care he died within 12 hours of transfer from overwhelming septic shock and multiorgan failure. Antemortem sputum and blood cultures had been negative.

The patient's deterioration while on appropriate treatment for community acquired pneumonia suggested the involvement of an unusual organism.<sup>1</sup> Indeed, postmortem cultures (blood, lungs, liver, and spleen) grew *Burkholderia cepacia*. The presence of this well known, opportunistic pathogen found in individuals with pre-existing respiratory epithelial damage (such as patients with cystic fibrosis) suggested an underlying neutrophil disorder.<sup>2</sup> The granulomatous inflammation of the lungs, liver, and spleen seen on postmortem histopathology further supported this possibility.

Unfortunately, because of the fulminant disease course, no immunological investigations were performed before death. However, 20% of the mother's neutrophils had reduced oxidative burst activity, suggesting a carrier state for X linked chronic granulomatous disease (CGD) (fig 2C). Consequently, the mother's sister's 4 year old son, who was being investigated at the time for the cause of recurrent ear infections, intermittent colitis, and reduced energy levels,

*J Clin Pathol* 2005;58:1339-1341. doi: 10.1136/jcp.2004.025098



**Figure 1** The unusual, butterfly shaped, pigmented, indolent palatal lesion that was present for many years in our patient.

came to our attention. His neutrophil oxidative burst activity was absent (fig 2B). A C189G mutation in the *CYBB* gene on the X chromosome, predicting Asn63Lys substitution in the gp-91<sup>phox</sup> component of leucocyte NADPH oxidase, confirmed the diagnosis of X linked CGD and a heterozygous state in both mothers.<sup>3</sup> He has since successfully undergone bone marrow transplantation from a human leucocyte antigen matched sibling.

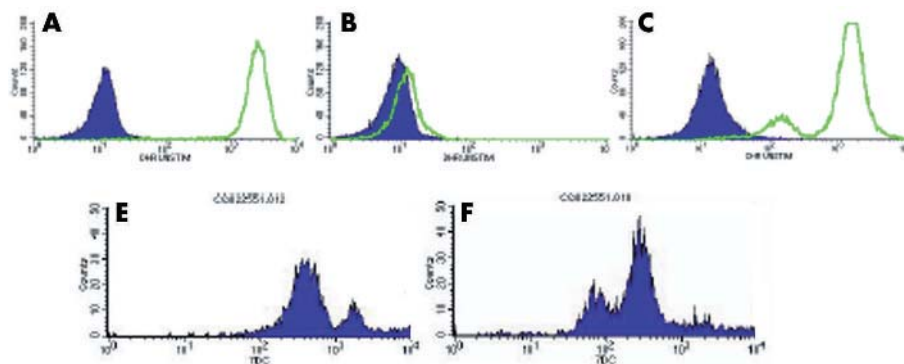
## DISCUSSION

The clinical, genetic, and biochemical features of CGD were recently reviewed.<sup>4</sup> Children with the X linked disease classically present during the 1st year of life with recurrent, life threatening bacterial and fungal infections. In patients with the variant form of the X linked disease (not absent but reduced gp-91<sup>phox</sup> function), the diagnosis may not be made for many years.<sup>5</sup> However, features of the neutrophil oxidative burst, with a mosaic of oxidase positive and negative neutrophils on dihydrorodamine staining in the two carrier sisters, confirmed by gp-91<sup>phox</sup> expression analysis (fig 2E), suggest that this mutation in the *CYBB* gene prevents gp-91<sup>phox</sup> expression.

"Chronic granulomatous disease is still associated with high morbidity and mortality, but recent encouraging results of haemopoietic stem cell transplantation suggest that this treatment may be curative"

The infrequent and variable oral manifestations of CGD include aphthous stomatitis, mucosal ulcers, granulomatous

**Abbreviation:** CGD, chronic granulomatous disease



**Figure 2** Neutrophil oxidative burst activity; neutrophil counts (y axis) and log scale of arbitrary units of fluorescence (x axis). (A–C) Before (shaded) and after (unshaded area) stimulation of neutrophils loaded with dihydrorodamine (DHR) with phorbol myristate acetate. (A) Increased fluorescence of all neutrophils in a healthy person (father). (B) No increase in fluorescence on stimulation suggesting chronic granulomatous disease (CGD; affected cousin). (C) Most neutrophils responding to stimulation with increased fluorescence, with a shoulder of less responsive neutrophils suggesting X linked CGD carrier status (identical for mother and her sister). (D,E) Staining of neutrophils with monoclonal antibody 7D5 specific for gp-91<sup>phox</sup>.<sup>3</sup> (D) Two peaks shown by the normal control (the higher peak represents high gp-91<sup>phox</sup> expression by eosinophils). (E) Three peaks shown by the carrier (mother): the “negative” peak (gp-91<sup>phox</sup> negative neutrophils), the “positive” peak (gp-91<sup>phox</sup> positive neutrophils), and the higher “positive” peak (eosinophils). The low oxidase activity seen in the DHR test in both carriers can be explained by the carryover of hydrogen peroxide from the normal cells to the oxidase negative cells, which leads to some DHR oxidation inside the oxidase negative cells. The 7D5 monoclonal antibody test confirms the existence of gp-91<sup>phox</sup> negative and gp-91<sup>phox</sup> positive neutrophils, suggesting that this mutation in *CYBB* prevents gp-91<sup>phox</sup> expression.

cheilitis, palatal granulomatous mucositis, and enamel hypoplasia.<sup>6</sup> This abnormal granulomatous inflammatory response is a direct consequence of inefficient killing by phagocytes as a result of their reduced oxidative metabolism.<sup>7</sup> In addition, polymorphism of host defence molecules and proinflammatory cytokines has been highlighted<sup>8</sup> as another factor for the unexpected autoimmune response<sup>9</sup> that can occur in affected individuals.<sup>10</sup>

Since the initial description of CGD in the 1950s as “fatal granulomatosis of childhood”, the survival and quality of life has substantially improved as a result of good conservative care, infection prevention, and aggressive surgical treatment. However, CGD is still associated with high morbidity and mortality, but recent encouraging results of haemopoietic stem cell transplantation suggest that this treatment may be curative.<sup>11</sup>

### Important teaching points

- An infection caused by an uncommon organism may be responsible for the lack of response to the usual line of treatment
- Finding of an unusual organism causing infection in an otherwise healthy individual should raise the suspicion of primary immunodeficiency, which, occasionally, may present with an unusual clinical feature and/or after many apparently healthy years
- The peculiar physical signs usually have an underlying pathophysiology and one should persevere in trying to explain the unusual and unexpected
- Once the diagnosis of a primary immunodeficiency is made, even after death of the patient in question, screening of the extended family is important because other affected members may be diagnosed and benefit from currently available treatment(s)

### Authors' affiliations

**R Lakshman, T J Flood, M Abinun**, Department of Paediatric Immunology, Newcastle upon Tyne Hospitals NHS Trust, Newcastle upon Tyne NE4 6BE, UK

**S Bruce**, Department of Paediatrics, Sunderland Royal Hospital, Sunderland SR4 7TP, UK

**D A Spencer**, Department of Paediatric Respiratory Medicine, Newcastle upon Tyne Hospitals NHS Trust, Freeman Hospital, Newcastle, NE7 7DN, UK

**D Crawford**, Department of Paediatric Intensive Care, Newcastle upon Tyne Hospitals NHS Trust

**A Galloway**, Department of Clinical Microbiology, Newcastle upon Tyne Hospitals NHS Trust

**P N Cooper**, Department of Histopathology, Newcastle upon Tyne Hospitals NHS Trust, Royal Victoria Infirmary, Newcastle, NE1 4LP, UK

**D Barge**, Immunology Laboratory, Newcastle upon Tyne Hospitals NHS Trust, Royal Victoria Hospital

**D Roos**, Sanquin Research at CLB and Landsteiner Laboratory of the Academic Medical Centre, University of Amsterdam, 1066 CX Amsterdam, The Netherlands

Consent was obtained from the parents of the child presented in this case report.

Correspondence to: Dr M Abinun, Children's Bone Marrow Transplantation Unit, Newcastle General Hospital, Westgate Road, Newcastle upon Tyne, NE4 6BE, UK; [Mario.Abinun@ncl.ac.uk](mailto:Mario.Abinun@ncl.ac.uk)

Accepted for publication 30 March 2005

### REFERENCES

- 1 **Russell G**. Community acquired pneumonia. *Arch Dis Child* 2001;**85**:445–6.
- 2 **Lakshman R**, Finn A. Neutrophil disorders and their management. *J Clin Pathol* 2001;**54**:7–19.
- 3 **Yamauchi A**, Yu L, Pötgens AJ, et al. Location of the epitope for 7D5, a monoclonal antibody raised against human flavocytochrome b<sub>558</sub>, to the extracellular peptide portion of primate gp91<sup>phox</sup>. *Microbiol Immunol* 2001;**45**:249–57.
- 4 **Segal BH**, Leto TL, Gallin JI, et al. Genetic, biochemical and clinical features of chronic granulomatous disease. *Medicine* 2000;**79**:170–200.
- 5 **Liese JG**, Jendrossek V, Jansson A, et al. Chronic granulomatous disease in adults. *Lancet* 1995;**346**:220–3.
- 6 **Lovas JGL**, Issekutz A, Walsh N, et al. Lupus erythematosus-like oral mucosal and skin lesions in a carrier of chronic granulomatous disease. *Oral Surg Oral Med Oral Pathol Oral Radiol Endod* 1995;**80**:78–82.

- 7 **Reeves EP**, Lu H, Jacobs HL, *et al*. Killing activity of neutrophils is mediated through activation of proteases by K<sup>+</sup> influx. *Nature* 2002;**416**:291–7.
- 8 **Foster CB**, Lehrnbecher T, Mol F, *et al*. Host defense molecule polymorphisms influence the risk for immune-mediated complications in chronic granulomatous disease. *J Clin Invest* 1998;**102**:2146–55.
- 9 **Arkwright PD**, Abinun M, Cant AJ. Autoimmunity in human primary immunodeficiency disease. *Blood* 2002;**99**:2694–702.
- 10 **Badolato R**, Notarangelo LD, Plebani A, *et al*. Development of systemic lupus erythematosus in a young child affected with chronic granulomatous disease following withdrawal of treatment with interferon-gamma. *Rheumatology* 2003;**42**:1–2.
- 11 **Seger RA**, Gungor T, Belohradsky BH, *et al*. Treatment of chronic granulomatous disease with myeloablative conditioning with an unmodified hemopoietic allograft: a survey of the European experience 1985–2000. *Blood* 2002;**100**:4344–50.



## Postmortem diagnosis of chronic granulomatous disease: how worthwhile is it?

R Lakshman, S Bruce, D A Spencer, et al.

*J Clin Pathol* 2005 58: 1339-1341  
doi: 10.1136/jcp.2004.025098

---

Updated information and services can be found at:  
<http://jcp.bmj.com/content/58/12/1339.full.html>

---

*These include:*

### References

This article cites 11 articles, 5 of which can be accessed free at:  
<http://jcp.bmj.com/content/58/12/1339.full.html#ref-list-1>

### Email alerting service

Receive free email alerts when new articles cite this article. Sign up in the box at the top right corner of the online article.

---

### Topic Collections

Articles on similar topics can be found in the following collections

[Immunology \(including allergy\)](#) (1279 articles)  
[Histopathology](#) (87 articles)  
[Molecular genetics](#) (253 articles)  
[Pneumonia \(infectious disease\)](#) (22 articles)  
[Pneumonia \(respiratory medicine\)](#) (21 articles)  
[TB and other respiratory infections](#) (61 articles)

---

### Notes

---

To request permissions go to:  
<http://group.bmj.com/group/rights-licensing/permissions>

To order reprints go to:  
<http://journals.bmj.com/cgi/reprintform>

To subscribe to BMJ go to:  
<http://group.bmj.com/subscribe/>