

CASE REPORT

Mucinous metaplasia of the vulva in a case of lichen sclerosus. A case report

E Rakha, C Mayne, L Brown

J Clin Pathol 2005;58:1217–1218. doi: 10.1136/jcp.2005.027847

Mucinous metaplasia of the genital area is a rare condition characterised by the emergence of mucin containing cells in stratified squamous epithelium. This report describes a unique case of benign mucinous metaplasia of the vulva associated with lichen sclerosus in a 60 year old woman. Histopathology revealed cervical type metaplasia with otherwise typical lichen sclerosus. This report discusses the pathogenesis and differential diagnosis of mucinous epithelium.

A 60 year old woman presented with a few months history of postcoital bleeding and pruritis vulvae. Physical examination revealed a white raw area 12 mm in diameter located on the left labium major and extending into the vaginal introitus. A biopsy was taken and histological examination showed lichen sclerosus. However, the most unusual aspect of this case was that the stratified squamous epithelium was replaced by a stratified epithelium, the superficial layers of which were represented by columnar cells with multivacuolated mucin containing cytoplasm. There was no nuclear atypia (fig 1). Mild acute inflammatory changes were also present, probably secondary to excoriation. Mucin laden cells in the epithelium stained violet with diastase periodic acid Schiff and Alcian blue at pH 2.5, indicating the presence of neutral and acid mucins (fig 2). These cells also stained positively for CA19.9, oestrogen receptor, and carcinoembryonic antigen. The cells also showed focal positivity for cytokeratin 7 and negative staining for cytokeratin 20, indicating endocervical type mucinous metaplasia.

DISCUSSION

Mucinous cells are not a normal component of the skin. The differential diagnosis of mucin containing cells in the epidermis of the vulva includes the following: cutaneous in situ and invasive squamous cell carcinoma with mucinous metaplasia, extramammary Paget's disease,¹ mucinous syringometaplasia,² mucinous papulosis,³ and epidermotropic metastasis. These must, in their turn, be distinguished from superficial spreading melanoma.

Lichen sclerosus is a well recognised common inflammatory dermatosis of unknown aetiology, which affects both sexes, but is most commonly seen in the vulva in women of any age.⁴ There seems to be a higher risk that lichen sclerosus may be associated with vulval carcinoma.^{5 6} An association with mucinous metaplasia has not been reported to date.

"Lichen sclerosus is a well recognised common inflammatory dermatosis of unknown aetiology, which affects both sexes, but is most commonly seen in the vulva in women of any age"

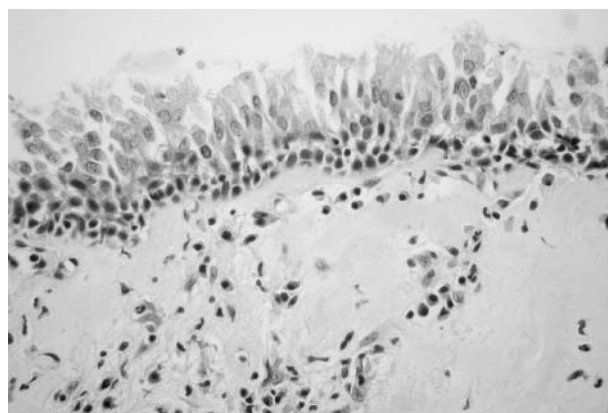


Figure 1 Lichen sclerosus of the vulva with surface columnar epithelium (haematoxylin and eosin staining).

Genital mucinous metaplasia is an uncommon disorder. A case of mucinous metaplasia of the vulva⁷ and vestibule and lower vagina,⁸ in addition to a few cases of mucinous metaplasia of the prepuce⁹ and glans penis,¹⁰ have been reported. However, the histogenesis of mucinous metaplasia of the genital area remains unknown. It probably represents a non-specific reactive process. The association with lichen sclerosus is probably fortuitous or may be a further indication of longterm external damage or chronic inflammation.^{9 10} The absence of nuclear atypia, preservation of nuclear polarity, confinement of mucin containing cells to the epidermis, the predominant location of the cells in the upper layers of the epithelium, and the fact that the mucinous cells replace squamous epithelium rather than infiltrating it distinguishing this condition from extramammary Paget's disease.

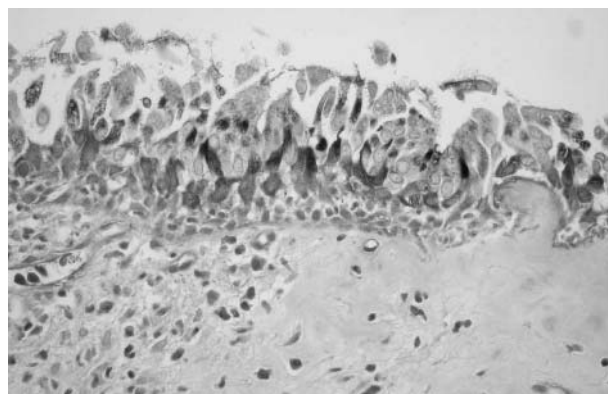


Figure 2 Mucin in the cytoplasm of the columnar cells (stained with Alcian blue/periodic acid Schiff with diastase).

Take home messages

- We report a rare case of benign mucinous metaplasia of the vulva associated with lichen sclerosus in a 60 year old woman
- Histopathology revealed endocervical type metaplasia with otherwise typical lichen sclerosus
- The histogenesis of mucinous metaplasia of the genital area is unknown, but it probably represents a non-specific reactive process
- The association with lichen sclerosus is probably fortuitous or may be a further indication of longterm external damage or chronic inflammation

Authors' affiliations

E Rakha, L Brown, Department of Histopathology, University Hospitals of Leicester, Leicester, LE1 5WW, UK

C Mayne, Department of Obstetrics and Gynaecology, University Hospitals of Leicester

The patient gave her informed consent for this case report to be published

Correspondence to: Dr L Brown, Department of Histopathology, University Hospitals of Leicester, Leicester, LE1 5WW, UK; laurence.brown@uhl-tr.nhs.uk

Accepted for publication 24 March 2005

REFERENCES

- 1 **Banuls J**, Ramon R, Silvestre JF, *et al*. Mucinous metaplasia of apocrine duct. *Am J Dermatopathol* 1998;**20**:189–93.
- 2 **Bergman R**, David R, Friedman-Birnbaum R, *et al*. Mucinous syringometaplasia. An immunohistochemical and ultrastructural study of a case. *Am J Dermatopathol* 1996;**18**:521–6.
- 3 **Mohanty SK**, Arora R, Kakkar N, *et al*. Clear cell papulosis of the skin. *Ann Diagn Pathol* 2002;**6**:385–8.
- 4 **Fung MA**, LeBoit PE. Light microscopic criteria for the diagnosis of early vulvar lichen sclerosus: a comparison with lichen planus. *Am J Surg Pathol* 1998;**22**:473–8.
- 5 **Kini U**. Squamous cell carcinoma of the vulva in association with mixed vulvar dystrophy. A brief report with review of literature. *Indian J Cancer* 1997;**34**:92–5.
- 6 **Carlson JA**, Mu XC, Slominski A, *et al*. Melanocytic proliferations associated with lichen sclerosus. *Arch Dermatol* 2002;**138**:77–87.
- 7 **Coghill SB**, Tyler X, Shaxted EJ. Benign mucinous metaplasia of the vulva. *Histopathology* 1990;**17**:373–5.
- 8 **Marquette GP**, Su B, Woodruff JD. Introital adenosis associated with Stevens-Johnson syndrome. *Obstet Gynecol* 1985;**66**:143–5.
- 9 **Fang AW**, Whittaker MA, Theaker JM. Mucinous metaplasia of the penis. *Histopathology* 2002;**40**:177–9.
- 10 **Ruiz-Genao DP**, Dauden-Tello E, Adrados M, *et al*. Mucinous metaplasia of the glans penis. *Histopathology* 2004;**44**:90–1.



Mucinous metaplasia of the vulva in a case of lichen sclerosus. A case report

E Rakha, C Mayne and L Brown

J Clin Pathol 2005 58: 1217-1218
doi: 10.1136/jcp.2005.027847

Updated information and services can be found at:
<http://jcp.bmj.com/content/58/11/1217.full.html>

References

These include:

This article cites 10 articles, 1 of which can be accessed free at:
<http://jcp.bmj.com/content/58/11/1217.full.html#ref-list-1>

Article cited in:
<http://jcp.bmj.com/content/58/11/1217.full.html#related-urls>

Email alerting service

Receive free email alerts when new articles cite this article. Sign up in the box at the top right corner of the online article.

Topic Collections

Articles on similar topics can be found in the following collections

[Dermatology](#) (185 articles)
[Histopathology](#) (87 articles)

Notes

To request permissions go to:
<http://group.bmj.com/group/rights-licensing/permissions>

To order reprints go to:
<http://journals.bmj.com/cgi/reprintform>

To subscribe to BMJ go to:
<http://group.bmj.com/subscribe/>