

## ORIGINAL ARTICLE

## Immunohistochemical analysis of desmoid tumours

A Leithner, M Gapp, R Radl, A Pascher, P Krippel, K Leithner, R Windhager, A Beham

*J Clin Pathol* 2005;58:1152–1156. doi: 10.1136/jcp.2005.026278

See end of article for authors' affiliations

Correspondence to:  
Dr A Leithner, Department of Orthopaedic Surgery, Medical University Graz, Auenbruggerplatz 5, A-8036 Graz, Austria; andreas.leithner@meduni-graz.at

Accepted for publication  
21 February 2005

**Background/Aims:** Although the standard treatment for desmoid tumours is complete surgical resection with wide margins, the optimal adjuvant treatment for recurrent or inoperable disease is unclear, often being based on sporadic immunohistochemical reports with a low number of cases. Therefore, a large immunohistochemical study was performed, to provide a theoretical basis for adjuvant treatment regimens.

**Methods:** One hundred and sixteen tissue samples from 80 patients (49 female, 31 male; mean age, 34 years; range, 0–83) with desmoid tumours (46 extra-abdominal, 21 abdominal, 13 intra-abdominal) were tested for oestrogen receptors  $\alpha$  and  $\beta$ , progesterone and androgen receptors, and somatostatin, in addition to HER2, cathepsin D, Ki-67, and c-KIT by immunohistochemistry.

**Results:** All samples were negative for oestrogen receptor  $\alpha$ , HER2, and the progesterone receptor. Positive staining for the androgen receptor was found in six extra-abdominal cases. Staining for oestrogen receptor  $\beta$  was positive in four extra-abdominal, two abdominal, and one intra-abdominal case. Staining for somatostatin was positive in six extra-abdominal, two abdominal, and one intra-abdominal case, and staining for cathepsin D was positive in all cases. Positive staining for Ki-67 was found in 14 extra-abdominal, three abdominal, and three intra-abdominal cases. C-KIT was detectable in one abdominal case only.

**Conclusions:** The data from this immunohistochemical study show that the published effects of antioestrogens and imatinib mesylate in the treatment of aggressive fibromatoses may not be attributable to oestrogen receptor  $\alpha$  or c-KIT expression.

Desmoid tumours—also known as aggressive fibromatoses—are rare (3–4/million/year), benign, but locally aggressive clonal fibroblastic proliferations that arise in the deep soft tissues, and are characterised by infiltrative growth and a tendency towards local recurrence, but an inability to metastasise.<sup>1,2</sup>

“We systemically screened a large number of stored tumour tissue samples for several receptors, to provide a basis for a possible adjuvant treatment regimen”

A wide local excision is the treatment of choice,<sup>3</sup> unless vital structures or major nerve trunks are involved. For these and for recurrent cases various adjuvant treatments such as chemotherapy, antioestrogens, imatinib mesylate, and radiotherapy have been used, often with contradictory results. Immunohistochemical studies on desmoid tumours are rare. Conflicting results have been reported particularly for oestrogen receptor  $\alpha$  expression. Therefore, in our present study we systemically screened a large number of stored tumour tissue samples for several receptors, to provide a basis for a possible adjuvant treatment regimen.

## MATERIALS AND METHODS

### Patients

For our present study, patients were identified from the central patient database of the Institute of Pathology, Medical University Graz, Austria with the documentation system AURA (Institute of Medical Informatics, Medical University Graz, Austria). In total, 116 archived desmoid tumour samples were identified. These samples were obtained from 80 individuals undergoing 102 surgical procedures, including nine biopsies. In detail, 90 samples were obtained during surgery on 76 primary tumours, whereas 26 samples came from surgery on 17 recurrences.

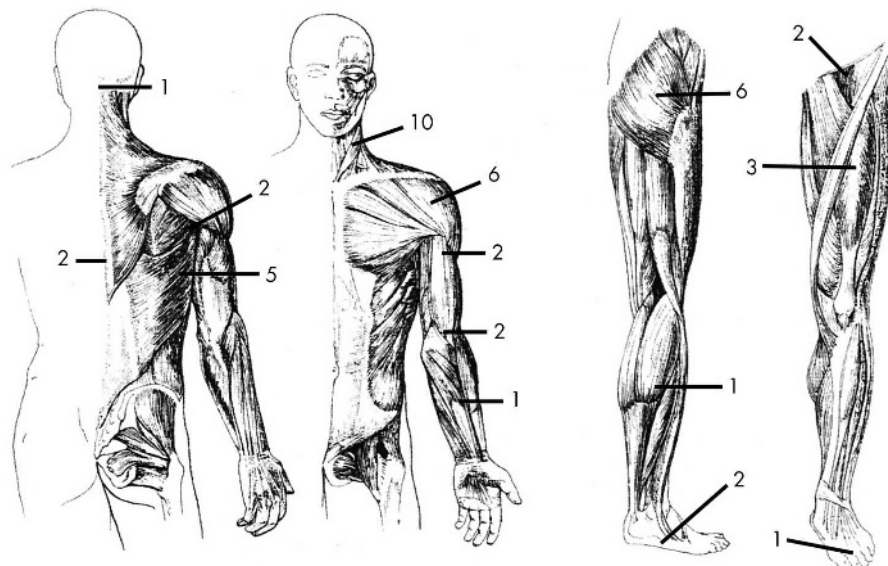
Forty nine cases occurred in female and 31 in male patients, with a mean age at presentation of 34 years (range, 0–83). Each anatomical subgroup had its distinct sex ratio and typical mean age distribution. The mean age of 46 patients with extra-abdominal tumours (19 males, 27 females) was 29 years, of 21 patients with abdominal tumours (four males, 17 females) 35 years, and of 13 patients with intra-abdominal tumours (eight males, five females) 53 years. Figure 1 shows the locations of the 46 extra-abdominal desmoid tumours. Patient consent was not required because only anonymised tissue samples were used. The study design was approved by the institutional review board of Cancer Aid Austria/Styria.

### Tissue specimens

Tissues obtained at surgery were fixed in 4.5% formaldehyde and paraffin wax embedded according to standard procedures. Before inclusion in our study, a senior pathologist reviewed the slides for the accuracy of the initial diagnosis. In four patients the primary diagnosis had to be revised and in seven patients there was not enough material available to perform immunohistochemistry. Therefore, these 11 patients were not included in our study.

### Immunohistochemistry

All formalin fixed, paraffin wax embedded tissue sections were dewaxed and rehydrated according to standard protocols. Ten sections were cut from each tissue block, nine for immunostaining and one as a haematoxylin and eosin control to define the tumour sections. Table 1 provides the details of the antibodies used. The tissue sections were processed according to company guidelines or standard protocols. All slides were evaluated independently by light microscopy by three of the authors. Normal human soft tissue, present in other sections, served as a reliable internal negative control. As a positive control the following specimens were stained: lymph nodes for Ki-67; prostate cancer



**Figure 1** Skeletal distribution of 46 extra-abdominal desmoid tumours. The figure design was modified from Pignatti and colleagues,<sup>6</sup> with permission.

for the androgen receptor; breast cancer for oestrogen receptors  $\alpha$  and  $\beta$ , the progesterone receptor, and cathepsin D; pancreas for somatostatin; and a gastrointestinal stromal tumour for c-KIT. A positive control was provided with the kit for HER2. Classification as positive was done either according to company guidelines or institutional standard protocols for the positive controls: a minimum of 10% of the tumour cells had to be positive for oestrogen receptors  $\alpha$  and  $\beta$ , progesterone receptor, c-KIT, and cathepsin D; more than 5% for androgen receptor and Ki-67; and more than 1% for somatostatin and HER2.

**RESULTS**

**Oestrogen receptor  $\alpha$ , progesterone receptor, and HER2**

All samples tested consistently negative. Table 2 summarises the results of the immunostaining.

**Androgen receptor**

Positive staining for the androgen receptor was found in only six of 46 extra-abdominal cases (fig 2C). One of the positive cases progressed from being negative in the primary tumour and the first recurrence to positive at the second recurrence.

**Somatostatin**

Staining for somatostatin was positive in six of 46 extra-abdominal (three focal positive only), two of 21 abdominal, and one of 13 intra-abdominal cases. In one of the extra-abdominal cases more than 90% of the cells showed

strong staining for somatostatin (fig 2D). In all other nine positive cases a smaller number of cells (< 20%) was positive.

**Oestrogen receptor  $\beta$**

Staining for oestrogen receptor  $\beta$  was positive in four (three only focal) of 46 extra-abdominal, two of 21 abdominal, and one of 13 intra-abdominal cases (fig 2E). One of the two positive abdominal cases progressed from being negative in the primary tumour to positive at the first recurrence.

**Cathepsin D**

Staining for cathepsin D was positive in all cases. However, strong expression was also seen in non-tumour stromal cells.

**Ki-67 (MIB-1)**

Positive Ki-67 staining was found in 14 of 46 extra-abdominal (three focal positive), three of 21 abdominal, and three (focal positive) of 13 intra-abdominal cases. Tumour cells showed between 5% and 10% immunostaining for Ki-67 in 18 cases, whereas in only two cases more than 10% of tumour cells were positive (fig 2F). One abdominal case and one extra-abdominal case progressed from negative in the primary tumour to positive at the first recurrence. In another extra-abdominal case, the primary tumour was Ki-67 negative but was positive (5–10% of tumour cells) at the first recurrence; however, the tumour was again negative at the second, third, and fourth recurrences.

**Table 1** Antibody details

Antibody/antigen	Company	Clonality	Type	Clone no.	Code no.	Dilution
ER $\alpha$	Ventana Medical Systems, Illkirch, France	Monoclonal	Mouse	6F11	760-2596	Kit (confirm)
ER $\beta$	Abcam, Cambridge, UK	Monoclonal	Mouse	14C8	ab288	1/50
PR	Ventana	Monoclonal	Mouse	16	760-2547	Kit (confirm)
AR	Dako Cytomation, Vienna, Austria	Monoclonal	Mouse	AR441	M3562	1/50
SOM	Dako	Polyclonal	Rabbit		A0566	1/2000
Cath D	Dako	Polyclonal	Rabbit		A0561	1/100
HER	Dako	Polyclonal	Rabbit		K5204	Kit (HercepTest)
Ki-67	Dako	Monoclonal	Mouse	MIB-1	M7240	1/200
c-KIT	Dako	Polyclonal	Rabbit		A4502	1/1000

AR, androgen receptor; Cath D, cathepsin D; ER $\alpha$ , oestrogen receptor  $\alpha$ ; ER $\beta$ , oestrogen receptor  $\beta$ ; PR, progesterone receptor; SOM, somatostatin.

**Table 2** Desmoid subtype and results of immunostaining

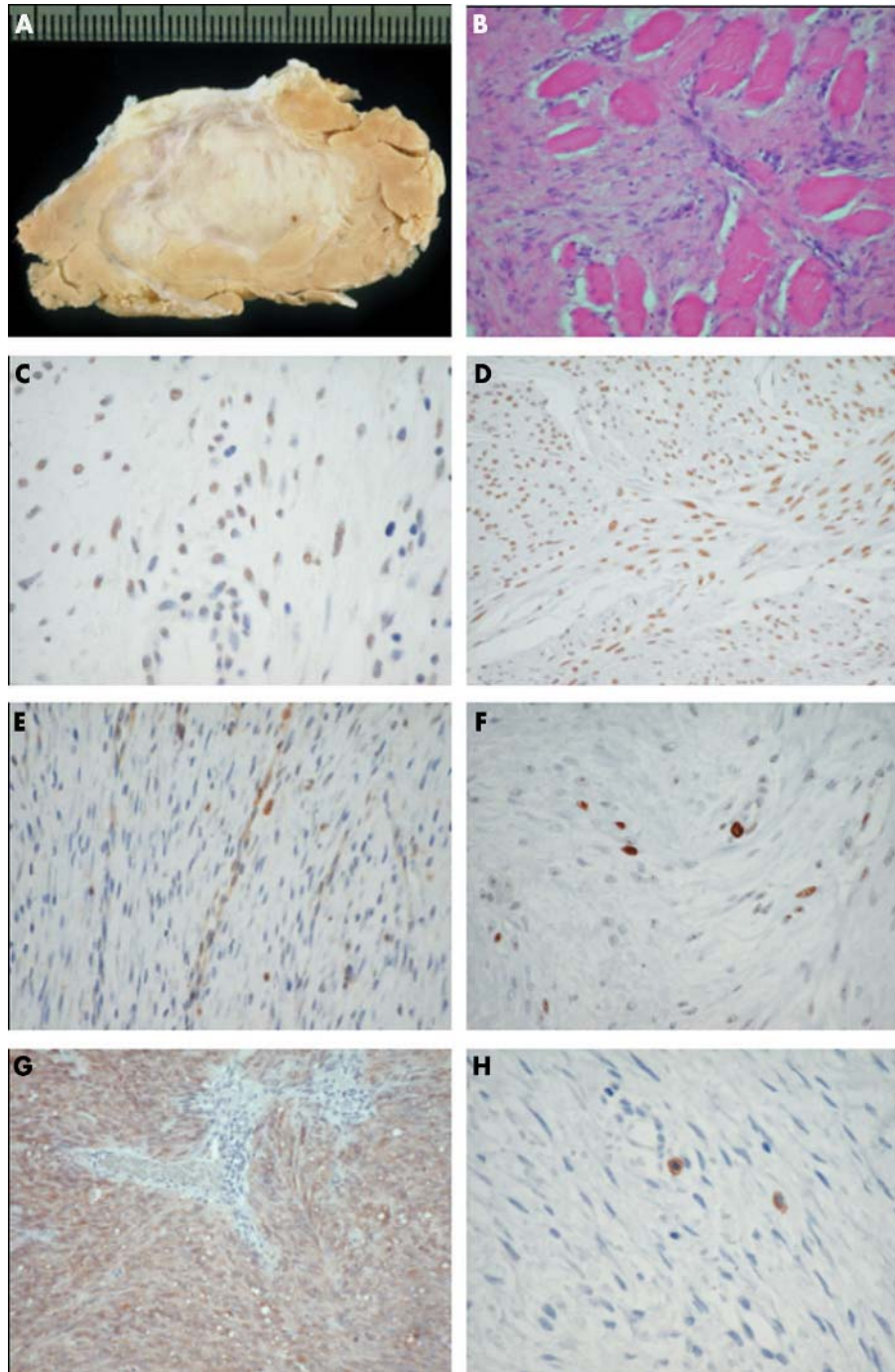
Desmoid subtype	No. patients	ER $\alpha$	ER $\beta$	PR	AR	SOM	HER2	Cath D	Ki-67	c-KIT
Extra-abdominal	46	0	4	0	6	6	0	46	14	0
Abdominal	21	0	2	0	0	2	0	21	3	1
Intra-abdominal	13	0	1	0	0	1	0	13	3	0
Total	80	0	7	0	6	9	0	80	20	1

AR, androgen receptor; Cath D, cathepsin D; ER $\alpha$ , oestrogen receptor  $\alpha$ ; ER $\beta$ , oestrogen receptor  $\beta$ ; PR, progesterone receptor; SOM, somatostatin.

**c-KIT (CD117)**

c-KIT was detected in only one of 21 abdominal cases, whereas gastrointestinal stromal tumour samples were

strongly positive (fig 2G, H). This single case was c-KIT negative in the primary tumour but positive in the first recurrence 25 months later.



**Figure 2** Histopathology of desmoid tumours and control samples. (A) Macroscopic view of the whitish cut surface of an extra-abdominal desmoid tumour. (B) Abdominal desmoid tumour showing the typical infiltrative growth pattern of the skeletal muscle (haematoxylin and eosin staining; original magnification,  $\times 200$ ). (C) Staining for androgen receptor showing a positive signal (original magnification,  $\times 600$ ). (D) Section of an extra-abdominal desmoid tumour with more than 90% of the cells showing strong staining for somatostatin (original magnification,  $\times 400$ ). (E) Staining for oestrogen receptor  $\beta$  showing focal positivity (original magnification,  $\times 400$ ). (F) Immunohistochemical analysis for Ki-67 (MIB-1) showing about 10% positive cells (original magnification,  $\times 600$ ). (G) Strong positive expression for c-KIT (CD117) in a gastrointestinal stromal tumour (original magnification,  $\times 200$ ) in contrast to (H) a c-KIT negative desmoid tumour, with two positive mast cells as a further internal positive control (original magnification,  $\times 600$ ).

## DISCUSSION

None of the present adjuvant treatment regimens for desmoid tumours has been evaluated in a randomised trial or is based on convincing clinical or experimental data. In contrast to the widely held belief, but in agreement with other published immunohistochemical series, our present study proves that desmoid tumours should be regarded as oestrogen receptor  $\alpha$  and c-KIT negative tumours.

Throughout the literature, desmoid tumours in general are thought to be hormonally sensitive, because young fertile women are often affected. Therefore, antioestrogens have been used as an adjuvant treatment successfully<sup>4</sup> or without benefit.<sup>5-6</sup> This treatment is based mainly on seven reports on the expression of oestrogen receptor  $\alpha$  in 20 of 38 desmoid tumours.<sup>2-7-13</sup> In contrast, no positive staining for oestrogen receptor  $\alpha$  was found in three large series with 72, 24, and 23 patients each,<sup>6-14-15</sup> or in five smaller reports with a total of 11 cases.<sup>16-20</sup> In addition, Chaudhuri and colleagues<sup>21</sup> reported negative oestrogen receptor findings in 17 fibrosarcomas, including a not specified number of desmoid tumours.

Oestrogen receptor negativity does not necessarily mean that the tumour is insensitive to oestrogen and is not affected by antioestrogens, such as tamoxifen.<sup>17</sup> Even some patients with oestrogen receptor negative breast cancer are known to respond to antioestrogens, although the response is much lower than that seen in oestrogen receptor positive patients.<sup>22</sup> An explanation for the sporadically reported effect of tamoxifen has been proposed by Lim and colleagues,<sup>7</sup> who found that four desmoid tumours that were oestrogen receptor negative had high numbers of antioestrogen binding sites in the subcellular fraction. However, this does not explain the conflicting results. In our present series, to rule out false negativity because of lack of sensitivity, the desmoid tumour samples were processed by an individual who has been in charge of breast cancer samples for many years.

Another enigma is the role of the newly established oestrogen receptor  $\beta$ , which has never been tested in desmoid tumours. The physiological role of oestrogen receptor  $\beta$  has not been extensively defined, so that the impact on treatment of a positive finding in a desmoid tumour is uncertain. Concerning sensitivity, seven different antibodies to oestrogen receptor  $\beta$  were tested by Skliris and colleagues,<sup>23</sup> and the one used in our present study provided the best nuclear immunoreactivity.<sup>23</sup>

Five small and one larger series reported immunostaining for the progesterone receptor, four with positive results in seven of 15 cases (including four juvenile fibromatoses),<sup>8-11</sup> two with negative results in eight cases,<sup>18-24</sup> and one with negative findings in 24 cases,<sup>15</sup> a finding that was confirmed in our series.

**“Oestrogen receptor negativity does not necessarily mean that the tumour is insensitive to oestrogen and is not affected by antioestrogens, such as tamoxifen”**

To our knowledge, the androgen receptor has been examined in only two cases (one positive) in a report focusing mainly on soft tissue sarcomas.<sup>18</sup> In our present series, six of 46 extra-abdominal desmoid tumours showed a weak positive signal.

De Pas and colleagues<sup>25</sup> retrospectively analysed 10 desmoid tumour samples for somatostatin receptor subtype 2, and found that two samples were positive. In our present series, nine of 80 samples were positive for somatostatin. The benefit of treatment with peptide receptor radiotherapy using a somatostatin analogue, as proposed by De Pas and colleagues,<sup>25</sup> remains unclear.

Overexpression of HER2 has been shown to be associated with tumorigenesis and enhanced tumorigenicity, and was

## Take home messages

- We analysed 80 desmoid tumours immunohistochemically for oestrogen receptor  $\alpha$  and  $\beta$ , HER2, the progesterone receptor, somatostatin, cathepsin D, and c-KIT
- All samples were negative for oestrogen receptor  $\alpha$  and only one sample was positive for c-KIT
- These data show that the published effects of anti-oestrogens and imatinib mesylate in the treatment of aggressive fibromatoses may not be attributable to oestrogen receptor  $\alpha$  or c-KIT expression

proposed as a prognostic factor in osteosarcoma.<sup>26</sup> However, our negative results are not surprising, because desmoid tumours do not dedifferentiate or metastasise.

Cathepsin D is a lysosomal acidic protease that may also stimulate tumour cell proliferation.<sup>16</sup> Its expression was previously reported in one intra-abdominal desmoid tumour.<sup>16</sup> Cathepsin D expression, which we found in all samples, might in part reflect the infiltrative growth behaviour of desmoid tumours.

Contrary to two negative reports in a total of 42 patients,<sup>27-28</sup> but in agreement with one series where 10 of 25 patients were positive,<sup>29</sup> and one case report,<sup>20</sup> we found that 20 of our 80 cases were positive for Ki-67. These discrepancies might result from the different cutoff values used: positive results with a cutoff value of 5%,<sup>29</sup> negative results with a cutoff value of 20%,<sup>28</sup> or not stated.<sup>27</sup> In our present series, using a cutoff value of 5%, only two of 20 positive samples had more than 10% positive cells. Brueckl and colleagues<sup>29</sup> found Ki-67 expression in 10 of 25 desmoid tumours, and also found it a useful predictive marker of disease free survival in patients with desmoid tumours. In our present series, it was impossible to validate this result because the samples tested originated from patients treated at 18 different institutions using different treatment regimens.

c-KIT is a transmembrane protein with tyrosine kinase activity. The pathogenetic role of c-KIT in the growth of several tumour types, such as gastrointestinal stromal tumours, has been demonstrated by expression analyses and mutational analyses,<sup>30</sup> and imatinib mesylate, a c-KIT tyrosine kinase inhibitor, has been used successfully in the treatment of gastrointestinal stromal tumours.<sup>30</sup> This new agent has been used in two patients with aggressive fibromatosis with, according to the authors, encouraging preliminary results.<sup>31</sup> However, data from previous studies on c-KIT immunoreactivity in aggressive fibromatoses are contradictory, with positive reports in 15 of 21 cases in two series,<sup>31-32</sup> negative ones in a total of 52 patients,<sup>20-33-35</sup> and one report on focal weak staining in only one of 20 desmoid tumours.<sup>36</sup> Moreover, Miettinen<sup>37</sup> and Hornick and Fletcher<sup>36</sup> questioned whether the positive report by Yantiss<sup>32</sup> might be a false positive. In our present series only one abdominal desmoid tumour showed weak positive immunostaining, unlike the strong expression seen in the positive controls (gastrointestinal stromal tumours). However, these differences might be explained in part by different c-KIT antibodies or the different dilutions used, as has been demonstrated by Lucas *et al.*<sup>33</sup> In our present study, the dilution used was higher (1/1000) than the one recommended by Lucas and colleagues (1/250)<sup>33</sup>; contrary to their report, we used a heat induced epitope retrieval method, which resulted in the gastrointestinal stromal tumours remaining highly positive and a reduction in the background

staining. Whether the reported effects of imatinib mesylate in two patients<sup>31</sup> are attributable to platelet derived growth factor receptor tyrosine kinase activity inhibition remains uncertain. Initially, we had planned to screen for platelet derived growth factor receptor also, but dismissed this idea because at present antibodies against platelet derived growth factor receptor remain inadequate.

In conclusion, the immunohistochemical analysis of tumour specimens from 80 patients with desmoid tumours showed that this tumour is oestrogen receptor  $\alpha$  and c-KIT negative. Therefore, the published effects of antioestrogens and imatinib mesylate in the treatment of aggressive fibromatoses may not be attributable to oestrogen receptor  $\alpha$  or c-KIT expression.

## ACKNOWLEDGEMENTS

This work was conducted by Austrian Cancer Aid/Styria as scientific research work, project number 05/2001. The authors thank M Al-Effah, Dr K Bodo, M Gogg-Kamerer, and A Sommersacher, Institute of Pathology, Medical University Graz, Austria for their helpful assistance with this project. Furthermore, the authors are indebted to A Schlemmer, Institute of Medical Informatics, Medical University Graz, Austria, for her data management.

## Authors' affiliations

**A Leithner, M Gapp, R Radl, A Pascher, R Windhager**, Department of Orthopaedic Surgery, Medical University Graz, Auenbruggerplatz 5, A-8036 Graz, Austria

**P Krippel**, Department of Medicine, Division of Oncology, Medical University Graz

**K Leithner**, Department of Medicine, Division of Pulmonology, Medical University Graz

**A Beham**, Institute of Pathology, Medical University Graz

## REFERENCES

- Goldblum J, Fletcher JA. Desmoid type fibromatoses. In: Fletcher CDM, Unni KK, Mertens F, eds. *World Health Organisation classification of tumours. Pathology and genetics of tumours of soft tissue and bone*. Lyon: IARC, 2002:83–4.
- Reitamo JJ, Scheinim TM, Hayry P. The desmoid syndrome. New aspects in the cause, pathogenesis and treatment of the desmoid tumor. *Am J Surg* 1986;**151**:230–7.
- Leithner A, Gapp M, Leithner K, et al. Margins in extra-abdominal desmoid tumors: a comparative analysis. *J Surg Oncol* 2004;**86**:152–6.
- Hansmann A, Adolph C, Vogel T, et al. High-dose tamoxifen and sulindac as first-line treatment for desmoid tumors. *Cancer* 2004;**100**:612–20.
- Easter DW, Halasz NA. Recent trends in the management of desmoid tumors. Summary of 19 cases and review of the literature. *Ann Surg* 1989;**210**:765–9.
- Pignatti G, Barbanti-Brodano G, Ferrari D, et al. Extraabdominal desmoid tumor. A study of 83 cases. *Clin Orthop* 2000;**375**:207–13.
- Lim CL, Walker MJ, Mehta RR, et al. Estrogen and antiestrogen binding sites in desmoid tumors. *Eur J Cancer Clin Oncol* 1986;**22**:583–7.
- Alman BA, Goldberg MJ, Naber SP, et al. Aggressive fibromatosis. *J Pediatr Orthop* 1992;**12**:1–10.
- Hayry P, Reitamo JJ, Vihko R, et al. The desmoid tumor. III. A biochemical and genetic analysis. *Am J Clin Pathol* 1982;**77**:681–5.
- Maddalozzo J, Tenta LT, Hutchinson LR, et al. Juvenile fibromatosis: hormonal receptors. *Int J Pediatr Otorhinolaryngol* 1993;**25**:191–9.
- Reis-Filho JS, Milanezi F, Pope LZ, et al. Primary fibromatosis of the breast in a patient with multiple desmoid tumors—report of a case with evaluation of estrogen and progesterone receptors. *Pathol Res Pract* 2001;**197**:775–9.
- Weiss SW, Langloss JM, Shmookler BM, et al. Estrogen receptor protein in bone and soft tissue tumors. *Lab Invest* 1986;**54**:689–94.
- McDougall A, McGarrity G. Extra-abdominal desmoid tumours. *J Bone Joint Surg Br* 1979;**61-B**:373–7.
- Sorensen A, Keller J, Nielsen OS, et al. Treatment of aggressive fibromatosis: a retrospective study of 72 patients followed for 1–27 years. *Acta Orthop Scand* 2002;**73**:213–19.
- Serpell JW, Tang HS, Donovan M. Factors predicting local recurrence of desmoid tumours including proliferating cell nuclear antigen. *Aust N Z J Surg* 1999;**69**:782–9.
- Arai N, Mitomi H, Uesugi H, et al. An aggressive desmoid tumor in a patient with familial adenomatous polyposis: immunohistochemical findings. *Am J Gastroenterol* 1999;**94**:530–2.
- Fong Y, Rosen PP, Brennan MF. Multifocal desmoids. *Surgery* 1993;**114**:902–6.
- Chaudhuri PK, Walker MJ, Beattie CW, et al. Presence of steroid receptors in human soft tissue sarcomas of diverse histological origin. *Cancer Res* 1980;**40**:861–5.
- Bulow S. Sulindac and tamoxifen in the treatment of desmoid tumours in patients with familial adenomatous polyposis. *Colorectal Dis* 2001;**3**:266–7.
- Heidemann J, Ogawa H, Otterson MF, et al. Antiangiogenic treatment of mesenteric desmoid tumors with toremifene and interferon alpha-2b: report of two cases. *Dis Colon Rectum* 2004;**47**:118–22.
- Chaudhuri PK, Walker MJ, Beattie CW, et al. Distribution of steroid hormone receptors in human soft tissue sarcomas. *Surgery* 1981;**90**:149–53.
- Early Breast Cancer Trialists' Collaborative Group. Systemic treatment of early breast cancer by hormonal, cytotoxic, or immune therapy. 133 randomised trials involving 31,000 recurrences and 24,000 deaths among 75,000 women. *Lancet* 1992;**339**:1–15.
- Skliris GP, Parkes AT, Limer JL, et al. Evaluation of seven oestrogen receptor beta antibodies for immunohistochemistry, western blotting, and flow cytometry in human breast tissue. *J Pathol* 2002;**197**:155–62.
- Biermann JS. Desmoid tumors. *Curr Treat Options Oncol* 2000;**1**:262–6.
- De Pas T, Bodei L, Pelosi G, et al. Peptide receptor radiotherapy: a new option for the management of aggressive fibromatosis on behalf of the Italian sarcoma group. *Br J Cancer* 2003;**88**:645–7.
- Morris CD, Gorlick R, Huvos G, et al. Human epidermal growth factor receptor 2 as a prognostic indicator in osteogenic sarcoma. *Clin Orthop Relat Res* 2001;**382**:59–65.
- Kouho H, Aoki T, Hisaoka M, et al. Clinicopathological and interphase cytogenetic analysis of desmoid tumours. *Histopathology* 1997;**31**:336–41.
- Hoos A, Lewis JJ, Antonescu CR, et al. Characterization of molecular abnormalities in human fibroblastic neoplasms: a model for genotype–phenotype association in soft tissue tumors. *Cancer Res* 2001;**61**:3171–5.
- Brueckl WM, Preuss JM, Wein A, et al. Ki-67 expression and residual tumour (R) classification are associated with disease-free survival in desmoid tumour patients. *Anticancer Res* 2001;**21**:3615–20.
- Heinrich MC, Blanke CD, Druker BJ, et al. Inhibition of KIT tyrosine kinase activity: a novel molecular approach to the treatment of KIT-positive malignancies. *J Clin Oncol* 2002;**20**:1692–703.
- Mace J, Sybil BJ, Sondak V, et al. Response of extraabdominal desmoid tumors to therapy with imatinib mesylate. *Cancer* 2002;**95**:2373–9.
- Yantiss RK, Spiro IJ, Compton CC, et al. Gastrointestinal stromal tumor versus intra-abdominal fibromatosis of the bowel wall: a clinically important differential diagnosis. *Am J Surg Pathol* 2000;**24**:947–57.
- Lucas DR, al Abbad M, Tabaczka P, et al. c-Kit expression in desmoid fibromatosis. Comparative immunohistochemical evaluation of two commercial antibodies. *Am J Clin Pathol* 2003;**119**:339–45.
- Miettinen M, Sobin LH, Sarlomo-Rikala M. Immunohistochemical spectrum of GISTs at different sites and their differential diagnosis with a reference to CD117 (KIT). *Mod Pathol* 2000;**13**:1134–42.
- Yamaguchi U, Hasegawa T, Masuda T, et al. Differential diagnosis of gastrointestinal stromal tumor and other spindle cell tumors in the gastrointestinal tract based on immunohistochemical analysis. *Virchows Arch* 2004;**445**:142–50.
- Hornick JL, Fletcher CD. Immunohistochemical staining for KIT (CD117) in soft tissue sarcomas is very limited in distribution. *Am J Clin Pathol* 2002;**117**:188–93.
- Miettinen M. Are desmoid tumors kit positive? *Am J Surg Pathol* 2001;**25**:549–50.



## Immunohistochemical analysis of desmoid tumours

A Leithner, M Gapp, R Radl, et al.

*J Clin Pathol* 2005 58: 1152-1156  
doi: 10.1136/jcp.2005.026278

---

Updated information and services can be found at:  
<http://jcp.bmj.com/content/58/11/1152.full.html>

---

### References

*These include:*

This article cites 34 articles, 5 of which can be accessed free at:  
<http://jcp.bmj.com/content/58/11/1152.full.html#ref-list-1>

Article cited in:  
<http://jcp.bmj.com/content/58/11/1152.full.html#related-urls>

### Email alerting service

Receive free email alerts when new articles cite this article. Sign up in the box at the top right corner of the online article.

---

### Topic Collections

Articles on similar topics can be found in the following collections  
[Immunology \(including allergy\)](#) (1279 articles)

---

### Notes

---

To request permissions go to:  
<http://group.bmj.com/group/rights-licensing/permissions>

To order reprints go to:  
<http://journals.bmj.com/cgi/reprintform>

To subscribe to BMJ go to:  
<http://group.bmj.com/subscribe/>