

CASE REPORT

Idiopathic pure red cell aplasia: first report on CD8 positive lymphocytosis in bone marrow biopsy sections

K M A Ramadan, J A M Anderson, M F McMullin, G M Markey

J Clin Pathol 2005;58:1118–1120. doi: 10.1136/jcp.2004.020875

There is no information in the literature regarding the lymphocyte content or type in bone marrow biopsies from patients with “idiopathic” pure red cell aplasia (PRCA). This report describes the bone marrow biopsy sections of a patient with PRCA. A diffuse CD3 positive (CD8 positive, granzyme B negative) lymphocytosis of approximately 1500/mm³ was revealed by immunohistochemical staining. The extent of the T cell increase was not evident from morphological examination of the bone marrow aspirate or biopsy, from flow cytometric analysis of the aspirate, or from the peripheral blood lymphocyte count. Therefore, immunohistochemical analysis should be performed routinely in this rare disease and the data acquired may help to inform the choice of treatment.

Many causes of pure red cell aplasia (PRCA) have been described—for example, B type lymphoproliferative neoplasia and occasionally T large granular lymphocytic (LGL) leukaemia, thymoma, autoimmune diseases, parvovirus B19 infection, and various drugs—but in 46% of cases no cause is demonstrable.¹ A variety of treatments (prednisolone, cyclosporin, antilymphocyte globulin, plasmapheresis, intravenous immunoglobulins, cyclophosphamide, and azathioprine) appear to be instituted on a fairly ad hoc basis, based on their variable success rates. Despite the differing lymphocyte subset targets of successful treatments, there has been little investigation of the presence and/or the nature of the lymphocyte populations involved in these “idiopathic” cases, and no investigation of the absolute lymphocytic content and its type in bone marrow biopsies from these patients. The only information from idiopathic cases appears to be occasional reports of an increase in an activated CD8 positive lymphocyte subset of non-clonal origin in peripheral blood or bone marrow aspirates.^{3–6} Our case report adds to knowledge of the pathogenesis of this disease and indicates the potential clinical usefulness of examining in detail the content and type of lymphocytes in bone marrow biopsies from patients with this rare disease.

“The only information from idiopathic cases appears to be occasional reports of an increase in an activated CD8 positive lymphocyte subset of non-clonal origin in peripheral blood or bone marrow aspirates”

CASE REPORT AND RESULTS

A 43 year old man presented with shortness of breath and palpitation for two weeks having lost 5 kg in weight over the previous two months. There was no drug history of note. On examination, he had no lymphadenopathy or organomegaly. His haemoglobin was 42 g/litre, white cell count was

5.1 × 10⁹ /litre, lymphocytes were 1.36 × 10⁹/litre, platelets were 497 × 10⁹/litre, mean corpuscular volume was 105 fl, and the reticulocyte count was 2.4 × 10⁹/litre (normal range, 50–200 × 10⁹/litre). Autoimmune screen (antinuclear, nucleolar, mitochondrial, smooth muscle, and gastric parietal cell antibody) and cytoplasmic and perinuclear antineutrophil cytoplasmic antibodies were negative.

A direct antiglobulin test was negative and vitamin B12 and folate values were normal. Serum erythropoietin was 7876 mIU/ml (normal range, 2.5–10.5). The erythrocyte sedimentation rate was 19 mm/hour. Iron studies and thyroid function tests were normal. Total bilirubin was 4 µmol/litre (normal range, 3–18) and lactate dehydrogenase was 506 U/litre (normal range, 360–720). Parvovirus IgM, human immunodeficiency virus, hepatitis B virus, and hepatitis C virus screens were negative. Paroxysmal nocturnal haemoglobinuria screening by peripheral blood flow cytometry after labelling with anti-CD55/59 was normal. A computerised tomography scan of the chest did not show a thymic mass. Oesophagogastroduodenoscopy showed a prepyloric ulcer and the patient had a positive CLO test. There was no evidence of coeliac disease in the biopsies.

A morphological examination of the bone marrow aspirate showed the absence of erythroid precursors, with 89% myeloid cells and 11% lymphocytes, none of which had LGL morphology. Flow cytometry revealed that 92% of the lymphocytes were T cells (CD3/4, +28%; CD3/8+, 63%; CD3+HLADR+, 38%) and 1.5% were B cells. Haematoxylin and eosin and Giemsa stained bone marrow biopsy (1.9 cm in length) sections showed the absence of erythroid precursors, no obvious diffuse increase of lymphocytes (fig 1A), and two lymphocytic aggregates, the largest measuring approximately 0.025 mm². Lymphocytes appeared to be extending from the aggregates into the surrounding bone marrow (fig 1B). Immunocytochemical staining was performed on sections of the patient's Bouin's fluid fixed bone marrow trephine biopsy using anti-CD3, anti-CD4, anti-CD8, anti-CD20, anti-granzyme B, and anti-glycophorin A monoclonal antibodies with avidin–biotin visualisation in an automated immunocytochemical analyser. The diffusely scattered positive cells were counted as described previously.² In brief, the visual field area of the ×25 objective of the light microscope used was 0.26 mm²; the positive cells in four consecutive fields of representative areas were counted. Figure 1C shows the pronounced diffuse increase in CD3+ T cells (CD3, ~ 1200/mm³; CD4, ~ 73/mm³; CD8, ~ 970/mm³; granzyme B+, ~ 48/mm³). CD 20+ cells were ~ 11/mm³ and very occasional groups of two to three glycophorin A+ erythroblasts were present. T cell receptor gene rearrangement (β and γ) was not demonstrated using primers and a gene scanning technique described previously.⁷

Abbreviations: LGL, T large granular lymphocytic; PRCA, pure red cell aplasia

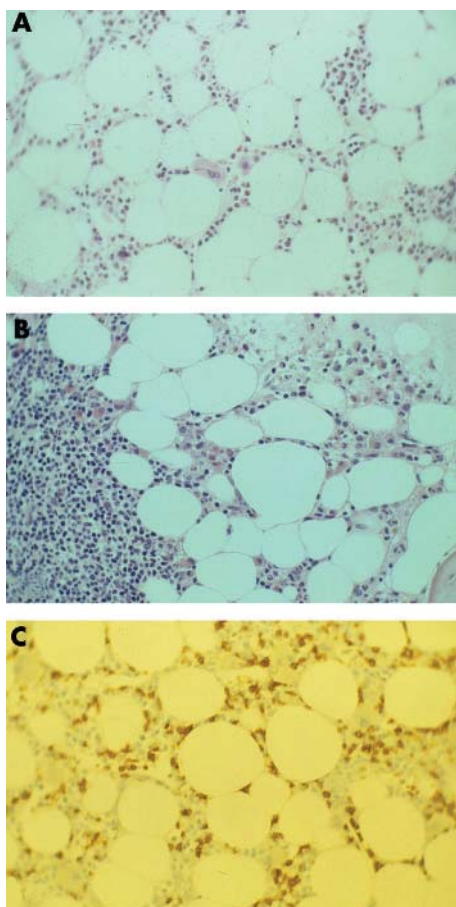


Figure 1 (A) Haematoxylin and eosin (H&E) stained section of bone marrow biopsy. (B) Lymphocytic aggregate in H&E stained section. (C) Anti-CD3 immunostained section.

Our patient was treated with prednisolone at 1 mg/kg/day with a good response: his haemoglobin rose rapidly to 128 g/litre. His haemoglobin value is currently maintained on 10 mg of prednisolone daily, although attempts to reduce this further resulted in a drop in haemoglobin. Peripheral blood lymphocyte immunophenotyping after the initiation of prednisolone treatment showed activated T cells. The white blood cell count was 6.7×10^9 /litre, 14% of which were lymphocytes. Flow cytometry showed that 90% of his lymphocytes were CD3+ (CD3/4+, 47%; CD3/8+, 42%; CD3/26+, 55%; CD3+HLADR+, 20%). He received triple therapy to eradicate *Helicobacter pylori*.

DISCUSSION

The presence of lymphocyte aggregates in our patient's biopsy and the apparent extension of lymphocytes from the lymphoid aggregates into the surrounding bone marrow raised the possibility of a lymphoproliferative neoplasia underlying the PRCA. T cell receptor gene rearrangement studies were negative using a technique that has been reported to detect rearrangements in 98% of patients with T cell clonal disease.⁷ In addition, the lymphocytes were not of the LGL type or granzyme B positive. To date, the evidence is that he has a "benign" lymphocytosis responsible for his PRCA, which is currently "idiopathic".

There is very little histopathological data in the literature regarding the lymphocytic content of bone marrow biopsies in idiopathic PRCA. There appears to be only one report of a nodular and diffuse infiltrate of small lymphocytes in the bone marrow biopsy of a patient who was, however,

subsequently shown to have T cell receptor gene rearrangement and T cell LGL leukaemia. LGL leukaemia/lymphoma was excluded in our patient. There are occasional reports of the occurrence of an increased proportion of an activated CD8+ T cell subset demonstrated in bone marrow aspirate samples by flow cytometry, as was the case in our patient.³⁻⁶ However, this gives no indication of the size of this population—in our patient only 11% of the aspirated cells were lymphocytes, whereas immunostaining of the biopsy revealed the presence of a very large T cell population. This demonstration of the size of the lymphocytic population by the immunohistochemical evaluation of the bone marrow biopsy was unexpected. Also striking was the fact that the peripheral blood lymphocyte count was normal despite the presence of a high number of T cells in the bone marrow biopsy. Another instructive feature of this case was that the magnitude of the lymphocyte increase revealed by immunostaining had not been apparent either on haematoxylin and eosin or Giemsa stained sections, posing the question of whether similar sized populations are common in PRCA but are missed without immunohistochemical staining.

"The peripheral blood lymphocyte count was normal despite the presence of a high number of T cells in the bone marrow biopsy"

Whether there is such a thing as a "normal" level of polyclonal B and T cells in bone marrow from patients who have bone marrow examination has not been established, but we regularly see (unpublished observations) 50–200 CD20+ or 100–300 CD3+ lymphocytes/mm³ in situations where neither is neoplastic. We can then be confident that in our patient the T cells were greatly increased. The increase was predominantly of the granzyme B–, CD8+ subtype, enabling us to predict a response to steroids/cyclosporin/antilymphocyte globulin treatment should spontaneous remission not occur (as proved to be the case). A response to rituximab in a patient who failed to respond to cyclosporin has also been described.⁸ Rituximab treatment would have been inappropriate in our patient. However, it is possible that the examination of lymphocyte subsets in the bone marrow biopsies of patients with idiopathic PRCA will reveal instances in which the B cell population is increased and more likely to be the subset involved. It is also possible that the size of the CD3+ population is related to responsiveness to treatment. Although our patient responded rapidly to prednisolone, he requires a relatively high maintenance dose

Take home messages

- We report a diffuse CD3 positive (CD8 positive, granzyme B negative) lymphocytosis of approximately 1500/mm³ in a patient with "idiopathic" pure red cell aplasia revealed by immunohistochemical staining of bone marrow biopsy sections
- The extent of the T cell increase was not evident from morphological examination of the bone marrow aspirate or biopsy, from flow cytometric analysis of the aspirate, or from the peripheral blood lymphocyte count
- We suggest that immunohistochemical analysis should be performed routinely in this rare disease and that the data acquired may help to inform the choice of treatment

and may require more specific anti-T cell treatment in the future.

PRCA is a rare disorder. Antibodies that enable a considerable degree of lymphocyte subtyping in bone marrow biopsies are now available and determination of absolute numbers of the various lymphocyte subsets in bone marrow biopsies is a quick and easy process that would permit interlaboratory comparability of data. We suggest that lymphocyte subtyping performed on biopsy sections should be incorporated into the investigation of these patients because there is information, which may inform treatment, yet to be acquired.

Authors' affiliations

K M A Ramadan, J A M Anderson, G M Markey, Haematology Department, Belfast City Hospital, Belfast BT9 7AB, Northern Ireland, UK
M F McMullin, The Queen's University at Belfast, Belfast BT7 1NN, Northern Ireland, UK

The patient gave full consent for this case report to be published

Correspondence to: Dr K M A Ramadan, Haematology Department, C-Floor, Belfast City Hospital Trust, Lisburn Road, Belfast BT9 7AB, Northern Ireland, UK; kramadan4@email.com

Accepted for publication 17 January 2005

REFERENCES

- 1 **Mamiya S**, Itoh T, Miura AB. Acquired pure red cell aplasia in Japan. *Eur J Haematol* 1997;**59**:199–205.
- 2 **Markey GM**, Kettle P, Morris TCM, *et al*. Quantitation of monoclonal plasma cells in bone marrow biopsies in plasma cell dyscrasia. *Anal Cell Pathol* 2003;**25**:167–71.
- 3 **Lipton JM**, Nadler LM, Canellos GP, *et al*. Evidence for a genetic restriction in the suppression of erythropoiesis by a unique subset of T lymphocytes in man. *J Clin Invest* 1983;**72**:694–706.
- 4 **Abkowitz JL**, Kadin ME, Powell JS, *et al*. Pure red cell aplasia: lymphocyte inhibition of erythropoiesis. *Br J Haematol* 1986;**63**:59–67.
- 5 **Totterman TH**, Bengtsson M. Treatment of pure red cell aplasia with cyclosporin: suppression of activated T suppressor/cytotoxic and NK-like cells in marrow and blood correlates with haematological response. *Eur J Haematol* 1988;**41**:204–11.
- 6 **Rameshwar P**, Ramkissoon SH, Sundararajan S, *et al*. Defect in the lymphoid compartment might account for CD8+-mediated effects in the pathophysiology of pure red cell aplasia. *Clin Immunol* 2003;**108**:248–56.
- 7 **Assaf C**, Hummel M, Dippel E, *et al*. High detection rate of T-cell receptor beta chain rearrangement in T-cell lymphoproliferations by family specific polymerase chain reaction in combination with the GeneScan technique and DNA sequencing. *Blood* 2000;**96**:640–6.
- 8 **Auner HW**, Wolfner A, Beham-Schmid C, *et al*. Restoration of erythropoiesis by rituximab in an adult patient with primary acquired pure red cell aplasia refractory to conventional treatment. *Br J Haematol* 2002;**116**:727–8.



Idiopathic pure red cell aplasia: first report on CD8 positive lymphocytosis in bone marrow biopsy sections

K M A Ramadan, J A M Anderson, M F McMullin, et al.

J Clin Pathol 2005 58: 1118-1120
doi: 10.1136/jcp.2004.020875

Updated information and services can be found at:
<http://jcp.bmj.com/content/58/10/1118.full.html>

These include:

References

This article cites 7 articles, 1 of which can be accessed free at:
<http://jcp.bmj.com/content/58/10/1118.full.html#ref-list-1>

Email alerting service

Receive free email alerts when new articles cite this article. Sign up in the box at the top right corner of the online article.

Topic Collections

Articles on similar topics can be found in the following collections

[Clinical diagnostic tests](#) (637 articles)
[Immunology \(including allergy\)](#) (1279 articles)

Notes

To request permissions go to:
<http://group.bmj.com/group/rights-licensing/permissions>

To order reprints go to:
<http://journals.bmj.com/cgi/reprintform>

To subscribe to BMJ go to:
<http://group.bmj.com/subscribe/>