



Best Practice No 180

# Nephrectomy for renal tumour; dissection guide and dataset

S Fleming, D F R Griffiths

*J Clin Pathol* 2005;58:7–14. doi: 10.1136/jcp.2003.014159

Renal tumours constitute 2.5% of all malignancies and are among the 10 most common malignancies in the UK. Most of these are renal cell carcinomas (RCC) of various subtypes. Although historically RCC has been shown to be resistant to radiotherapy and chemotherapy, recent data suggest that the use of biological treatments, such as adjuvants, may be beneficial in patients with disease that has progressed at the time of presentation. The accurate diagnosis, staging, and grading of RCC is now a crucial element in optimal patient management. There are data to support the importance of histological type, tumour size, stage (especially patterns of extrarenal spread), and grade in determining outcome, and these data have been used to develop the published classification (Heidelberg/Rochester), staging (TNM), and grading (Fuhrman) systems. This article describes a dissection and histological sampling protocol that has been shown to increase the yield of staging information, a guide to histological classification and grading, and finally a minimum dataset for the completion of a satisfactory pathology report.

treatments, such as interleukin 2 and  $\gamma$  interferon, which interfere with tumour neoangiogenesis, and more recently tumour vaccines.<sup>3</sup> The importance of surgery in the management of renal cell carcinoma means that early diagnosis, treatment, and accurate surgical pathology evaluation are crucial in the management of patients with renal cancer. The role of the surgical pathologist is to give accurate information on the diagnosis of renal cell carcinoma, and to document accurately the pathological features that have prognostic relevance and which may guide future non-surgical treatment.

## EVIDENCE BASE FOR PATHOLOGICAL EVALUATION

### Staging criteria

In almost all series of renal cell carcinomas the most important prognostic factor is tumour stage at the time of surgical resection.<sup>4–8</sup> Historically, the Robson staging protocol has been used,<sup>4</sup> but nowadays the TNM classification provides more complete data and is regularly updated to accommodate new evidence. The most recent update of the TNM classification for the staging of renal cell carcinoma was published in 2002 (fig 1),<sup>9</sup> and shows significant changes from the 1997 version. These changes, in tumour size criteria and in the status of renal sinus invasion, have a major impact on the technique of primary dissection of nephrectomy specimens. For the surgical pathologist an important point to remember is that almost all of the TNM staging criteria are derived from the primary dissection and macroscopic observation rather than histology. The exceptions to this are the assessment of nodal status, renal sinus invasion including microvascular invasion of the renal sinus, invasion of segmental veins, and histological evidence of invasion outside the kidney.

**R**enal cancer is common, representing 2.5% of all malignancies, and there are now 6500 new cases/year in the UK. Indeed, it is estimated that the worldwide incidence of renal cell carcinoma is increasing at an annual rate of approximately 1.5–5.9%.<sup>1</sup>

“The importance of surgery in the management of renal cell carcinoma means that early diagnosis, treatment, and accurate surgical pathology evaluation are crucial in the management of patients with renal cancer”

Most of these malignancies are renal carcinomas, but in childhood Wilms’s tumour is much more frequent. Overall survival is relatively poor, achieving only 35–40% at five years in the UK.<sup>2</sup> The main curative option for management is surgical excision, because renal cell carcinoma appears to be particularly resistant to chemotherapy and radiotherapy. There have been some mildly encouraging results of delayed progression and increased survival using biological

### Kidney confined cancer (pT1 and pT2)

For tumours of the pT1 and pT2 categories, the maximum tumour diameter of kidney confined tumours is the determining criterion. The maximum size of the primary tumour emerges as an important factor in most studies of prognostic significance, although not always as an influential variable in multivariate analysis.<sup>10–13</sup> This variable and its impact on outcome<sup>11–13</sup> has a continuous distribution, therefore accurate documentation of the tumour size is important; however, for the purposes of management and clinical trial protocols case grouping is necessary.

See end of article for authors’ affiliations

Correspondence to:  
Professor S Fleming,  
Division of Pathology and  
Neuroscience, University  
of Dundee, Ninewells  
Hospital, Dundee DD1  
9SY, UK; [s.fleming@dundee.ac.uk](mailto:s.fleming@dundee.ac.uk)

Accepted for publication  
16 June 2004

**Primary tumour**

pT1	< 7 cm confined to kidney
pT1a	< 4 cm
pT1b	4–7 cm
pT2	> 7 cm confined to kidney
pT3	Invasion of perinephric tissue, adrenal, or vein
pT3a	Adrenal or perinephric fat invaded
pT3b	Invasion of renal vein(s) and/or vena cava below diaphragm
pT3c	Invasion of vena cava above diaphragm
pT4	Invasion beyond Gerota's fascia

**Lymph nodes**

NX	Nodal status cannot be assessed
N0	No nodal involvement
N1	One node involved
N2	More than one node involved

**Metastasis**

MX	Distant metastases cannot be assessed
M0	No distant metastases
M1	Distant metastases present

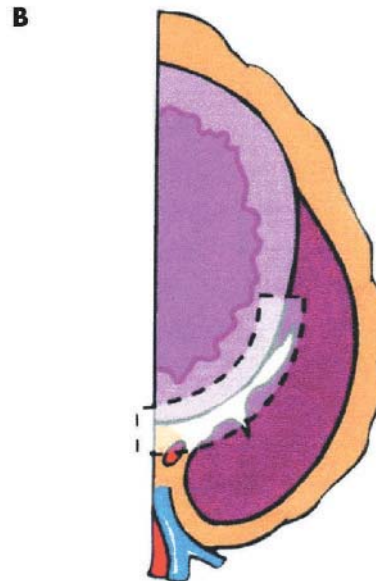
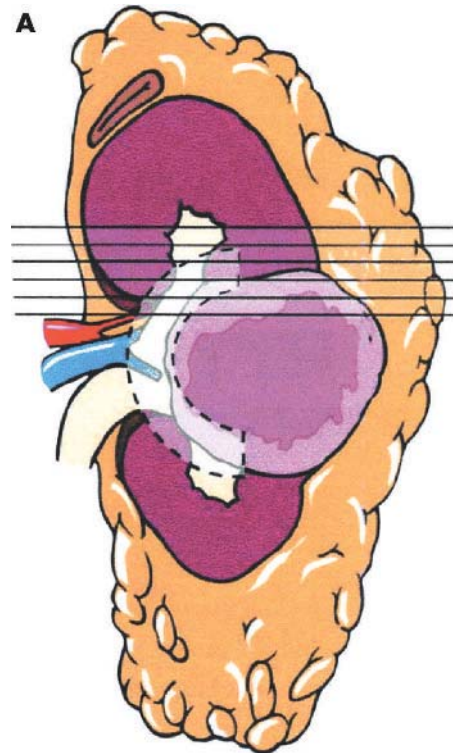
**Figure 1** TNM staging of renal carcinoma.

Evidence from several large series has suggested that identifying primary tumours of greater than 7 cm in diameter, even when still kidney confined, provided a useful prognostic group compared with tumours of less than 7 cm in diameter<sup>11</sup>. However, for assessing cancer specific survival, a maximum tumour diameter of 4.5 or 5 cm had a stronger predictive value,<sup>14–15</sup> whereas 4 cm diameter correlated better with disease free survival.<sup>16</sup> These data suggested that small tumours, less than 4 cm, had a significantly better prognosis, that the 4 cm cut off provided better discrimination, and furthermore that these tumours were more likely to be amenable to nephron sparing surgery. With this evidence in mind, the latest TNM classification recognises tumours of less than 7 cm as pT1, with a subcategory of tumours of less than 4 cm in diameter as pT1a, tumours between 4 and 7 cm as pT1b, and tumours of greater than 7 cm but still kidney confined as pT2.

**Extension beyond the kidney (pT3)**

Spread beyond the kidney has been recognised as a major prognostic factor for many years. This is the basis for the Robson classification,<sup>4–17</sup> which has been widely used since its introduction in the 1960s. However, identification of invasion outside the kidney is not necessarily straightforward; tumours commonly distort the renal capsule, will usually have a fibrous pseudocapsule, and there may be collar stud invasion into this pseudocapsule. It will not usually be possible to identify the original renal capsule. A recent study has shown that the only tumour margin type that has any prognostic impact is cellular invasion of fat without a surrounding pseudocapsule<sup>16</sup>; it is recommended that this should be the criterion used or the designation of category pT3a. Direct spread into the perinephric fat and adjacent tissues is best assessed by sectioning through the radical nephrectomy specimen without previous removal of the perinephric fat.

Involvement of the ipsilateral adrenal gland by direct spread, which occurs in about 5% of cases, is significantly



**Figure 2** (A) Sagittal cut surface of specimen: the opaque overlay indicates the site of the tumour–renal sinus interface. The lines indicate the orientation of the slices to be taken. (B) An individual slice including tumour; the opaque overlay indicates the tumour–renal sinus interface. This may be present in multiple slices and should be systematically sampled (from Griffiths and colleagues<sup>32</sup>).

different from adrenal involvement by blood borne metastases. The first scenario is categorised as pT3a and the second as M1. Careful identification of direct spread is therefore crucial.

Recently, Bonsib *et al* have provided evidence suggesting a poor prognosis after invasion of the renal sinus.<sup>18</sup> The renal sinus is the fatty tissue located within the boundaries of the kidney and enveloping the collecting system. It contains numerous large thin walled veins and lymphatics, and it is not separated from the renal cortex by a fibrous capsule.

Bonsib *et al* showed that involvement of the renal sinus, especially invasion of small sinus veins, was common in renal cell carcinoma.<sup>18</sup> Invasion of the renal sinus for staging purposes is defined as either direct invasion of the sinus fat or penetration of veins within the renal sinus. These two categories of extrarenal spread, namely perirenal and sinus invasion, are both designated as pT3a.

### Invasion of the renal vein (pT3b, pT3c)

Invasion of the major renal veins by renal carcinoma has long been thought to have poor prognosis, venous invasion being seen as the precursor to distant blood borne metastases. It is important to recognise this phenomenon during the initial dissection of the nephrectomy specimen; in the TNM classification, invasion of the main renal vein or its muscle containing segmental branches is the criterion for the pT3b category. Vein wall retraction occurs after surgery, so at this site adequacy of excision may be difficult to determine, and is not in any case a staging criterion. Renal cell carcinoma frequently grows en masse along the renal vein into the inferior vena cava. Identification of the level of extension into the inferior vena cava will not usually be possible on a nephrectomy specimen alone. If there is caval thrombus this will usually be submitted separately from the nephrectomy; here, the role of the pathologist is to confirm that the thrombus consists of tumour and to record the level from which it was taken. The level at which increasing caval involvement confers a higher risk is controversial with two recent papers coming to opposite conclusions.<sup>19 20</sup> However, it is generally accepted that extension above the diaphragm confers a significantly worse prognosis, partly because of the consequence of metastatic spread, but also because of the pronounced increase in operative mortality for tumours extending above the diaphragm. The TNM classification recognises these differences—renal vein or inferior vena caval involvement below the diaphragm is classified as pT3b, whereas involvement above the diaphragm is pT3c.

“Extension above the diaphragm confers a significantly worse prognosis, partly because of the consequence of metastatic spread, but also because of the pronounced increase in operative mortality for tumours extending above the diaphragm”

It has recently been appreciated that microvascular invasion—that is, vascular invasion only recognised histologically—is of prognostic value, particularly for kidney confined renal cell carcinoma.<sup>21 22</sup> In the UICC 2002 system, microvascular invasion in the renal sinus, the most common

site, is considered to be pT3a, whereas microvascular invasion identified elsewhere is not part of the staging system, although it probably has similar prognostic impact and should be sought during histological examination and included in the final report.

### Involvement of the pelvicalyceal system

At the moment, invasion of the pelvicalyceal system is not considered part of the TNM classification. However, recent work has shown that although it is uncommon it does confer a significantly worse outcome.<sup>23</sup> It is of value to record involvement of the collecting system if it is seen.

### Extensive local spread

Invasion beyond Gerota’s fascia is an important prognostic feature, largely because of the surgical implications. Gerota’s fascia is in the surgical dissection plane for radical nephrectomy, and tumours that have invaded beyond this plane have a high incidence of residual retroperitoneal disease after radical nephrectomy. Renal cell carcinoma can also spread to involve adjacent organs, such as the pancreas and colon. All of these features of direct continuous spread beyond Gerota’s fascia and/or involving adjacent organs are classified as pT4.

### Nodal involvement

Renal cell carcinoma can invade and spread via the lymphatics to regional lymph nodes, but the detection rate of this pattern of spread depends on the surgical procedure. Hermanek and Schrott<sup>24</sup> showed that, in patients in whom lymph node status was definitively ascertained and shown to be N0, there was a 74% five year survival, whereas in the group in whom lymph node status could not be determined (NX), there was only a 61% five year survival, suggesting that among the NX group there are patients with unrecognised lymph node metastases who have been inaccurately down-staged. This is supported by a study from Genoa of 328 cases of renal cell carcinoma treated routinely by radical nephrectomy and lymphadenectomy.<sup>25</sup> Lymph node dissection and

#### Summary of histological sampling of renal carcinoma

- One block/cm of primary tumour
- Two or three blocks of extension into perirenal fat
- One block/cm of tumour–renal sinus interface
- One block from renal vein, renal artery, and ureter
- Blocks from areas of venous or collecting system invasion
- At least one block from tumour–kidney interface
- Blocks from all lymph nodes
- One block from adrenal gland
- Blocks from any other renal abnormalities
- One or two blocks from macroscopically normal renal parenchyma

Figure 3 Summary of histological sampling.

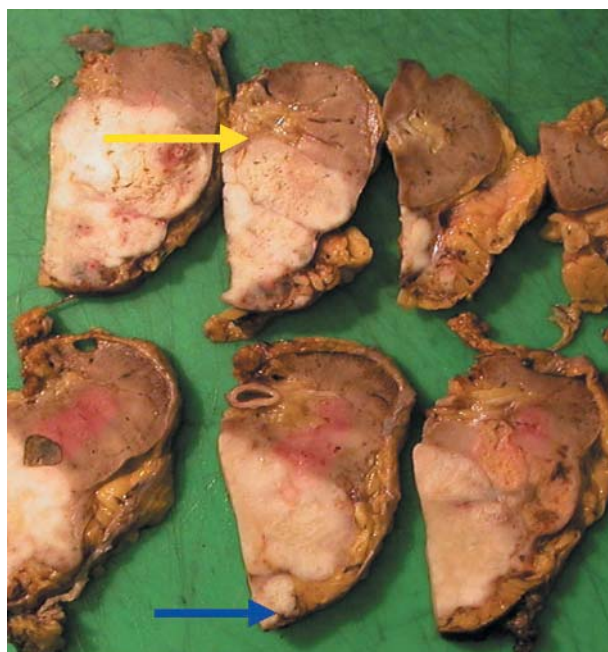

Figure 4 The use of digital photography retains a record of the dissection and the identification of areas of tumour invasion of the renal sinus (yellow arrow) or extracapsular spread (blue arrow). The digital image can be reviewed as part of multidisciplinary team meetings.

accurate histological demonstration of metastases led to 7% of the total series being accurately staged with lymph node involvement as their only evidence of extra renal spread. Similar data from other centres,<sup>26</sup> and from EORTC trials,<sup>27</sup> suggest that for kidney confined tumours (pT1, pT2), between 3% and 10% have nodal involvement, often only microscopically. This is clearly an important group to recognise because these patients showed a 53% five year survival, compared with those confirmed to be N0, who had a 70% five year survival. Furthermore, the use of immunotherapy in patients with confirmed extrarenal spread (pT3, pT4, N1, N2, or M1) has been shown to confer a significantly improved survival at two and five years.<sup>26, 28</sup> Therefore, accurate staging of renal carcinoma with regard to nodal involvement is now important for therapeutic decision making. However, the surgeon must make a balanced judgement of the benefit for the 5–10% of patients accurately staged against the 90–95% in whom the lymphadenectomy would probably have no added benefit and may increase postoperative morbidity and even mortality.<sup>26</sup> In practice, in the UK, most surgeons, based on this assessment of risk versus benefit, do not perform extended lymphadenectomy. Within the TNM criteria, adequate assessment of nodes for determining N status requires eight lymph nodes to be sampled,<sup>9</sup> although the evidence base would suggest that only after assessment of 12 nodes can metastasis be excluded.<sup>29</sup> Surprisingly, the TNM publication states that no evidence of nodal metastases, even if less than eight nodes are sampled, should be classified as N0, although it would be more logical to consider these as pNX. Involvement of one lymph node is designated pN1 and more than one node as pN2.

“In practice, in the UK, most surgeons, based on this assessment of risk versus benefit, do not perform extended lymphadenectomy”

#### Distant metastases

Metastatic spread—usually to the lung, bone, liver, or contralateral kidney—is present in approximately 25% of patients undergoing surgery for renal cancer in the UK. More cases with metastasis may be seen in the future because nephrectomy has been shown to improve the prognosis in patients with disseminated disease.<sup>30</sup> The presence of such metastases at presentation confers very poor prognosis, with a five year survival of less than 5%.

#### PRIMARY DISSECTION AND SPECIMEN SAMPLING FOR HISTOLOGY

The Royal College of Pathologists' minimum data set for adult renal tumours was published in 2000,<sup>31</sup> but the data included have been superseded by the revision of the TNM categories, and the dataset included no guidance as to the method of generating the required information. Several protocols for the examination of nephrectomy specimens have been proposed, but recent data suggest that the model proposed by Griffiths *et al* and proposed here,<sup>32</sup> itself a minor modification of previous protocols,<sup>33–35</sup> maximises the diagnostic yield, in particular the identification of renal sinus and microvascular invasion.<sup>32</sup> This protocol is to be recommended for the examination of nephrectomy specimens, for the accurate recording of the current accepted morbid anatomical prognostic data, and for histological sampling (figs 2, 3).

#### Recommended procedure

- (1) Weigh, measure, and then bisect, in the sagittal plane, the nephrectomy specimen into anterior and posterior halves, cutting from the lateral border towards the

#### Primary tumour

pTa	Non-invasive papillary
pTis	Carcinoma in situ
pT1	Invasion of subepithelial connective tissue
pT2	Invasion of muscularis of renal pelvis or ureter
pT3	Invasion of peripelvic fat or renal parenchyma
pT4	Invasion of adjacent organs through the kidney into perinephric fat

#### Lymph nodes

pNx	Lymph nodes cannot be assessed
pN0	No regional lymph node metastases
pN1	Metastasis in a single node < 2 cm diameter
pN2	Metastasis in a single node 2–5 cm or multiple nodes all < 5 cm
pN3	Nodal metastasis > 5 cm maximum dimension

#### Metastasis

pM	Distant metastasis cannot be assessed
pM0	No distant metastasis
pM1	Distant metastasis present

Figure 5 TNM classification of tumours of the renal pelvis.

hilum. This should be performed with the perinephric fat being disturbed as little as possible. The tumour will normally be adequately displayed by this procedure, and the specimen can then be photographed and fixed (fig 4). If on external examination of the specimen the pathologist has any concerns about the excision margins, the outer border can be inked before dissection. Although we do not routinely ink all nephrectomy specimens, some pathologists do.

- (2) Identify and dissect any perirenal and hilar lymph nodes if they are present, although these are rarely identifiable unless specifically dissected by the surgeon. Sample all nodes for histology.
- (3) Identify the ureter, renal vein, and artery at the hilum. Identify invasion of the renal vein and its segmental branches or invasion of the pelvicalyceal system. Sample a transection of the ureter, renal vein, and artery at the resection margin. Sample any areas suspicious of venous or collecting system invasion.
- (4) Measure the maximum tumour diameter in millimetres.
- (5) Each half of the nephrectomy specimen should then be cut into 4–5 mm slices in the horizontal plane, without removing perinephric fat. The slices should then be separated and laid out sequentially, so that the relation between the tumour, the remaining kidney, perinephric fat, and renal sinus can clearly be seen (fig 4).
- (6) Assess the surgical margin at the renal capsule or perinephric fat. In particular, note any invasion of Gerota's fascia, incomplete excision, or for upper pole tumours involvement of the adrenal gland. Take histological samples of two to three blocks at the point of greatest extension into the perinephric fat.
- (7) Assess the renal tumour at the renal sinus. Ideally, sample the entire tumour sinus interface. Large or centrally sited tumours may appear to obliterate the renal sinus. In these cases, it is essential to lay out the slices so that they can be examined in a good light. After smeared blood is rinsed off with running water, careful examination will usually reveal some residual renal

sinus. This can be identified by flecks of fat and prominent blood vessels at the edge of the tumour, or compressed between the tumour and the adjacent parenchyma. In cases with an extensive tumour renal sinus interface (many of which will show renal sinus or vascular invasion), it is suggested that 10 blocks are taken in the first instance, with further blocks taken if such invasion is not identified.

- (8) Sample at least one block of the interface between the tumour and the adjacent kidney.
- (9) Sample any macroscopically distinctive areas to ensure sarcomatoid change or high grade is not missed. The total tumour sampling (peripheral margin + sinus margin + other blocks of tumour) should be at least one block for each centimetre of tumour diameter.
- (10) Describe and sample the adrenal gland.
- (11) Identify any further abnormality in the renal parenchyma and sample.
- (12) Sample one or two blocks from macroscopically normal kidney.

### Nephron sparing surgery

Nephron sparing surgery is increasingly being performed for small renal tumours. For the assessment of partial

nephrectomies, the procedure is essentially the same as for radical nephrectomy, with a few modifications. In these specimens, perirenal fat may or may not be submitted.<sup>36-38</sup> Tumour present at the excision margin correlates with local recurrence,<sup>39-40</sup> so the most important additional feature to be assessed is the excision margin at the renal parenchyma. It is recommended that the excision margins are inked before dissection, and that in addition to all the other staging criteria (above), examination for tumour at the resection margin is undertaken and reported. The current data suggest that the distance of the surgical clearance shows no correlation with outcome, although the measurement from tumour to the closest margin may be useful for surgical audit.<sup>39-41</sup> Tumour stage and grade remain the most important prognostic factors in renal cell carcinoma when treated by nephron sparing surgery.<sup>39</sup> Frequently, frozen section examination is requested in nephron sparing surgery for an assessment of the excision margin and/or histological characterisation of the tumour. If frozen section is requested, it is recommended that the primary dissection is performed in such a way as to maintain, as far as possible, morbid anatomy, to allow accurate assessment of the tumour pathology and stage when one comes to fix and dissect the specimen for paraffin wax sections. The techniques for sampling for frozen sections are standard, and the potential pitfalls in their assessment for the pathology of the primary tumour and for the assessment for excision margins have been described.<sup>42</sup>

#### Benign

- Renal adenoma
- Metanephric adenoma
- Nephrogenic adenofibroma
- Oncocytoma

#### Malignant

- Renal cell carcinoma conventional type
- Morphologic variants
- Papillary renal cell carcinoma type 1 or 2
- Chromophobe renal carcinoma
- Collecting duct carcinoma
- Medullary carcinoma of kidney
- Low grade collecting duct carcinoma
- Xp11 translocation associated renal tumour
- Mucinous tubular and spindle cell carcinoma
- Primary neuroepithelial or neuroendocrine tumour of the kidney
- Mixed epithelial and stromal tumour of kidney
- Oncocytoid renal tumour in neuroblastoma survivors
- Renal cell carcinoma unclassified

#### Mesenchymal renal tumours

- Angiomyolipoma
- Epithelioid angiomyolipoma
- JGA tumour
- Renomedullary interstitial cell tumour
- Synovial sarcoma
- Solitary fibrous tumour
- Cystic embryonal sarcoma of the kidney
- Haemangioma
- Leiomyoma
- Leiomyosarcoma
- Lipoma
- Liposarcoma
- Malignant fibrous histiocytoma
- Rhabdomyosarcoma
- Haemangiopericytoma
- Osteosarcoma
- Chondrosarcoma
- Lymphoma

#### Tumour-like lesions

- Multilocular cystic nephroma
- Xanthogranulomatous pyelonephritis
- Malakoplakia
- Fibroepithelial polyp
- Inflammatory pseudotumour

### Urothelial carcinoma of the renal pelvis

Primary urothelial carcinoma accounts for about 5% of malignancies in the kidney. The TNM staging criteria for primary urothelial carcinoma are an anatomical modification of the staging criteria applied to urothelial carcinoma of the bladder.<sup>9</sup> There is no separate evidence base for these criteria when applied to the kidney, but rather the criteria are applied in an attempt to achieve consistency in staging among the various sites in which urothelial carcinoma develops. The surgery performed for urothelial carcinoma, when the diagnosis is suspected preoperatively, differs from that performed for parenchymal renal tumours. The high rate of recurrence or simultaneous tumours throughout the collecting system has led to the use of nephro-ureterectomy in the surgical management of urothelial carcinoma of the renal pelvis. The extended ureteric tissue, and the need to exclude multifocal disease, mean that these specimens are dissected by a modification of the above protocol. The renal pelvis and ureter are inspected for any abnormalities and these are sampled for histology. Blocks are taken from morphologically normal renal pelvis and ureter to exclude flat in situ urothelial carcinoma, and the distal excision margin of the ureter is sampled. Lymph nodes should all be sampled histologically, but enlarged nodes should also be measured (fig 5). Figure 5 summarises the TNM criteria for staging of

**Table 1** Fuhrman nuclear grading of renal carcinoma<sup>49</sup>

Grade	Features
Grade 1	Round uniform nuclei approximately 10 µm in diameter with very small or absent nucleoli
Grade 2	Slightly irregular nuclear contours and diameters of approximately 15 µm with nucleoli visible at ×400
Grade 3	Moderately to severely irregular nuclear contours and diameters of approximately 20 µm, with large nucleoli visible at ×100
Grade 4	Nuclei similar to grade 3 but also multilobular, multiple, or bizarre nuclei and heavy clumps of chromatin

**Figure 6** Histological classification of adult renal tumours.<sup>45</sup>

<b>Tumour</b>		
IDENTIFICATION DATA		
PATHOLOGY DATA		
Macroscopic examination		
Size of resection specimen	.....x.....x.....mm	
Location of tumour		
Adrenal identified (describe if present)	y/n	
Number of lymph nodes identified		
Maximum tumour size		
Additional tumours		
Renal vein or segmental branch involved	y/n	
Pelvicalyceal system involved	y/n	
Invasion beyond capsule	y/n	
Invasion beyond Gerota's fascia	y/n	
Excision margin tumour free	y/n/tbc	
Renal sinus	y/n/tbc	
Abnormalities in renal parenchyma		
Abnormalities in collecting system		
<b>Histology</b>		
Tumour type		
Conventional (Clear cell)	Papillary	Oncocytoma
Chromophobe	Collecting duct	Other
Fuhrman grade		
Sarcomatoid change	y/n	
Vascular invasion		
Microvascular invasion	y/n Site: Sinus; peripheral margin; renal margin	
Renal vein or segmental branches	Yes/no	
Vena cava	Yes/no	level
Invasion of	Perirenal fat	Collecting system
	Renal sinus	Gerota's fascia
Excision margin		
Lymph nodes involved	y/n/na Number examined: Number with tumour:	

**Figure 7** Specimen reporting template—radical nephrectomy for tumour.

renal pelvis tumours. Urothelial carcinoma should be graded as for bladder cancer.

## HISTOLOGICAL ASSESSMENT AND REPORTING

### Classification

The tumours should be classified by the Heidelberg/Rochester classification for renal cell carcinoma, a classification that recognises conventional (clear cell), papillary, chromophobe, oncocytoma, and collecting duct carcinomas.<sup>43 44</sup> The more extended classification of the World Health Organisation recognises the same carcinoma types but includes further

new entities.<sup>45</sup> The morphological criteria to be applied have been discussed in detail and are beyond the scope of our current article.<sup>46</sup> Other less common tumours principally recognised since the Heidelberg/Rochester conferences are diagnosed only rarely (summarised in fig 6). Immunocytochemistry may help in distinguishing difficult cases.<sup>47 48</sup> Occasionally, to aid the diagnosis, specialist genetic techniques may be required, although these would usually involve referral to a specialist centre. The Heidelberg/Rochester classification recognises that up to 5% of renal cell carcinomas may be unclassifiable.

## Grading

The tumours should be graded by morphological criteria, preferably using the Fuhrman grading system.<sup>49–50</sup> Although all grading systems in renal carcinoma have proved to be remarkably subjective, Lanigan and others found no significant difference among three different grading systems in terms of consistency of reporting. The Fuhrman grading system has much more widespread international use, and therefore allows more accurate comparison between centres for treatment or epidemiological data. Most series analysing clinical outcome against grade show only three segregated groups, and in these studies either grades 1 and 2 or grades 2 and 3 cannot be separated at the end point. This suggests that it is the upper and lower boundaries of grade 2 that are difficult for pathologists to recognise. Al Aynati and colleagues<sup>51</sup> have recently shown that applying the same morphological criteria but collapsing the grading to two grades (1 and 2 v 3 and 4) significantly improved interobserver and intraobserver variability, without loss of discrimination of outcome. However, this remains to be confirmed. Table 1 summarises the criteria of the Fuhrman grading system.

“Tumours should be graded by morphological criteria, preferably using the Fuhrman grading system”

The presence of sarcomatoid change should also be noted because this confers a significantly worse prognosis. Sarcomatoid change may be seen in any of the histological types of renal cancer, and is recognised by a loss of epithelial phenotype, tumour cells becoming spindle shaped, usually with high grade nuclei, an infiltrative border, and frequent and abnormal mitosis. It is estimated that sarcomatoid change will be found in approximately 5% of all renal carcinomas.

The pattern of infiltration of the adjacent kidney, namely infiltrative versus pushing edge, may also indicate a poor prognosis and a biologically more aggressive tumour. An infiltrative pattern is characteristically seen in collecting duct carcinoma, and in high grade renal malignancies.

## Extra renal extension

Histological evaluation of lymph nodes, and particularly the requirement for histological levels, has not been analysed. Usually, lymph node metastases are self evident on histological examination, and in the current TNM classification any evidence of infiltration of a node leads to a designation of pN1 and more than one node involved as pN2.

Confirmation of invasion of perirenal or sinus fat is, on occasion, more problematic. Tumours with a pushing edge and a fibrous pseudocapsule frequently bulge into the perirenal fat without true infiltration. One study has suggested that the diagnosis of invasion of fat should be confined to cases in which direct infiltration of the fatty tissue by tumour cells without a surrounding fibrous capsule, although occasionally with surrounding inflammatory infiltrate, is demonstrated histologically.<sup>52</sup> This remains to be confirmed by other studies.

To confirm microvascular invasion, tumour cells should be identifiable within an endothelial cell lined space.<sup>21</sup> In cases in which there is uncertainty, immunohistochemistry for epithelial markers, to confirm the nature of the tumour, or endothelial markers to confirm the endothelial lining to the space, may be helpful.

## Reporting

In addition to including patient and specimen identification data, the report should be structured in such a way as to allow accessibility of the information required for accurate

diagnosis and prognostication from the nephrectomy procedure. The use of a reporting template may be helpful in this regard (fig 7).

## ACKNOWLEDGEMENTS

The authors wish to thank Mr M Aitchison (Glasgow) and Dr M Rahilly (Fife) for helpful comments during the preparation of these guidelines. Thanks to J Sharp of Media Resources, University of Wales College of Medicine for the artwork in fig 2.

## Authors' affiliations

**S Fleming**, University of Dundee, Ninewells Hospital, Dundee DD1 9SY, UK

**D F R Griffiths**, Department of Pathology, University of Wales College of Medicine, Heath Park, Cardiff CF14 4XN, UK

## REFERENCES

- Mickisch G, Carballido J, Hellsten S, *et al*. Guidelines on renal cell cancer. *Eur Urol* 2001;**40**:252–5.
- Scottish Cancer Intelligence Unit. *Trends in cancer survival 1971–1995*. 2000. Edinburgh: Information and Statistics Division.
- Jocham D, Richter A, Hoffmann L, *et al*. Adjuvant autologous renal tumour cell vaccine and risk of tumour progression in patients with renal-cell carcinoma after radical nephrectomy: phase III, randomised controlled trial. *Lancet* 2004;**363**:594–9.
- Robson CJ, Churchill BM, Anderson W. The results of radical nephrectomy for renal cell carcinoma. *Trans Am Assoc Genitourin Surg* 1968;**60**:122–9.
- Robson CJ. Staging of renal cell carcinoma. *Prog Clin Biol Res* 1982;**100**:439–45.
- Fiori E, De Cesare A, Galati G, *et al*. Prognostic significance of primary-tumor extension, stage and grade of nuclear differentiation in patients with renal cell carcinoma. *J Exp Clin Cancer Res* 2002;**21**:229–32.
- Lau WK, Cheville JC, Blute ML, *et al*. Prognostic features of pathologic stage T1 renal cell carcinoma after radical nephrectomy. *Urology* 2002;**59**:532–7.
- Frank I, Blute ML, Cheville JC, *et al*. An outcome prediction model for patients with clear cell renal cell carcinoma treated with radical nephrectomy based on tumor stage, size, grade and necrosis: the SSIGN score. *J Urol* 2002;**168**:2395–400.
- Sobin LH, Wittekind Ch. Urological tumours. In: Sobin LH, Wittekind C. *TNM classification of malignant tumours*. Geneva: UICC, 2002:179–206.
- Kanomata N. Impact of tumor size on the clinical outcomes of patients with Robson stage I renal cell carcinoma. *Cancer* 1999;**86**:545–6.
- Delahunt B, Kittelson JM, McCredie MR, *et al*. Prognostic importance of tumor size for localized conventional (clear cell) renal cell carcinoma: assessment of TNM T1 and T2 tumor categories and comparison with other prognostic parameters. *Cancer* 2002;**94**:658–64.
- Yaycioglu O, Rutman MP, Balasubramaniam M, *et al*. Clinical and pathologic tumor size in renal cell carcinoma; difference, correlation, and analysis of the influencing factors. *Urology* 2002;**60**:33–8.
- Frank I, Blute ML, Cheville JC, *et al*. Solid renal tumors: an analysis of pathological features related to tumor size. *J Urol* 2003;**170**:2217–20.
- Cheville JC, Zincke H, Lohse CM, *et al*. pT1 clear cell renal cell carcinoma: a study of the association between MIB-1 proliferative activity and pathologic features and cancer specific survival. *Cancer* 2002;**94**:2180–4.
- Zisman A, Pantuck AJ, Chao D, *et al*. Reevaluation of the 1997 TNM classification for renal cell carcinoma: T1 and T2 cutoff point at 4.5 rather than 7 cm better correlates with clinical outcome. *J Urol* 2001;**166**:54–8.
- Igarashi T, Tobe T, Nakatsu HO, *et al*. The impact of a 4 cm cutoff point for stratification of T1N0M0 renal cell carcinoma after radical nephrectomy. *J Urol* 2001;**165**:1103–6.
- Robson CJ, Churchill BM, Anderson W. The results of radical nephrectomy for renal cell carcinoma. *J Urol* 1969;**101**:297–301.
- Bonsib SM, Gibson D, Mhoon M, *et al*. Renal sinus involvement in renal cell carcinomas. *Am J Surg Pathol* 2000;**24**:451–8.
- Moinzadeh A, Libertino JA. Prognostic significance of tumor thrombus level in patients with renal cell carcinoma and venous tumor extension. Is all T3b the same? *J Urol* 2004;**171**:598–601.
- Kim HL, Zisman A, Han KR, *et al*. Prognostic significance of venous thrombus in renal cell carcinoma. Are renal vein and inferior vena cava involvement different? *J Urol* 2004;**171**:588–91.
- Van Poppel H, Vandendriessche H, Boel K, *et al*. Microscopic vascular invasion is the most relevant prognosticator after radical nephrectomy for clinically nonmetastatic renal cell carcinoma. *J Urol* 1997;**158**:45–9.
- Griffiths DF, Verghese A, Golash A, *et al*. Contribution of grade, vascular invasion and age to outcome in clinically localized renal cell carcinoma. *BJU Int* 2002;**90**:26–31.
- Palapattu GS, Pantuck AJ, Dorey F, *et al*. Collecting system invasion in renal cell carcinoma: impact on prognosis and future staging strategies. *J Urol* 2003;**170**:768–72.
- Hermanek P, Schrott KM. Evaluation of the new tumor, nodes and metastases classification of renal cell carcinoma. *J Urol* 1990;**144**:238–41.
- Giberti C, Oneto F, Martorana G, *et al*. Radical nephrectomy for renal cell carcinoma: long-term results and prognostic factors on a series of 328 cases. *Eur Urol* 1997;**31**:40–8.

- 26 **Zisman A**, Pantuck AJ, Belldegrun A. Lymph node dissection. In: Belldegrun A, Ritchie AWS, *et al*, eds. *Renal and adrenal tumors*. Oxford: Oxford University Press, 2003:318–23.
- 27 **Blom JH**, Van Poppel H, Marechal JM, *et al*. Radical nephrectomy with and without lymph node dissection: preliminary results of the EORTC randomized phase III protocol 30881. EORTC genitourinary group. *Eur Urol* 1999;**36**:570–5.
- 28 **Mickisch GH**, Garin A, Van Poppel H, *et al*. Radical nephrectomy plus interferon- $\alpha$ -based immunotherapy compared with interferon  $\alpha$  alone in metastatic renal-cell carcinoma: a randomised trial. *Lancet* 2001;**358**:966–70.
- 29 **Terrone C**, Guercio S, De Luca S, *et al*. The number of lymph nodes examined and staging accuracy in renal cell carcinoma. *BJU Int* 2003;**91**:37–40.
- 30 **Flanigan RC**, Mickisch G, Sylvester R, *et al*. Cytoreductive nephrectomy in patients with metastatic renal cancer: a combined analysis. *J Urol* 2004;**171**:1071–6.
- 31 **Ansell ID**. *Minimum dataset for adult renal tumour histopathology reports*. London: Royal College of Pathologists, 2000.
- 32 **Griffiths DF**, Nind N, O'Brien CJ, *et al*. Evaluation of a protocol for examining nephrectomy specimens with renal cell carcinoma. *J Clin Pathol* 2003;**56**:374–7.
- 33 **Govender D**. The pathology of nephroblastoma. *Curr Diagn Pathol* 2000;**6**:45–54.
- 34 **Zuppan CW**. Handling and evaluation of pediatric renal tumors. *Am J Clin Pathol* 1998;**109**:S31–7.
- 35 **Eble JN**. Recommendations for examining and reporting tumor-bearing kidney specimens from adults. *Semin Diagn Pathol* 1998;**15**:77–82.
- 36 **Derweesh IH**, Novick AC. Nephron-sparing surgery for renal cell carcinoma. *Cancer Treat Res* 2003;**116**:93–7.
- 37 **Uzzo RG**, Novick AC. Nephron sparing surgery for renal tumors: indications, techniques and outcomes. *J Urol* 2001;**166**:6–18.
- 38 **Ghavamian R**, Zincke H. Nephron sparing surgery. In: Belldegrun A, Ritchie AWS, Figlin R, *et al*, eds. *Renal and adrenal tumors*. Oxford: Oxford University Press, 2003:309–17.
- 39 **Castilla EA**, Liou LS, Abrahams NA, *et al*. Prognostic importance of resection margin width after nephron-sparing surgery for renal cell carcinoma. *Urology* 2002;**60**:993–7.
- 40 **Krejić KG**, Blute ML, Cheville JC, *et al*. Nephron-sparing surgery for renal cell carcinoma: clinicopathologic features predictive of patient outcome. *Urology* 2003;**62**:641–6.
- 41 **Piper NY**, Bishoff JT, Magee C, *et al*. Is a 1-CM margin necessary during nephron-sparing surgery for renal cell carcinoma? *Urology* 2001;**58**:849–52.
- 42 **McHale T**, Malkowicz SB, Tomaszewski JE, *et al*. Potential pitfalls in the frozen section evaluation of parenchymal margins in nephron-sparing surgery. *Am J Clin Pathol* 2002;**118**:903–10.
- 43 **Kovacs G**, Akhtar M, Beckwith BJ, *et al*. The Heidelberg classification of renal cell tumours [editorial]. *J Pathol* 1997;**183**:131–3.
- 44 **Storkel S**, Eble JN, Adlakha K, *et al*. Classification of renal cell carcinoma: workgroup no. 1. Union Internationale Contre le Cancer (UICC) and the American Joint Committee on Cancer (AJCC). *Cancer* 1997;**80**:987–9.
- 45 **Eble JN**, Sauter G, Epstein JI, *et al*. *Tumours of the urinary system and male genital organs*. Lyon: IARC Press, 2004.
- 46 **Fleming S**, O'Donnell M. Surgical pathology of renal epithelial neoplasms: recent advances and current status. *Histopathology* 2000;**36**:195–202.
- 47 **Leroy X**, Moukassa D, Copin MC, *et al*. Utility of cytokeratin 7 for distinguishing chromophobe renal cell carcinoma from renal oncocytoma. *Eur Urol* 2000;**37**:484–7.
- 48 **Mathers ME**, Pollock AM, Marsh C, *et al*. Cytokeratin 7: a useful adjunct in the diagnosis of chromophobe renal cell carcinoma. *Histopathology* 2002;**40**:563–7.
- 49 **Fuhrman SA**, Lasky LC, Limas C. Prognostic significance of morphologic parameters in renal cell carcinoma. *Am J Surg Pathol* 1982;**6**:655–63.
- 50 **True LD**. The time for accurate Fuhrman grading of renal cell carcinomas has arrived. *Am J Clin Pathol* 2002;**118**:827–9.
- 51 **Al Aynati M**, Chen V, Salama S, *et al*. Interobserver and intraobserver variability using the Fuhrman grading system for renal cell carcinoma. *Arch Pathol Lab Med* 2003;**127**:593–6.
- 52 **Thomas DH**, Verghese A, Kynaston HG, *et al*. Analysis of the prognostic implications of different tumour margin types in renal cell carcinoma. *Histopathology* 2003;**43**:374–80.



## **Best Practice No 180 Nephrectomy for renal tumour; dissection guide and dataset**

S Fleming and D F R Griffiths

*J Clin Pathol* 2005 58: 7-14

doi: 10.1136/jcp.2003.014159

---

Updated information and services can be found at:

<http://jcp.bmj.com/content/58/1/7.full.html>

---

### **References**

*These include:*

This article cites 45 articles, 3 of which can be accessed free at:

<http://jcp.bmj.com/content/58/1/7.full.html#ref-list-1>

Article cited in:

<http://jcp.bmj.com/content/58/1/7.full.html#related-urls>

### **Email alerting service**

Receive free email alerts when new articles cite this article. Sign up in the box at the top right corner of the online article.

---

### **Notes**

---

To request permissions go to:

<http://group.bmj.com/group/rights-licensing/permissions>

To order reprints go to:

<http://journals.bmj.com/cgi/reprintform>

To subscribe to BMJ go to:

<http://group.bmj.com/subscribe/>