

CASE REPORT

Mediastinal hibernoma: a case report

A Baldi, M Santini, P Mellone, V Esposito, A M Groeger, M Caputi, F Baldi

J Clin Pathol 2004;57:993–994. doi: 10.1136/jcp.2004.017897

Hibernomas are rare benign tumours that arise most often in adults from the remnants of fetal brown adipose tissue. They usually affect muscle and subcutaneous tissue and are asymptomatic and slow growing. The distribution of this tumour follows the sites of persistence of brown fat. Out of more than 100 cases described in the word literature only three hibernomas were mediastinal. A recent clinicopathological study of 170 cases from the Armed Forces Institute of Pathology confirmed the exceptionality of the intrathoracic location. This report describes a very rare case of mediastinal hibernoma in a young man.

A 25 year old man was referred to the thoracic surgery department of the Second University of Naples (Italy) because of a left mediastinal mass, which was discovered on a routine pre-employment physical examination. The patient was completely asymptomatic. Physical examination and laboratory tests were non-contributory. A chest roentgenogram showed considerable enlargement of the mediastinum, involving particularly the left side of the chest (fig 1A). Computed tomography showed a mixed density voluminous mass with well defined edges and non-homogeneous density, involving predominantly the left part

of the mediastinum (fig 1B). A thoracotomy was performed. A large, tan, lobulated, and encapsulated mass was found in the left mediastinum and was removed completely.

The excised tumour specimen was fixed in 10% buffered formalin and paraffin wax embedded. Sections of 5 μ m thickness were stained with haematoxylin and eosin, haematoxylin–van Gieson, and periodic acid Schiff–haematoxylin. Other sections were immunohistochemically stained using the standard avidin–biotin peroxidase complex method with S-100 antibody (Dako Corporation, Glostrup, Denmark). Diaminobenzidine was used as final chromogen and haematoxylin as nuclear counterstain. Negative controls were obtained by omitting the primary antibodies.

Light microscopic examination revealed a tumour divided into numerous lobules by well vascularised connective tissue (fig 2A). The tumour cells were round or polygonal, multivacuolated with centrally placed nuclei resembling lipoblasts. Immunohistochemically, the cytoplasm of these cells was stained for S-100 protein (fig 2B). Univacuolated cells with eccentrically placed nuclei resembling mature lipocytes were also present. A delicate fibrocollagenous and vascular capsule was present.

These macroscopic and microscopic findings were suggestive of a mediastinal hibernoma. The patient made an uneventful recovery and after a five year follow up period there has been no recurrence.

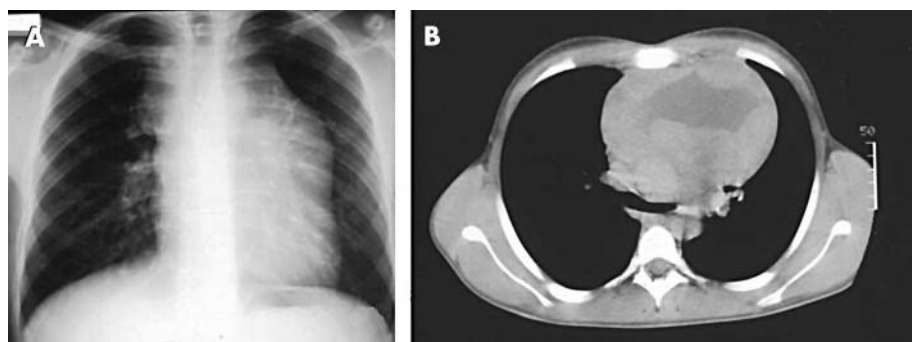


Figure 1 (A) An x ray shows an enlargement of the mediastinum involving particularly the left side of the chest. (B) A chest computed tomography scan shows a voluminous mass with well defined edges and non-homogeneous density, involving predominantly the left part of mediastinum.

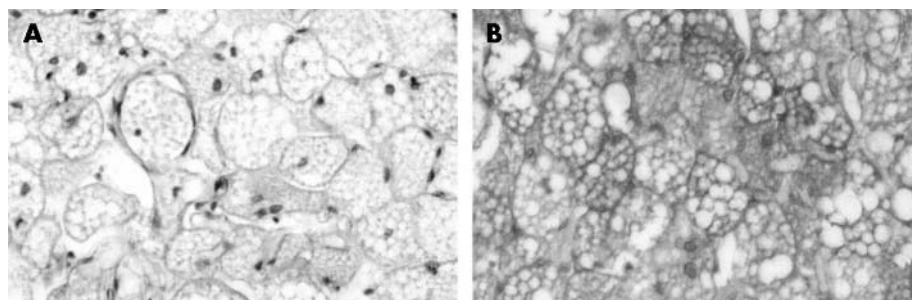


Figure 2 (A) Light microscopic examination reveals a tumour divided into numerous lobules by well vascularised connective tissue. The tumour cells are round or polygonal, multivacuolated with centrally placed nuclei resembling lipoblasts (haematoxylin and eosin stain; original magnification, $\times 40$). (B) The cytoplasm of the tumour cells is stained for S-100 protein (avidin–biotin complex stain; original magnification, $\times 40$).

Table 1 Clinical features of reported mediastinal hibernomas

Author	Age (years)	Sex	Symptoms	Tumour location
Ahn and Harvey ²	16	Male	Asymptomatic	Left anterior mediastinum
Santambrogio and colleagues ³	33	Female	Asymptomatic	Cervicomediastinal
Udwadia and colleagues ⁴	46	Male	Asymptomatic	Left posterior mediastinum
Baldi <i>et al</i> (case presented)	28	Male	Asymptomatic	Left posterior mediastinum

Take home messages

- Hibernomas are rare, asymptomatic, benign tumours that arise mostly in adults from the remnants of fetal brown adipose tissue, and usually affect muscle and subcutaneous tissue
- We describe only the fourth case of mediastinal hibernoma to be reported in the world literature
- We suggest that mediastinal hibernomas should be included among the differential diagnosis in every growing mass of the thorax, especially if the detection of the tumour is a fortuitous coincidence in an asymptomatic patient

DISCUSSION

Hibernoma is an unusual benign soft tissue tumour derived from a specialised form of brown fat.¹ In the adult, brown fat is usually found in scattered foci as persisting vestigial remnants along the oesophagus, trachea, posterior neck, and interscapular area, and around the great vessels of the mediastinum.²⁻⁵ Hence, hibernomas are usually seen at one of these sites, even though unusual sites have also been reported.⁵ These tumours occur mostly in the third or fourth decade of life with no predominance of sex distribution.

“Because the routine use of chest x rays is increasing, most of these tumours will be detected as asymptomatic opacities, as in the case described here”

Hibernomas have computed tomography and magnetic resonance imaging appearances similar to other fibrous and lipomatous tumours; therefore, histopathological analysis is always necessary for a correct diagnosis.⁶ Because the routine use of chest x rays is increasing, most of these tumours will be detected as asymptomatic opacities, as in the case described here. Although these tumours are always benign, they tend to grow to large sizes, sometimes causing compression of the neighboring structures, so that surgical excision is always recommended.

A review of the world literature brings the total number of reported cases of mediastinal hibernomas, including the one described here, to four.²⁻⁴ The clinical features of these neoplasms are reported in table 1. All of these patients underwent successful thoracotomy and resection of tumour with no evidence of recurrence.

We suggest that mediastinal hibernomas should be included among the differential diagnosis in every growing mass of the thorax, especially if the detection of the tumour is a fortuitous coincidence in an asymptomatic patient.

ACKNOWLEDGEMENTS

This work was supported by FUTURA-Onlus and ISSCO.

Authors' affiliations

A Baldi, P Mellone, F Baldi, Department of Biochemistry and Biophysic “F. Cedrangolo”, Section of Pathology, Second University of Naples, Naples 80128, Italy

M Santini, Department of Thoracic Surgery, Second University of Naples
V Esposito, Third Division of Infective Diseases, D. Cotugno Hospital, Naples 80100, Italy

A M Groeger, Department of Cardio-Thoracic Surgery, University of Vienna, Vienna 00100, Austria

M Caputi, Department of Cardiological, Respiratory and Thoracic Medical Sciences, Second University of Naples

Correspondence to: Dr A Baldi, Department of Biochemistry and Biophysic “F. Cedrangolo”, Section of Pathology, Second University of Naples, Via G. Orsi 25, 80128 Naples, Italy; alfonsobaldi@tiscali.it

Accepted for publication 8 April 2004

REFERENCES

- 1 **Dardick I**. Hibernoma, a possible model of brown fat histogenesis. *Hum Pathol* 1978;**5**:321-9.
- 2 **Ahn C, Harvey JC**. Mediastinal hibernoma, a rare tumor. *Ann Thorac Surg* 1990;**50**:828-30.
- 3 **Santambrogio L, Cioffi U, De Simone M, et al**. Cervicomediastinal hibernoma. *Ann Thorac Surg* 1997;**64**:1160-2.
- 4 **Udwadia ZF, Kumar N, Bhaduri AS**. Mediastinal hibernoma. *Eur J Cardiothorac Surg* 1999;**15**:533-5.
- 5 **Furlong MA, Fanburg-Smith JC, Miettinen M**. The morphologic spectrum of hibernoma. *Am J Surg Pathol* 25:809-14.
- 6 **Mugel T, Ghossain MA, Guinnet C, et al**. MR and CT findings in a case of hibernoma of the thigh extending to the pelvis. *Eur Radiol* 1998;**8**:476-8.



Mediastinal hibernoma: a case report

A Baldi, M Santini, P Mellone, et al.

J Clin Pathol 2004 57: 993-994

doi: 10.1136/jcp.2004.017897

Updated information and services can be found at:

<http://jcp.bmj.com/content/57/9/993.full.html>

These include:

References

This article cites 4 articles, 2 of which can be accessed free at:

<http://jcp.bmj.com/content/57/9/993.full.html#ref-list-1>

Article cited in:

<http://jcp.bmj.com/content/57/9/993.full.html#related-urls>

Email alerting service

Receive free email alerts when new articles cite this article. Sign up in the box at the top right corner of the online article.

Notes

To request permissions go to:

<http://group.bmj.com/group/rights-licensing/permissions>

To order reprints go to:

<http://journals.bmj.com/cgi/reprintform>

To subscribe to BMJ go to:

<http://group.bmj.com/subscribe/>