

SHORT REPORT

A primary amelanotic melanoma of the vagina, diagnosed by immunohistochemical staining with HMB-45, which recurred as a pigmented melanoma

H Oguri, C Izumiya, N Maeda, T Fukaya, T Moriki

J Clin Pathol 2004;57:986-988. doi: 10.1136/jcp.2004.016220

Usually, malignant melanoma is readily diagnosed by the presence of melanin granules. Although amelanotic melanoma contains a few melanin granules, it is often difficult to differentiate from non-epithelial malignant tumours. This report describes a case of amelanotic melanoma of the vagina, which was originally suspected to be a non-epithelial malignant tumour, but was subsequently correctly diagnosed by immunohistochemical staining with the HMB-45 antibody and for the S-100 protein. A light grey tumour with superficial ulceration was located in the upper third of the vagina. The patient was treated with irradiation followed by chemotherapy. Subsequently, the tumour disappeared and cytology was negative; thus, she achieved complete remission. However, 20 months after complete remission, the tumour recurred locally: the site had a grossly black appearance, which was pathognomonic for a malignant melanoma. Thus, HMB-45 and S-100 protein immunohistochemistry confirmed the diagnosis of amelanotic melanoma.

Primary malignant melanoma of the vagina is extremely rare.¹ Less than 250 cases have been reported. The diagnosis of malignant melanoma is readily made if melanin pigment is present. A small but important group of coetaneous melanomas can be classified as unusual variants. Many of these unusual variants have a distinct histopathological appearance; they include desmoplastic melanomas, neurotropic melanomas, pedunculated melanomas, metastatic melanomas, amelanotic melanomas, melanomas arising within a benign naevus, regressing melanomas, and balloon cell melanomas.² One large retrospective study reported that 50 (1.8%) of 2881 patients with melanoma had an amelanotic primary or metastatic melanoma.³ Amelanotic melanomas can be misdiagnosed as carcinomas or sarcomas because of the minimal number of melanin granules. Recently, an immunohistochemical technique incorporating the use of the HMB-45 monoclonal antibody has improved the accuracy of diagnosing malignant melanomas.^{2,4}

“Amelanotic melanomas can be misdiagnosed as carcinomas or sarcomas because of the minimal number of melanin granules”

We present a case of amelanotic melanoma of the vagina, which was initially suspected to be a non-epithelial malignant tumour, but was subsequently correctly diagnosed by HMB-45 and S-100 protein immunohistochemistry. Despite intensive treatment, the patient experienced a local

recurrence 20 months after achieving complete remission (CR). The site of recurrence was grossly black, and was an obvious malignant melanoma. Specifically, this is a case of amelanotic melanoma of the vagina, which was diagnosed by HMB-45 and S-100 protein immunohistochemistry; it recurred as a pigmented melanoma.

CASE REPORT

A 53 year old (gravida 5, para 3) Japanese woman was referred to our hospital on 25 December 2000. Her main complaint was a yellowish discharge and vaginal bleeding. On vaginal examination, we found a light grey tumour with superficial ulceration, involving the upper third of the anterior vaginal wall. The tumour did not involve the cervix.

Magnetic resonance imaging of the pelvis was performed. A mass in the anterior vaginal wall, 35 × 18 × 35 mm in size, was found on T1 weighted imaging. Subsequent studies revealed no distant metastases or infiltration to the urethra, urinary bladder, or rectum.

Cytological examination of vaginal mucosa scrapings was performed. Loose aggregates of large pleomorphic tumour cells with granular hyperchromatic nuclei and the occasional conspicuous nucleolus were observed (fig 1); many multinucleated tumour cells and occasional mitoses were also seen. The tumour cells were polygonal and spindle shaped, with ill defined, lacy cytoplasmic borders. These cytological findings suggested a non-epithelial malignant tumour of the vagina.

Histological examination of the biopsy specimen revealed a diffuse infiltration of large pleomorphic and spindle shaped tumour cells in the vaginal mucosa (fig 2). The tumour cells had large oval or pleomorphic hyperchromatic nuclei and eosinophilic cytoplasm. Most of the cells had multiple nuclei with distinct nucleoli. Immunohistochemical analysis revealed that the tumour cells were positive with the HMB-45 antibody and were also positive for the S-100 protein and vimentin. They were negative for cytokeratin, epithelial membrane antigen, desmin, myoglobin, α smooth muscle actin, CD34, and CD68. Although the tumour cells were negative with Fontana-Masson silver staining for melanin pigment, some of the cells reacted positively with HMB-45 (fig 3). These findings supported the diagnosis of an amelanotic melanoma.

The patient was treated with external and intracavitary irradiation. The total dose administered to the tumour was 64 Gy. After irradiation, chemotherapy was instituted, consisting of four cycles every five weeks of cisplatin 80 mg/m² (intravenous (iv), day 1), dacarbazine 140 mg/m² (iv, days 2-6), and vindesine sulfate 2 mg/m² (iv, day 2). After four courses of chemotherapy, no residual tumour could be

Abbreviations: CR, complete remission; iv, intravenous

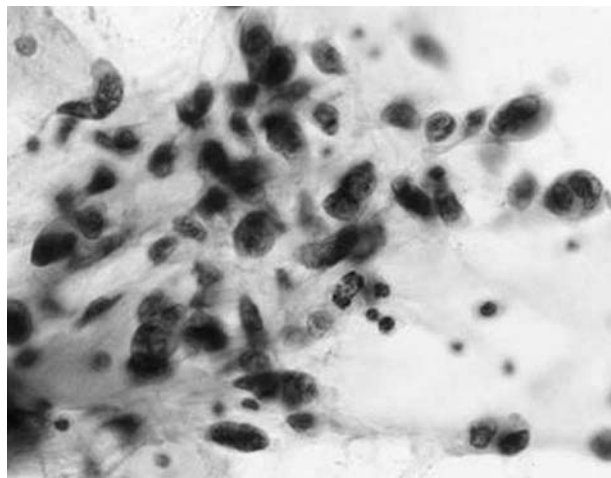


Figure 1 Cytological specimen from the vaginal mucosa demonstrating loose aggregates of pleomorphic tumour cells. The tumour cells had relatively abundant lacy cytoplasm and granular hyperchromatic large nuclei, with occasional prominent nucleoli (original magnification, $\times 40$; Papanicolaou stain).

detected by magnetic resonance imaging, and cytological and histological examination revealed no evidence of malignancy. Thus, the patient achieved CR with this treatment. To prevent recurrence, four cycles of the same chemotherapy regimen were performed every four months after CR. However, a local recurrence was found 20 months after achieving CR. The recurrence had a grossly black appearance, which was pathognomonic for a malignant melanoma. Malignant melanoma containing many melanin granules was confirmed by histopathological studies of the biopsied specimen.

DISCUSSION

Primary malignant melanoma of the vagina is extremely rare. It accounts for less than 10% of female genital tract melanomas, and just 4% of all vaginal malignancies.¹ Primary vaginal melanoma is less frequent than other melanomas of the female genital tract in both Europe and America.¹⁻⁵ In contrast, Ikegaya *et al* reported that approximately 52% of female genital tract melanomas in Japan are primary vaginal melanomas.⁶ These differences in incidence seem to be caused by race.

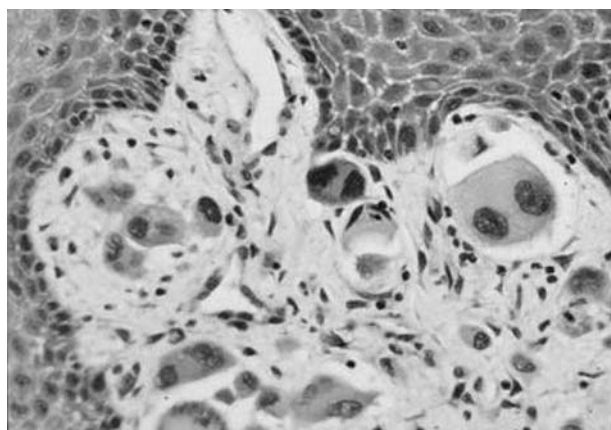


Figure 2 Biopsied specimen from the vaginal tumour demonstrating diffuse infiltration of large pleomorphic or spindle shaped tumour cells. The tumour cells have large oval or pleomorphic hyperchromatic nuclei and eosinophilic cytoplasm (original magnification, $\times 40$; haematoxylin and eosin stain).

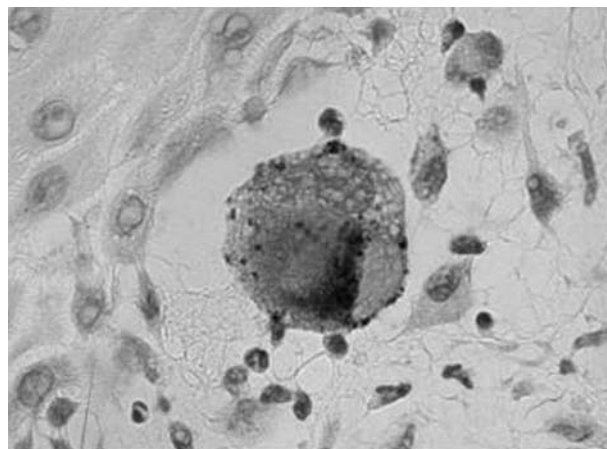


Figure 3 Immunohistochemical staining with HMB-45 in the vaginal tumour tissue. Note the positive staining in the cytoplasm of the tumour cell (original magnification, $\times 100$).

Vaginal melanomas are usually pigmented; in a recent review, less than 10% were found to lack pigmentation.⁷ In Japan, approximately 15% of vaginal melanomas have been reported as amelanotic,⁵ so that amelanotic melanoma of the vagina is extremely rare across different races.

“The HMB-45 antibody stains a 10 kDa cytoplasmic glycoprotein thought to be part of the premelanosome complex”

The diagnosis of malignant melanoma is readily made if melanin pigment is present. More than 90% of primary vaginal cancers are epithelial neoplasms, and squamous cell carcinoma is the most common type. Malignant melanoma usually presents as a black or brown lesion. It is readily diagnosed by conventional histochemical staining; however, amelanotic melanoma, which is a unique variant of malignant melanoma, can be misdiagnosed as a carcinoma or sarcoma because of the lack of pigmentation. It has been recently reported that immunohistochemical staining with HMB-45 is useful for the cytological and histological diagnosis of amelanotic melanoma.^{8,9} The HMB-45 antibody stains a 10 kDa cytoplasmic glycoprotein thought to be part of the premelanosome complex.⁴ HMB-45 can be important in the evaluation of undifferentiated neoplastic lesions that are suspected to be melanomas.²

In our case, the tumour was unpigmented, and melanin granules were not demonstrated by either conventional histochemical staining or Fontana-Masson silver staining. Because of these findings, we initially suspected a non-epithelial malignant tumour. Subsequently, immunohistochemical staining for several different antigens was performed.

Take home messages

- We present a rare case of amelanotic melanoma of the vagina, originally suspected to be a non-epithelial malignant tumour, but subsequently correctly diagnosed by HMB-45 and S-100 protein immunohistochemistry
- The tumour recurred locally as a malignant melanoma, confirming that HMB-45 and S-100 protein immunohistochemistry are useful for the diagnosis of amelanotic melanoma

Immunohistochemical staining with HMB-45 demonstrated melanin granules in a few tumour cells; thus, this case was ultimately diagnosed as an amelanotic melanoma.

The patient subsequently experienced a recurrence, and the lesion was an obvious pigmented malignant melanoma, proving that the previous diagnosis of amelanotic melanoma was correct. We reconfirmed the usefulness of immunohistochemical staining with HMB-45 and S-100 protein for the diagnosis of amelanotic melanoma.

Authors' affiliations

H Oguri, C Izumiya, N Maeda, T Fukaya, Department of Aging and Reproductive Medicine, Kochi Medical School, Kohasu, Oko, Nankoku, Kochi, Japan 783-8505

T Moriki, Department of Clinical Laboratory, Kochi Medical School

Correspondence to: H Oguri, Department of Aging and Reproductive Medicine, Kochi Medical School, Okocho, Nankoku, Kochi, Japan 783-8505; ogurih1966@yahoo.co.jp

Accepted for publication 19 March 2004

REFERENCES

- 1 **Creasman WT**, Phillips JL, Menck HR. The National Cancer Data Base report on cancer of the vagina. *Cancer* 1998;**83**:1033-40.
- 2 **Pernicaro C**. Dermatopathologic variants of malignant melanoma. *Mayo Clin Proc* 1997;**72**:273-9.
- 3 **Giuliano AE**, Cochran AJ, Morton DL. Melanoma from unknown primary site and amelanotic melanoma. *Semin Oncol* 1982;**9**:442-7.
- 4 **Scambia G**, Benedetti Panici P, Baiocchi G, *et al*. A primary amelanotic melanoma of the vagina diagnosed by immunocytochemistry. *Int J Gynaecol Obstet* 1989;**29**:159-64.
- 5 **Ragnarsson-Olding B**, Johansson H, Rutqvist LE, *et al*. Malignant melanoma of the vulva and vagina. Trends in incidence, age distribution, and long-term survival among 245 consecutive cases in Sweden 1960-1984. *Cancer* 1993;**71**:1893-7.
- 6 **Ikegaya H**, Iwasaki T, Matsuda I, *et al*. Primary amelanotic malignant melanoma of the vagina—a case report [in Japanese]. *Gan No Rinsho* 1987;**33**:1515-23.
- 7 **Piura B**, Rabinovich A, Yanai-Inbar I. Primary malignant melanoma of the vagina: case report and review of literature. *Eur J Gynaecol Oncol* 2002;**23**:195-8.
- 8 **Takehara M**, Ito E, Saito T, *et al*. HMB-45 staining for cytology of primary melanoma of the vagina. A case report. *Acta Cytol* 2000;**44**:1077-80.
- 9 **Saito T**, Takehara M, Tanaka R, *et al*. Usefulness of silver intensification of immunostaining for cytologic diagnosis of primary melanoma of the female genital organs. *Acta Cytol* 2002;**46**:1075-80, .



A primary amelanotic melanoma of the vagina, diagnosed by immunohistochemical staining with HMB-45, which recurred as a pigmented melanoma

H Oguri, C Izumiya, N Maeda, et al.

J Clin Pathol 2004 57: 986-988
doi: 10.1136/jcp.2004.016220

Updated information and services can be found at:
<http://jcp.bmj.com/content/57/9/986.full.html>

	<i>These include:</i>
References	This article cites 9 articles, 1 of which can be accessed free at: http://jcp.bmj.com/content/57/9/986.full.html#ref-list-1
	Article cited in: http://jcp.bmj.com/content/57/9/986.full.html#related-urls
Email alerting service	Receive free email alerts when new articles cite this article. Sign up in the box at the top right corner of the online article.

Topic Collections	Articles on similar topics can be found in the following collections Cancer: dermatological (87 articles) Dermatology (185 articles)
--------------------------	--

Notes

To request permissions go to:
<http://group.bmj.com/group/rights-licensing/permissions>

To order reprints go to:
<http://journals.bmj.com/cgi/reprintform>

To subscribe to BMJ go to:
<http://group.bmj.com/subscribe/>