

# PostScript

## CORRESPONDENCE

If you have a burning desire to respond to a paper published in the *Journal of Clinical Pathology*, why not make use of our "rapid response" option?

Log on to our website ([www.jclinpath.com](http://www.jclinpath.com)), find the paper that interests you, and send your response via email by clicking on the "eLetters" option in the box at the top right hand corner.

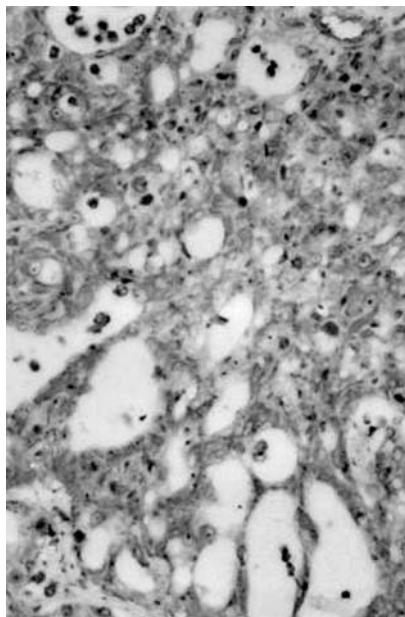
Providing it isn't libellous or obscene, it will be posted within seven days. You can retrieve it by clicking on "read eletters" on our homepage.

The editors will decide as before whether to also publish it in a future paper issue.

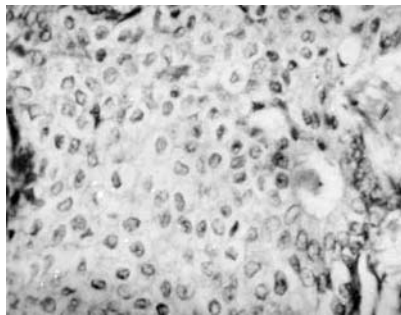
### Secretory carcinoma of the male breast

Breast carcinomas in men account for < 1% of all subtypes and most belong to the infiltrating duct variety of the "not otherwise specified" type.<sup>1</sup> To date, only 15 cases of the rare subtype of secretory carcinoma have been reported in men.<sup>2</sup> The youngest patient was a 6 year old boy<sup>3</sup> and oldest a 66 year old man.<sup>4</sup> We present a case of secretory carcinoma in a 19 year old man whose tumour cells were vimentin positive and oestrogen and progesterone receptor negative.

The patient presented to a private clinic in rural Northern India with a painful, rapidly progressing lump in the right breast of two



**Figure 1** Low power view of tumour cells arranged in a microcystic pattern.



**Figure 2** High power view of polygonal tumour cells with abundant pale to clear cytoplasm and focal intraluminal secretions.

years duration. A lumpectomy was performed at a local hospital. Three months after surgery, two small lumps reappeared on the right chest wall, which were excised and sent to our hospital for histopathology. Two nodules measuring 4 × 2 × 2 cm and 2 × 2 × 2 cm were received. Cut sections were greyish yellow and densely fibrous.

Microsections showed an infiltrating tumour with tumour cells arranged in microcystic and cribriform patterns separated by scant fibroconnective stroma (fig 1). The tumour cells were round to polygonal with abundant pale to clear amphophilic cytoplasm. The nuclei were large and central with stippled chromatin (fig 2). Pink amphophilic secretions were seen in the lumina of microcysts (fig 2) and focally within the cells. The intracellular and extracellular secretions were periodic acid Schiff (diastase resistant) and mucicarmine positive. Immunohistochemistry for the oestrogen receptor (ER ID5; Immunotech, Marseille, France), progesterone receptor (PR 105; Immunotech), and vimentin (Dako, Glostrup, Denmark) was performed. The tumour cells were universally oestrogen receptor and progesterone receptor negative, but were vimentin positive (100% positivity).

Mc Diwitt and Stewart first described breast tumours in children with a favourable prognosis (1966) and named them juvenile carcinomas.<sup>3</sup> This was later replaced by the term secretory carcinoma by Tavassoli.<sup>3</sup> De Bree *et al* have recently reviewed secretory carcinoma in men and reported a median age of 17 years, with the tumour size ranging from 1.2 to 4 cm.<sup>2</sup> They also noticed that lymph node metastases were frequent in tumours less than 2 cm, unlike secretory carcinomas in women. Hence, secretory carcinomas in men appear to be more aggressive.<sup>2</sup> The tumour in our patient was also an aggressive one because an early recurrence was seen.

Very few authors have performed immunohistochemical studies on secretory carcinomas of male breasts.<sup>3</sup> These tumours are said to be epithelial membrane antigen, cytokeratin, carcinoembryonic antigen (polyclonal), S-100, and  $\alpha$  lactalbumin positive.

Although traditionally vimentin expression has been associated with mesenchyme and mesenchymal tumours, many epithelial

malignancies are vimentin positive, including those of the breast.<sup>6</sup> Vimentin expression has been studied extensively in female breast tumours (predominantly in infiltrating ductal carcinomas) and is associated with biological aggressiveness.<sup>6</sup> The role of vimentin positivity in male breast carcinomas needs to be explored. It is unclear whether vimentin positivity in our case is related to the aggressiveness of the tumour and larger studies are needed to investigate this possibility.

S R Niveditha, P Bajaj, A Nangia

Department of Pathology, Lady Hardinge Medical College, Smt. Sucheta Kriplani and Kalawati Saran Hospitals, New Delhi 110 001, India; [snriveditha@hotmail.com](mailto:snriveditha@hotmail.com)

### References

- 1 Rosen PP. Breast lesions in men and children. In: Rosen PP, ed. *Breast pathology—diagnosis by needle core biopsy*. Philadelphia: Lippincott Williams and Wilkins, 1999:263–6.
- 2 De Bree E, Askoxyklakis J, Giannikaki E, *et al*. Secretory carcinoma of the male breast. *Ann Surg Oncol* 2002;**9**:663–7.
- 3 Rosen PP. Secretory carcinoma. In: Rosen PP, ed. *Breast pathology—diagnosis by needle core biopsy*. Lippincott Williams and Wilkins, 1999:183–4.
- 4 Kervabera H, Yamana M, Okoda S. Secretory carcinoma in a 66 year old man. *J Clin Pathol* 1998;**57**:545–7.
- 5 Tavassoli FA. Infiltrating carcinoma, special types. In: Tavassoli FA, ed. *Pathology of the breast*. New York: Elsevier Science, 1992:384–8.
- 6 Santini D, Ceccarelli C, Taffurelli M, *et al*. Differentiation pathways in primary invasive breast carcinoma as suggested by intermediate filament and biopathological marker expression. *J Pathol* 1996;**179**:386–91.

### Gastric intestinal metaplasia

We read with interest the article by Dinis-Ribeiro *et al* concerning a follow up model for patients with atrophic gastritis and intestinal metaplasia (IM).<sup>1</sup> The model proposed is based on "a minimum of two endoscopic biopsies", although 40% of patients had at least three biopsies, and more than 15% of patients had more than four biopsies performed. Within that setting, the authors investigated the significance of type I, II, and III IM, and concluded that those with type I IM should have a less intensive follow up protocol, whereas in those with type III IM, "a hunt for high grade neoplasia should be performed".

In previous publications, several authors have reported that IM may be detected in biopsies taken exclusively from endoscopically abnormal areas,<sup>2</sup> whereas others recommended that gastric biopsies should be harvested from pre-established mucosal sites.<sup>3</sup> In this respect, the Sydney system<sup>3</sup> for grading of gastritis has provided practical guidelines for optimal biopsy sampling of the gastric mucosa. Notwithstanding, using the Sydney system's recommendations, El-Zimaity and Graham<sup>4</sup> found that IM was missed in more than 50% of the biopsies from "Sydney" sites in patients with confirmed gastric IM on multiple site sampling. These authors concluded that the minimum

number of biopsies needed to identify IM should probably be eight,<sup>4</sup> and emphasised that current and future studies that use the Sydney system as a basis for detecting gastric IM are not likely to be reliable. Thus, it appears that sampling gastric biopsies from pre-established mucosal sites,<sup>2</sup> or from endoscopically abnormal areas<sup>3</sup> may be both insufficient to calculate IM prevalence figures, and inadequate to estimate the possible risk of gastric IM in long follow up studies.<sup>4</sup>

By assessing IM at low power ( $\times 4$ ) examination, we found in histological sections from gastrectomy specimens that IM could be either spotty or extended (encompassing one or more entire low power microscopic field/section).<sup>5</sup> When extended IM was present in  $\geq 5$  histological sections, IM was considered to be widespread. Thus, IM may be spotty, or extended and widely distributed. Against that background, the proposal of Dinis-Ribeiro *et al* of obtaining two or three biopsies (in most of their series) as representative for the state of the gastric mucosa appears highly unsatisfactory. Moreover, several authors have been unable to corroborate the prognostic significance of incomplete IM type III.<sup>6,7</sup> Kato *et al* found that incomplete IM usually occurs in the antrum, whereas complete IM is usually seen in the fundus.<sup>7</sup>

The article by Dinis-Ribeiro *et al* points out that two pathologists reviewed all the slides, and that "agreement was achieved in 85% of the cases. In case of disagreement, a consensus was obtained...". Because no mention is made regarding double blind examination with coated slides, we assume that the authors did not carry out that procedure. The possibility of intraobserver and of interobserver variations was not explored.

According to Dinis-Ribeiro "...endoscopic examination throughout the entire gastric cavity may still fail to diagnosis dysplasia and cancer". The authors forgot to include areas with IM, particularly when chromography of the gastric mucosa is not performed. That procedure was not mentioned in the list of "methods" used in their follow up studies.

**C A Rubio, R Befrits**

Department of Pathology and Gastroenterology, Karolinska Institute and Hospital, 17176 Stockholm, Sweden; [Carlos.Rubio@onkpat.ki.se](mailto:Carlos.Rubio@onkpat.ki.se)

## References

- 1 Dinis-Ribeiro M, Lopes C, da Costa-Pereira A, *et al*. A follow up model for patients with atrophic chronic gastritis and intestinal metaplasia. *J Clin Pathol* 2004;**57**:177-82.
- 2 Whiting J, Sigurdsson A, Rowlands D, *et al*. The long term results of endoscopic surveillance of premalignant gastric lesions. *Gut* 2002;**50**:378-81.
- 3 Misiewicz J, Tygat G, Goodwin C, *et al*. The Sydney system: a new classification of gastritis. *Working Party Reports* 1990:1-10.
- 4 El-Zimaity H, Graham D. Evaluation of gastric biopsy site and number of identification of H pylori or intestinal metaplasia. The role of Sydney system. *Hum Pathol* 1999;**30**:72-7.
- 5 Rubio CA, Hirota T, Itabashi T, *et al*. Extended intestinal metaplasia. A survey in 1392 gastrectomies from dwellers of the Pacific basin. *Anticancer Res* [In press.]
- 6 Rameshar K, Danders D, Hopwood D. Limited value of type III intestinal metaplasia in predicting risk of gastric carcinoma. *J Clin Pathol* 1987;**40**:1287-90.
- 7 Kato Y, Kitagawa T, Yanagisawa A, *et al*. Site-dependent development of complete and

incomplete intestinal metaplasia types in the human stomach. *Jpn J Cancer Res* 1992;**83**:178-83.

## CALENDAR OF EVENTS

Full details of events to be included should be sent to Maggie Butler, Technical Editor JCP, The Cedars, 36 Queen Street, Castle Hedingham, Essex CO9 3HA, UK; email: [maggie.butler2@btopenworld.com](mailto:maggie.butler2@btopenworld.com)

### ACP Management Course for Pathologists, 2004

8-10 September 2004, Hardwick Hall Hotel, Sedgfield, County Durham, UK

Further details: V Wood, ACP Central Office, 189 Dyke Road, Hove, East Sussex BN3 1TL, UK. (Tel: +44 (0) 1273 775700; Fax: +44 (0) 1273 773303; Email: [Jacqui@pathologists.org.uk](mailto:Jacqui@pathologists.org.uk))

### Combined Adult and Congenital Cardiovascular Pathology Course

8-10 November 2004, Imperial School of Medicine, National Heart and Lung Institute, London, UK

Further details: Short Course Office, National Heart and Lung Institute, Dovehouse Street, London SW3 6LY, UK. (Tel: +44 (0)20 7351 8172; Fax: +44 (0)20 7351 8246; Email: [shourtcourse.NHLI@IC.AC.UK](mailto:shourtcourse.NHLI@IC.AC.UK))

### Asian Pacific Association for Study of the Liver Biennial Conference

11-15 December 2004, New Delhi, India

Further details: Dr V Malhotra (General Secretary) or Dr P Sakhuja (Treasurer and Pathology Coordinator), Room 325, Academic Block, Department of Pathology, GB Pant Hospital, New Delhi 110002, India. (Tel: +91 11 23237455; Email: [welcome@apasindia2004.com](mailto:welcome@apasindia2004.com); Website: [www.apasindia2004.com](http://www.apasindia2004.com))

## BOOK REVIEWS

### Atlas of Diagnostic Cytopathology: Second Edition

Edited by B F Atkinson. Published by Saunders, 2003, £156.00, pp 856. ISBN 0 71216 00638

Those who are interested in cytology, at all levels of experience, are notoriously fond of atlases. The neophyte nourishes a belief that a set of images and (relatively) brief text will quickly lead to competence, whereas the expert hopes that there will be help with a difficult diagnostic problem, or the aesthetic enjoyment of images more beautiful than any in their experience. The "Atlas of Diagnostic Cytopathology" (second edition) edited by Barbara F Atkinson alludes to these disparate audiences in the preface, stating that the work is for "cytopathology residents, fellows, cytotechnology students, and ...experienced cytopathologists". The first two categories are likely to judge a book by its brevity and clarity, and the last by comparison with their favourites of the genre, such as the works of Orell, DeMay, or Lopes Cardozo.

By anyone's criteria Atkinson's atlas is a worthwhile addition to the diagnostic

cytology armamentarium. In many respects it is excellent, although a slight unevenness, perhaps inevitable in any multiple author work must be acknowledged. Its text, authored by an impressive array of experts in the field, although laudably concise, is comprehensive in its breadth. It effectively covers basic information, such as the diagnostic approach to a smear, in addition to the most recent ancillary techniques, such as fluorescent in situ hybridisation and laser scanning cytometry. It is timely and useful, but unfortunately, that the breadth of coverage also extends to a discussion of medicolegal liability in the practice of cytology.

The images, central to the purpose of this work, are almost universally of high quality, both in terms of their initial acquisition and reproduction. The source of the images, the collections of the many authors, inevitably leads to some inconsistencies. I found the occasional image dark, light, "milky", or poorly focused, and rarely found an example of a picture that did not really illustrate, in my opinion, any characteristic feature of the entity it purported to represent. But for the aficionado there is plenty of lagniappe here, from beautiful images of humble observations (such as Spinnbarkeit in a cervical smear) to rare fine needle aspiration samples of follicular dendritic cell sarcoma and other unusual neoplasms.

This work, despite its imperfections, does span the utility gap between the beginner and the expert and will be useful in both large academic and small departments.

**W R Geddie**

### Diagnostic Musculoskeletal Surgical Pathology

Edited by S E Kilpatrick, J B Renner. London: Published by Elsevier, 2003, £119.00 (hardback), pp 393. ISBN 0-7216-9163-3

This is a superb book combining radiological and pathological features and including colour illustrations of both bone and soft tissue tumours.

Entities are discussed in a clear, cogent manner. Numerous helpful tables liberally supplement the text and serve as an aide de memoir.

All illustrations are of high quality and show the reader the essential diagnostic features. The additional feature of this book is the associated fine needle aspiration findings. Although not a practising cytopathologist, I must say that I found these to be aesthetically pleasing but would have difficulty diagnosing a myxofibrosarcoma on fine needle aspiration! Be that as it may, I am sure that aficionados of cytopathology would no doubt find the illustrations diagnostic.

All in all, there is a little, if any, fault with this book. I thoroughly recommend it as a bench book for those encountering soft tissue and bone tumours. The radiological pictures are also excellent and give the reader a handle on what to expect with the various tumours. This book compares very favourably with its larger and better known competitors. As a starting point for the diagnosis of bone and/or soft tissue tumours, I think that this is an excellent book.

**R Chetty**

## Handbook on Proteomic Methods

Edited by P M Conn. New Jersey: Humana Press, 2003, \$135.00 (hardback), pp 610. ISBN 1 58829 3408

This book is a 510 page, hard cover issue covering proteomic methods and their applications in molecular biology, a subject that is of interest to many molecular scientists. It consists of four major sections, which include both colour and black and white illustrations. The first major section deals with the general techniques of proteomics and specific aspects of the technology. The second section concentrates on post-translational modifications, variants, and isoforms. Here, the characterisation of protein isoforms is discussed at length.

The book is written by a group of well recognised scientists who describe a wide range of state of the art techniques used for the identification of and analysis of a variety of proteins that are expressed in the cell.

The techniques described vary from very general to highly specific ones that are used for data analysis and the investigation of post-translational modifications. In addition, several methods describing how the application of proteomics can be used to identify new drugs and markers for cancer are also discussed. The methods for each protocol are described in great detail, together with potential trouble shooting approaches, which may be necessary when encountering problems.

This book is a well written, fully referenced text on proteomic methods, which provides an excellent guide to any scientist working in the field. In addition, the book also demonstrates how proteomic methods might provide a clearer insight into complex biological systems ranging from plants to humans in the amelioration of disease. Furthermore, this technology could provide a means for better and more effective drug development.

The editor has produced a remarkable book, which is ideal for any scientist working in the proteomics field.

R Naidoo

## Quinolone Antimicrobial Agents. 3rd Ed.

Edited by D C Hooper, E Rubinstein. Washington: ASM Press, 2003, \$125.95, pp 485. ISBN 1-55581-231-7

In 1984, as a wet behind the ears house officer, I remember waiting with great anticipation for the new wonder drug ciprofloxacin to arrive by motorcycle courier so that it could be used for a patient with refractory febrile neutropenia. Nowadays, quinolones such as ciprofloxacin have become so widely used that it may be difficult for younger bacteriologists to imagine BBQ (bacteriology before quinolones)! The important place that these compounds have assumed in the antimicrobial pharmacopoeia is reflected by the fact that this is the third edition of this text in 10 years.

The book is divided into four sections, covering mechanisms and spectrum of antibacterial activity and resistance; pharmacology; clinical applications; and adverse and other effects. For a USA produced book, it is refreshing to see a truly international line up of contributors. Inevitably, for a work that is so broad in its outlook, it is unlikely that every chapter, particularly in the first two sections, will be consulted with equal frequency—for example, the chapter on structure-activity relations of the quinolones is unlikely to whip the jobbing clinical bacteriologist into an uncontrolled state of frenzied excitement. However, this is not to say that all of the non-clinical chapters will go unread by those with a more clinical orientation—the chapters on mechanisms of action and resistance make interesting reading. The clinical applications section accounts for 16 of the book's 30 chapters and includes chapters on the use of quinolones in the management of intra-abdominal infections and infections caused by intracellular pathogens, and the use of these drugs in intensive care unit infections and, perhaps of most interest, paediatrics; none of these areas appeared in the second edition of the book. Quinolone resistance is revisited again in this section, but there is little overlap with earlier chapters. Donald Low's excellent chapter on the clinical relevance of quinolone resistance is one of the highlights of the book, and the chapter on the impact of veterinary use of these drugs on resistance in bacterial isolates from human infection makes sobering reading, and emphasises the fact that there is still much to be done in limiting the use of these drugs in the agricultural sector.

The infamous list of quinolones withdrawn before or after reaching the market place because of serious toxicity must be the cause of many a sleepless night for some of those

employed by the pharmaceutical industry, and the final section of the book considers these toxicities in detail.

Several chapters throughout the book stray a little from their remit—for example, the one which deals with QT prolongation by quinolones includes a rather too detailed discussion of electrophysiology, and the chapter on the treatment of intracellular infection focuses much of its attention on the use of other drugs, such as tetracyclines and macrolides, in this setting. I would also have liked to have seen more discussion concerning the accumulating evidence linking quinolones with the emergence of methicillin resistant *Staphylococcus aureus*. Nevertheless, these are relatively minor criticisms, and the book would make a valuable addition to the departmental library of any clinical microbiology laboratory.

K G Kerr

## CORRECTIONS

**Mouse models of childhood cancer of the nervous system.** M A Dyer. *J Clin Pathol* 2004;**57**:561–76. The author apologises for the ambiguous sentence on page 573. The sentence: "Tumours form when Rb, p107, and p53 are inactivated, but whether p107, p53, or both genes must be inactivated for retinoblastoma to form in the mouse retina is unknown." should have read: "Tumours form when Rb, p107, and p53 are inactivated, or when Rb and p107 are inactivated. However, it is not known whether p107, p53, or both genes must be inactivated for metastatic retinoblastoma to form in the mouse retina because all possible genetic combinations were not characterised."

**The practical application of reflectance spectrophotometry for the demonstration of haemoglobin and its degradation in bruises.** V K Hughes, P S Ellis, T Burt, *et al.* *J Clin Pathol* 2004;**57**:355–9. Reference 27 is incorrect. It should have been: Edwards EA, Duntley SQ. The pigments and color of living skin. *Am J Anat* 1939;**65**:1–33. The author apologises for any inconvenience this may have caused.



## Secretory carcinoma of the male breast

S R Niveditha, P Bajaj and A Nangia

*J Clin Pathol* 2004 57: 894

doi: 10.1136/jcp.2003.015149

---

Updated information and services can be found at:

<http://jcp.bmj.com/content/57/8/894.1.full.html>

---

*These include:*

### References

This article cites 2 articles

<http://jcp.bmj.com/content/57/8/894.1.full.html#ref-list-1>

### Email alerting service

Receive free email alerts when new articles cite this article. Sign up in the box at the top right corner of the online article.

---

### Notes

---

To request permissions go to:

<http://group.bmj.com/group/rights-licensing/permissions>

To order reprints go to:

<http://journals.bmj.com/cgi/reprintform>

To subscribe to BMJ go to:

<http://group.bmj.com/subscribe/>