

# PostScript

## CORRESPONDENCE

If you have a burning desire to respond to a paper published in the *Journal of Clinical Pathology*, why not make use of our "rapid response" option?

Log on to our website ([www.jclinpath.com](http://www.jclinpath.com)), find the paper that interests you, and send your response via email by clicking on the "eletters" option in the box at the top right hand corner.

Providing it isn't libellous or obscene, it will be posted within seven days. You can retrieve it by clicking on "read eletters" on our homepage.

The editors will decide as before whether to also publish it in a future paper issue.

### Vocal cord biopsy leading to the diagnosis of hyperlipidaemia

A 33 year old man presented with three months of persistent hoarseness with no preceding upper respiratory tract infection. He was otherwise a healthy young policeman and he was a non-smoker.

A benign looking polyp was discovered on microlaryngoscopic examination at the anterior end of the left vocal cord adjacent to the anterior commissure. This was biopsied and subsequent histological examination showed a polypoid fragment of respiratory tract mucosa with abundant fibrinoid material in its core, as would be expected in a typical vocal cord polyp. However, numerous foamy histiocytes were also present, with most

forming sheets surrounding blood vessels (fig 1A, B). This raised the suspicion of hyperlipidaemia.

Subsequent blood tests revealed a random cholesterol value of 9.2 mmol/litre (normal range, 2.9-5.2) and triglycerides of 6.78 mmol/litre (normal range, 0-2 fasting). His general practitioner was informed and a repeat fasting blood test was performed. This showed the fasting cholesterol and triglyceride values to be 7.3 mmol/litre and 2.86 mmol/litre, respectively. Therefore, he was started on treatment for hyperlipidaemia.

Foamy histiocyte collections are well described in the gastrointestinal tract.<sup>1-5</sup> To the best of our knowledge, however, this is the first report of the presence of foamy histiocytes in the larynx.

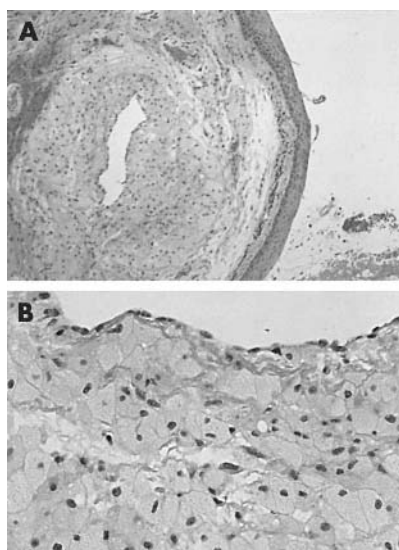
All studies on the association between tissue collections of foamy histiocytes and disorders of lipid metabolism have been done on patients with palpebral xanthelasma. Although not all patients with xanthelasma have dyslipidaemia, xanthelasma is a good marker for dyslipidaemia, and thus an indication for a full lipid profile study.<sup>6,7</sup> Our case is unique in that the patient's hyperlipidaemia was diagnosed through an initial presentation of hoarseness. This is the first ever reported case to show an association between a tissue collection of foamy histiocytes, other than palpebral xanthelasma, and hyperlipidaemia. This may be a very rare association, or it may be that we have not previously paid enough attention to the presence of foamy histiocytes in our vocal cord biopsies. Considering the prevalence of dyslipidaemia in developed nations, the presence of foamy histiocytes in the larynx may be more common than we expect.

S K Kang, L G McClymont

ENT Department, Raigmore Hospital, Inverness  
IV2 3UJ, UK; [skkang@globalnet.co.uk](mailto:skkang@globalnet.co.uk)

J R Goodlad

Pathology Department, Raigmore Hospital



**Figure 1** (A) A haematoxylin and eosin stained section of the vocal cord polyp biopsy taken with a  $\times 2$  objective. Numerous foamy histiocytes are seen in the core of the polyp surrounding a central blood vessel. (B) The same section viewed at higher power ( $\times 40$  objective), showing sheets of foamy histiocytes around the blood vessel lumen.

### Ciliated cell variant of endometrioid adenocarcinoma: a rare tumour

The ciliated cell variant of endometrioid adenocarcinoma is a very rare tumour with sporadic reports in the literature. It is only briefly mentioned in most textbooks on gynaecological pathology.<sup>1-3</sup> We report a case of ciliated adenocarcinoma arising from the endometrium.

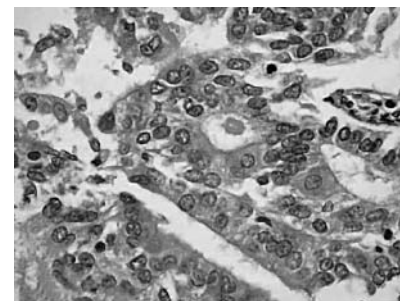
A 52 year old woman presented with continuous vaginal bleeding for 10 weeks. Of interest, she had two older sisters who had both undergone hysterectomy for bleeding problems. An ultrasound scan suggested the possibility of cystic glandular hyperplasia of the endometrium. An endometrial biopsy was performed, raising the possibility of a neoplastic process. A total abdominal hysterectomy and bilateral salpingo-oophorectomy was then carried out for definitive diagnosis.

Grossly, the endometrial cavity was expanded by thick friable material interspersed with areas of haemorrhage. Macroscopic invasion was not seen. Histologically, the endometrium was seen to be extensively and almost totally replaced by an adenocarcinoma composed predominantly of ciliated cells (fig 1), with a focally cribriform appearance. Minute foci of necrosis were present. The tumour was noted to have a pushing border, infiltrating the inner half of the myometrium. Vascular invasion was also seen.

Adenocarcinomas of the endometrium often contain a few ciliated cells.<sup>1,2,4</sup> Rarely, they may be composed predominantly, or even exclusively, of ciliated cells. At least 75% of the tumour cells have to be ciliated for the tumour to be termed a ciliated cell carcinoma.<sup>4</sup>

These very rare and distinctive tumours consist of sheets of cells with a cribriform pattern imparted by scattered extracellular lumina. The lining cells have prominent cilia, projecting into the luminal space.<sup>2</sup>

Because most ciliated endometrial proliferations are benign, the diagnosis of ciliated cell carcinoma necessitates caution, with the presence of myometrial or vascular invasion establishing the diagnosis.<sup>1-5</sup> Although these tumours can extensively invade the myometrium, the prognosis of the few reported cases has been relatively favourable.<sup>4</sup>



**Figure 1** High power view of the endometrium, with ciliated cells visible. Haematoxylin and eosin stain.

### References

- Moreto M, Ojembarrena E, Zaballa M, et al. Retrospective endoscopic analysis of gastric xanthelasma in the non-operated stomach. *Endoscopy* 1985;17:210-11.
- Vimala R, Ananthakshmi V, Murthy M, et al. Xanthelasma of oesophagus and stomach. *Indian J Gastroenterol* 2000;19:135.
- Knolle J, Wessel H, Hildebrandt E. Lipid island (xanthelasma) of the duodenal mucosa—a rarely found diagnosis and differential diagnosis. *Z Gastroenterol* 1995;33:457-61.
- Bejarano PA, Aranda-Michel J, Fenoglio-Preiser C. Histochemical and immunohistochemical characterisation of foamy histiocytes (muciphages and xanthelasma) of the rectum. *Am J Surg Pathol* 2000;24:1009-15.
- Boruchowicz A, Rey C, Fontaine M, et al. Colonic xanthelasma due to glyceride accumulation associated with an adenoma. *Am J Gastroenterol* 1997;92:159-61.
- Ribera M, Pinto X, Argimon JM, et al. Lipid metabolism and apolipoprotein E phenotypes in patients with xanthelasma. *Am J Med* 1995;99:485-90.
- Bates MC, Warren SG. Xanthelasma: clinical indicator of decreased levels of high-density lipoprotein cholesterol. *South Med J* 1989;82:570-4.

S E Low, A Nicol

Department of Histopathology, Leighton Hospital, Crewe, Cheshire CW1 4QJ, UK; suenn10@aol.com

## References

- 1 Robboy SJ, Anderson MC, Russell P. Endometrial carcinoma. In: *Pathology of the female reproductive tract*. London: Churchill Livingstone, 2002:343–4.
- 2 Buckley CH, Fox H. Histological variants of endometrioid adenocarcinoma. In: *Biopsy pathology of the endometrium*. London: Arnold, 2002:156–7.
- 3 Silverberg SG, Kurman RJ. *Tumors of the uterine corpus and gestational trophoblastic disease, atlas of tumor pathology, 3rd Series, Fascicle 3*. Washington DC: Armed Forces Institute of Pathology, 1996.
- 4 Hendrickson MR, Kempson RL. Ciliated carcinoma—a variant of endometrial adenocarcinoma: a report of 10 cases. *Int J Gynecol Pathol* 1983;2:1–12.
- 5 Haibach H, Oxenhandler RW, Luger AM. Ciliated adenocarcinoma of the endometrium. *Acta Obstet Gynecol Scand* 1985;64:457–62.

## Pathologists' slide storage: ice age technology comes to the rescue

Piles of glass slides (fig 1) from cases pending, strewn untidily across a pathologist's desk, adjacent to his or her microscope, is a far from uncommon sight. As one pile collapses inevitably into another, slides from different cases become increasingly jumbled, and the quick identification of the slides becomes ever more difficult. And while the pathologist eagerly awaits the arrival of the requested levels, special stains, or sections from further blocks, yet more slides (from new cases pending) invariably accumulate. We decided to investigate how common this scenario is and what could be done to improve it.

We prepared a simple questionnaire and invited our histopathologist colleagues in Plymouth, Exeter, and Truro, UK, to tell us how they coped with the problem of storing slides from cases pending and, if they were experiencing problems, whether they could think of any solutions. We received responses from 15 consultant pathologists and five registrars.

The average number of pending cases was five for each person (range, 1–10). The average number of pending slides was 39 for each person (range, 2–80). The preferred choice of storage (12 pathologists) was to retain the slides with the request form in a slide tray, whereas seven preferred to pile the slides on the desk or in a drawer. One pathologist sent the slides back to the lab along with the request form for extra work. Four pathologists maintained no paper record of their cases pending and as a consequence




Figure 1 Scattered slides on the desk.



Figure 2 Well organised slides in an ice cube tray.

tended to lose track of them. Most pathologists kept track and were reminded of their pending cases by the sight of the retained slides and request forms.

Four pathologists were very satisfied by their chosen method of slide storage and found slide retrieval always easy (two of these used slide trays and two piled their slides on the desk). Fourteen pathologists admitted to encountering some problem but usually found slide retrieval easy. Two pathologists found slide retrieval always difficult and one of them was seriously looking for a better option for slide storage.

We suggest that an effective solution to the problem of storing slides from pending cases is to use a plastic tray with multiple deep wells, each well capable of storing multiple slides (up to 12 slides) of a single case. The slides would be naturally inclined at an angle of 45 degrees, thus allowing the easy viewing of their labels from the vantage of the microscope. If request forms were to be retained, they could be stored under the tray.

An ideal design for just such a slide tray has in fact been available for many years, typically incorporating 18 separate wells, and thereby accommodating the slides from 18 cases: the almost ubiquitous ice cube tray (fig 2). Such a tray has been used for several months now by one of us to great effect.

R Awasthi, A Sherwood, S Blunden, H Blakely, M E F Smith

Department of Histopathology, Derriford Hospital, Derriford Road, Plymouth PL6 8DH, UK; rachnaawasthi@hotmail.com

## Lack of lymphangiogenesis during breast carcinogenesis

We read with interest the recent article by Vleugel *et al*, in which the presence of lymph vessels was investigated during breast cancer progression.<sup>1</sup> The authors claim that the observed absence of intratumorous lymph vessels in invasive breast cancer can be explained by the absence of lymphangiogenesis. In our opinion, this is a rather bold conclusion because only lymph vessel density was assessed and not lymph endothelial cell proliferation. By analogy with angiogenesis, the mere presence of a number of vessels at a certain time point—for example, at surgery—provides no information concerning the degree of ongoing angiogenesis.<sup>2</sup> Lymph vessel density is the net result of lymphangiogenesis and vessel regression or remodelling.

A second remark is that the authors made no distinction between different growth patterns of breast cancer, as described earlier

by Colpaert *et al*.<sup>3</sup> However, the recognition of growth patterns of malignant tumours is of crucial importance when evaluating (lymph)-angiogenesis: breast carcinomas with an expansive growth pattern form a well circumscribed nodule consisting of carcinoma cells and desmoplastic connective tissue with ongoing angiogenesis, whereas breast carcinomas with an infiltrating growth pattern grow between pre-existing structures and co-opt blood vessels without disturbing the tissue architecture.<sup>3</sup> In addition, liver metastases of breast cancer have a very high density of blood vessels, but this is a result of the co-option of pre-existing liver sinusoids and not the result of angiogenesis.<sup>4</sup>

We recently studied the presence of lymphangiogenesis in 31 breast carcinomas by double immunostaining for the proliferation marker Ki-67 and the lymph endothelial cell marker LYVE-1, taking into account the growth pattern.<sup>5</sup> Intratumorous lymph vessels were present in eight of 10 breast carcinomas with an infiltrating growth pattern. In breast carcinomas with an expansive growth pattern, intratumorous lymph vessels were present in only seven of 18 cases ( $p = 0.04$ ). Proliferating lymph endothelial cells were seen in 15 of 31 breast tumour specimens in the tumour parenchyma and at the tumour–breast tissue interface. Fractions of proliferating lymph endothelial cells ranged from 0% to 11.4%. Thus, lymphangiogenesis is ongoing during breast cancer growth and its extent depends on the tumour growth pattern. In the same study, higher mRNA expression of lymphangiogenesis related factors (vascular endothelial growth factor C (VEGF-C), VEGF-D, VEGF receptor 3; assessed by quantitative real time reverse transcription polymerase chain reaction) in inflammatory breast cancer versus non-inflammatory breast cancer correlated with higher fractions of proliferating lymph endothelial cells. The presence of this positive association between the expression of lymphangiogenic factors and the fraction of proliferating lymph endothelial cells is at variance with the hypothesis stated by Vleugel *et al* that inhibitors completely counter the lymphangiogenic signal in breast cancer.<sup>1</sup>

In addition, a methodological issue that needs further investigation is whether the expression of LYVE-1 is downregulated by the presence of breast cancer cells, as suggested by Stessels *et al* and by Williams *et al*.<sup>4,6</sup> If this is true, slight variations in immunostaining protocols might be responsible for false negative results of intratumorous lymph vessel assessment.

In conclusion, our results are in favour of ongoing lymphangiogenesis during breast cancer progression, the extent of this process being modulated by the growth pattern, and advocate the assessment of the lymph endothelial cell proliferation fraction as a measure of lymphangiogenesis.

I Van der Auwera, P Vermeulen, E Van Marck, L Dirix

Translational Cancer Research Group (University of Antwerp and General Hospital Sint-Augustinus), Oosterveldlaan 24 Wilrijk, Antwerp 2610, Belgium; peter.vermeulen2@pandora.be

## References

- 1 Vleugel MM, Bos R, van der Groep P, *et al*. Lack of lymphangiogenesis during breast carcinogenesis. *J Clin Pathol* 2004;57:746–51.

- 2 Vermeulen PB, Gasparini G, Fox SB, *et al*. Second international consensus on the methodology and criteria of evaluation of angiogenesis quantification in solid human tumours. *Eur J Cancer* 2002;**38**:1564–79.
- 3 Colpaert CG, Vermeulen PB, van Beest P, *et al*. Cutaneous breast cancer deposits show distinct growth patterns with different degrees of angiogenesis, hypoxia and fibrin deposits. *Histopathology* 2003;**42**:530–40.
- 4 Stessels F, Van den Eynden G, Van der Auwera I, *et al*. Breast adenocarcinoma liver metastases, in contrast to colorectal cancer liver metastases, display a non-angiogenic growth pattern that preserves the stroma and lacks hypoxia. *Br J Cancer* 2004;**90**:1429–36.
- 5 Van der Auwera I, Van Laere S, Van den Eynden G, *et al*. Increased angiogenesis and lymphangiogenesis in inflammatory versus non-inflammatory breast cancer by real-time RT-PCR gene expression quantification. *Clin Cancer Res* 2004 [In press.]
- 6 Williams CSM, Leek RD, Robson AM, *et al*. Absence of lymphangiogenesis and intratumoural lymph vessels in human metastatic breast cancer. *J Pathol* 2003;**200**:195–206.

## BOOK REVIEWS

### Medical Bacteriology

P Hawkey, D Lewis, eds. Oxford University Press, 2003, £40.00 (paperback), pp 409. ISBN 0 19963 778 4

Medical Bacteriology, 1st edition (Hawkey and Lewis), is an excellent book and was part of a Practical Approach series published by IRL Press in 1989. This book had chapters on the bacteriology of urine, normally sterile fluids, the respiratory tract, the genital tract, superficial and deep tissue infection, intestinal disease, susceptibility testing, antibiotic assays, reporting and record keeping, quality control, outbreak investigation, and epidemiology. I was given a free copy by an antibiotic representative while training for the MRCPATH examination in microbiology. I read it several times, used it at the bench, added my own notes, and inserted many extra pages. It was a great back bone for the development of practical skills and understanding their importance.

Medical Bacteriology, 2nd edition, again edited by Peter Hawkey and Deirdre Lewis, is a little thicker and larger than its predecessor, with the same chapter and appendix headings. Its “practical approach” is still a central theme and has been enhanced with the use of black text boxes to describe particular protocols. For example, how to perform the Stokes’s method of susceptibility testing using both band and rotary plating methods to standardise the inoculum, and dilution protocols for aminoglycoside assays on the Abbott TDX/FLX analysers. These are useful and highlight the importance of an understanding of the principles of a particular test for the reader. For example, in the case of antibiotic assays that are usually highly automated using specialised machinery, a student would ideally first acquire knowledge of the biochemical basis for the antibiotic assay, and subsequently develop the knowledge of how to work the machine; despite the fact that it is possible to perform the test without an understanding of the rationale.

The chapter on antimicrobial susceptibility testing has doubled in size since the first edition, reflecting in part a greater number of

options for susceptibility testing and their automation, and efforts to standardise the approach to antibiotic susceptibility testing in the UK. Automation is discussed in depth, including the fact that automated readers for disc susceptibility testing have become increasingly important, particularly when used in conjunction with the BSAC disc susceptibility method, and reduce errors in transcription, operator variability, and interpretation, while enhancing the epidemiological usefulness of this information. Completely automated susceptibility test methods are also described—for example, systems by Microscan and Vitek. These have been commonplace for over a decade in large North American laboratories, but are not commonly used in the UK. However, with an increasing requirement for the integration of information technology systems within healthcare institutions and 24 hour working in clinical laboratories, there will be an increasing need for these solutions.

In conclusion, despite the fact that this book is now just a little too big to fit into a standard white coat pocket, it is nevertheless a comprehensive, accessible, and eloquent review of those processes essential to medical bacteriology, and as such is still valuable for both students and experienced staff.

J Kerr

### p53 Protocols: the Original Soundtrack of 25 Years of p53 Research. Methods in Molecular Biology. Vol. 234

Edited by S Deb, S P Deb. Published by Humana Press, 2003, \$99.50 (hardback), pp 280. ISBN 1 58829 106 5

This is 2004. Rock’n roll has reached 50, and p53, discovered in 1979 has just turned 25. Fitting time for this “Protocols around p53”, which sounds like one of these tribute CD compilations of the standards that have made the history of the field. With close to 20 000 papers indexed into PubMed quoting “p53” as a keyword, this protein is perhaps one of the biggest success stories of molecular oncology—one that has already fascinated two generations of laboratory scientists. And, in contrast to the Rolling Stones, p53 is still producing top of the chart hits every year.

This book on p53 protocols, edited by Sumitra Deb and Swati Palit Deb, covers an incredible range of practical information, useful to the informed p53 reader as well as to the newcomer to the field (and I have in mind, in particular, the young PhD students in my laboratory or elsewhere: they are going to love it). However, in my opinion, the best target audience is all those who, not being privy to developments in p53-ology, might feel left out and wish to do some catching up with practical matters. In this respect, from one chapter to the other, the book provides a clever outline of the state of the art in p53 research; in particular, through the short and informative introduction that opens each chapter. The book covers a wide range of topics, from basic p53 protein biochemistry (production, purification, protein–protein and protein–DNA interactions, immunodetection) to expression in cells (adenoviruses, transfection, degradation, cellular localisation), transactivation and transrepression,

identification of target genes, effects on proliferation and apoptosis, and assessment of mutant p53 functions using p53 mutant mice. One of the most interesting aspects is that the book gives some insight on exciting, underestimated, and recent aspects of p53 biology, such as transrepression or mitochondrial localisation. The authors are all p53 experts who have contributed outstanding conceptual and technical papers in the field, including some of the most important p53 findings of the past 15 years.

Now, inevitably, there are some weak points. Not so much in the contents of the book but rather in what it lacks (exactly like a compilation CD: you buy it for *Satisfaction* and *Bebop-a-lula* but you complain because it does not feature that ‘67 hit by *The Zombies*). For example, for many years there has been a heated debate on the use and relevance of anti-p53 antibodies. Some of them react with specific protein conformations. Others may recognise only some isoforms and others, still, bind to epitopes that contain post-translational modification sites. We are still looking for a good roadmap of p53 antibody usage. Another (relative) weakness is the lack of coverage of RNA interference as a tool to probe p53 functions. However, from my perspective, the most important problem lies in the poor coverage of issues related to mutation detection and analysis in human tumours. The book features an excellent, well documented paper on mutation detection by single strand conformation polymorphism and direct dideoxy sequencing. However, it does not discuss the many recent technical developments in other detection methods, such as denaturing high performance liquid chromatography, pyrosequencing, or mutation screening using different kinds of DNA arrays that are now commercially available, not to speak of yeast based functional assays.

In conclusion, this book is a goldmine for those who will take care to scrape the surface and get into the meat. It will provide readers with many keys to open up the difficult p53 literature. Moreover, it will provide scientists working on other, less fashionable proteins with several tools to turn their protégée into a Rock ‘n Roll star. This is the very least that p53 can offer as retribution to the community: after all, these p53 protocols have been developed from backbones borrowed from other proteins....

P Hainaut

### A Clinician’s Dictionary of Pathogenic Microorganisms

Edited by J H Jorgenson, M A Pfaller. Published by ASM Press, 2004, £29.95 (paperback), pp 282. ISBN 1 55581 280 5

This little pocket sized dictionary is primarily designed to provide clinicians with a convenient means of understanding the clinical features of the microorganisms they encounter. In most situations, this will be when they try to make sense of microbiology reports or understand published articles. As a practising clinical microbiologist, much of my time is taken up in trying to get clinicians to make sense, so I welcome any help that is on offer. The dictionary aims to include information on all the common microbes that are likely to be encountered, as well as some of the more esoteric species that even most microbiologists might struggle to write a few lines

about. The dictionary is divided into sections for bacteria, fungi, parasites, and viruses. As a microbiologist, this is second nature to me, and I know instantly which section to look at for each individual species, but I do wonder whether this is the most useful format for clinicians who may sometime struggle to remember whether a particular organism is a virus, a bacterium, or other. In the UK, we confuse our clinical colleagues at the best of times; in my laboratory, *Treponema pallidum*, *Chlamydia trachomatis*, *Legionella pneumophila*, and *Toxoplasma gondii* are all honorary viruses. Throughout the dictionary, most of the entries are for individual microorganisms rather than for diseases, and a knowledge of some microbiology is assumed again. For example, there is no entry for anthrax; relevant information on that disease is found under the entry for *Bacillus anthracis*. Each of these entries provides some brief information on taxonomy, but more importantly, the emphasis is on the clinical importance, and where relevant provides references to important review articles. Old and now obsolete species names are included and are usefully cross referenced to the current name where the information will be found. Some of these old names are now very old indeed; hopefully, these days not many laboratories still report the presence in sputum of Pfeiffer's bacillus or send out serology reports for the Eaton agent, but I found the inclusion of these names interesting for historical reasons. However, with the advance of molecular biology, taxonomy is in constant flux, and the dictionary covers the recent important changes. Even though this book is not intended for microbiologists, I still learnt a great deal—for example, the new classification of the nutritionally deficient streptococci that were formerly *Abiotrophia* and are now *Granulicatella*. In addition to the organism entries, there are a few more general sections, which are also listed alphabetically, such as the polymerase chain reaction. There is also a very useful section on normal flora, but rather confusingly this appears alphabetically out of sequence at the end of the bacteriology section. As with most books, there were a few minor errors, but nothing that seriously detracts from what is throughout an extremely comprehensive dictionary for its size.

The publishers claim that no other portable source of information provides the type of information included. This may indeed be true, but these days with the demise of the white coat in UK hospitals there is a lack of pockets for pocket books. If a pocket does become available the competition is fierce. Despite this, I believe that this is a useful little dictionary and would recommend that a

copy be available in all clinical areas, if not pockets, where infection may be encountered. The dictionary is also available in PDA format as an eBook for those who have the suitable equipment nestling in... well yes, their pockets. Practising microbiologists and other pathologists would also find this dictionary an easy way to keep abreast of the recent taxonomic changes. I enjoyed reading it, although this may not surprise my friends and colleagues who think that I only ever read dictionaries anyway.

P A Riley

### Surgical Pathology of the GI tract, Liver, Biliary Tract, and Pancreas

R D Odze, J R Goldblum, J M Crawford, eds. 2004 (hardback), Saunders, pp 1067. ISBN 0 7216 9318 0

This book represents a mammoth undertaking—to write one textbook on the entire gastrointestinal tract, liver, biliary tree, and pancreas—and to cover it in a shade over 1000 pages is indeed a commendable feat. Such a task, of necessity, requires multiple authors and 59 contributors were responsible for this offering. Despite this, there is not much variation in style or quality, and the editors have done a sterling job in weaving it all together somewhat seamlessly.

I found the book easy to read, comprehensive, up to date, and with very few gaps. I am mindful that a single all embracing text does not rival specialist books (such as those on the liver) in terms of detail, but this book does not do too badly! The style is crisp and to the point, the colour illustrations are lavish, and the content is excellent. These are supplemented by pertinent tables and flow diagrams. The index of a book is a good place to gauge the content and layout. The index of this book is user friendly and comprehensive.

Although showing a decided North American bias in its authorship, this book transcends any artificial geographical boundaries. In my opinion, this book is the best "one stop shop" on gastrointestinal tract, liver, and pancreas pathology. Buy the book and do yourself a favour: read it!

R Chetty

### Emerging Infections

W M Scheld, B E Murray, J M Hughes, eds. 2004 (paperback): ASM Press, pp 210. ISBN 1 55581 242 2

This book is the sixth of a series of books based on ICAAC symposia on emerging infections, and contains chapters on hepatitis C virus and liver disease, re-emergence of poliovirus disease from a polio vaccine virus, yellow fever associated disease, Ebola haemorrhagic fever, the global epidemiology of AIDS, enteroaggregative *Escherichia coli*, clostridial necrotising fasciitis in injecting drug users in California, unexplained illness in drug users in the UK, travel associated fungal infections, African trypanosomiasis, Raccoon roundworm infection (baylisascariasis), consideration of the surveillance of unexplained deaths as a public health measure for early recognition of new pathogens, and the international emerging infections program in Thailand. It is edited by three distinguished infectious disease physicians.

The term "emerging" as it relates to infectious disease is difficult to define, but it tends to mean an infectious agent for which the epidemiology has changed greatly within the past two decades, and is usually accepted to be those in which the seriousness of the infection has increased in some way. Confusion arises when the term is overused. However, this book rises above that, dealing with real threats to global health, and is interesting, but it does suffer as a result of the book being a record of a symposium, and the various chapters seem a little uneasy together.

The chapter on yellow fever vaccine associated disease discusses prevention using vaccination and mosquito eradication. Although eradication is clearly most desirable, it is not feasible, and vaccination with the 17D live, attenuated vaccine is a necessity for protection when travelling to an affected area. Reactions are typically mild with headache, myalgia, low grade fever for several days, and occur in approximately 25% of those vaccinated. Immediate hypersensitivity reactions, characterised by rash, urticaria, or asthma occur in those with a history of allergy to egg or other substances (possibly gelatine), and have an incidence of 1/131 000. However, the most serious complications are vaccine associated neurotropic disease and viscerotropic disease, for which the frequency increases dramatically with age, thus creating a problem for the protection of persons 60 years and older. The authors discuss options for the elderly traveller.

I cannot say that I enjoyed reading or reviewing this book, because it feels incomplete; however, it is most certainly factual and I would certainly feel differently if I was researching one of the included topics. The book will be valuable for those interested in global public health or the most up to date information in these various fields.

J Kerr



## Surgical Pathology of the GI tract, Liver, Biliary Tract, and Pancreas

R Chetty

*J Clin Pathol* 2004 57: 1344  
doi: 10.1136/jcp.2004.017376

---

Updated information and services can be found at:  
<http://jcp.bmj.com/content/57/12/1344.1.full.html>

---

### Email alerting service

*These include:*

Receive free email alerts when new articles cite this article. Sign up in the box at the top right corner of the online article.

---

### Notes

---

To request permissions go to:  
<http://group.bmj.com/group/rights-licensing/permissions>

To order reprints go to:  
<http://journals.bmj.com/cgi/reprintform>

To subscribe to BMJ go to:  
<http://group.bmj.com/subscribe/>