

## LETTER TO JCP

## Pneumocystis carinii, cytomegalovirus, and severe transient immunodeficiency

A J Rowling, A J Kvalsvig, P M Sharples, A B Foot, D J Unsworth

*J Clin Pathol* 2003;56:718-719

*Pneumocystis carinii* infection is rare in infants, and raises strong concerns of immune deficiency. This report describes the unusual case of a male infant with concurrent chest infections caused by *P carinii* and cytomegalovirus. Investigation was complicated by the strong suspicion of non-accidental injury, including subdural haematomas. The case illustrates how to investigate for possible immunodeficiency. Low immune function tests at presentation slowly improved and have remained normal on longterm follow up. Possible explanations for the transient severe clinical immunodeficiency in this case are discussed.

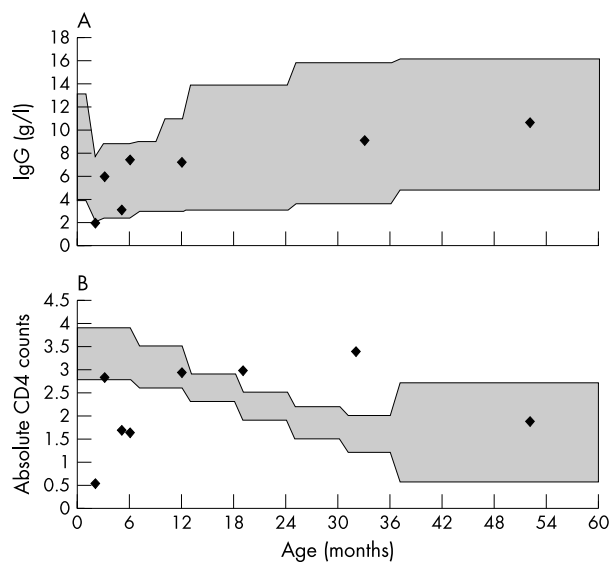
Infection with *Pneumocystis carinii* is rare in infants, and raises strong concerns of immune deficiency.<sup>1</sup> We present the unusual case of a male infant with concurrent chest infections caused by *P carinii* and cytomegalovirus (CMV).

## CASE HISTORY

The patient was born at term by normal delivery after an uneventful pregnancy. He was the first child of non-consanguineous parents, both aged 19, with no relevant family history. He was breast fed for two weeks. His postnatal check was unremarkable, but a mild cough from birth led to several visits to the family doctor. He was first admitted to hospital at the age of 9 weeks following an apnoeic episode at home. He had a fine non-blanching rash on his arms, and was treated for presumed sepsis. However, all cultures were negative and he was well at discharge 48 hours later.

The patient next presented to his local hospital at the age of 3 months, with a four day history of fever, pallor, vomiting, and a high pitched cry. On the morning of admission he had three generalised seizures. Examination findings were of a pale, floppy, unresponsive infant with respiratory distress and poor peripheral perfusion. He had no rash, bruising, or hepatosplenomegaly. Weight and height were on the 25th and 50th centiles, respectively, but his head circumference was above the 97th centile. Intravenous antibiotics were begun, with a presumptive diagnosis of sepsis. Further fits occurred over the next 12 hours and the patient was ventilated for an emergency computerised tomography (CT) head scan, initially reported as normal. His respiratory condition deteriorated and he was transferred to the regional paediatric intensive care unit, where he required high frequency oscillatory ventilation.

Initial investigations showed normal clotting screens and biochemistry, but the lymphocyte count was only  $1.8 \times 10^9$ /litre (normal range, 2.7-5.4). All lymphocyte subsets were reduced non-selectively. IgM was normal but IgG was low at 1.98 g/litre (normal range, 2.4-8.8), and IgA was undetectable. C reactive protein was greatly raised at 1240 g/litre. Cerebrospinal fluid examination revealed a white cell count of < 1, red cell count of 250, normal protein and glucose values,



**Figure 1** (A) IgG values (g/litre) and (B) absolute CD4 counts in our patient from admission at 3 months of age until the end of the three year follow up. The initial lymphocytopenia and borderline low IgG resolved rapidly, and have remained normal.

and no growth on culture. Chest x ray showed diffuse bilateral lower zone interstitial shadowing. Bronchoalveolar lavage was positive for both *P carinii* and CMV. Ganciclovir and high dose cotrimoxazole were begun intravenously. The patient improved over the next few days and was weaned from ventilation on day 6.

The original CT scan was reviewed and was felt to show borderline enlarged ventricles with bilateral subdural haematomas, confirmed at subsequent magnetic resonance imaging. The haematomas were surgically drained and a child protection investigation begun. There was no evidence of retinal haemorrhages, but a skeletal survey identified two rib fractures on the left side. Radiological opinion estimated the time of injury to have been 7-10 days before this admission.

## LABORATORY DATA

The low total lymphocyte count, low CD4 subset, and low IgG values, associated with pneumocystis and CMV were highly suggestive of immunodeficiency. Serology and polymerase chain reaction for human immunodeficiency virus (HIV) were negative. Further immune function tests followed, specifically to exclude severe combined immunodeficiency (SCID) or

**Abbreviations:** CMV, cytomegalovirus; CT, computerised tomography; HIGM, hyper-IgM syndrome; HIV, human immunodeficiency virus; SCID, severe combined immunodeficiency

other forms of T cell deficiency. T cell function tests consistently gave acceptable results, as judged by phytohaemagglutinin responses in vitro. Stimulated T cells expressed CD40 ligand normally (important in the context of "hyper-IgM" (HIGM) syndrome). Neutrophil numbers were normal. Adenosine deaminase and nucleotide phosphorylase concentrations, human leucocyte antigen (HLA) class I and II expression (on peripheral blood lymphocytes by flow cytometry), bone marrow aspirate, chromosome karyotype, DNA testing for ataxia telangiectasia, and response to tetanus immunisation were all normal/negative.

The initial lymphocytopenia and borderline low IgG resolved rapidly, and have remained normal on three year follow up (fig 1). Immunophenotyping of blood lymphocytes improved within months, to show normal numbers and percentages of T (CD3 positive) cells, B (CD19 positive) cells, and natural killer (CD56 positive) cells. IgA and IgM have been normal since 2 years of age. Thus, possible diagnoses such as HIV, SCID, and HIGM syndrome were all excluded.

The examination of maternal serum between early pregnancy and this acute illness showed CMV seroconversion. Therefore, the patient probably acquired the infection in the late antenatal or early postnatal period.

On follow up over a period of three years, the patient shows severe developmental delay, but has been strikingly free of infection on cotrimoxazole prophylaxis. He has received all routine immunisations, omitting live vaccines. Prophylactic septrin was stopped without adverse consequence at this stage.

## DISCUSSION

This patient had three major problems: *P carinii* infection, CMV infection, and evidence of non-accidental injury.

*Pneumocystis carinii* is a common infectious agent. Seroconversion can be demonstrated in most infants and small children,<sup>2</sup> but clinical disease occurs almost exclusively in the setting of immune compromise. Therefore, this infection should always trigger a search for possible HIV infection or other immunodeficiency. In this case, the search was surprisingly unrewarding. Had we missed something?

"Clinical disease occurs almost exclusively in the setting of immune compromise"

Cytomegalovirus is a relatively common congenital infection with a reported incidence of between 0.2% and 2.2% of live births.<sup>3</sup> Transmission may occur during birth through cervical secretions, or later via breast milk. The virus has been shown to suppress immunity through a variety of mechanisms.<sup>4 5</sup>

## Take home messages

- *Pneumocystis carinii* infection is rare in infants, and raises strong concerns of immune deficiency
- We describe the unusual case of a male infant with concurrent chest infections caused by *P carinii* and cytomegalovirus (CMV) who did not appear to be immunocompromised
- We postulate that CMV transiently impaired this child's immune function and predisposed him to pneumocystis infection

We postulate that CMV transiently impaired this child's immune function and predisposed him to pneumocystis infection. Indeed, a similar case of congenital CMV complicated by pneumocystis has been described.<sup>6</sup>

Neither fractures, subdural haematomas, nor non-accidental injury have previously been reported in association with CMV or pneumocystis.

.....

## Authors' affiliations

**A J Rowling, P M Sharples, A B Foot**, Bristol Royal Hospital for Children, Bristol BS2 8BJ, UK

**A J Kvalsvig, D J Unsworth**, Southmead Hospital, Bristol BS10 5ND, UK

Correspondence to: Dr D J Unsworth, Southmead Hospital, Bristol BS10 5ND, UK; [joeunsworth@hotmail.com](mailto:joeunsworth@hotmail.com)

Accepted for publication 15 January 2003

## REFERENCES

- 1 **Cailliez JC**, Seguy N, Denis CM, *et al*. *Pneumocystis carinii*: an atypical fungal micro-organism. *J Med Vet Mycol* 1996;**34**:227-39.
- 2 **Pifer LL**, Hughes WT, Stagno S, *et al*. *Pneumocystis carinii* infection: evidence for high prevalence in normal and immunosuppressed children. *Pediatrics* 1978;**61**:35-41.
- 3 **Gaytant MA**, Steegers EA, Semmekrot BA, *et al*. Congenital cytomegalovirus infection: review of the epidemiology and outcome. *Obstet Gynecol Surv* 2002;**57**:245-56.
- 4 **Wainberg MA**, Mills EL. Mechanisms of virus-induced immune suppression. *Can Med Assoc J* 1985;**132**:1261-7.
- 5 **Wallace JM**. Pulmonary infections in human immunodeficiency disease: viral pulmonary infections. *Semin Respir Infect* 1989;**4**:147-54.
- 6 **Leung TF**, Ng PC, Fok TF, *et al*. *Pneumocystis carinii* pneumonia in an immunocompetent infant with congenital cytomegalovirus infection. *Infection* 2000;**28**:184-6.



## Pneumocystis carinii, cytomegalovirus, and severe transient immunodeficiency

A J Rowling, A J Kvalsvig, P M Sharples, et al.

*J Clin Pathol* 2003 56: 718-719

doi: 10.1136/jcp.56.9.718

---

Updated information and services can be found at:

<http://jcp.bmj.com/content/56/9/718.full.html>

---

*These include:*

### References

This article cites 6 articles, 2 of which can be accessed free at:

<http://jcp.bmj.com/content/56/9/718.full.html#ref-list-1>

### Email alerting service

Receive free email alerts when new articles cite this article. Sign up in the box at the top right corner of the online article.

---

### Topic Collections

Articles on similar topics can be found in the following collections

[Immunology \(including allergy\)](#) (1279 articles)

[Pneumonia \(infectious disease\)](#) (22 articles)

[TB and other respiratory infections](#) (61 articles)

---

### Notes

---

To request permissions go to:

<http://group.bmj.com/group/rights-licensing/permissions>

To order reprints go to:

<http://journals.bmj.com/cgi/reprintform>

To subscribe to BMJ go to:

<http://group.bmj.com/subscribe/>