

## ORIGINAL ARTICLE

# Digital slide and virtual microscopy based routine and telepathology evaluation of routine gastrointestinal biopsy specimens

B Molnar, L Berczi, C Diczhazy, A Tagscherer, S V Varga, B Szende, Z Tulassay

*J Clin Pathol* 2003;56:433–438

**Aims:** To evaluate a recently developed digital slide and virtual microscope system, and to compare this method with optical microscopy on routine gastrointestinal biopsy specimens in both local and remote access modes.

**Methods:** A fully computer controlled commercial microscope was used. The scanning program included object detection, autofocus, and image compression algorithms. The overall hard disk space for a gastric biopsy was between 30 and 50 MB and the scanning time was between 20 and 40 minutes. Haematoxylin and eosin stained routine gastric (61) and colon (42) biopsy specimens were selected, scanned, and evaluated by two specialists on an optical (OM) and virtual microscope (VM).

**Results:** The overall concordance of VM and OM with the consensus diagnosis was 95.1% and 97%, respectively. Clinically important concordance was 96.1% and 98% for VM and OM, respectively. The two methods showed concordance in 92% of cases and clinically important concordance in 94.1% of cases. The reasons for discordance were image quality (one case), interpretation difference (three cases), and insufficient clinical information (three cases). Remote evaluation of the digital slides through the Internet has the advantages of the previously used static and dynamic telepathology methods.

**Conclusions:** Diagnostic concordance was found between OM and VM. The digital slide and the virtual microscope can be alternative techniques in the computerisation of the histology laboratory and in teleconsultation services after further evaluation of time and storage constraints.

See end of article for authors' affiliations

Correspondence to:  
Dr B Molnar, II Department of Medicine, Semmelweis University, Szentkirályi St. 46, 1088 Budapest, Hungary; mb@bel2.sote.hu

Accepted for publication  
14 January 2003

As a result of the rapid developments in information technology, medical digital image analysis is becoming a widely accepted technique.<sup>1</sup> Digital techniques and laboratories<sup>2</sup> already exist for radiological applications. New stand alone automated microscope systems have been developed for histological and cytological applications in the past decade.

The automated screening and rescreening of cervical smears is now available for routine practice.<sup>3,4</sup> In addition, several new semiautomatic microscopes have been developed to aid in quality control of the cytotechnologists' work.<sup>5–8</sup> These systems notify the observer of the scanned areas and images, and electronic recording of selected images is also available.

Automated histological analysis has been an important research tool for several years, but until recently it was not suitable for routine applications.<sup>9–10</sup> However, now histological diagnoses can be supported by new electronic techniques, such as TV image cytometry and teleconsultation based on histological images rather than entire samples.<sup>11</sup>

"Automated histological analysis has been an important research tool for several years, but until recently it was not suitable for routine applications"

Telepathology services were built up during the past decade around two technology platforms. Dynamic telepathology uses remote controlled microscope systems with high throughput online image transport channels.<sup>12–13</sup> This method has the advantage of entire slide access and lacks the error source of preselected microscopical frames, although the costs of setting up and running the system are relatively high. The use of static preselected images for teleconsultation needs

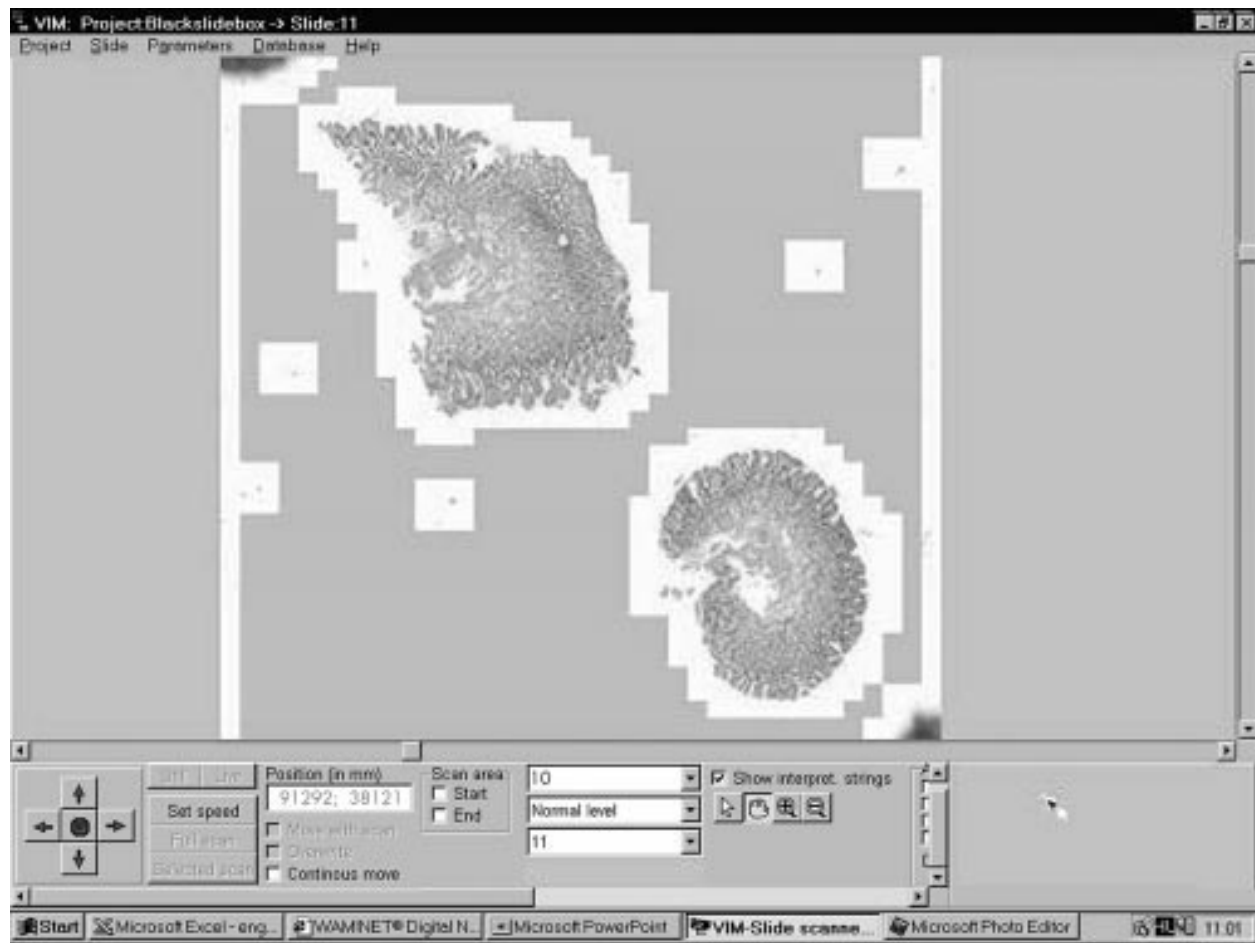
**Table 1** Diagnoses

Organ	Diagnoses	No of cases
Gastric	Healthy	5
	Chronic gastritis without intestinal metaplasia	16
	Chronic gastritis with intestinal metaplasia	12
	Chronic gastritis with atrophy	3
	Adenocarcinoma, well differentiated, intestinal type	9
	Adenocarcinoma, non-differentiated	6
	Sigillocellular carcinoma	4
	Anaplastic carcinoma	2
	Adenopapillary carcinoma	1
	Hyperplastic polyp	1
	MALT lymphoma	2
	Colon	Healthy
Colitis ulcerosa		14
Crohn's disease		7
Chronic aspecific colitis		4
Hyperplastic polyp		2
Adenoma tubulare with severe dysplasia		2
Adenoma tubulovillusom with severe dysplasia		1
Adenoma papillare		1
Adenoma tubulopapillare		1
Adenoma villosum with dysplasia		1
Adenocarcinoma	4	

MALT, mucosa associated lymphoid tissue.

much less hardware investment, but sampling errors can occur.<sup>14–15</sup> Using the Internet as a telecommunication pathway for static images is a low cost widely available alternative.<sup>16–17</sup>

**Abbreviations:** OM, optical microscopy; VM, virtual microscopy



**Figure 1** The user interface of the virtual microscope program. The artificial magnification ( $\times 10$ ) of a scanned gastric biopsy section is shown on the screen. Note the moving arrows in the left bottom corner and the + and – labels in the middle. These can be used for discrete step magnification and the reduction of a specified area of the slide. On the right bottom of the screen the scanned area of the slide is highlighted.

The applications of digital slides are considerable, as sources and targets of telepathology and automated histological analysis; however, attempts to prepare electronic or digital slides have been limited (R Ferreira *et al.* Digital dynamic telepathology—the virtual microscope. Proceedings of the 1997 AMIA Annual Fall Symposium, 1997).<sup>18,19</sup> Only recently has the storage capacity and speed of personal computers become sufficient to handle the extremely large amount of image information stored on a slide. In addition, low cost, commercial motorised microscopes have recently been developed by several manufacturers.

Working on digital slides requires virtual or digital microscopy. Preliminary positive results on a limited number of mosaicked microscopic images have been reported recently.<sup>20</sup>

The aim of our present study was to evaluate our recently reported digital slide and microscopy system<sup>21</sup> on routine gastrointestinal biopsy specimens. We compared the performance of optical and digital microscope evaluations in local and remote modes.

## MATERIALS AND METHODS

### Gastric routine biopsy specimen analysis

Biopsy specimens were placed in buffered formalin, routinely processed, and stained with haematoxylin and eosin. Altogether, 103 specimens were selected from the files of the first department of pathology. Single representative slides were evaluated from each case. Table 1 shows the distribution of the cases.

The histological sections were evaluated in separate settings on a virtual microscope (VM) and an optical microscope

(OM), without knowledge of the results of the previous analysis by two independent, board certified histologists.

First, the glass slides were assessed by optical microscopy. The paper copies of the clinical histories and the evaluation report were collected.

Over the next few weeks the slides were digitised; this was carried out in the digital microscopy laboratory. The scanning computer was also used as a digital slide server. The virtual microscopy evaluation was done on a separate local area network workstation in the pathology department with access to the slide server computer using the Internet.

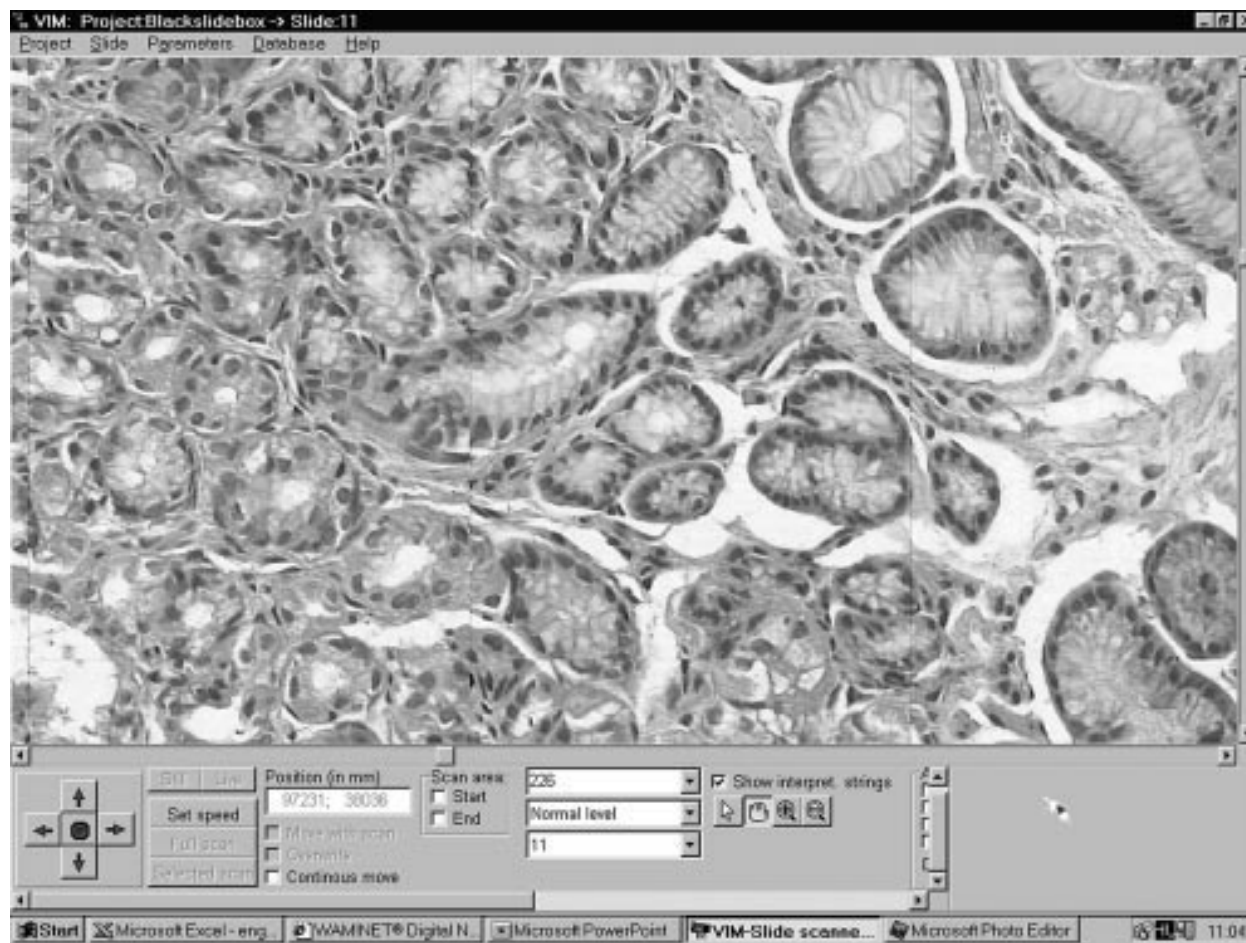
### Data analysis

At the end of the study, when all the optical and virtual microscopy results were available, the consensus data, concordance, and source of diagnostic discordance were determined.

Concordance was designated level “A”. Levels “B” and “C” were clinically unimportant and important discordance, respectively, as suggested by Weinberg *et al.*<sup>22</sup>

Those cases with discordant results were collected together with the optical and electronic data. The final diagnosis and definition of the source of the discordant data were agreed upon at a consensus session in the consultation room. Here, access to the digital slides was also available through a computer workstation and the Internet.

The reasons for discordance were classified by the consensus meeting as follows: inadequate image quality (class I), interpretation (class II), and insufficient clinical information (class III).



**Figure 2** An intermediate magnification of a scanned gastric biopsy specimen (original magnification,  $\times 200$ ).

The significance of the concordance was determined using Kendall's concordance coefficient determined by the Statistica program package (V.4.3, Statsoft, Tulsa, Oklahoma, USA).

### Slide digitisation and the virtual microscope system

#### Hardware tools used

We used an Axioplan 2 MOT (Carl Zeiss, Jena, Germany) microscope. The microscope functions (objectives, stage, focus, illumination, and filters) can be controlled and changed through the RS232 interface from an application program. The mechanical accuracy of the motorised scanning stage for X/Y and Z directions was  $0.5 \mu\text{m}$ .

We used the Grundig FAC 830 1/2 inch, one chip CCD camera with  $752 \times 581$  (440 000) pixels. The integration time of the camera can be controlled through the computer interface RS485. The applied image digitisation card was the Screen Machine II from Fast Electronic Germany (Munich, Germany) with a resolution of  $640 \times 560$  pixels and 64 K colour depth. The programs were running on computers with at least an Intel Pentium II 350 MHz processor, 128 MB RAM, and 2 GB hard disk.

#### Features of the digital slide scanning program

Scanning area determination was performed by upper right and lower left corner fixing.

Autoscanning was started after setting the stage at the zero position. During the scanning process autofocusing was done only at each third to fifth field of view. All the images were compressed in JPEG format and stored in the slide databank in the corresponding position. Autofocusing was done using Brenner's algorithm.<sup>23</sup> At  $\times 40$  magnification, 125 856 frames

would need to be stored for the entire slide. However, a threshold filter was used to store only those frames with image content. In this way, only the area containing the biopsy was stored, amounting to 302 to 1334 frames for each slide.

First, the fields of view were mosaicked using mathematical algorithms<sup>24</sup>; however, the error between the required and real positions of the stage was found to be less than  $\pm 0.5 \mu\text{m}$ . Based on this high precision no software mosaic alignment was used.

#### Features of the virtual microscope program

##### Slide selection

After scanning, the slides were stored in subdirectories called projects for a higher ordering. After selection an electronically minimised slide image is shown on the screen (fig 1).

##### Slide orientation map

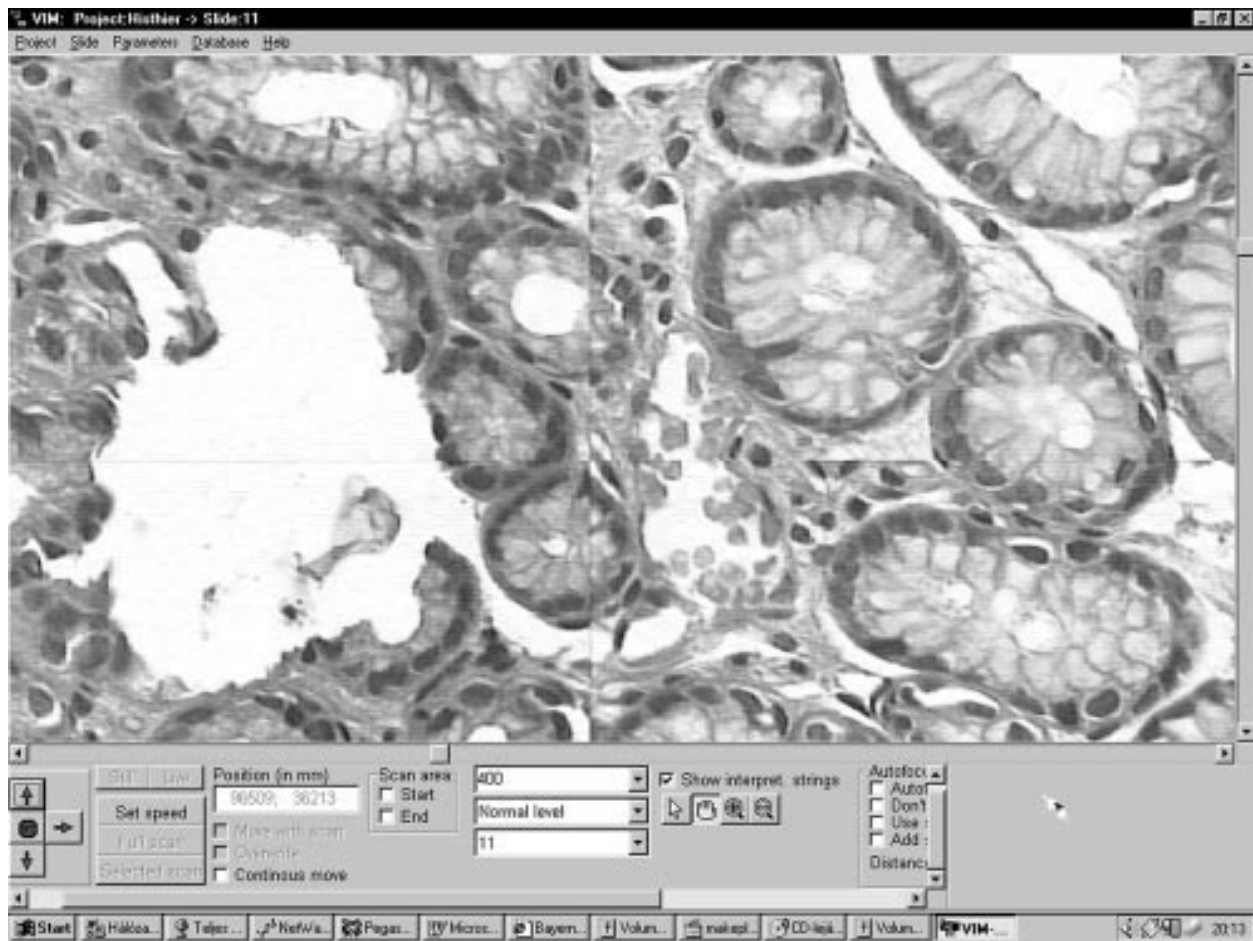
This map represents the whole slide, where one pixel on the screen corresponds to one field of view. The recorded segments are labelled with white pixels on a grey background.

##### Applicable electronic magnifications

After finding the area of interest, the user has several options for magnification of the selected segments. The prepared magnification steps of  $\times 100$  and  $\times 200$  or special "+" and "-" mouse arrows can be used to change the magnification (figs 1–3).

##### Moving and scrolling the slide

If the interested area is not on the screen at the required magnification, then the moving arrows (up, down, left, and right) can be used to move the slide in any direction.



**Figure 3** The real world scanning magnification (original magnification,  $\times 400$ ) on the virtual microscope. The borders between the mosaicked microscopic field of views can also be detected.

#### Labelling of interesting frames for re-evaluation, consultation, and reporting

Up to 10 coloured labels can be placed on the digital slide in the software. This option can also be used for reconsultation by experts via the local area network or in specific cases via the Internet.

#### Internet access

Every virtual microscopy workstation can be a slide server too. On the remote workstation the slide server's IP address has to be defined. After connecting to the server computer, a list of available slides and the information about these slides is transported to the client workstation. After selecting a slide, its electronically compressed low resolution image is transferred to the workstation. Every image that is transported during the evaluation will be stored on the local machine for safety reasons.

## RESULTS

### Concordance

Discordance was found in eight cases (7.8%) between the VM or OM results and the consensus diagnosis. In five cases the OM and in three cases the VM yielded the correct diagnosis.

There was concordance in 95 (92.2%) of the 103 cases, and clinically important concordance in 97 cases (94.1%). OM yielded higher (100 of 103; 97%) concordance with the consensus results than did VM (98 of 103; 95.1%). The highest degree of concordance for clinically important diagnosis was also seen for OM (101 of 103; 98%) (table 2).

**Table 2** Concordance between optical microscopy, virtual microscopy, and the consensus diagnosis

	Concordance (all types)	Concordance (clinically important)
OM v VM	92% (95/103)	94% (97/103)
OM v Con	97% (100/103)	98% (101/103)
VM v Con	95% (98/103)	96% (99/103)

Con, consensus; OM, optical microscopy; VM, virtual microscopy.

### Reasons for diagnostic discordance

Because the entire specimen was digitised there was no sampling error. However, the other common sources of error in telepathology—low image quality (one of eight), interpretation (four of eight), and insufficient clinical information (three of eight) were seen.

The effects of poor image quality were seen in only one case, although this was a clinically important one. In this case, the VM diagnosis was ulceration ventriculi and the OM diagnosis was ulcerated well differentiated adenocarcinoma ventriculi. The correct diagnosis was achieved by evaluating multiple focus levels in OM, an option that is not currently available in VM (table 3).

### Technical and practical data regarding the application of VM

The hard disk volume of a microscopic field of view is between 60 and 100 KB after JPEG compression. The overall hard disk space required for a gastric biopsy is between 30 and 50 MB

**Table 3** Reasons for diagnostic discordance

Level of discordance	Reason for discordance	VM diagnosis	OM diagnosis	Review consensus diagnosis
B	II	Chronic gastritis	Acute and chronic gastritis	VM
C	III	Gastric adenoma	Gastric hyperplastic polyp	VM
C	I	Ulceration ventriculi	Ulcerated, well differentiated adenocarcinoma	OM
C	II	Chronic atrophic gastritis	Chronic gastritis with low grade dysplasia	OM
B	II	Hyperplastic polyp	Hyperplastic mucosa	OM
C	II	Mild colitis	Normal colon	OM
C	III	Colitis ulcerosa with dysplasia	Colitis ulcerosa	VM
C	III	Adenoma papillare	Hyperplastic polyp	OM

Discordance: B, clinically not important; C, clinically important. Reason for discordance: I, image quality; II, interpretation; III, insufficient clinical information.  
OM, optical microscopy; VM, virtual microscopy.

**Table 4** Comparison between optical and virtual microscope evaluation methods

Microscopy feature	Optical evaluation	Electronic evaluation
Speed	4–5 minutes	2–3 minutes
Costs	Every user, high quality microscope	One high quality scanning microscope, image server, PC
Working conditions	Only limited number of slides can be evaluated because of fatigue	Normal monitor work
Consultation	With slide transportation or with image transfer, through ISDN, telephone line	Internet Remote access to the image server through local area network or internet
Quality control	With special additional hardware	By recording of evaluated image segments

and the scanning time is between 20 to 40 minutes, depending on the number and area of sections on a slide.

Evaluating the specimen on the monitor is more comfortable for the histologist, more reproducible, and more easily documented when compared with the optical method (table 4).

Remote access via the Internet was relatively fast. The first minimised image was uploaded in real time. As the user switched over to high magnification the single fields of view were seen on the screen in seconds (figs 2,3).

## DISCUSSION

In our study, we evaluated the technical feasibility and diagnostic concordance of a digital histological section evaluation system and compared it with the routine OM procedure.

Low cost computational techniques were used. The scanning speed was too slow for routine applications, but there are free resources available for increasing scanning speed by several magnitudes. The digitisation card should be changed to a higher resolution and speed ( $\times 10$ ). The computer should also be updated ( $\times 5$ ). In addition, an automated microscope could be considered.

Image quality should be further enhanced using a digital one chip, analogue three chip camera instead of the analogue, one chip camera used at present. In this case, an increase in diagnostic accuracy would be expected.

However, these developments and results show that in the near future we can have microscope free virtual microscopy workstations with the functions of the optical microscope. One advantage would be a more comfortable working environment for histologists. In addition, it would also support quality control techniques and consultation with remote experts. The first application of digital slides and virtual microscopy should be telepathology consultation. However, later this technology could be used in the routine histology evaluation process, as was done in our study.

Remote evaluation of the slides through the Internet has the advantages of the previously used static or dynamic telepathology methods (the entire slide is available at high magnification, microscope and remote assistance free evaluation).<sup>25</sup>

We found a higher concordance with optical microscopy than previous static image based telepathology studies.<sup>13–15</sup> This might be explained by the fact that this technology eliminates sampling error.

Time constraints and fatigue were not evaluated. We are planning to assess these factors in a larger interlaboratory study.

“In the near future we can have microscope free virtual microscopy workstations with the functions of the optical microscope”

The reasons for discordance yielded new information for future developments. In selected cases several focus planes are required for correct diagnosis. The virtual microscope cannot be used for the analysis of underlying cells. However, with further technical and mathematical developments several focus levels can be recorded, stored, and evaluated by the virtual microscope.

In his 1996 review article, O'Brien stated that the computerisation of the histology laboratory was desirable but that it would be far in the future.<sup>26</sup> More, recently, Leong and McGee<sup>27</sup> stated that complete automated slide digitisation has influence at all levels of clinical practice and education. They emphasised the importance of dedicated software technology. Recently, the usefulness of digital slides and virtual microscopy for quality assurance and teaching applications has been demonstrated.<sup>28, 29</sup>

Our results show that digital slides and virtual microscopy technology can be used in selected cases for telepathology consultation. After the definition of the time and storage requirements the routine use of this technique could also be considered.

## Authors' affiliations

**B Molnar, A Tagscherer, S V Varga, Z Tulassay**, Digital Microscopy Laboratory, Second Department of Medicine, Semmelweis University, Szentkirályi St. 46, 1088 Budapest, Hungary  
**L Berczi, C Diczhazy, B Szende**, First Department of Pathology and Experimental Oncology, Semmelweis University

**Take home messages**

- We found diagnostic concordance between optical microscopy and virtual microscopy on gastrointestinal biopsy specimens
- Virtual microscopy has the advantage of providing a more comfortable working environment for histologists
- Virtual microscopy also supports quality control techniques and consultation with remote experts
- Initially, digital slides and virtual microscopy should be used in telepathology consultation
- After further evaluation of time and storage constraints this technology might be useful in routine histology

**REFERENCES**

- 1 **Shotton DM**. Robert Feulgen prize lecture 1995. Electronic light microscopy: present capabilities and future prospects. *Histochem Cell Biol* 1995;**104**:97–137.
- 2 **Dooley RL**, Engel C, Muller ME. Automated scanning and digitizing of roentgenographs for documentation and research. *Clin Orthop* 1997;**274**:113–19.
- 3 **Mango LJ**, Ivasauskas EZ. Computer assisted cervical cytology using the PAPNET testing. In: Wied GL, Keebler CM, Rosenthal DL, et al, eds. *Compendium on quality assurance, proficiency testing and workload limitations on clinical cytology*. Chicago, USA: Tutorials of Cytology, 1995:155–67.
- 4 **Hailey DM**, Lea R. Prospects for newer technologies in cervical cancer screening programmes. *J Qual Clin Pract* 1995;**15**:139–45.
- 5 **Baker RW**, Wadsworth J, Brugal G, et al. An evaluation of "rapid review" as a method of quality control of cervical smears using the AxiHOME microscope. *Cytopathology* 1998;**8**:85–95.
- 6 **Grohs DH**, Dadeshidze VV, Domanik RA, et al. Utility of the TracCell system in mapping Papanicolaou-stained cytologic material. *Acta Cytol* 1997;**41**:144–52.
- 7 **Anderson TL**, Nelson AC. Quality control and proficiency testing of cytological smear screening: an integrated approach using automation. In: Wied GL, Keebler CM, Rosenthal DL, et al, eds. *Compendium on quality assurance, proficiency testing and workload limitations on clinical cytology*. Chicago, USA: Tutorials of Cytology, 1995:83–287.
- 8 **Grohs DH**, Gombrich PP, Domanik RA. AccuMed International, Inc. Meeting the challenges in cervical cancer screening: the AcCell Series 2000 automated slide handling and data management system. *Acta Cytol* 1996;**40**:26–30.
- 9 **Ong SH**, Jin XC, Sinniah R. Image analysis of tissue sections. *Comput Biol Med* 1996;**26**:269–79.
- 10 **Belhomme P**, Elmoataz A, Herlin P, et al. Generalised region growing operator with optimal scanning: application to segmentation of breast cancer images. *J Microsc* 1996;**886**:41–50.
- 11 **Dictor M**. The surgical pathologist in a client/server computer network: work support, quality assurance, and the graphical user interface. *Mod Pathol* 1997;**10**:259–66.
- 12 **Dunn BE**, Almagro UA, Choi H, et al. Dynamic-robotic telepathology: Department of Veteran Affairs feasibility. *Hum Pathol* 1997;**28**:8–12.
- 13 **Weinstein RS**, Battacharayya AK, Graham AR, et al. Telepathology a ten-year progress report. *Hum Pathol* 1997;**28**:1–7.
- 14 **Cross SS**, Burton JL, Dube AK, et al. Offline telepathology diagnosis of colorectal polyps: a study of interobserver agreement and comparison with glass slide diagnoses. *J Clin Pathol* 2002;**55**:452–60.
- 15 **Tucker JH**, Busch C, Spatz A, et al. An experimental inter-expert telepathology network using static imaging. *J Clin Pathol* 2002;**52**:761–6.
- 16 **Montironi R**, Thompson D, Scarpelli M, et al. Transcontinental communication and quantitative digital histopathology via the Internet: with special reference to prostate neoplasia. *J Clin Pathol* 2002;**55**:305–13.
- 17 **Gombas P**, Szende B, Stotz G. Support by telecommunications in diagnostic pathology. Experience with the first telepathology system in Hungary. *Orv Hetil* 1996;**137**:2299–303.
- 18 **Burns BF**. Creating low power photomicrographs using a 35 mm digital slide scanner. *Am J Surg Pathol* 1997;**21**:865–6.
- 19 **Demichelis F**, Barbareschi M, Dalla Palma P, et al. The virtual case: a new method to completely digitize cytological and histological slides. *Virchows Arch* 2002;**441**:159–64.
- 20 **Singson RPC**, Natarajan S, Greenson JK, et al. Virtual microscopy and the Internet as telepathology consultation tools. A study of gastrointestinal biopsy specimens. *Am J Pathol* 1999;**111**:792–5.
- 21 **Molnar B**, Papik K, Tagscherer A, et al. Three-dimensional reconstruction and analysis of gastric malignancies by electronic slides of consecutive sections and virtual microscopy. *Proceedings of the International Society for Optical Engineering* 1999;**3605**:190–200.
- 22 **Weinberg DS**, Allaert FA, Dusserre P, et al. Telepathology diagnosis by means of digital still images: an international validation study. *Hum Pathol* 1996;**27**:111–18.
- 23 **Firestone L**, Cook K, Culp K, et al. Comparison of autofocus methods for automated microscopy. *Cytometry* 1991;**12**:195–206.
- 24 **Ott SR**. Acquisition of high-resolution digital images in video microscopy: automated image mosaicking on a desktop microcomputer. *Microsc Res Tech* 1997;**38**:335–43.
- 25 **Weinberg DS**. How is telepathology being used to improve patient care. *Clin Chem* 1996;**42**:831–5.
- 26 **O'Brien MJ**, Sotnikov AV. Digital imaging in anatomic pathology. *Am J Clin Pathol* 1996;**106**:25–32.
- 27 **Leong FJWM**, McGee O'D. Automated complete slide digitization: a medium for simultaneous viewing by multiple pathologists. *J Pathol* 2001;**195**:508–14.
- 28 **Demichelis F**, Della Mea V, Forti S, et al. Digital storage of glass slides for quality assurance in histopathology and cytopathology. *J Telemed Telecare* 2002;**8**:138–42.
- 29 **Hediger PM**, Dee F, Consoer D, et al. Integrated approach to teaching and testing in histology with real and virtual imaging. *Anat Rec* 2002;**269**:107–19.



## Digital slide and virtual microscopy based routine and telepathology evaluation of routine gastrointestinal biopsy specimens

B Molnar, L Berczi, C Diczhazy, et al.

*J Clin Pathol* 2003 56: 433-438

doi: 10.1136/jcp.56.6.433

---

Updated information and services can be found at:

<http://jcp.bmj.com/content/56/6/433.full.html>

---

### References

*These include:*

This article cites 26 articles, 3 of which can be accessed free at:

<http://jcp.bmj.com/content/56/6/433.full.html#ref-list-1>

Article cited in:

<http://jcp.bmj.com/content/56/6/433.full.html#related-urls>

### Email alerting service

Receive free email alerts when new articles cite this article. Sign up in the box at the top right corner of the online article.

---

### Topic Collections

Articles on similar topics can be found in the following collections

[Clinical diagnostic tests](#) (637 articles)

---

### Notes

---

To request permissions go to:

<http://group.bmj.com/group/rights-licensing/permissions>

To order reprints go to:

<http://journals.bmj.com/cgi/reprintform>

To subscribe to BMJ go to:

<http://group.bmj.com/subscribe/>