

REVIEW

Endocervical glandular lesions: controversial aspects and ancillary techniques

W G McCluggage

J Clin Pathol 2003;**56**:164–173

The incidence of malignant and premalignant endocervical glandular lesions is increasing. This review covers controversial and difficult aspects regarding the categorisation and diagnosis of these lesions. The terminology of premalignant endocervical glandular lesions is discussed because of the differences between the UK terminology and the widely used World Health Organisation classification. The morphology and histological subtypes of premalignant endocervical glandular lesions are described. Early invasive adenocarcinoma and difficulties in the diagnosis and recognition of this entity are covered, as is the measurement of early invasion within cervical adenocarcinoma. Several benign endocervical glandular lesions can mimic malignant and premalignant endocervical glandular lesions, and the distinction of these benign mimics from premalignant and malignant lesions using ancillary immunohistochemical studies is also covered. Antibodies used to distinguish between endometrial and endocervical adenocarcinoma, in the diagnosis of cervical minimal deviation adenocarcinoma of mucinous type (adenoma malignum), and in the diagnosis of cervical mesonephric lesions are also reviewed.

(AIS) were 0.04 and 1.37, reflecting an even greater increase.

“There is some evidence that there is also a real increase in the incidence of malignant and premalignant endocervical glandular lesions, which are thus assuming increasing importance in diagnostic surgical pathology”

Previous reviews have mainly concentrated on morphological subtypes of cervical adenocarcinoma and on the histopathological features of the many benign mimics of malignant and premalignant endocervical glandular lesions.^{4–6} I will not cover these topics in detail in this review. Rather, I will concentrate on controversial aspects of endocervical glandular lesions. These include terminological aspects of premalignant endocervical glandular lesions because different terminologies are in use. In addition, the morphological features of premalignant glandular lesions will be described, including some recently reported variants. The difficult area of early invasive cervical adenocarcinoma will be reviewed and some guidance given on how to measure early invasive foci. Ancillary immunohistochemical studies of value in the distinction of benign mimics from malignant and premalignant endocervical glandular lesions will be reviewed. Ancillary techniques useful in the distinction of endocervical and endometrial carcinoma, in the diagnosis of the mucinous variant of cervical minimal deviation adenocarcinoma (MDA) (adenoma malignum), and in the diagnosis of cervical mesonephric lesions will also be discussed.

Malignant and premalignant endocervical glandular lesions are relatively rare but their incidence appears to be increasing.^{1,2} Most of this increase is more apparent than real because of the better recognition of premalignant endocervical glandular lesions by histopathologists and the realisation that some poorly differentiated cervical carcinomas are glandular in type. In addition, in many countries there has been a reduction in the incidence of invasive squamous cell carcinoma because of the success of organised cervical screening programmes. However, there is some evidence that there is also a real increase in the incidence of malignant and premalignant endocervical glandular lesions,³ which are thus assuming increasing importance in diagnostic surgical pathology. For example, a study from Sweden found that the incidence of cervical adenocarcinoma increased from 1.59/100 000 person years in the 1950s and 1960s to 2.36 in the early 1990s.³ The corresponding figures for cervical adenocarcinoma in situ

TERMINOLOGY OF PREMALIGNANT CERVICAL GLANDULAR LESIONS

The World Health Organisation (WHO), under the auspices of the International Society of Gynecological Pathologists, categorises premalignant endocervical glandular lesions as endocervical

Correspondence to:
Dr W G McCluggage,
Department of Pathology,
Royal Group of Hospitals
Trust, Grosvenor Road,
Belfast BT12 6BL, UK;
glenn.mccluggage@bll.ni.nhs.uk

Accepted for publication
17 October 2002

Abbreviations: AIS, adenocarcinoma in situ; AISM, atypical immature squamous metaplasia; CEA, carcinoembryonic antigen; CGIN, cervical glandular intraepithelial neoplasia; CIN, cervical intraepithelial neoplasia; EGD, endocervical glandular dysplasia; ER, oestrogen receptor; HCGIN, high grade cervical glandular intraepithelial neoplasia; HPV, human papillomavirus; LCGIN, low grade cervical glandular intraepithelial neoplasia; MDA, minimal deviation adenocarcinoma; MGH, microglandular hyperplasia; PAS, periodic acid Schiff; TEM, tubo-endometrial metaplasia; WHO, World Health Organisation

glandular dysplasia (EGD) (also known as atypical hyperplasia) and AIS.⁷ A category of glandular atypia is also included. This refers to atypical glandular epithelial changes, such as those associated with inflammation or previous radiotherapy, which are felt to be reactive and less severe than EGD. The WHO terminology is in widespread use in the USA and elsewhere. In the UK, the term cervical glandular intraepithelial neoplasia (CGIN) is in widespread use. The use of the CGIN terminology was endorsed in the publication "Histopathology reporting in cervical screening" which was produced by a working party of the Royal College of Pathologists and the National Health Service cervical screening programme.⁸ Using this terminology, CGIN is divided into two grades, low grade CGIN (LCGIN) and high grade CGIN (HCGIN). In this classification, HCGIN is usually synonymous with AIS and LCGIN with EGD. However, it is recognised that the two systems are not directly interchangeable, with some cases of HCGIN being included in the WHO category of EGD. Moreover, a three tier grading system for CGIN has been proposed,^{9 10} and some hybrid systems have evolved with categories of LCGIN, HCGIN, and AIS being used simultaneously. However, it is probably unrealistic to use more than two categories and it would be expected that using a three tier system would result in poor reproducibility.

In the remainder of this review the CGIN system will be used, with premalignant glandular lesions being categorised as LCGIN or HCGIN with the preface that HCGIN is generally synonymous with AIS and LCGIN with EGD. I would endorse the CGIN terminology because it is similar to the cervical intraepithelial neoplasia (CIN) system used for preinvasive cervical squamous lesions and takes account of the likelihood that there is a continuum of lesions from low to high grade. However, it is recognised that the use of different terminologies results in confusion among histopathologists and makes direct comparison of data between studies difficult. Furthermore, the CGIN terminology, which is widely used in the UK, is out of line with the WHO system, which is in widespread use throughout the rest of the world. These issues should be dealt with in the future. Other terms used to classify preinvasive neoplastic endocervical glandular lesions have included cervical intraepithelial glandular neoplasia, endocervical columnar cell intraepithelial neoplasia, and atypical endocervical hyperplasia.

MORPHOLOGICAL FEATURES OF CGIN

There is a popular misconception among pathologists and gynaecologists that CGIN often occurs high up the endocervical canal. However, in most, but not all, cases CGIN occurs close to the transformation zone. There is often an associated squamous intraepithelial lesion. Another popular misconception is that skip lesions are extremely common in CGIN. Skip lesions undoubtedly do occur but these are relatively rare, probably occurring in approximately 10–15% of patients.¹¹ In some cases, an impression of skip lesions may occur as a result of tangential cutting of the endocervical canal. Table 1 lists the morphological features of CGIN (which are more pronounced in HCGIN than LCGIN). Not all of these need be present in any individual case. There is often an abrupt transition from normal glands to glands involved by CGIN (fig 1) and this abrupt transition may be seen within individual glands. Both the surface epithelium and the underlying crypts may be involved. Most of the morphological features of CGIN are those expected with any premalignant lesion. Recent studies have drawn attention to the common occurrence of apoptotic bodies in CGIN (fig 2).^{12 13} Although not prominent in every case, their presence in appreciable numbers is useful in establishing a diagnosis. In fact, apoptotic bodies are more commonly seen in HCGIN than in invasive cervical adenocarcinoma.¹³ The presence of cribriform areas and of a microglandular growth pattern in CGIN is discussed below. Although these may occur

Table 1 Morphological features of cervical glandular intraepithelial neoplasia

Nuclear stratification and loss of polarity
Nuclear atypia and hyperchromasia
Macronucleoli
Loss of intracytoplasmic mucin
Increased mitotic activity
Atypical mitoses
Apoptotic bodies
Goblet cells (also neuroendocrine and Paneth cells)
Abrupt transition to normal

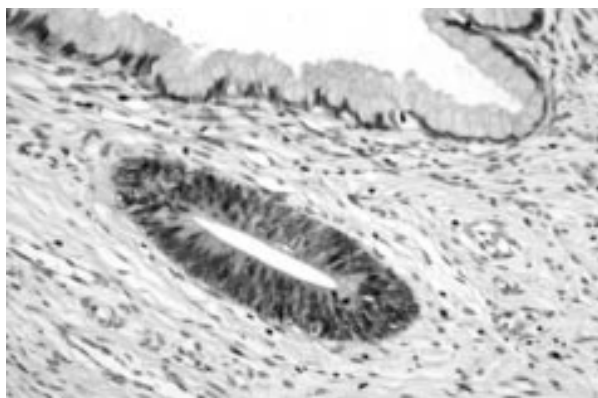


Figure 1 Abrupt transition between normal gland (above) and gland involved by high grade cervical glandular intraepithelial neoplasia (below).

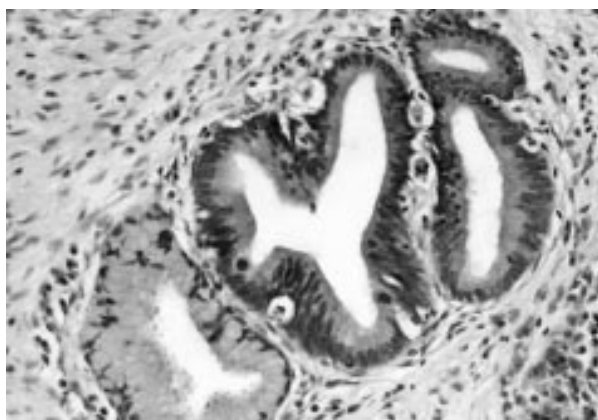


Figure 2 Cervical glandular intraepithelial neoplasia with easily identifiable apoptotic bodies.

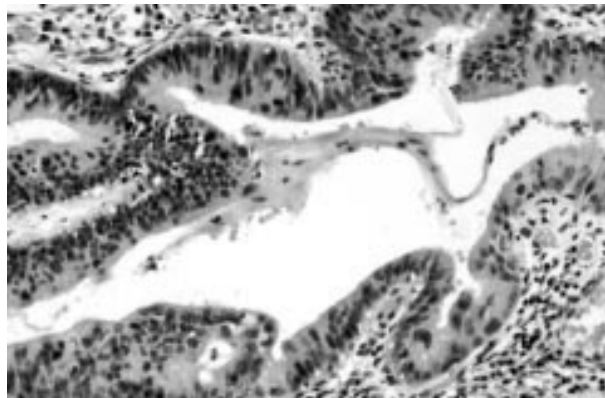
in CGIN, their presence (especially when extensive) should prompt consideration of an invasive lesion.

"Recent studies have drawn attention to the common occurrence of apoptotic bodies in cervical glandular intraepithelial neoplasia"

Most cases of CGIN are of usual endocervical type (fig 3). However, other rare variants have been described and are listed in table 2. An endometrioid variant of CGIN has been described. However, in my experience, this is rare (if it occurs at all) and most cases diagnosed as such are probably cases of usual endocervical-type CGIN with scant intracytoplasmic mucin (further discussed under "Morphological subtypes of cervical adenocarcinoma" below). An intestinal variant of CGIN exists and is relatively common. This is characterised by

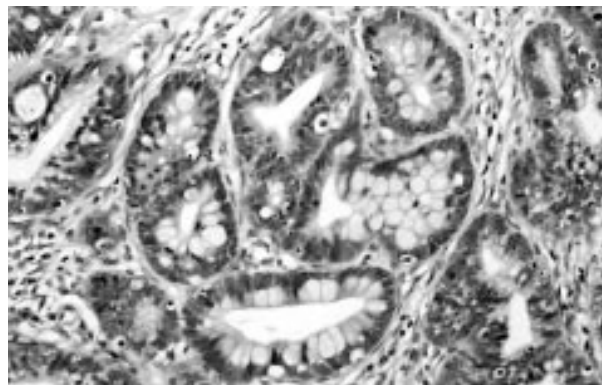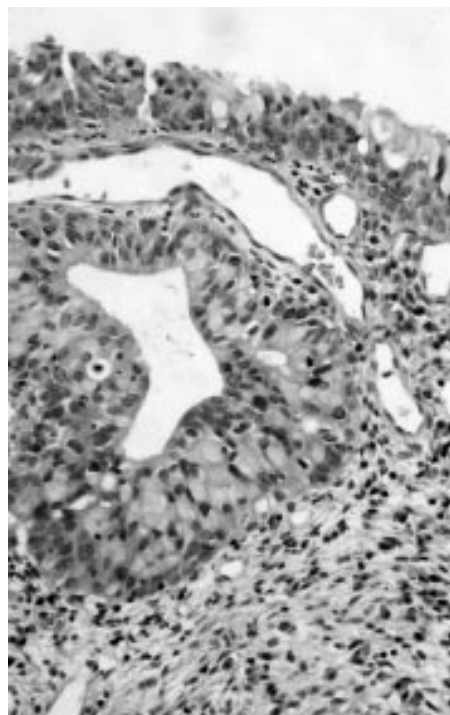
Table 2 Histological subtypes of cervical glandular intraepithelial neoplasia

Usual endocervical
Endometrioid
Intestinal
Ciliated
Serous
Clear cell
Stratified mucinous intraepithelial lesion

**Figure 3** Usual type of high grade cervical glandular intraepithelial neoplasia.

the presence of goblet cells (fig 4) and less commonly Paneth or neuroendocrine cells. It is doubtful whether intestinal differentiation in endocervical glands ever occurs without coexistent CGIN or invasive adenocarcinoma. Benign intestinal metaplasia involving endocervical glands has been described,¹⁴ but it is probably an extremely rare phenomenon, if it occurs at all, and the presence of goblet cells almost always indicates CGIN. A review of the photomicrographs in one paper describing intestinal metaplasia involving endocervical glands shows, in my opinion, nuclear changes characteristic of CGIN.¹⁴ A ciliated variant of CGIN has recently been described (designated endocervical adenocarcinoma in situ of tubal type).¹⁵ This variant of CGIN undoubtedly occurs but is rare. The cases described were associated with typical and atypical tubal metaplasia and with residual tubal morphology, in the form of apical cilia, in the areas of CGIN. The borderline between atypical tubal metaplasia and ciliated CGIN is not clear and undoubtedly atypical tubal metaplasia, which in most cases has no malignant potential, is much more common than the ciliated variant of CGIN.

A recently described variant of CGIN, which deserves mention, has been designated stratified mucinous intraepithelial lesion by Park and colleagues.¹⁶ This lesion is characterised by a multilayered epithelium resembling CIN. However, numerous cytoplasmic mucin globules are also present throughout the full thickness of the epithelium (fig 5), creating an appearance reminiscent of atypical immature squamous metaplasia (AISM). However, these lesions are associated with more extreme nuclear pleomorphism and hyperchromasia and a much higher proliferation index, as demonstrated by MIB1 immunostaining, than is the case with AISM. Moreover, these lesions are almost always associated with coexistent typical CIN or CGIN and also commonly with an invasive cervical carcinoma. This invasive component may be either squamous or glandular in type but adenocarcinoma is more common. Adenosquamous carcinoma may also be found. Park and colleagues have concluded that this is a form of reserve cell CGIN and is a marker of phenotypic instability.¹⁶ When

**Figure 4** Intestinal type of high grade cervical glandular intraepithelial neoplasia containing goblet cells.**Figure 5** Stratified mucinous intraepithelial lesion in which stratified epithelium resembling cervical intraepithelial neoplasia contains abundant mucin globules. In this case the lesion involves both the surface epithelium and an underlying endocervical gland.

confronted with such a lesion, especially in a small punch biopsy, the possibility of coexistent CIN, CGIN, or invasive carcinoma should always be considered.

A diagnosis of HCGIN is probably fairly reproducible, although in some cases distinction from early invasive adenocarcinoma (discussed below) may be problematic. However, clearly a diagnosis of LCGIN is more problematic and poorly reproducible. Indeed, many pathologists do not diagnose LCGIN in the absence of HCGIN. In my opinion, if a diagnosis of LCGIN is made, then it should be stated in the histopathology report that, given our present state of knowledge, the management should be similar to that of HCGIN. At present, the natural history of LCGIN is not known and there is some controversy as to whether this is a precursor lesion of HCGIN and invasive adenocarcinoma.^{17 18} Contrary to the situation with cervical squamous lesions, where CIN I is diagnosed more commonly than CIN III, with endocervical glandular lesions a diagnosis of HCGIN should be made more frequently than LCGIN, and in my practice it is rare to diagnose LCGIN in

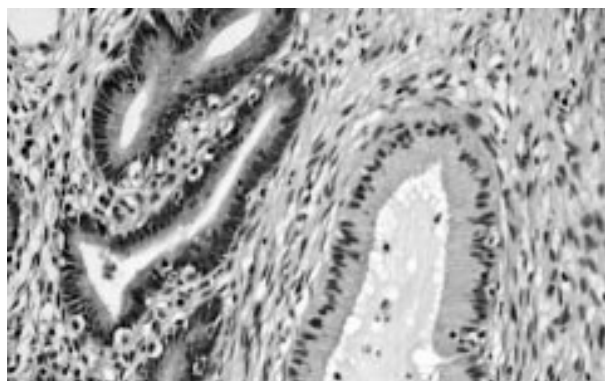


Figure 6 Low grade cervical glandular intraepithelial neoplasia in which there is mild nuclear atypia and easily identifiable mitotic figures and apoptotic bodies. The cytological features are less severe than in high grade cervical glandular intraepithelial neoplasia.

the absence of HCGIN. Benign mimics of CGIN must be carefully excluded before making a diagnosis of LCGIN. The morphological features of LCGIN are similar to those of HCGIN but are less severe (fig 6). Some authors have attempted to define precise diagnostic criteria for LCGIN (EGD).^{19–22} However, the criteria suggested are poorly reproducible, with some using features such as the degree of nuclear pleomorphism and the number of mitotic figures.^{19–21} It has also been proposed that when one gland shows features of AIS a diagnosis of EGD should be made.

“The natural history of low grade cervical glandular intraepithelial neoplasia (CGIN) is not known and there is some controversy as to whether this is a precursor lesion of high grade CGIN and invasive adenocarcinoma”

EARLY INVASIVE ADENOCARCINOMA

In recent years, there has been interest in the concept of early invasive cervical adenocarcinoma. I do not use the term “microinvasive adenocarcinoma” when referring to small (presumably early) invasive cervical adenocarcinomas. One reason for this is that the term microinvasive carcinoma does not appear in the FIGO staging system of cervical carcinomas,²³ and in different institutions microinvasive carcinoma is taken as being synonymous with stage 1a1 or all stage 1a carcinomas. However, a more important reason for not using the term microinvasive cervical adenocarcinoma is because the concept of microinvasion is that there is a minimal chance of lymph node metastasis and that conservative treatment, in the form of local excision, suffices. The risk of nodal metastasis related to depth of invasion in cervical squamous carcinomas is well established, but this information is not available for early invasive adenocarcinoma. Moreover, the allowable depth of invasion for early invasive or microinvasive cervical adenocarcinoma has varied between different studies, making direct comparisons of these difficult. Some have used a depth of invasion of 1, 2, or 3 mm or less and others 5 mm or less.^{24–31} Others have used volume measurements,³² and another definition proffered has been a depth of invasion that is too small to be measurable. Clearly, there is no consensus in the acceptable depth of invasion for a diagnosis of early cervical adenocarcinoma. Ostor undertook a meticulous review of several published series of early invasive cervical adenocarcinoma and combined these with a large series of cases that he personally viewed.³³ In this study, a depth of invasion of 5 mm or less was the definition used for early invasive adenocarcinoma. In those patients who had pelvic lymph node dissection, five of 219 (2%) had lymph node

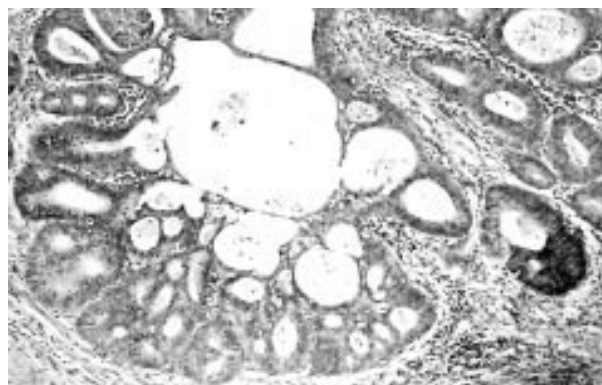


Figure 7 Confluent glandular pattern with cribriform areas. There is an associated stromal reaction. In this case a diagnosis of early invasive adenocarcinoma should be strongly considered.

metastasis. Of the 436 patients included in this study, there were 15 recurrences and six tumour related deaths. Twenty one patients had conisation as the only treatment and none suffered a recurrence. The author concluded that early invasive cervical adenocarcinoma behaves in the same way as its squamous counterpart and that conisation is acceptable treatment when the cone biopsy has been adequately sampled and the margins are free. It was further concluded that loop excision procedures were not acceptable, either for diagnosis or treatment. Many gynaecologists think that, because of the risk of skip lesions and lesions high up the endocervical canal (which as previously stated are not as common as generally thought), hysterectomy is necessary for HCGIN or early invasive cervical adenocarcinoma. However, although it is beyond the scope of this review to discuss in detail the management of HCGIN and early invasive adenocarcinoma it is clear that, in those who wish to preserve their fertility (HCGIN and early invasive adenocarcinoma often occur in young women), local excision with careful pathological examination and free margins combined with close cytological follow up may be used for treatment.^{34–39}

RECOGNITION OF EARLY INVASIVE ADENOCARCINOMA

The recognition of early invasion in HCGIN is more problematic than with squamous lesions. Indeed, the identification of early invasion in cervical glandular lesions may not always be possible, and in approximately 10–15% of patients the pathologist may be uncertain. It is often stated that CGIN is limited to the normal glandular field, whereas with invasive adenocarcinoma the glands extend beyond this field. However, because normal endocervical glands may have a complicated growth pattern and extend deep within the wall of the cervix this criterion is of limited value.

There are at least three morphological patterns of early invasive cervical adenocarcinoma, namely:

- (1) An obvious small adenocarcinoma.
- (2) Cases in which the glandular pattern becomes so complicated that the normal endocervical glandular field is obliterated, often resulting in a cribriform or solid appearance. In these cases, a stromal reaction in the form of oedema, desmoplasia, or an inflammatory infiltrate (fig 7) is a useful clue to the presence of early invasion, although this is not always present.
- (3) The presence of early stromal infiltration from glands involved by HCGIN of small buds of cells, often with a squamoid appearance (fig 8).²⁴

It is usually easy to recognise an obvious small adenocarcinoma. In addition, the presence of small buds of cells, often

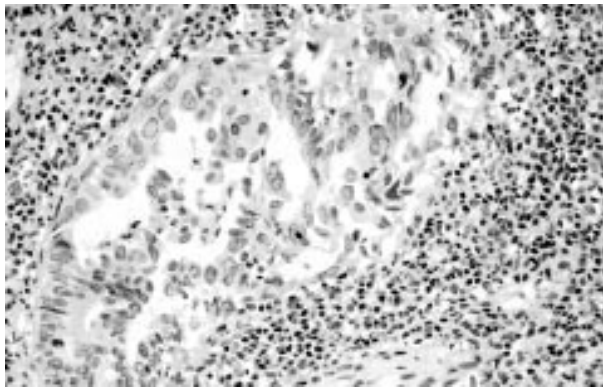


Figure 8 Early invasive adenocarcinoma in which small buds of cells with a squamoid appearance emanate from high grade cervical glandular intraepithelial neoplasia.

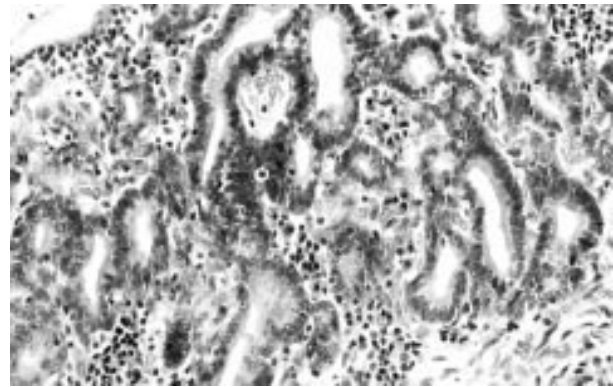


Figure 9 Microglandular growth pattern in high grade cervical glandular intraepithelial neoplasia (HCGIN). In other areas there was microglandular hyperplasia (MGH), suggesting involvement of MGH by HCGIN.

with a squamoid appearance, arising from HCGIN and infiltrating the stroma is usually easily recognised. However, there are problems with those cases where a diagnosis of invasion is considered based on the presence of a complicated confluent glandular pattern with obliteration of the normal endocervical field. Some pathologists equate pronounced cribriforming of glandular elements or solid formations with a diagnosis of early invasion, but undoubtedly cribriform or solid areas may be present in HCGIN. Indeed, in other organs, such as breast, the presence of a cribriform or solid growth pattern is widely accepted in the diagnosis of in situ, non-invasive lesions. However, when cribriform and/or solid areas are extremely prominent and confluent then a diagnosis of invasion should be strongly considered, especially if there is an associated stromal reaction. Loss of the normal smooth peripheral glandular outlines may also be a useful pointer that early invasion is present. It is stressed that in some cases it may be impossible to ascertain whether or not invasion is present. A microglandular growth pattern should also raise the possibility of an invasive lesion. However, a proviso is that CGIN may occasionally involve areas of microglandular hyperplasia (MGH) within the cervix (fig 9). In such cases, the presence of residual MGH not involved by CGIN is the key to establishing the diagnosis. However, clearly MGH may be totally obliterated by CGIN, creating obvious diagnostic difficulties. It should be noted that CGIN may also involve other benign endocervical glandular lesions, such as tunnel clusters.

“When cribriform and/or solid areas are extremely prominent and confluent then a diagnosis of invasion should be strongly considered, especially if there is an associated stromal reaction”

MEASUREMENT OF EARLY INVASIVE ADENOCARCINOMA

Measurement should be by calibrated optics. Clearly, it is straightforward to measure an obvious small invasive adenocarcinoma. In addition, in those cases of early stromal invasion from the base of CGIN, measurement of these foci is straightforward, although problems occur in those cases where there are multiple small foci of invasion. My practice is that if these invasive foci are clearly separate then each should be measured individually. However, if these multiple small foci are present close together within one area then the whole width and depth of the lesion should be measured. In cases where there is doubt whether to measure the whole lesion or just each individual focus of invasion, I err on the side of caution and measure the whole lesion. It is problematic to measure those cases of early invasive adenocarcinoma where a diagnosis of invasion is made on the presence of pronounced

glandular complexity. In these cases, the diagnosis is usually between florid HCGIN and early invasive adenocarcinoma. However, because normal endocervical glands may be present deep within the cervix and because these foci may extend over quite a wide area, if a diagnosis of invasion is made purely on architectural complexity with cribriforming or solid areas then when such foci are measured the depth or width of invasion may exceed 5 mm or 7 mm, respectively. Consequently, where initially the problem was in deciding whether or not invasive foci were present, measurement of the entire lesion may result in a diagnosis of a stage 1b1 cervical adenocarcinoma. I feel that caution should be exercised and that measurement of the lesion should be from the luminal surface to the deepest aspect of the lesion and from one lateral aspect to another, even though this may result in an overestimate of the size of the tumour. Therefore, as with malignant melanoma, it is tumour thickness rather than depth of invasion that is being measured. As with squamous lesions, a diagnosis of early invasive adenocarcinoma should not be made when carcinoma or CGIN is present at the margin of a biopsy or when the surface is ulcerated, because in this instance it is impossible to ascertain how much tissue has been lost.

It is recognised that commonly used staging systems for cervical cancer, such as the FIGO²³ and SGO⁴⁰ systems, offer little guidance on how to measure cancers, both squamous and glandular. It would be desirable for this to be rectified, and when such systems are being updated guidance should be given on problematic aspects of measuring invasion in cervical carcinomas.

MORPHOLOGICAL SUBTYPES OF CERVICAL ADENOCARCINOMA

This subject has been reviewed previously⁴⁻⁶ and will not be discussed in detail here. Table 3 provides a classification of cervical adenocarcinomas. A few selected points on morphological subtypes of cervical adenocarcinoma will be discussed.

Endometrioid adenocarcinomas occur within the cervix. However, in my experience, endometrioid variants of cervical adenocarcinoma are overdiagnosed. In some institutions, endometrioid adenocarcinomas account for up to 50% of cervical adenocarcinomas,⁴¹⁻⁴² whereas in other institutions this diagnosis is rarely made. I feel that this is probably because some pathologists will diagnose an endometrioid-type adenocarcinoma when there is pronounced depletion of intracytoplasmic mucin. However, in my opinion these neoplasms are identical to the usual endocervical-type adenocarcinoma, except that intracytoplasmic mucin is minimal. This point has been emphasised recently.⁶ An additional point is that with endometrioid adenocarcinomas of the endometrium and

Table 3 Classification of cervical adenocarcinoma

Usual endocervical adenocarcinoma (variant: villoglandular adenocarcinoma)
Mucinous adenocarcinoma (variant: minimal deviation adenocarcinoma)
Endometrioid adenocarcinoma (variant: minimal deviation adenocarcinoma)
Serous adenocarcinoma
Clear cell adenocarcinoma
Intestinal-type adenocarcinoma
Signet ring adenocarcinoma
Mesonephric adenocarcinoma
Adenoid basal carcinoma
Adenoid cystic carcinoma
Mixed adenocarcinoma
Metastatic adenocarcinoma

ovary, benign squamous elements are common. However, these are rarely seen in those cervical adenocarcinomas that are diagnosed as endometrioid in type.

"In my experience, endometrioid variants of cervical adenocarcinoma are overdiagnosed"

Villoglandular adenocarcinoma is a variant of endocervical adenocarcinoma, often found in young women and characterised by the formation of complex branching papillary processes with fibrous cores.⁴³⁻⁴⁴ Often, the gross appearance is of a polypoid lesion, and the prognosis is better than for other cervical adenocarcinomas. A diagnosis of villoglandular adenocarcinoma should be reserved for those cases in which there is a pronounced villous-like growth pattern and low grade cytological features. A papillary pattern, which may be prominent, is common on the surface of many ordinary endocervical adenocarcinomas and some of these may be deeply invasive. True villoglandular adenocarcinomas are often only superficially invasive, although some may invade deeply. The diagnosis can be suggested on small biopsies but a definitive diagnosis can only be made on a loop or cone biopsy or hysterectomy specimen. Villoglandular adenocarcinoma should be distinguished from serous papillary adenocarcinoma, which has much more pronounced nuclear atypia, similar to the corresponding tumour within the endometrium or ovary.⁴⁵

Ancillary studies useful in the diagnosis of the mucinous variant of MDA and mesonephric adenocarcinoma are discussed later.

ANCILLARY TECHNIQUES USEFUL IN DISTINCTION OF MALIGNANT AND PREMALIGNANT LESIONS FROM BENIGN MIMICS

A wide variety of benign endocervical glandular lesions may be confused with CGIN and even invasive cervical adenocarcinoma, especially the mucinous variant of MDA.⁴⁶⁻⁴⁷ These are listed in table 4 and have been reviewed elsewhere.⁴⁻⁶ They will not be described in detail here. Many of these benign mimics are rare and in everyday practice the lesions most likely to be confused with CGIN are tubo-endometrial metaplasia (TEM) and endometriosis. TEM is extremely common in the cervix, especially after loop or cone biopsy or some other operative procedure.⁴⁸⁻⁴⁹ The presence of cilia is a useful diagnostic clue to TEM, but these may be absent or inconspicuous, especially in cases showing endometrioid differentiation. In addition, as previously discussed, a ciliated variant of CGIN has been described.¹⁵ Moreover, cervical TEM, especially when associated with a previous operative procedure, may have an altered stroma,⁵⁰ raising the possibility of a desmoplastic reaction. Endometriosis within the superficial cervix may also cause

Table 4 Benign glandular mimics of cervical glandular intraepithelial neoplasia and adenocarcinoma

Tubo-endometrial metaplasia
Endometriosis
Microglandular hyperplasia
Inflammatory atypia
Mesonephric remnants/hyperplasia
Lobular endocervical glandular hyperplasia, not otherwise specified
Diffuse laminar endocervical glandular hyperplasia
Tunnel clusters
Deep cervical glands/cysts
Endocervicosis
Atypical oxyphil metaplasia
Adenomyoma
Radiation effects
Ectopic prostate
Arias-Stella effect
Florid cystic endosalpingiosis
Cautery artefact
Mullerian papilloma
Villous adenoma

diagnostic problems, especially when the characteristic stroma is inconspicuous.⁵¹ Fibrosis, caused by previous episodes of haemorrhage, may result in consideration of a desmoplastic stromal reaction. MGH is also common within the cervix.⁵² Although most cases are easily recognised, atypical features may be found, including the presence of signet ring cells, stromal hyalinisation, or a lace-like growth pattern.⁵³ These features may cause confusion with invasive cervical adenocarcinoma, especially of the clear cell type.

Immunohistochemical staining using a panel of antibodies, namely—MIB1, bcl2, and p16—may be extremely useful in problematic cases in distinguishing these benign mimics from HCGIN or invasive adenocarcinoma,⁵⁴ although it is stressed that careful morphological examination is the mainstay of diagnosis. The proliferation marker MIB1, which reacts with the Ki-67 antigen, has been shown to be a useful adjunct to histology in distinguishing HCGIN from benign mimics.⁵⁵⁻⁵⁸ A proliferation index of > 30% is generally indicative of HCGIN, whereas most cases of TEM, endometriosis, and MGH exhibit a proliferation index of < 10%. However, there may be some overlap, with occasional cases of HCGIN also exhibiting a proliferation index of < 10%. In addition, in some studies occasional benign lesions have exhibited a proliferation index of up to 50%.⁵⁸ In general, however, there are great differences in the MIB1 index between TEM, endometriosis, and HCGIN. Characteristically, many positive nuclei are present in HCGIN (fig 10A), with only scattered immunoreactivity in benign lesions (fig 10B).

Immunohistochemical staining for bcl2 may also be useful in distinguishing TEM and endometriosis from HCGIN.⁵⁴⁻⁵⁹⁻⁶⁰ Bcl2 is a proto-oncogene, located on chromosome 18, which encodes a 25 kDa protein mainly localised to the inner mitochondrial membrane.⁶¹ This extends cell survival by blocking apoptosis.⁶¹ In recent studies, we have found that cervical TEM and endometriosis (but not MGH) show consistent cytoplasmic expression of bcl2 (fig 11).⁵⁴⁻⁵⁹⁻⁶⁰ Most cases of CGIN are negative. Why cervical TEM and endometriosis should exhibit positive staining for bcl2 is not certain but interestingly there is strong positive staining of normal fallopian tube epithelial cells⁶² and of proliferative endometrium with antibodies to bcl2.⁶³ Of course, TEM and endometriosis are morphologically similar to normal fallopian tube and normal proliferative endometrium, respectively.

In the distinction of benign mimics from HCGIN, p16 staining may also be of value.⁵⁴ The cyclin dependent kinase 4 inhibitor, also known as p16, is the product of the INK4a gene

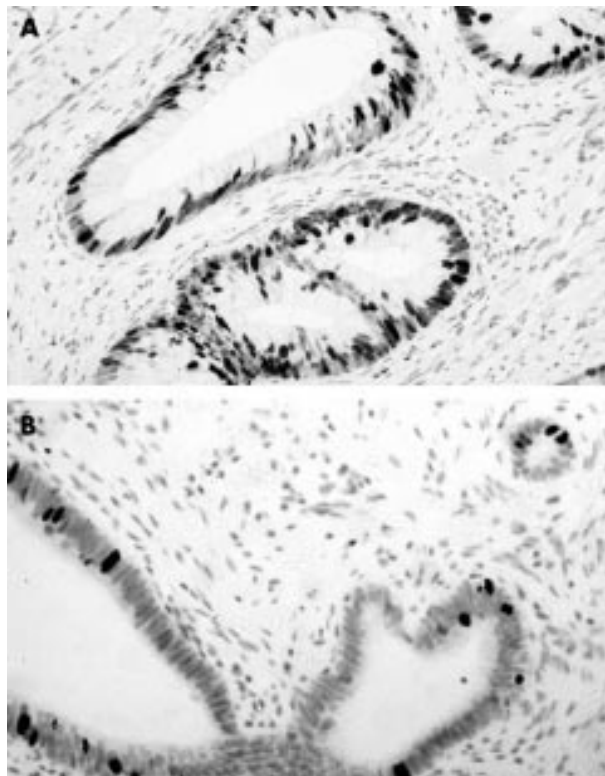


Figure 10 (A) High grade cervical glandular intraepithelial neoplasia where many nuclei are positive with the MIB1 antibody. (B) In a case of tubo-endometrial metaplasia only scattered nuclei are positive.

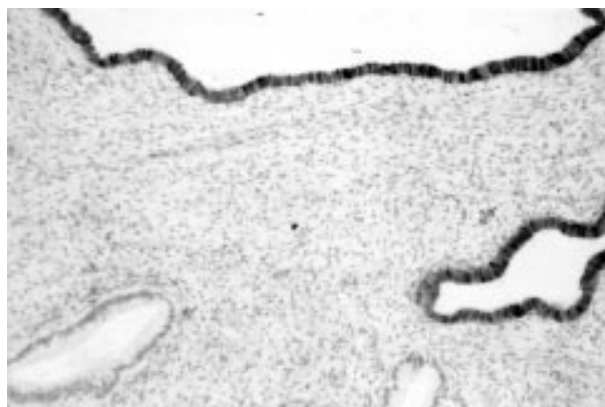


Figure 11 Tubo-endometrial metaplasia exhibits diffuse strong cytoplasmic positivity for bcl2.

and specifically binds to cyclin D–cyclin dependent kinase 4/6 complexes to control the cell cycle at the G1–S interphase. Recent studies have shown overexpression of p16 in high grade cervical squamous intraepithelial lesions and in low grade lesions associated with high risk human papillomavirus (HPV) types.^{64–65} p16 overexpression seems to be related to the presence of high risk HPV types. In a recent study, we found consistent positive staining of HCGIN (involving 100% of cells) with antibodies to p16 (fig 12).⁵⁴ In contrast, cells of MGH were negative. Staining of TEM and endometriosis was common but this was always focal and completely different to the pattern of immunoreactivity found in HCGIN. Thus, the combination of p16, MIB1, and bcl2 may be extremely useful in separating these benign mimics from HCGIN. The situation with LCGIN has not been well studied and further work is necessary to ascertain whether these antibodies are of value in

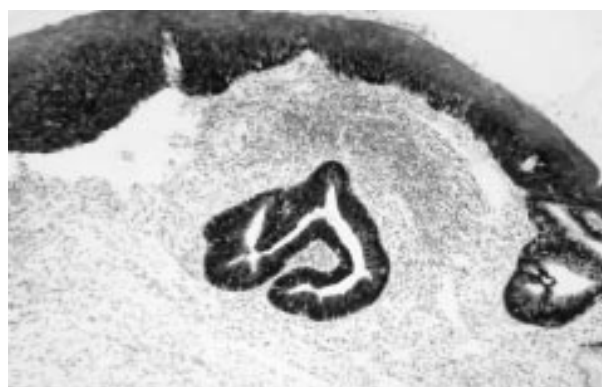

Figure 12 High grade cervical glandular intraepithelial neoplasia exhibiting diffuse strong positivity for p16. Surface cervical intraepithelial neoplasia III is also diffusely positive.

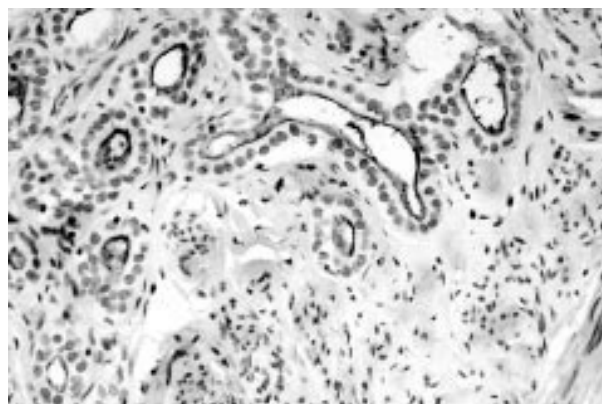


Figure 13 Positive luminal staining of cervical mesonephric remnants for CD10.

the separation of LCGIN from benign mimics. It is stressed that, in all cases, these antibodies are only of ancillary use and that careful morphological examination remains the cornerstone of diagnosis.

Other studies have found that a combination of carcinoembryonic antigen (CEA), MIB1, and p53 staining is useful in discriminating between benign and malignant endocervical glandular lesions.⁵⁷ Immunohistochemical expression of the transmembrane glycoprotein CD44 has also been investigated in endocervical glandular lesions.⁶⁶ The conclusion of this study was that CD44 variant 5 immunoreactivity may be a useful marker of endocervical neoplasia.⁶⁶ The value of ancillary studies in the diagnosis of endocervical glandular lesions has recently been reviewed elsewhere.⁶⁷

ANCILLARY STUDIES USEFUL IN DISTINCTION BETWEEN ENDOCERVICAL AND ENDOMETRIAL ADENOCARCINOMA

Occasionally in preoperative specimens, adenocarcinoma is present in both endometrial and endocervical biopsies and determining the site of the primary tumour is difficult. Even in the subsequent hysterectomy specimen, it may not be clear as to the site of tumour origin. This is of importance because adjuvant treatments may differ depending on whether the tumour is of endometrial or endocervical origin and the choice of primary surgery may also differ. Clues to a primary endometrial lesion include the presence of adjacent atypical endometrial hyperplasia or the presence of benign squamous elements or stromal foam cells. A primary endocervical tumour is favoured when there is adjacent CGIN or CIN. The combination of staining for vimentin, oestrogen receptor

Take home messages

- There is evidence that there is a real increase in the incidence of malignant and premalignant endocervical glandular lesions, which are thus assuming increasing importance in diagnostic surgical pathology
- In most, but not all, cases cervical glandular intraepithelial neoplasia (CGIN) occurs close to the transformation zone and there is often an associated squamous intraepithelial lesion
- The identification of early invasion in cervical glandular lesions may not always be possible and in 10–15% of cases the pathologist may be uncertain
- A wide variety of benign endocervical glandular lesions can be confused with CGIN and even invasive cervical adenocarcinoma, particularly the mucinous variant of minimal deviation adenocarcinoma
- Immunohistochemical staining using a panel of antibodies, namely—MIB1, bcl2, and p16—may be useful in problematic cases in distinguishing benign mimics from high grade CGIN or invasive carcinoma, although it is stressed that careful morphological examination is the mainstay of diagnosis
- Staining for a combination of vimentin, the oestrogen receptor, and carcinoembryonic antigen may assist in the distinction between an endometrial and an endocervical adenocarcinoma

(ER), and CEA may assist in this distinction.^{68–69} In general, primary endometrial adenocarcinomas of endometrioid type are strongly vimentin and ER positive and negative for CEA. However, some cases may be focally positive for CEA and there is often strong positive staining of benign squamous elements. In contrast, typical endocervical adenocarcinomas are often, but not always, CEA positive and are negative for vimentin. ER is usually negative or there may be focal weak positivity. However, the situation with mucinous adenocarcinoma of the endometrium and endometrioid adenocarcinoma of the cervix is less clear. As already discussed, I feel that endometrioid adenocarcinomas of the cervix are overdiagnosed. A recent study has investigated whether the immunophenotype of mucinous adenocarcinoma of the endometrium and endometrioid adenocarcinoma of the cervix is more dependent upon the site of origin or the pattern of differentiation.⁷⁰ This study found that ER positivity was more dependent on the site of origin, being more common in endometrial than cervical tumours, whereas vimentin positivity was more dependent on differentiation, being more common in endometrioid than mucinous tumours. This study concluded that if there was strong positive staining for vimentin and ER the tumour was almost certainly of endometrial origin.⁷⁰

“In general, primary endometrial adenocarcinomas of endometrioid type are strongly vimentin and oestrogen receptor positive and negative for carcinoembryonic antigen”

A recent study performed by us has shown that p16 may also be of some value in distinguishing between an endocervical and an endometrial adenocarcinoma.⁷¹ Strong diffuse positivity involving 100% of cells is the rule in primary endocervical adenocarcinoma, whereas endometrial adenocarcinoma usually exhibits a lesser degree of staining. However, occasional endometrial adenocarcinomas will exhibit diffuse positivity and there is often strong staining of benign squamous elements for p16. Further studies are necessary to refine the diagnostic use of p16 immunostaining in this situation and to ascertain whether those endometrial adeno-

carcinomas that exhibit diffuse positivity are associated with high risk HPV types.

ANCILLARY STUDIES USEFUL IN DIAGNOSIS OF CERVICAL MESONEPHRIC LESIONS

Mesonephric remnants are common within the cervix, characteristically deep within the cervical stroma and with a lateral location. However, mesonephric remnants, especially when hyperplastic, may extend close to the luminal surface of the cervix and may be intermingled with normal endocervical glands.^{72–73} I have even identified mesonephric glands within cervical punch biopsies. In addition, rarely, cervical mesonephric adenocarcinomas may occur.^{74–75} Again, these are usually situated deep within the cervix with a lateral location and there may be adjacent mesonephric hyperplasia. These tumours often have a tubular or an endometrioid appearance and a spindle cell component may be present,⁷⁴ indicating a variant of cervical carcinosarcoma. Cervical mesonephric hyperplasia and adenocarcinoma may both cause diagnostic difficulties, the former in the separation from other benign mimics and from adenocarcinoma (especially MDA) and the latter in the recognition of this as a special subtype of cervical adenocarcinoma. A recent immunohistochemical study investigated CD10 staining in cervical mesonephric remnants and adenocarcinomas.⁷⁶ In this study, consistent positive staining of cervical mesonephric lesions for CD10 with a characteristic luminal staining pattern was found (fig 13). In the cervix, CD10 positivity of benign glandular elements appears to be relatively specific for mesonephric derivatives, with little or no staining of normal endocervical glands or of other benign mimics, although some ordinary endocervical adenocarcinomas may be focally positive (personal unpublished data).

ANCILLARY STUDIES USEFUL IN DIAGNOSIS OF CERVICAL MDA

Cervical MDA is an extremely well differentiated adenocarcinoma, which can be confused with a variety of benign mimics. An endometrioid variant exists,^{77–78} but cervical MDA is most commonly mucinous in type, with this variant being known as adenoma malignum.⁷⁹ Recent studies have shown that gastric mucins are present in cervical adenoma malignum and that HIK1083, a monoclonal antibody against gastric gland mucous cell mucin, is useful in the diagnosis of this neoplasm.^{80–82} Normal endocervical glands are negative, although very small foci of positivity may be found in ordinary endocervical adenocarcinomas. Thus, HIK1083 staining may be useful in discriminating between benign endocervical glands and the well differentiated glands of adenoma malignum. Interestingly, the benign endocervical glandular lesion termed lobular endocervical glandular hyperplasia,⁸³ which may mimic adenoma malignum, is now also thought to have a pyloric gland phenotype on the basis of histochemical staining and immunohistochemistry with antibodies against pyloric gland-type mucins.⁸⁴

“In doubtful cases, a combined Alcian blue–periodic acid Schiff stain may be useful in distinguishing normal endocervical glands from the glands of adenoma malignum”

Histochemical stains may also be useful in the diagnosis of cervical adenoma malignum. A combined Alcian blue–periodic acid Schiff (PAS) stain may be useful because normal endocervical glands, as a result of their high content of acid and neutral mucins, stain a purple/violet colour.⁸⁵ In contrast, the glands of cervical adenoma malignum (and conventional adenocarcinomas) stain red using this preparation because of the almost exclusive presence of neutral mucin.⁸⁵ In doubtful

cases, a combined Alcian blue–PAS stain may be useful in distinguishing normal endocervical glands from the glands of adenoma malignum. However, it is stressed that in most such instances appreciation of the overall architecture of the lesion with deep invasion of the cervical stroma, the presence of a stromal desmoplastic reaction, and the presence of focal areas of atypia on adequate sampling will usually allow a correct diagnosis. Vascular or perineural infiltration, when present, are also helpful pointers that one is dealing with a malignant lesion.

REFERENCES

- 1 Leminen A, Paavonen J, Forss M, *et al*. Adenocarcinoma of the uterine cervix. *Cancer* 1990;**65**:53–9.
- 2 Hopkins MP, Morley GW. A comparison of adenocarcinoma and squamous cell carcinoma of the cervix. *Obstet Gynecol* 1991;**77**:912–17.
- 3 Hemminki K, Li X, Vaitinen P. Time trends in the incidence of cervical and other genital squamous cell carcinomas and adenocarcinomas in Sweden, 1958–1996. *Eur J Obstet Gynecol Reprod Biol* 2002;**101**:64–9.
- 4 McCluggage WG. Glandular lesions of the uterine cervix. *Current Diagnostic Pathology* 2000;**6**:1–12.
- 5 Anderson MC, Robboy SJ. Glandular lesions of the cervix. *Current Diagnostic Pathology* 1996;**3**:99–108.
- 6 Young RH, Clement PB. Endocervical adenocarcinoma and its variants: their morphology and differential diagnosis. *Histopathology* 2002;**41**:185–207.
- 7 Kurman RJ, Norris HJ, Wilkinson EJ. Tumours of the cervix. In: Rosai J, Sobin LH, eds. *Tumours of the cervix, vagina and vulva*. Atlas of tumor pathology, 3rd series, Fascicle 4. Washington: Armed Forces Institute of Pathology.
- 8 *Histopathology reporting in cervical screening*. NHSCSP Publication, No 10. London: NHSCSP, April 1999.
- 9 Gloor E, Hurlmann J. Cervical intraepithelial glandular neoplasia (adenocarcinoma in situ and glandular dysplasia). *Cancer* 1986;**58**:1272–80.
- 10 Brown LJR, Wells M. Cervical glandular atypia associated with squamous intraepithelial neoplasia: a premalignant lesion? *J Clin Pathol* 1986;**39**:22–8.
- 11 Zaino RJ. Adenocarcinoma in situ, glandular dysplasia and early invasive adenocarcinoma of the uterine cervix. *Int J Gynecol Pathol* 2002;**21**:314–26.
- 12 Biscotti CV, Hart WR. Apoptotic bodies. A consistent morphologic feature of endocervical adenocarcinoma in situ. *Am J Surg Pathol* 1998;**22**:434–9.
- 13 Moritani S, Ioffe OB, Sagae S, *et al*. Mitotic activity and apoptosis in endocervical glandular lesions. *Int J Gynecol Pathol* 2002;**21**:125–33.
- 14 Trowell JE. Intestinal metaplasia with argentaffin cells in the uterine cervix. *Histopathology* 1985;**9**:551–9.
- 15 Schlesinger C, Silverberg SG. Endocervical adenocarcinoma in situ of tubal type and its relation to atypical tubal metaplasia. *Int J Gynecol Pathol* 1999;**18**:1–4.
- 16 Park JJ, Sun D, Quade BJ, *et al*. Stratified mucin-producing intraepithelial lesions of the cervix. Adenosquamous or columnar cell neoplasia? *Am J Surg Pathol* 2000;**24**:1414–19.
- 17 Kurian K, Al-Nafussi A. Relation of cervical glandular intraepithelial neoplasia to microinvasive and invasive adenocarcinoma of the uterine cervix. A study of 121 cases. *J Clin Pathol* 1999;**52**:112–17.
- 18 Goldstein NS, Ahmad E, Hussain M, *et al*. Endocervical glandular atypia. Does a preneoplastic lesion of adenocarcinoma in situ exist? *Am J Clin Pathol* 1998;**110**:200–9.
- 19 Jaworski R. Endocervical glandular dysplasia, adenocarcinoma in situ and early invasive (microinvasive) adenocarcinoma of the uterine cervix. *Semin Diagn Pathol* 1990;**7**:190–205.
- 20 Casper G, Ostor A, Quinn M. A clinicopathologic study of glandular dysplasia of the cervix. *Gynecol Oncol* 1997;**64**:166–70.
- 21 Gompel C, Silverberg SG. *Pathology in gynecology and obstetrics*. Philadelphia: Lippincott, 1994.
- 22 Brown LJ, Wells M. Cervical glandular atypia associated with squamous intraepithelial neoplasia: a premalignant lesion? *J Clin Pathol* 1986;**39**:22–8.
- 23 FIGO News. Modifications in the staging for stage I vulvar and stage I cervical cancer: report of the FIGO committee on gynecologic oncology. *Int J Gynecol Obstet* 1995;**50**:215–16.
- 24 Rollason TP, Cullimore J, Bradgate MG. A suggested columnar cell morphological equivalent of squamous carcinoma in situ with early stromal invasion. *Int J Gynecol Pathol* 1989;**8**:230–6.
- 25 Matzukuma K, Tsukamoto N, Kaku T, *et al*. Early adenocarcinoma of the uterine cervix—its histologic and immunohistologic study. *Gynecol Oncol* 1989;**35**:38–43.
- 26 Schorge JO, Lee KR, Flynn CE, *et al*. Stage IA1 cervical adenocarcinoma: definition and treatment. *Obstet Gynecol* 1999;**93**:219–22.
- 27 Qizilbash AH. In-situ and microinvasive adenocarcinoma of the uterine cervix: a clinical, cytologic and histologic study of 14 cases. *Am J Clin Pathol* 1975;**64**:155–70.
- 28 Teshima S, Shimosato Y, Kishi K, *et al*. Early stage adenocarcinoma of the uterine cervix: histologic analysis with consideration of histogenesis. *Cancer* 1985;**56**:167–72.
- 29 Kaku T, Kamura T, Sakai K, *et al*. Early adenocarcinoma of the uterine cervix. *Gynecol Oncol* 1997;**65**:281–5.
- 30 Ostor AG, Rome R, Quinn M. Microinvasive adenocarcinoma of the cervix: a clinicopathologic study of 77 women. *Obstet Gynecol* 1997;**89**:88–93.
- 31 Nicklin JL, Perrin LC, Crandon AJ, *et al*. Microinvasive adenocarcinoma of the cervix. *Aust N Z J Obstet Gynaecol* 1999;**39**:411–13.
- 32 Burghardt E, Holzer E. Diagnosis and treatment of microinvasive carcinoma of the cervix uteri. *Obstet Gynecol* 1977;**49**:641–53.
- 33 Ostor AG. Early invasive adenocarcinoma of the uterine cervix. *Int J Gynecol Pathol* 2000;**19**:29–38.
- 34 Krivak TC, Rose GS, McBroom JW, *et al*. Cervical adenocarcinoma in situ: a systematic review of therapeutic options and predictors of persistent or recurrent disease. *Obstet Gynecol Surv* 2001;**56**:567–75.
- 35 Shipman SD, Bristow RE. Adenocarcinoma in situ and early invasive adenocarcinoma of the uterine cervix. *Curr Opin Oncol* 2001;**13**:394–8.
- 36 McHale MT, Lee TD, Burger RA, *et al*. Fertility sparing treatment for in situ and early invasive adenocarcinoma of the cervix. *Obstet Gynecol* 2001;**98**:726–31.
- 37 Soutter WP, Haidopoulos D, Gornall RJ, *et al*. Is conservative therapy for adenocarcinoma in situ of the cervix safe? *Br J Obstet Gynaecol* 2001;**108**:1184–9.
- 38 Sheets EE. Management of adenocarcinoma in situ, microinvasive and early stage adenocarcinoma of the cervix. *Curr Opin Obstet Gynecol* 2002;**14**:53–9.
- 39 Houghton SJ, Shafi MI, Rollason TP, *et al*. Is loop excision adequate primary management of adenocarcinoma in situ of the cervix? *Br J Obstet Gynaecol* 1997;**104**:325–9.
- 40 Creasman WT, Parker RT. Microinvasive carcinoma of the cervix. *Clin Obstet Gynecol* 1973;**16**:261–75.
- 41 Zaino RJ. The fruits of our labors: distinguishing endometrial from endocervical adenocarcinoma. *Int J Gynecol Pathol* 2001;**21**:1–3.
- 42 Alfsen GC, Thoresen SO, Kristensen GB, *et al*. Histopathologic subtyping of cervical adenocarcinoma reveals increasing incidence rates of endometrioid tumors in all age groups. *Cancer* 2000;**89**:1291–9.
- 43 Young RH, Scully RE. Villoglandular papillary adenocarcinoma of the uterine cervix. A clinicopathologic analysis of 13 cases. *Cancer* 1989;**63**:1773–9.
- 44 Jones MW, Silverberg SG, Kurman RJ. Well-differentiated villoglandular adenocarcinoma of the uterine cervix—a clinicopathological study of 24 cases. *Int J Gynecol Pathol* 1993;**12**:1–7.
- 45 Zhou C, Gilks CG, Hayes M, *et al*. Papillary serous carcinoma of the uterine cervix: a clinicopathologic study of 17 cases. *Am J Surg Pathol* 1998;**22**:113–20.
- 46 Young RH, Clement PB. Pseudoneoplastic glandular lesions of the uterine cervix. *Semin Diagn Pathol* 1991;**8**:234–49.
- 47 Nucci MR. Tumor-like lesions of the uterine cervix. *Int J Gynecol Pathol* 2002;**21**:347–59.
- 48 Ismail SM. Cone biopsy causes cervical endometriosis and tuboendometrioid metaplasia. *Histopathology* 1991;**18**:107–14.
- 49 Al-Nafussi A, Rahilly M. The prevalence of tuboendometrioid metaplasia and adenomatoid proliferation. *Histopathology* 1993;**22**:177–9.
- 50 Oliva E, Clement PB, Young RH. Tubal and tubo-endometrioid metaplasia of the uterine cervix. Unemphasised features that may cause problems in differential diagnosis. A report of 25 cases. *Am J Clin Pathol* 1995;**103**:618–23.
- 51 Baker PM, Clement PB, Bell DA, *et al*. Superficial endometriosis of the uterine cervix: a report of 20 cases of a process that may be confused with endocervical glandular dysplasia or adenocarcinoma in situ. *Int J Gynecol Pathol* 1999;**18**:198–205.
- 52 Greeley C, Schroeder S, Silverberg SG. Microglandular hyperplasia of the cervix: a true “pill” lesion? *Int J Gynecol Pathol* 1995;**14**:50–4.
- 53 Young RH, Scully RE. Atypical forms of microglandular hyperplasia of the cervix simulating carcinoma: a report of five cases and review of the literature. *Am J Surg Pathol* 1989;**13**:50–6.
- 54 Cameron RI, Maxwell P, Jenkins D, *et al*. Immunohistochemical staining with MIB1, bcl-2 and p16 assists in the distinction of cervical glandular intraepithelial neoplasia from tubo-endometrioid metaplasia, endometriosis and microglandular hyperplasia. *Histopathology* 2002;**41**:313–21.
- 55 McCluggage WG, Maxwell P, McBride HA, *et al*. Monoclonal antibodies Ki-67 and MIB1 in the distinction of tuboendometrioid metaplasia from endocervical adenocarcinoma and adenocarcinoma in situ in formalin-fixed material. *Int J Gynecol Pathol* 1995;**14**:209–16.
- 56 van Hoeven KH, Ramondetta L, Kovatich AJ, *et al*. Quantitative image analysis of MIB1 reactivity in inflammatory, hyperplastic and neoplastic endocervical lesions. *Int J Gynecol Pathol* 1997;**16**:15–21.
- 57 Cina SJ, Richardson MS, Austin RM, *et al*. Immunohistochemical staining for Ki-67 antigen, carcinoembryonic antigen, and p53 in the differential diagnosis of glandular lesions of the cervix. *Mod Pathol* 1997;**10**:176–80.
- 58 Pirog EC, Isacson C, Szabolcs MJ, *et al*. Proliferative activity of benign and neoplastic endocervical epithelium and correlation with HPV DNA detection. *Int J Gynecol Pathol* 2001;**21**:22–6.
- 59 McCluggage WG, Maxwell P, Bharucha H. Immunohistochemical detection of p53 and bcl-2 proteins in neoplastic and non-neoplastic endocervical glandular lesions. *Int J Gynecol Pathol* 1997;**16**:22–7.

- 60 **McCluggage WG**, Maxwell P. Bcl-2 and p21 immunostaining of cervical tubo-endometrial metaplasia. *Histopathology* 2002;**40**:107–8.
- 61 **Hockenberry D**, Nunez G, Millinan C, *et al*. Bcl-2 is an inner mitochondrial membrane protein that blocks programmed cell death. *Nature* 1990;**348**:334–46.
- 62 **Piek JMJ**, van Diest PJ, Verheijen RHM, *et al*. Cell cycle-related proteins p21 and bcl-2: markers of differentiation in the human fallopian tube. *Histopathology* 2001;**38**:481–2.
- 63 **Henderson GS**, Brown KA, Perkins SL, *et al*. Bcl-2 is down regulated in atypical endometrial hyperplasia and adenocarcinoma. *Mod Pathol* 1996;**9**:430–6.
- 64 **Keating JT**, Cviko A, Reithdorf S, *et al*. Ki-67, cyclin E and p16 (INK4) are complimentary surrogate biomarkers for human papilloma virus-related cervical neoplasia. *Am J Surg Pathol* 2001;**25**:894–8.
- 65 **Klaes R**, Friedrich T, Spitkovsky D, *et al*. Overexpression of p16 (INK4A) as a specific marker for dysplastic and neoplastic epithelial cells of the cervix uteri. *Int J Cancer* 2001;**92**:276–84.
- 66 **Ibrahim EM**, Blackett AD, Tidy JA, *et al*. CD44 is a marker of endocervical neoplasia. *Int J Gynecol Pathol* 1999;**18**:101–8.
- 67 **Wells M**, Brown IJR. Investigative approaches to endocervical pathology. *Int J Gynecol Pathol* 2002;**21**:360–7.
- 68 **McCluggage WG**, Sumathi VP, McBride HA, *et al*. A panel of immunohistochemical stains, including carcinoembryonic antigen, vimentin and estrogen receptor aids the distinction between primary endometrial and endocervical adenocarcinomas. *Int J Gynecol Pathol* 2002;**21**:11–15.
- 69 **Castrillon DH**, Lee KR, Nucci MR. Distinction between endometrial and endocervical adenocarcinomas: an immunohistochemical study. *Int J Gynecol Pathol* 2002;**21**:4–10.
- 70 **Kamoi S**, Al-Juboury ML, Akin MR, *et al*. Immunohistochemical staining in the distinction between endometrial and endocervical adenocarcinomas: another viewpoint. *Int J Gynecol Pathol* 2002;**21**:217–23.
- 71 **McCluggage WG**, Jenkins D. Immunohistochemical staining with p16 may assist in the distinction between endometrial and endocervical adenocarcinoma. *Int J Gynecol Pathol* [In press.]
- 72 **Ferry JA**, Scully RE. Mesonephric remnants, hyperplasia and neoplasia of the uterine cervix: a study of 49 cases. *Am J Surg Pathol* 1990;**14**:1100–11.
- 73 **Seidman JD**, Tavassoli FA. Mesonephric hyperplasia of the uterine cervix: a clinicopathologic study of 51 cases. *Int J Gynecol Pathol* 1995;**14**:293–9.
- 74 **Clement PB**, Young RH, Keh P, *et al*. Malignant mesonephric neoplasms of the uterine cervix—a report of eight cases, including four with a malignant spindle cell component. *Am J Surg Pathol* 1995;**19**:1158–71.
- 75 **Silver SA**, Devouassoux-Shisheboran M, Mezzetti TP, *et al*. Mesonephric adenocarcinomas of the uterine cervix: a study of 11 cases with immunohistochemical findings. *Am J Surg Pathol* 2001;**25**:379–87.
- 76 **Ordi J**, Nogales FF, Palacin A, *et al*. Mesonephric adenocarcinoma of the uterine corpus: CD10 expression as evidence of mesonephric differentiation. *Am J Surg Pathol* 2001;**25**:1540–5.
- 77 **Rahilly MA**, Williams ARW, An-Nafussi A. Minimal deviation endometrioid adenocarcinoma of the cervix: a clinicopathological and immunohistochemical study of two cases. *Histopathology* 1992;**20**:351–4.
- 78 **Young RH**, Scully RE. Minimal deviation endometrioid adenocarcinoma of the uterine cervix. A report of five cases of a distinctive neoplasm that may be misinterpreted as benign. *Am J Surg Pathol* 1993;**17**:660–5.
- 79 **Gilks CB**, Young RH, Aquirre P, *et al*. Adenoma malignum (minimal deviation adenocarcinoma) of the uterine cervix. A clinicopathological and immunohistochemical analysis of 26 cases. *Am J Surg Pathol* 1989;**13**:717–29.
- 80 **Ishii K**, Kumagai T, Tozuka M, *et al*. A new diagnostic method for adenoma malignum and related lesions: latex agglutination test with a new monoclonal antibody, HK1083. *Clin Chim Acta* 2001;**312**:231–3.
- 81 **Ischimura T**, Koizumi T, Tateiwa H, *et al*. Immunohistochemical expression of gastric mucin and p53 in minimal deviation adenocarcinoma of the uterine cervix. *Int J Gynecol Pathol* 2001;**20**:220–6.
- 82 **Utsugi K**, Hirai Y, Takeshima N, *et al*. Utility of the monoclonal antibody HIK1083 in the diagnosis of adenoma malignum of the uterine cervix. *Gynecol Oncol* 1999;**75**:345–8.
- 83 **Nucci MP**, Clement PB, Young RH. Lobular endocervical glandular hyperplasia, not otherwise specified: a clinicopathologic analysis of 13 cases of a distinctive pseudoneoplastic lesion and comparison with four cases of adenoma malignum. *Am J Surg Pathol* 1999;**23**:886–91.
- 84 **Mikami Y**, Hata S, Fujiwara K, *et al*. Florid endocervical glandular hyperplasia with intestinal and pyloric gland metaplasia: worrisome benign mimic of “adenoma malignum”. *Gynecol Oncol* 1999;**74**:504–11.
- 85 **Hayashi I**, Tsuda H, Shimoda T. Reappraisal of orthodox histochemistry for the diagnosis of minimal deviation adenocarcinoma of the cervix. *Am J Surg Pathol* 2000;**24**:559–62.



Endocervical glandular lesions: controversial aspects and ancillary techniques

W G McCluggage

J Clin Pathol 2003 56: 164-173

doi: 10.1136/jcp.56.3.164

Updated information and services can be found at:

<http://jcp.bmj.com/content/56/3/164.full.html>

References

These include:

This article cites 76 articles, 2 of which can be accessed free at:

<http://jcp.bmj.com/content/56/3/164.full.html#ref-list-1>

Article cited in:

<http://jcp.bmj.com/content/56/3/164.full.html#related-urls>

Email alerting service

Receive free email alerts when new articles cite this article. Sign up in the box at the top right corner of the online article.

Notes

To request permissions go to:

<http://group.bmj.com/group/rights-licensing/permissions>

To order reprints go to:

<http://journals.bmj.com/cgi/reprintform>

To subscribe to BMJ go to:

<http://group.bmj.com/subscribe/>