

ORIGINAL ARTICLE

Hepatic granulomas: a 10 year single centre experience

D R Gaya, D Thorburn, K A Oien, A J Morris, A J Stanley

J Clin Pathol 2003;56:850–853

See end of article for authors' affiliations

Correspondence to: Dr D Gaya, Flat 1/2, 15 Julian Avenue, Kelvinside, Glasgow, G12 0RB, UK; danielgaya@aol.com

Accepted for publication 10 April 2003

Background: Epithelioid granulomas have been reported in 2–15% of unselected liver biopsies, with numerous underlying aetiologies described. However, all UK series were reported before identification of hepatitis C virus (HCV).

Aim: To evaluate the current aetiologies of hepatic granulomas and to assess the prognosis for the "idiopathic" group, in which all investigations for a recognised cause were negative or normal.

Methods: A retrospective review of patient case notes between 1991 and 2001; all patients who had a liver biopsy at Glasgow Royal Infirmary revealing epithelioid granulomas had their case notes and liver biopsies reviewed and a standard proforma completed.

Results: Over the study period, 1662 liver biopsies were performed. Hepatic granulomas were found in 63. Of those identified, 47 were female, with a mean age of 42 years (range, 17–81). Underlying aetiologies were as follows: primary biliary cirrhosis (PBC; 23.8%), sarcoidosis (11.1%), idiopathic (11.1%), drug induced (9.5%), HCV (9.5%), PBC/autoimmune hepatitis (AIH) overlap (6.3%), Hodgkin lymphoma (6.3%), AIH (4.8%), tuberculosis (4.8%), resolving biliary obstruction (3.2%), and other single miscellaneous causes (9.5%). Of the seven patients with idiopathic hepatic granulomas, one was lost to follow up, one died of stroke, and the remaining five were well with no liver related morbidity at a mean follow up of 6.2 years.

Conclusions: The aetiology of hepatic granulomas is broad ranging, with HCV an important cause in this population. Despite extensive investigations, a 10–15% of patients still had "idiopathic" hepatic granulomas. However, the prognosis for this last group appears to be excellent.

Granulomas are focal accumulations of modified macrophages (epithelioid cells), which may fuse to form multinucleated giant cells, and typically have a surrounding rim of lymphocytes and fibroblasts. They represent an example of a delayed-type hypersensitivity reaction in response to some form of antigenic stimulation. A wide variety of underlying conditions can cause hepatic granulomas, with resulting prognostic and therapeutic implications.

"The only published series from the UK largely included patients diagnosed before the discovery of the hepatitis C virus, now recognised as a common cause of hepatic epithelioid granulomas"

Epithelioid granulomas have been reported in 2–15% of unselected liver biopsies^{1–8} with a large number of underlying aetiologies. Unfortunately, only rarely do granulomas possess distinct histological features—for example, caseous necrosis containing acid fast bacilli (tuberculosis; TB) or ova of *Schistosoma mansoni* (schistosomiasis), which enable such clinical conditions to be diagnosed.^{9–10} Thus, a specific aetiological agent often cannot be identified despite serological, immunological, microbiological, and radiological investigations, leading to a diagnosis of "idiopathic" hepatic granulomas; there is a consistent cohort of such patients, accounting for approximately 15% of hepatic granuloma series.^{1–8}

The only published series from the UK, including one from this centre, largely included patients diagnosed before the discovery of the hepatitis C virus (HCV), now recognised as a common cause of hepatic epithelioid granulomas.^{4–7, 8–10} We undertook a further analysis of all liver biopsies revealing hepatic granulomas over a 10 year period, after the introduction of HCV antibody testing, to establish whether,

with advances in immunological and virological testing, there has been an alteration in the distribution of diagnoses in patients identified with hepatic granulomas. In addition, we were interested to see whether there had been a resulting reduction in the proportion of "idiopathic" cases. Because few data exist regarding the characteristics and outcome of this group, we aimed to document the presentation and outcome of this "idiopathic" group.

METHODS

A retrospective case note review was performed on all patients found to have hepatic epithelioid granulomas on liver biopsy performed between January 1991 and December 2001 at Glasgow Royal Infirmary. A list of all biopsies reporting granulomas, regardless of coexistent histological hepatitis (that is, "granulomatous hepatitis"), was generated from the pathology department computer database. All biopsies revealing only lipogranulomas (clusters of lipid droplets surrounded by macrophages and lymphocytes) were excluded from our study because these are not related to the usual aetiologies of true epithelioid granulomas.¹¹ All the remaining biopsies were stained for mycobacteria and fungi and reviewed by our pathologist.

Aetiology was determined by results from autoantibodies, immunoglobulins, hepatitis serology, and full drug history. Chest radiography had been performed if sarcoid or TB were deemed likely. Serum angiotensin converting enzyme and calcium measurements were performed to aid with the diagnosis of sarcoidosis. The above results and clinical assessment were recorded in a standard proforma, as were

Abbreviations: AIH, autoimmune hepatitis; AMA, antimitochochondrial antibodies; HCV, hepatitis C virus; PBC, primary biliary cirrhosis; TB, tuberculosis

liver function tests at the time of biopsy. Patient outcome was assessed on the basis of the most recent clinic review.

RESULTS

Incidence of hepatic granulomas

Granulomas were detected in 96 patients. Of these, 24 biopsies contained only lipogranulomas and were excluded. The remaining 72 patients with epithelioid granulomas were included in our study. Five case notes could not be traced and four patients did not have full appropriate investigations to determine an aetiology. Of the 63 remaining patients, 47 were female, with a mean age of 49 years (range, 17–81). Figure 1 shows the number of liver biopsies revealing hepatic granulomas and the total number of biopsies performed each year. Over the study period, the percentage of liver biopsies revealing granulomas has been fairly consistent, with a mean of 4.2% out of a total of 1662 liver biopsies performed over the study period.

Diagnoses

Table 1 reveals the various underlying aetiologies expressed both as the number of cases and as a percentage of the total number of liver biopsies revealing epithelioid granulomas.

Fifteen cases were attributed to primary biliary cirrhosis (PBC), and of these four patients had negative antimitochondrial antibodies (AMA) at the time of biopsy. However, each of these four patients had raised IgM, cholestatic liver function derangement, and compatible liver histology, and were therefore thought to have “AMA negative PBC”. Interestingly, none subsequently developed positive AMA during the study period.

Sarcoid accounted for seven of the 63 cases. Liver function tests in all these seven patients were deranged in a predominantly cholestatic pattern.

Seven patients fell into the idiopathic category, six were female and the overall mean age was 52.6 years. This diagnosis was made only after all the investigations described above were negative. In this idiopathic group, liver function tests were deranged in a cholestatic pattern.

Five patients in our series were deemed to have drug induced hepatic granulomas. The granulomas in all six of these biopsies were noted to have an associated eosinophilic infiltrate. The drugs in question were identified as

Table 1 Underlying diagnosis of patients diagnosed with epithelioid hepatic granulomas between January 1991 and December 2001 at Glasgow Royal Infirmary

Underlying diagnosis	Number of cases	Percentage of cases
PBC	15	23.8%
Sarcoidosis	7	11.1%
Idiopathic	7	11.1%
HCV	6	9.5%
Drug induced	5	7.9%
PBC/AIH overlap	4	6.3%
Hodgkin lymphoma	4	6.3%
AIH	3	4.8%
Tuberculosis	3	4.8%
Biliary obstruction	2	3.2%
Other*	6	9.5%
Total	63	100%

*One case of each of the following diagnoses was noted: non-Hodgkin lymphoma (NHL), polymyalgia rheumatica, juvenile chronic arthritis, graft versus host disease, jejunio-ileal bypass surgery, HCV + NHL, and intravesical BCG.
AIH, autoimmune hepatitis; HCV, hepatitis C virus; PBC, primary biliary cirrhosis.

glibenclamide, metronidazole, baclofen, nitrofurantoin, and allopurinol.

Autoimmune hepatitis (AIH)/PBC overlap syndrome was the diagnosis in four cases. The diagnosis in all four was made on the basis of mixed liver function test derangement, positive AMA and antismooth muscle antibodies, and a mixture of hepatitic/cholestatic histopathology.

There were three cases of AIH, a condition not normally associated with hepatic granulomas. In all three cases, other causes of granulomas were excluded and in addition typical autoantibodies on serology and interface hepatitis on histology were found. Of note, AMA antibodies were persistently negative in all cases.

Resolving biliary obstruction of duration more than six months as a result of gallstones accounted for two cases. The histological findings of poorly formed granulomas in close association with necrotic hepatocytes and bile pigment have been described previously. These were accompanied by features of extrahepatic biliary obstruction, including bile stasis, ductal proliferation, and a neutrophil infiltrate.

One case was ascribed to each of the following aetiologies; non-Hodgkin lymphoma, polymyalgia rheumatica, juvenile chronic arthritis, graft versus host disease, jejunio-ileal bypass surgery, and intravesical BCG. In one other case, it was felt impossible to determine the cause of a patient’s hepatic granulomas because both HCV and non-Hodgkin lymphoma were present at the time of biopsy, and both (either alone or in combination) could have been responsible.

Outcomes of patients with hepatic granulomas

Table 2 shows the outcome of patients diagnosed with hepatic granulomas over a follow up period ranging from 4.4 to seven years.

Of particular interest to us was the outcome of the idiopathic cohort. From this group, one patient died from a cerebrovascular accident, one was lost to follow up, and the remaining five are well and still attending our liver clinic, with a mean 6.2 years of follow up.

DISCUSSION

Our study confirms the broad range of underlying aetiologies of hepatic granulomas. In addition, HCV was seen to be an important cause of hepatic granulomas in our patient cohort. Despite this, a large cohort with presumed idiopathic hepatic granulomas persisted.

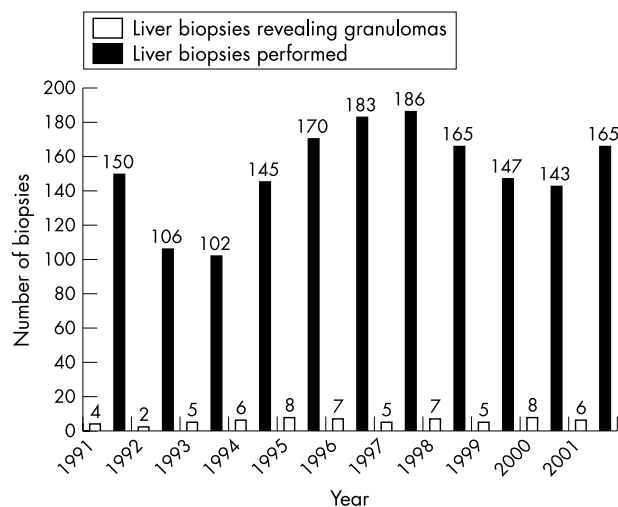


Figure 1 Number of liver biopsies and number of cases revealing hepatic epithelioid granulomas performed at Glasgow Royal Infirmary between 1991 and 2001.

Table 2 Outcomes of patients diagnosed with epithelioid hepatic granulomas between January 1991 and December 2001 at Glasgow Royal Infirmary

Underlying diagnosis	N	Mean follow up (years)	Morbidity		Mortality	
			Decompensated liver disease	Liver transplantation	Overall	Liver related
PBC	15	5.0	2	2	5	2
Sarcoidosis	7	6.7	0	0	2	0
Idiopathic	7	5.2	0	0	1	0
Drug induced	6	7.0	0	0	0	0
HCV infection	6	5.8	2	1	2	1
PBC/AIH overlap	4	4.4	0	1	2	1
Hodgkin lymphoma	4	6.0	0	0	1	0
AIH	3	5.4	0	0	0	0
Tuberculosis	3	6.0	0	0	1	0
Biliary obstruction	2	4.8	0	0	1	0
Other*	6	6.3	0	0	2	0
Total	63	5.7 (mean)	4	4	17	4

*One case of each of the following diagnoses was noted: non-Hodgkin lymphoma (NHL), polymyalgia rheumatica, juvenile chronic arthritis, graft versus host disease, jejunum-ileal bypass surgery, HCV + NHL, and intravesical BCG. AIH, autoimmune hepatitis; HCV, hepatitis C virus; PBC, primary biliary cirrhosis.

Chronic HCV has only been recognised as a cause of hepatic granulomas since the availability of routine serological testing in 1991, and was therefore not described as a cause of hepatic granulomas in the previous large UK series.^{4 7 8 10} Hepatic granulomas have been described in up to 10% of liver biopsies from HCV infected patients,¹²⁻¹⁵ although the clinical relevance of this finding is unknown.^{16 17}

Thus, we expected that there would have been a smaller proportion of "idiopathic" cases in our series. Interestingly, this was not the case because we identified a subgroup of patients (11.1%) in our study in whom an underlying aetiology could not be found, despite extensive investigations. The most likely explanation for this is that those patients with HCV, most of whom were infected through intravenous drug abuse, were rarely investigated for abnormal liver function tests before 1990 (when widespread HCV serology testing became available), and certainly rarely underwent liver biopsy before the HCV era. Thus, the HCV granuloma group probably represents a new cohort of previously undiagnosed hepatic granulomas.

In our experience, those patients with so called idiopathic hepatic granulomas tend to be middle aged women with cholestatic liver function tests who have an excellent outcome. The benign prognosis of this patient group has been noted previously.^{7 18} Earlier publications on this subset of patients^{19 20} have highlighted the systemic upset, with fever, myalgia, weight loss, and weakness that may accompany the deranged liver function. In our "idiopathic" cohort, no patient exhibited such a clinical picture and, in addition, the fact that nine of the 10 patients in our study¹⁹ were male suggests this may represent a distinct disorder. Indeed, it is possible that these cases may represent underlying polymyalgia rheumatica, a recognised cause of hepatic granulomas and systemic upset. This is supported by the reported good clinical/laboratory response of such patients to corticosteroids.¹⁹

PBC remains the most common diagnosis in patients with hepatic granulomas and is consistent with previous granuloma series from the UK.⁸ However, it should be noted that PBC may be underestimated as a cause in our series because we do not routinely biopsy all patients with presumed PBC, particularly if they are middle aged women with positive AMA and cholestatic liver function test derangement.

"Those patients with so called idiopathic hepatic granulomas tend to be middle aged women with cholestatic liver function tests who have an excellent outcome"

In sarcoidosis, the histological findings are not diagnostic, and a wide range of pathological features is recognised.²¹⁻²³ Thus, a combination of multisystem involvement, chest radiograph abnormalities, raised serum calcium, and raised angiotensin converting enzyme values were used to make the diagnosis.

In our drug induced group, all of the patients had a favourable outcome and none developed acute liver failure. Many other medications have been reported to be associated with hepatic granulomas.²⁴

It has long been recognised that Hodgkin disease is associated with the development of hepatic granuloma, and a study in 1974²⁵ revealed that 8% of staging liver biopsies in 103 patients with Hodgkin disease contained granulomas. An earlier study had suggested a figure of 17%.²⁶ The presence of hepatic granulomas does not appear to be related to disease outcome or prognosis in Hodgkin lymphoma. Cases of hepatic granulomas associated with non-Hodgkin lymphoma,²⁷ polymyalgia rheumatica,^{28 29} and jejunum-ileal bypass surgery^{30 31} have previously been described.

In our series, similar to that reported by McGluggage and Sloan,⁸ infections accounted for only a small proportion of cases. This is in sharp contrast to other parts of the world. A series from Turkey³² revealed that infectious agents including TB, hydatid disease, brucella, and typhoid fever accounted for over half of their hepatic granuloma cases. In addition, in a series from Saudi Arabia,³ schistosomiasis accounted for over half of the cases, with TB the next most common cause. We noted one case that was caused by systemic BCG infection after an intravesicular BCG injection for a bladder tumour, which has been described previously.³³⁻³⁶ We may have expected some opportunistic infections (for example, *Mycobacterium avium* intracellulare, toxoplasmosis) to account for some cases in human immunodeficiency virus infected patients, but these patients are exclusively cared for in a dedicated infectious diseases unit at another hospital in our city.

Perhaps surprisingly, in none of our cases of hepatic granuloma was inflammatory bowel disease the underlying aetiology, despite our hospital having a cohort of approximately 1000 patients with inflammatory bowel disease. For many years, it has been recognised that hepatic granulomas are associated with this disease, and are particularly prevalent in patients with Crohn's disease.^{37 38} The series of McGluggage and Sloan,⁸ carried out in Northern Ireland during the 1980s, revealed three (1.8%) cases of underlying Crohn's disease. It is possible that endoscopic retrograde

Take home messages

- The aetiology of hepatic granulomas is broad ranging
- Hepatitis C virus is an important cause of hepatic granulomas
- Despite extensive investigations, 10–15% of patients had “idiopathic” hepatic granulomas, although the prognosis for these patients appears to be excellent

cholangiopancreatography or magnetic resonance cholangiopancreatography are being performed in preference to liver biopsy for the investigation of abnormal liver function tests in our patient cohort.

As previously mentioned, steroids have been advocated in the treatment of idiopathic granulomatous hepatitis; some believe their benefit depends on the fact that a proportion of these are cases of undiagnosed sarcoid. However, this course of action risks exacerbating underlying TB, and an earlier paper⁴ described a patient who died from miliary TB after empirical steroids in this setting. Therefore, caution must be exercised, particularly in parts of the world with a high incidence of TB, where empirical antituberculous treatment should be considered as a first line treatment. Of our three cases of TB, one showed central caseation and none had acid fast bacilli revealed on Ziehl-Neelsen staining. This is consistent with earlier studies,^{1,4} highlighting the poor diagnostic yield for TB on hepatic histology, and underlines the need to consider this diagnosis.

In conclusion, our study confirms that hepatic granulomas have a wide aetiology. HCV is emerging as an important causal agent in the West. Finally, despite extensive investigations, 10–15% of our patients had no aetiology identified and were thus labelled “idiopathic”. These patients were typically middle aged women with cholestatic liver function tests and had an excellent prognosis.

Authors' affiliations

D R Gaya, D Thorburn, A J Morris, A J Stanley, Gastroenterology Unit, Glasgow Royal Infirmary, 84 Castle St, Glasgow, G4 0SF, UK
K A Oien, Department of Pathology, Glasgow Royal Infirmary

REFERENCES

- 1 **Wagoner GP**, Anton AT, Gall EA, *et al*. Needle biopsy of the liver. Experiences with hepatic granulomas. *Gastroenterology* 1963;**25**:487–94.
- 2 **Guckien JC**, Perry SE. Granulomatous hepatitis. An analysis of 63 cases and review of the literature. *Ann Intern Med* 1969;**65**:1081–100.
- 3 **Sartin JS**, Walker RC. Granulomatous hepatitis: a retrospective review of 88 cases at the Mayo Clinic. *Mayo Clin Proc* 1991;**66**:914–18.
- 4 **Cunningham D**, Mills PR, Quigley EMM, *et al*. Hepatic granulomas: experience over a 10 year period in the West of Scotland. *Q J Med* 1982;**51**:162–70.
- 5 **Sati MB**, Hussein AF, Ibrahim J, *et al*. Hepatic granuloma in Saudi Arabia: a clinicopathological study of 59 cases. *Am J Gastroenterol* 1990;**85**:669–74.
- 6 **Mir-Madjlessi SH**, Farmer RG, Hawk WA. Granulomatous hepatitis. A review of 50 cases. *Am J Gastroenterol* 1973;**60**:122–33.
- 7 **Neville E**, Piyasena KHG, Geraint JD. Granulomas of the liver. *Postgrad Med J* 1975;**51**:361–5.
- 8 **McCluggage WG**, Sloan JM. Hepatic granulomas in Northern Ireland: a thirteen year review. *Histopathology* 1994;**25**:219–28.
- 9 **Klatskin G**. Hepatic granulomata: problems in interpretation. *Ann N Y Acad Sci* 1976;**278**:427–31.
- 10 **Hughes M**, Fox H. A histological analysis of granulomatous hepatitis. *J Clin Pathol* 1972;**25**:817–20.
- 11 **Denk H**, Scheuer PJ, Baptista A, *et al*. Guidelines for the diagnosis and interpretation of hepatic granulomas. *Histopathology* 1994;**25**:209–18.
- 12 **Emile JF**, Sebagh M, Feray C, *et al*. The presence of epithelioid granulomas in hepatitis C-related cirrhosis. *Hum Pathol* 1993;**24**:1095–7.
- 13 **Goldin RD**, Levine TS, Foster GR, *et al*. Granulomas in hepatitis C. *Histopathology* 1996;**28**:265–7.
- 14 **Back N**, Thang S, Schaffner F. The histological features of chronic hepatitis C and autoimmune chronic hepatitis: a comparative analysis. *Hepatology* 1992;**15**:572–7.
- 15 **Scheuer P**, Ashrafzadeh P, Sherlock S, *et al*. The pathology of hepatitis C. *Hepatology* 1992;**15**:567–71.
- 16 **Veerabagu MP**, Finkelstein SD. Granulomatous hepatitis in a patient with chronic hepatitis C treated with interferon- α . *Dig Dis Sci* 1997;**42**:1445–8.
- 17 **Propst A**, Propst T, Dietze O, *et al*. Development of granulomatous hepatitis during treatment with interferon- α 2b. *Dig Dis Sci* 1995;**40**:2117–18.
- 18 **Anderson CS**, Nicholls J, Rowland R, *et al*. Hepatic granulomas: a 15 year experience in the Royal Adelaide Hospital. *Med J Aust* 1988;**148**:71–4.
- 19 **Simon HB**, Wolff SM. Granulomatous hepatitis and prolonged fever of unknown origin: a study of 13 patients. *Medicine* 1973;**52**:1–21.
- 20 **Terplan M**. Hepatic granulomas of unknown cause presenting with fever. *Am J Gastroenterol* 1971;**55**:43–9.
- 21 **Klatskin G**, Yesner R. Hepatic manifestations of sarcoidosis and other granulomatous diseases. *Yale J Biol Med* 1950;**23**:207.
- 22 **Israel HL**, Goldstein RA. Hepatic granulomas and sarcoidosis. *Ann Intern Med* 1973;**79**:669–78.
- 23 **Mitchell DM**, Scadding JG, Heard BE, *et al*. Sarcoidosis: histological definition and clinical diagnosis. *J Clin Pathol* 1977;**30**:395–408.
- 24 **McMaster KR**, Hennigar GR. Drug induced granulomatous hepatitis. *Lab Invest* 1981;**44**:61–73.
- 25 **Abt AB**, Kirschnner RH, Belliveau RE, *et al*. Hepatic pathology associated with Hodgkin's disease. *Cancer* 1974;**33**:1564–71.
- 26 **Kadin ME**, Donaldson SS, Dorfman RF. Isolated granulomas in Hodgkin's disease. *N Engl J Med* 1970;**283**:859–61.
- 27 **Braylan RC**, Long JC, Jaffe ES, *et al*. Malignant lymphoma obscured by concomitant extensive epithelioid granulomas. *Cancer* 1977;**39**:1146.
- 28 **Dickson ER**, Maldonado JE, Sheps SG, *et al*. Systemic giant cell arthritis with polymyalgia rheumatica: reversible abnormalities in liver function. *JAMA* 1973;**224**:1495–8.
- 29 **Long R**, James O. Polymyalgia rheumatica and liver disease. *Lancet* 1974;**1**:77–9.
- 30 **Hocking MP**, Duerson M, O'Leary P. Jejunio-ileal bypass for morbid obesity: late follow up of 100 cases. *N Engl J Med* 1983;**308**:995–9.
- 31 **Requarth JA**, Burchard KW, Colacchi TA, *et al*. Long term morbidity following jejunioileal bypass: the continuing need for surgical reversal. *Arch Surg* 1995;**130**:318–25.
- 32 **Mert A**, Ozarus R, Bilir M, *et al*. The aetiology of hepatic granulomas. *J Clin Gastroenterol* 2001;**32**:275–6.
- 33 **Bodurtha A**, Kim YH, Laucius JF, *et al*. Hepatic granulomas and other hepatic lesions associated with BCG immunotherapy in cancer. *Am J Clin Pathol* 1974;**61**:747–52.
- 34 **Hunt JS**, Silverstein MJ, Sparks FC, *et al*. Granulomatous hepatitis: a complication of BCG immunotherapy. *Lancet* 1973;**2**:820–1.
- 35 **Thomas D**, Cumming J. Granulomatous hepatitis following intravesical BCG therapy. *Br J Urol* 1990;**66**:432–3.
- 36 **Leebeck FW**, Ouwendijk RJ, Koll AH, *et al*. Granulomatous hepatitis caused by Bacillus Calmette Guerin (BCG) infection after bladder installation. *Gut* 1996;**38**:616–18.
- 37 **Maurer LH**, Hughes RW, Folley JH, *et al*. Granulomatous hepatitis associated with regional enteritis. *Gastroenterology* 1967;**53**:301–5.
- 38 **Eade MN**, Cooke WT, Brooke PN, *et al*. Liver disease in Crohn's colitis. *Ann Intern Med* 1971;**74**:518–28.



Hepatic granulomas: a 10 year single centre experience

D R Gaya, D Thorburn, K A Oien, et al.

J Clin Pathol 2003 56: 850-853
doi: 10.1136/jcp.56.11.850

Updated information and services can be found at:
<http://jcp.bmj.com/content/56/11/850.full.html>

References

These include:

This article cites 34 articles, 7 of which can be accessed free at:
<http://jcp.bmj.com/content/56/11/850.full.html#ref-list-1>

Article cited in:
<http://jcp.bmj.com/content/56/11/850.full.html#related-urls>

Email alerting service

Receive free email alerts when new articles cite this article. Sign up in the box at the top right corner of the online article.

Topic Collections

Articles on similar topics can be found in the following collections

[Clinical diagnostic tests](#) (637 articles)
[Hepatitis \(sexual health\)](#) (51 articles)
[Hepatitis and other GI infections](#) (51 articles)
[Liver disease](#) (88 articles)
[Pancreas and biliary tract](#) (114 articles)

Notes

To request permissions go to:
<http://group.bmj.com/group/rights-licensing/permissions>

To order reprints go to:
<http://journals.bmj.com/cgi/reprintform>

To subscribe to BMJ go to:
<http://group.bmj.com/subscribe/>