

ORIGINAL ARTICLE

Telomerase activity detected in oral lichen planus by RNA in situ hybridisation: not a marker for malignant transformation

C O'Flatharta, M Leader, E Kay, S R Flint, M Toner, W Robertson, M J E M F Mabruk

J Clin Pathol 2002;**55**:602–607

See end of article for authors' affiliations

Correspondence to: Dr M Mabruk, Department of Pathology, RCSI, Education and Research Centre, Beaumont Hospital, Beaumont Road, Dublin 9, Ireland; mmabruk@rcsi.ie

Accepted for publication 4 February 2002

Background: Oral lichen planus (OLP) is a chronic inflammatory condition. Clinically, it is characterised by the presence of a white lace-like lesion on the buccal mucosa, tongue, and gingivae, with erosions and ulceration. The World Health Organisation considers OLP to be a premalignant condition.

Aims: To investigate expression of the telomerase RNA component (hTR) in OLP compared with normal control buccal mucosa and to assess the possibility of using hTR expression as a marker for malignant transformation in OLP.

Methods: hTR expression was analysed in 40 cases of OLP and 18 normal control buccal mucosa samples using an RNA in situ hybridisation approach.

Results: Strong hTR RNA expression was seen in the basal, suprabasal, and to a lesser extent in the upper epithelial layers in 36 of the 40 OLP lesions examined. Infiltrating subepithelial lymphocytes in OLP were also shown to express hTR RNA. Weak hTR RNA expression was seen in seven of the 18 normal control buccal mucosa specimens, with expression confined exclusively to the basal layer of the epithelium and absent in the suprabasal and upper layers.

Conclusion: The telomerase RNA component hTR is found to be highly expressed in the epithelium of non-dysplastic OLP lesions. It is possible that this high expression is related to the increased cellular proliferation seen in OLP lesions rather than being an indicator of susceptibility to malignancy. Thus, hTR RNA expression may not be a suitable marker for predicting malignant transformation in OLP.

Oral lichen planus (OLP) is a common chronic inflammatory disorder, which is present in about 1% of the population and usually appears in the 5th or 6th decade of life.¹ It preferentially affects women at a ratio of 3 : 2.² OLP assumes a variety of clinical types, namely: reticular, papular, plaque-like, atrophic/erosive, ulcerative, and bullous. Clinically, OLP is characterised by multiple white lace-like lesions, erosions, and ulceration that most commonly affect the buccal mucosa, tongue, and gingivae, but can also occur at any number of oral mucosal sites within an individual.³

Histologically, OLP is represented by a dense band-like lymphocytic infiltrate at the epithelial–stromal junction, with basal epithelial cell destruction.⁴ Disruption of the epithelial basement membrane and keratinocyte anchoring elements results in microscopic clefts between the connective tissue and the epithelium.⁵

The aetiology of OLP is unknown, but it is thought to be immune mediated and to involve the cell mediated arm of the immune system.⁶

Several studies have shown that OLP has a malignant potential, albeit very low, with reports in the literature estimating the rate of malignant transformation in OLP as between 0.4% and 5.6%.⁷ The World Health Organisation considers OLP to be a premalignant condition, particularly if there is evidence of dysplasia.⁸ However, the question of malignant transformation in OLP remains an ongoing matter for debate.^{4, 9, 10}

Human telomeres are the distal ends of chromosomes composed of several kilobases of tandem repeats of the sequence TTAGGG, which protect the chromosomes from DNA degradation, end to end fusion, rearrangements, and chromosomal loss.¹¹ In most normal somatic cells, conventional DNA replication does not allow for completion of the chromosome ends, hence the slow loss of telomeric repeats and genetic material after successive rounds of replication.^{12, 13} This reduc-

tion in telomere length has been proposed to be the major timing mechanism that determines cellular senescence in normal cells.¹⁴

“Several studies have shown that OLP has a malignant potential, albeit very low, with reports in the literature estimating the rate of malignant transformation in OLP as between 0.4% and 5.6%”

Telomerase is a specialised ribonucleoprotein polymerase composed of RNA and protein components and is thought to compensate for the loss of telomere during cell division. The hTR RNA moiety of telomerase has been cloned recently and its presence was shown to be crucial for telomerase activity. This integral RNA template element (hTR) directs the synthesis of telomeric repeats at chromosomal ends.¹⁵ Among the protein components are the human telomerase reverse transcriptase hTERT (hTERT, hEST2),¹⁶ which is thought to be the catalytic subunit of the enzyme, and human telomerase protein 1.¹⁷

As one would expect, telomerase activity has been detected in immortalised and cancer cell lines, germ line cells, and most human malignancies, including head and neck squamous cell carcinomas.^{18–21}

Recent findings suggest that the activation of telomerase is a crucial step in the continuous proliferation of cancer cells, which allows them to attain immortality and therefore may be considered as a marker for tumour progression.¹⁸

Telomerase activity is thought to be minimal or undetectable in normal differentiated somatic cells. However, recent

Abbreviations: hTR, RNA template component of human telomerase; OLP, oral lichen planus; PCR, polymerase chain reaction

Table 1 Relation between clinical appearance, biopsy site, sex, age, and expression of the RNA template component of telomerase in oral lichen planus tissue samples

No.	Telomerase expression	Clinical appearance	Age	Sex	Biopsy site
1	Positive	Erosive	40	F	Labial mucosa
2	Positive	Reticular	43	F	BM
3	Positive	RP	45	F	BM
4	Positive	Reticular	61	M	N/A
5	Positive	Erosive bullous	60	F	BM
6	Positive	RP	66	F	Tongue
7	Positive	RP	41	M	BM
8	Negative	Reticular	69	F	BM
9	Positive	N/A	71	F	BM
10	Positive	Erosive/RP	45	F	BM
11	Positive	Erosive	42	F	BM
12	Positive	Plaque	46	F	BM
13	Positive	Plaque	75	F	Maxillary alveolus
14	Positive	Plaque	49	F	BM
15	Positive	Erosive	48	F	Tongue
16	Positive	RP	58	F	BM
17	Negative	Plaque	N/A	M	BM
18	Positive	Erosive/RP	44	F	BM
19	Positive	RP	38	F	BM
20	Positive	Reticular	47	F	BM
21	Positive	White patches	19	M	BM
22	Negative	RP	34	F	BM
23	Negative	RP	66	F	Tongue
24	Positive	Plaque	37	F	N/A
25	Positive	Erosive	63	F	BM
26	Positive	N/A	52	F	BM
27	Positive	N/A	62	F	BM
28	Positive	N/A	27	F	BM
29	Positive	Erosive reticular	66	F	BM
30	Positive	Reticular	37	M	BM
31	Positive	Plaque	42	F	BM
32	Positive	N/A	39	F	Tongue
33	Positive	Reticular	50	F	Alv ridge
34	Positive	N/A	55	F	Lower lip
35	Positive	RP	51	M	BM
36	Positive	Desquam gingivitis	32	M	Gingiva
37	Positive	Reticular	34	M	BM
38	Positive	Reticular	41	M	BM
39	Positive	Erosive reticular	N/A	M	N/A
40	Positive	Erosive	N/A	M	N/A

Alv ridge, alveolar ridge; BM, buccal mucosa; N/A, data not available; RP, reticular papular.

published reports show that telomerase is expressed in a variety of regenerative tissues and may be associated with cellular proliferation.²² Low amounts of telomerase activity have been detected in studies including normal oral mucosa,^{19 23 24} normal human epithelial cells and cell cultures,^{25 26} blood,^{27 28} endometrial cells,²⁹ and human hair follicles.³⁰

A recent report demonstrated telomerase activity in OLP using the *in vitro* telomere repeat amplification protocol (TRAP) assay.³¹ To date, nearly all information acquired on telomerase activity in OLP is derived from the use of the TRAP assay.¹⁸

However, the TRAP assay has several drawbacks. First, it does not allow for *in situ* analysis of telomerase activity. Second, the TRAP assay uses fresh or frozen tissue extracts and cannot identify which cells in tissue samples exhibit telomerase activity so that the precise contribution of infiltrating lymphocytes cannot be determined using this technique.³²⁻³⁴

Therefore, in our present study, and for the first time, we have investigated the use of an RNA *in situ* hybridisation approach to elucidate the patterns of hTR RNA expression in OLP and normal buccal mucosal biopsies obtained from patients attending the Dublin Dental Hospital, Ireland.

MATERIALS AND METHODS

Patients

Fifty eight formalin fixed, paraffin wax embedded tissue specimens were obtained from the Departments of Pathology, Beaumont Hospital and St James's Hospital, Dublin, Ireland. These specimens consisted of 40 histologically confirmed

non-dysplastic OLP tissue biopsies and 18 normal control buccal mucosa tissue biopsies without clinical evidence of OLP. Medical records and haematoxylin and eosin slides of the biopsies were reviewed by an oral pathologist (MT) to confirm the histological diagnosis.

The OLP group consisted of 11 men and 29 women, with a mean age of 48, ranging from 19 to 75 years (table 1). Twenty seven of the OLP specimens were taken from the buccal mucosa, four from the tongue, and one from each of the following: labial mucosa, maxillary alveolus, alveolar ridge, lower lip, and gingiva. Information on the biopsy site was unavailable for four patients (table 1). None of the patients in the study group went on to develop oral cancer during this time.

Lichenoid reactions, topographically related to buccal amalgam fillings, were excluded.

Positive control normal testis tissue was analysed in each *in situ* hybridisation experiment.

In situ hybridisation

The RNA *in situ* hybridisation technique was applied to OLP and normal control buccal mucosal sections. All chemicals were supplied by Sigma-Aldrich (Poole, Dorset, UK) unless otherwise stated.

Preparation of digoxigenin labelled hTR probes Cloning and transformation

The telomerase clone was a gift from Dr N Keith from the University of Glasgow.³⁵ This clone contains a fragment (154 bp) of

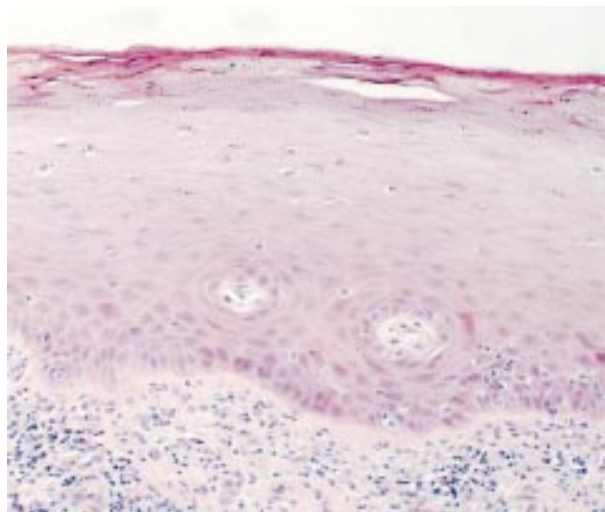


Figure 1 Haematoxylin and eosin staining showing the characteristic histological features of oral lichen planus.

the telomerase gene (TRC3R/TRC3F), subcloned into a PCR script vector containing both a T3 and a T7 promoter.

PCR amplification

PCR was performed with self designed primers: primer AB2, 5'-GTT TTC CCA GTC ACG ACG-3' (sense) and primer AB1, 5'-GAA TTG TGA GCG GAT AAC-3' (antisense). These primers were designed to amplify a region containing the insert of interest (in this case the TRC3R/TRC3F fragment of human telomerase flanked by the T3 and T7 promoters).

The PCR was conducted in a 50 μ l reaction volume. Each reaction contained 1 \times PCR buffer (10mM Tris/HCl (pH 9.0 at 25°C), 50mM KCl, and 0.1% Triton X-100), 1mM MgCl₂, 0.2mM of each dNTP, and 5 U of Taq DNA polymerase (Promega, Wisconsin, USA). Initial denaturation at 95°C for five minutes was followed by 30 cycles of denaturation at 94°C for 45 seconds, annealing at 37°C for 45 seconds, and extension at 72°C for one minute in a programmable DNA thermal cycler (Hybaid, Teddington, UK). A five minute extension step was carried out after the last cycle to ensure complete polymerisation. For the electrophoretic analysis of amplified DNA, a 10 μ l aliquot of PCR product was electrophoresed on a 1% agarose gel and visualised by ethidium bromide staining.

Probe labelling

Probe labelling was performed as described by the manufacturer (Boehringer Mannheim/ Roche Molecular Biochemicals, Lewes, East Sussex, UK), using T3 RNA polymerase and T7 RNA polymerase to create the antisense and sense probes, respectively.

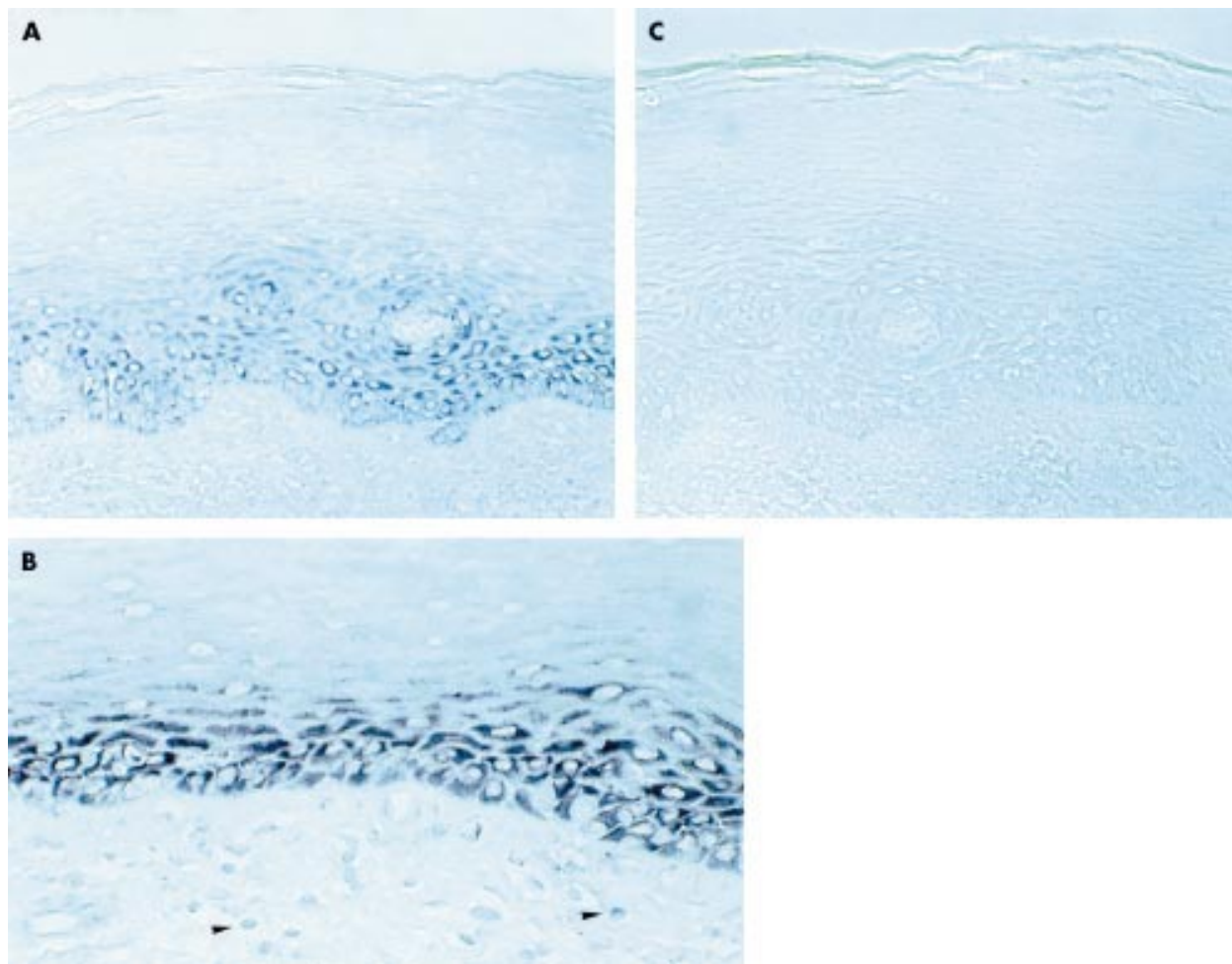


Figure 2 In situ detection of telomerase RNA gene expression in oral lichen planus biopsies. Expression of the telomerase RNA gene (hTR) was detected by in situ hybridisation with a riboprobe labelled with digoxigenin. Using an antisense probe, telomerase RNA expression appeared as blue/purple cytoplasmic staining in (A) the basal and suprabasal layers of epithelium, and (B) the subepithelial infiltrating lymphocytes (arrowheads). (C) No staining was observed using the sense RNA probe.

Probe precipitation

The labelled RNA was precipitated by the addition of 4M LiCl, 100% ethanol (-20°C) and glycogen, and the mix was then stored overnight at -20°C . Each reaction mix was subsequently centrifuged at $12\,000 \times g$ for 15 minutes. The resulting pellet was washed with 70% ethanol (-20°C) and then air dried. The dried pellets were resuspended in sterile RNase free water. The probe was further purified by passing it through a Nick Column (Amersham Pharmacia Biotech AB, Uppsala, Sweden), as described by the manufacturer. The integrity of the RNA probe was verified by electrophoresis on a 1% BSSE gel (50 mM boric acid, 5mM sodium tetraborate, 10mM sodium sulphate, 0.1mM EDTA) and visualised by ethidium bromide staining.

Digoxigenin labelled RNA in situ hybridisation

Sections of formalin fixed, paraffin wax embedded normal testes were used as a positive control for the detection of telomerase expression. The sections of testes were cut at a thickness of $4\ \mu\text{m}$ on a microtome (Microm HM325; Walldorf, Germany) and baked on to silanised slides at 57°C overnight.

In situ hybridisation

The prehybridisation and post hybridisation treatments used were essentially the same as described previously by Soder *et al*,³⁵ except that we used a digoxigenin labelling approach.

Visualisation of digoxigenin labelled probes

This was carried out as described by the manufacturer using the digoxigenin nucleic acid detection kit (Boehringer Mannheim/ Roche Molecular Biochemicals).

Statistical analysis

Statistical analysis was carried out using Fisher's exact test.

RESULTS

Histopathology

The biopsies showed features of OLP with varying degrees of keratosis. In some, the epithelium was hypertrophic, whereas others were atrophic. All had a lymphocytic infiltrate with exocytosis and basal layer liquefactive necrosis, some containing numerous Civatte bodies. Some of the biopsies included areas of ulceration and most of these contained plasma cells focally within the infiltrate, adjacent to areas of classic OLP. In a few cases, there was a subtle subepithelial split but no obvious bulla formation. None of the cases showed dysplasia. Figure 1 shows a typical example of OLP.

Detection of hTR RNA expression by in situ hybridisation

The telomerase antisense probe (T7) gave clear blue/purple cytoplasmic staining in the epithelial cells of the seminiferous tubules of the testis (positive control specimen). Using the telomerase sense probe (T3) no staining of any kind was seen in the epithelial cells of the seminiferous tubules of the testis with each in situ hybridisation experiment performed, thereby controlling for the specificity of each experiment.

The in situ hybridisation expression of hTR was detected in the epithelium of 36 of the 40 OLP lesions examined using the antisense RNA probe.

The expression patterns of hTR RNA were heterogeneous and confined to the epithelial cytoplasm, with strong expression of hTR RNA in the basal and suprabasal layers of all hTR RNA positive OLP cases (fig 2A).

In five of the 36 positive cases the more superficial prickle cells were positive for hTR RNA.

Expression of hTR RNA was also detected in a high proportion of the sublesional infiltrating lymphocytes in 35 of the 40 OLP cases (fig 2B).

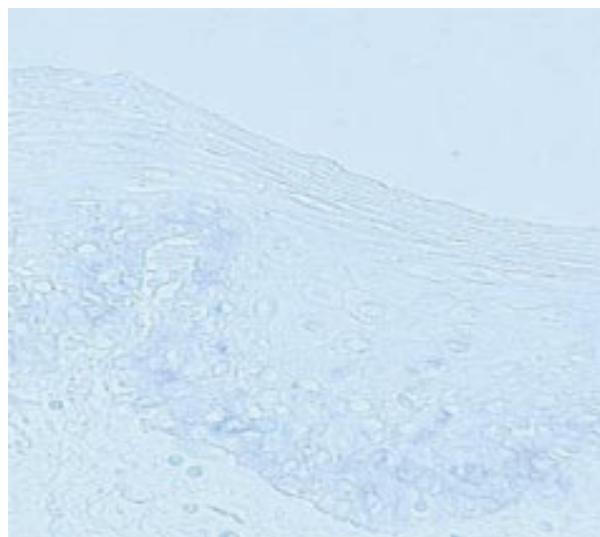


Figure 3 In situ detection of telomerase RNA expression in normal control buccal mucosa biopsies using the telomerase RNA antisense RNA probe.

No staining was observed using the sense hTR probe, which was applied to each OLP (fig 2C) and normal buccal mucosal case.

Weak hTR RNA expression was detected in seven of the 18 normal buccal mucosal cases using the anti-sense RNA probe. This weak staining was localised to the basal layer (fig 3). No expression was detected in the suprabasal and upper layers of the mucosa.

Statistical analysis

Fisher's exact test showed that there was a significance difference between the expression of hTR in OLP and in normal control tissue samples ($p < 0.0001$).

DISCUSSION

In most human tumours and tumour cell lines, the telomere maintenance mechanism involves the activity of telomerase. RNA in situ hybridisation experiments have previously shown the telomerase RNA gene (hTR) to be expressed in 81.6–100% of oral squamous cell carcinomas^{21 24 36} and also in oral hairy leukoplakia.²⁴ Using the TRAP assay, telomerase activity has been detected in 75–100% of oral squamous cell carcinomas^{20 21 23 34 36–39} and 43.4–86% of oral hairy leukoplakias.^{19 21 23 36 39}

A recent report published using the TRAP assay (an in vitro PCR based method) detected telomerase activity in 70% of OLP tissues investigated.³¹ This TRAP assay has several disadvantages. First, the TRAP assay does not allow the visualisation of the exact cell types in a tissue sample that are expressing telomerase activity. Second, fresh or frozen tissue is required for the technique. Third, the TRAP assay is complicated and can be affected by many factors. For example, in the case of oral lesions, false positive results may be the result of positivity in infiltrating lymphocytes and contaminating factors such as bacteria and blood. In contrast, the in situ hybridisation approach is more informative because it has the ability to detect and localise the expression of hTR in formalin fixed, paraffin wax embedded archival tissue.

“We have applied a novel approach for generating an RNA probe for the in situ hybridisation technique”

In our present study, we have applied a novel approach for generating an RNA probe for the in situ hybridisation

technique. This approach was developed in our laboratory to detect the expression of hTR in archival formalin fixed, paraffin wax embedded tissue.

We have applied this in situ approach to OLP biopsies for the first time. Telomerase hTR RNA expression was detected in the basal cells, suprabasal cells, and more superficially located prickle cells in 36 of the 40 OLP specimens examined.

Four of our OLP samples did not express hTR RNA. The study by Thongprasom *et al*, which used the TRAP assay, found that 30% of OLP samples did not exhibit telomerase activity.³¹

In addition, we detected low amounts of hTR expression in the basal layer of seven of the 18 normal control buccal mucosa tissue samples. Expression of hTR was considerably weaker than that seen in the OLP specimens and no expression was seen in the suprabasal or upper layers of the mucosa. Recent in situ hybridisation studies have shown hTR expression in the basal layers of normal oral epithelia,^{23 24 36} normal cervical epithelium,^{40 41} and epidermal basal cells from sun exposed skin.⁴²

Although telomerase activity has been shown to be absent in most normal somatic tissues, there have been reports of telomerase activity in cells with a high proliferation potential, such as normal oral squamous epithelium,³⁹ haematopoietic stem cells and lymphocytes,^{27 28 43} skin keratinocytes,^{25 33} cultured normal human epidermal keratinocytes,²⁶ and mitotically active segments of human hair follicles.³⁰ The detection of low amounts of telomerase activity in some histologically normal tissues probably reflects the presence of proliferating stem cells in these samples.

OLP is an immune mediated disorder characterised by the presence of a dense band-like inflammatory infiltrate at the epithelial/subepithelial interface.⁴ These activated lymphocytes may have telomerase activity and hTR expression. We examined each OLP specimen for the presence of hTR expression in the infiltrating lymphocytes. This in situ hybridisation technique detected hTR expression in the lymphocytes within the inflammatory infiltrate in OLP. hTR expression in the lymphocytic infiltrate corresponded with the presence of lymphocytes seen in the haematoxylin and eosin stained section for each OLP sample. Although lymphocytic hTR expression has not been detected by in situ hybridisation in studies involving the oral mucosa, in situ studies on normal and cancerous cervical tissue⁴⁰ and non-neoplastic livers⁴⁴ have revealed hTR expression localised to infiltrating lymphocytes. In addition, moderate hTR expression was limited to the secondary lymphoid follicles (for example, lymph node and spleen) in embryonic tissues,⁴⁵ whereas hTR expression was also shown to be present in the germinal centres of benign lymph nodes.⁴⁶

It has been shown previously that the treatment of immortalised human cell lines with antisense oligonucleotides for hTR limits their proliferative capacity.¹⁵ Recent studies have reported an association between hTR expression and the degree of malignancy in oral mucosal lesions,^{21 47} and a correlation between hTR expression and telomerase activity has been described in lung and cervical cancer.^{48 49}

Although telomerase was thought to be associated mainly with the malignant phenotype, evidence has accumulated that telomerase may be related to cellular proliferation. Telomerase activity has been reported in endometrial tissue and was shown to correlate with proliferation during the menstrual cycle.^{29 50} It has been shown previously that OLP has an increased proliferative capacity compared with other oral keratoses and normal mucosa.³¹ It is possible that the increased expression of the telomerase RNA component in OLP may be evidence of the hyperproliferative state, as shown by the determination of growth fraction.

"We hypothesise that hTR expression is associated with the high proliferation rate of OLP and does not necessar-

Take home messages

- The in situ hybridisation approach is more informative than the telomere repeat amplification protocol because it has the ability to detect and localise the expression of the telomerase RNA component (hTR) in formalin fixed, paraffin wax embedded archival tissue
- hTR is highly expressed in the epithelium of non-dysplastic oral lichen planus (OLP) lesions
- However, we think that this high expression is related to the increased cellular proliferation seen in OLP lesions rather than being an indicator of susceptibility to malignancy
- Therefore, hTR RNA may not be a suitable marker for predicting malignant transformation in OLP

ily provide a marker for the malignant potential of the disease"

The potential for malignant transformation in OLP is relatively low.⁷ Our study has shown that the telomerase RNA component is expressed in the suprabasal epithelium of 90% of the OLP samples examined. Other investigators have detected telomerase activity by TRAP assay in 70% of a smaller number of OLP tissues,³¹ although this last study did not include normal control tissue.

This and previous studies have demonstrated a relatively high expression of hTR and telomerase activity in OLP. We suggest that hTR expression is associated with the high proliferation rate of OLP rather than being an indicator of malignant transformation.

ACKNOWLEDGEMENTS

The authors thank Dr N Keith, University of Glasgow, UK for donating the telomerase clone and for his technical advice, and Dr M Murphy, Department of Medicine and Therapeutics, University College, Dublin for providing the AB1 and AB2 primers. We also acknowledge the Charitable Infirmary Charitable Trust of Ireland and The Royal College of Surgeons of Ireland for their financial support.

Authors' affiliations

C O'Flatharta, M Leader, E Kay, W Robertson, M J E M F Mabruk, Department of Pathology, Royal College of Surgeons in Ireland and Beaumont Hospital, Beaumont Road, Dublin 9, Ireland
S R Flint, M Toner, Department of Oral Surgery, Oral Medicine, and Oral Pathology, School of Dental Science, Dublin Dental Hospital, Trinity College, Dublin, Ireland

REFERENCES

- 1 Scully C, El-Korm M. Lichen planus. A review and update on pathogenesis. *J Oral Pathol* 1985;**14**:421-58.
- 2 Mollaoglu N. Oral lichen planus: a review. *Br J Oral Maxillofac Surg* 2000;**38**:370-4.
- 3 Andreasen JO. Oral lichen planus. A clinical evaluation of 115 cases. *Oral Surg Oral Med Oral Pathol* 1968;**25**:31-41.
- 4 Eisenberg M. Oral lichen planus: a benign lesion. *J Oral Maxillofac Surg* 2000;**58**:1278-85.
- 5 Haapalainen T, Oksala O, Kallioinen M, *et al*. Destruction of the epithelial anchoring system in lichen planus. *J Invest Dermatol* 1995;**105**:100-13.
- 6 Sugarman PB, Savage NW, Zhou X, *et al*. Oral lichen planus: pathogenesis and treatment. *Clin Dermatol* 2000;**18**:533-9.
- 7 Van der Meij EH, Schepman KP, Smeele LE, *et al*. A review of the recent literature regarding malignant transformation of oral lichen planus. *Oral Surg Oral Med Oral Pathol Oral Radiol Endod* 1999;**88**:307-10.
- 8 Holmstrup P. The controversy of the premalignant nature of oral lichen planus is over. *Oral Surg Oral Med Oral Pathol* 1992;**73**:704-6.
- 9 Zhang L, Michelson C, Cheng X, *et al*. Molecular analysis of oral lichen planus. A premalignant lesion? *Am J Pathol* 1997;**151**:323-7.
- 10 Krutchkoff DJ, Cutler L, Laskowski S. Oral lichen planus: the evidence regarding potential malignant transformation. *J Oral Pathol Med* 1978;**7**:1-7.
- 11 Blackburn EH. Structure and function of telomeres. *Nature* 1991;**350**:569-73.
- 12 Allsopp RC, Chang E, Kashfi-Aazam M, *et al*. Telomere shortening is associated with cell division in vitro and in vivo. *Exp Cell Res* 1995;**220**:194-200.

- 13 **Shay JW**. Aging and cancer: are telomeres and telomerase the connection? *Mol Med Today* 1995;1:378–84.
- 14 **Allsopp RC**, Harley CB. Evidence for a critical telomere length in senescent human fibroblasts. *Exp Cell Res* 1995;219:130–6.
- 15 **Feng J**, Funk WD, Wang SS, *et al*. The RNA component of human telomerase. *Science* 1995;269:1236–41.
- 16 **Meyerson M**, Counter CM, Eaton EN, *et al*. hEST2, the putative human telomerase catalytic subunit gene, is up-regulated in tumor cells and during immortalization. *Cell* 1997;90:785–95.
- 17 **Harrington L**, McPhail T, Mar V, *et al*. A mammalian telomerase-associated protein. *Science* 1997;275:973–7.
- 18 **Kim NY**, Piatyzek MA, Prowse KR, *et al*. Specific association of human telomerase activity with immortal cells and cancer. *Science* 1994;266:2011–15.
- 19 **Mutirangura A**, Supiyaphun P, Trirekapan S, *et al*. Telomerase activity in oral leukoplakia and head and neck squamous cell carcinoma. *Cancer Res* 1996;56:3530–3.
- 20 **Califano J**, Ahrent S, Meiningner G, *et al*. Detection of telomerase activity in oral rinses from head and neck squamous cell carcinoma patients. *Cancer Res* 1996;56:5720–2.
- 21 **Chang LY**, Lin SC, Wong YK, *et al*. Telomerase activity and in situ telomerase RNA expression in oral carcinogenesis. *J Oral Pathol Med* 1999;28:399–6.
- 22 **Greider CW**. Telomerase activity, cell proliferation, and cancer. *Proc Natl Acad Sci U S A* 1998;95:90–2.
- 23 **Liao J**, Mitsuyasu T, Yamane K, *et al*. Telomerase activity in oral and maxillofacial tumours. *Oral Oncol* 2000;36:347–52.
- 24 **Fujimoto R**, Kamata N, Yokoyama K, *et al*. Expression of telomerase components in oral keratinocytes and squamous cell carcinomas. *Oral Oncol* 2001;37:132–40.
- 25 **Harle-Bachor C**, Boukamp P. Telomerase activity in the regenerative basal layer of the epidermis in human skin and in immortal and carcinoma-derived skin keratinocytes. *Proc Natl Acad Sci U S A* 1996;93:6476–81.
- 26 **Yasumoto S**, Kunimura C, Kikuchi K, *et al*. Telomerase activity in normal human epithelial cells. *Oncogene* 1996;18:433–9.
- 27 **Counter CM**, Gupta J, Harley CB, *et al*. Telomerase activity in normal leukocytes and in hematologic malignancies. *Blood* 1995;85:2315–20.
- 28 **Hiyama K**, Hirai Y, Kyoizumi S, *et al*. Activation of telomerase in human lymphocytes and hematopoietic progenitor cells. *J Immunol* 1995;155:3711–15.
- 29 **Kyo S**, Takakura M, Kohama T, *et al*. Telomerase activity in human endometrium. *Cancer Res* 1997;57:610–14.
- 30 **Ramirez RD**, Woodring EW, Shay JW, *et al*. Telomerase activity concentrated in the mitotically active segments of human hair follicles. *J Invest Dermatol* 1997;108:113–17.
- 31 **Thongprasom K**, Mutirangura A, Cheerat S. Telomerase activity in oral lichen planus. *J Oral Pathol Med* 1998;27:395–8.
- 32 **Piatyzek MA**, Kim NW, Weinrich SL, *et al*. Detection of telomerase activity in human cells and tumours by a telomeric repeat amplification protocol (TRAP). *Methods Cell Sci* 1995;17:1–15.
- 33 **Taylor RS**, Ramirez RD, Ogoshi M, *et al*. Detection of telomerase activity in malignant and non-malignant skin conditions. *J Invest Dermatol* 1996;106:759–65.
- 34 **Soria JC**, Morat L, Commo F, *et al*. Telomerase activation cooperates with inactivation of p16 in early head and neck tumorigenesis. *Br J Cancer* 2001;84:504–11.
- 35 **Soder AI**, Going JJ, Kaye SB, *et al*. Tumour specific regulation of telomerase RNA gene expression visualised by in situ hybridisation. *Oncogene* 1998;16:979–83.
- 36 **Shimamoto H**. Telomerase activity in oral squamous cell carcinoma and leukoplakia. *Kokubyo Gakkai Zasshi*. 2001;68:125–33.
- 37 **Sumida T**, Hamakawa H, Sogawa K, *et al*. Telomerase components as a diagnostic tool in human oral lesions. *Int J Cancer* 1999;80:1–4.
- 38 **Sumida T**, Sogawa K, Hamakawa H, *et al*. Detection of telomerase activity in oral lesions. *J Oral Pathol Med* 1998;27:111–15.
- 39 **Kannan S**, Tahara H, Yokozaki H, *et al*. Telomerase activity in premalignant and malignant lesions of human oral mucosa. *Cancer Epidemiol Biomarkers Prev* 1997;6:413–20.
- 40 **Nakano K**, Watney E, McDougall JK. Telomerase activity and expression of telomerase RNA component and telomerase catalytic subunit gene in cervical cancer. *Am J Pathol* 1998;153:857–64.
- 41 **Yashima K**, Ashfaq R, Nowak J, *et al*. Telomerase activity and expression of its RNA component in cervical lesions. *Cancer* 1998;82:1319–27.
- 42 **Ogoshi M**, Le T, Shay JW, *et al*. In situ hybridization analysis of the expression of human telomerase RNA in normal and pathologic conditions of the skin. *J Invest Dermatol* 1998;110:818–23.
- 43 **Broccoli D**, Young JW, de Lange T. Telomerase activity in normal and malignant hematopoietic cells. *Proc Natl Acad Sci U S A* 1995;92:9082–6.
- 44 **Harada K**, Yasoshima M, Ozaki S, *et al*. PCR and in situ hybridization studies of telomerase subunits in human non-neoplastic livers. *J Pathol* 2001;193:210–17.
- 45 **Yashima K**, Maitra A, Rogers BB, *et al*. Expression of the RNA component of telomerase during human development and differentiation. *Cell Growth Differ* 1998;9:805–13.
- 46 **Yashima K**, Piatyzek MA, Saboorian HM, *et al*. Telomerase activity and in situ telomerase RNA expression in malignant and non-malignant lymph nodes. *J Clin Pathol* 1997;50:110–17.
- 47 **Zhang L**, Zhang W. Telomerase hTR and hTERT gene expression in oral precancerous lesions and squamous cell carcinomas. *Chin J Dent Res* 1999;2:43–8.
- 48 **Yashima K**, Litzky LA, Kaiser L, *et al*. Telomerase expression in respiratory epithelium during the multistage pathogenesis of lung cancer. *Cancer Res* 1997;57:2373–7.
- 49 **Yashima K**, Ashfaq R, Nowak J, *et al*. Telomerase activity and expression of its RNA component in cervical lesions. *Cancer* 1998;82:1319–27.
- 50 **Brien TP**, Kallakury BV, Lowry CV, *et al*. Telomerase activity in benign endometrium and endometrial carcinoma. *Cancer Res* 1997;57:2760–4.
- 51 **Schifter M**, Jones AM, Walker DM. Epithelial p53 gene expression and mutational analysis combined with growth fraction assessment, in oral lichen planus. *J Oral Pathol Med* 1998 27:318–24.



Telomerase activity detected in oral lichen planus by RNA in situ hybridisation: not a marker for malignant transformation

C O'Flatharta, M Leader, E Kay, et al.

J Clin Pathol 2002 55: 602-607

doi: 10.1136/jcp.55.8.602

Updated information and services can be found at:

<http://jcp.bmj.com/content/55/8/602.full.html>

These include:

References

This article cites 46 articles, 16 of which can be accessed free at:

<http://jcp.bmj.com/content/55/8/602.full.html#ref-list-1>

Article cited in:

<http://jcp.bmj.com/content/55/8/602.full.html#related-urls>

Email alerting service

Receive free email alerts when new articles cite this article. Sign up in the box at the top right corner of the online article.

Topic Collections

Articles on similar topics can be found in the following collections

[Dermatology](#) (185 articles)

Notes

To request permissions go to:

<http://group.bmj.com/group/rights-licensing/permissions>

To order reprints go to:

<http://journals.bmj.com/cgi/reprintform>

To subscribe to BMJ go to:

<http://group.bmj.com/subscribe/>