

SHORT REPORT

Detection of the CD56+/CD45- immunophenotype by flow cytometry in neuroendocrine malignancies

G J Bryson, D Lear, R Williamson, R C W Wong

J Clin Pathol 2002;55:535-537

Aims: Antibodies against CD56 are primarily used in flow cytometric studies to detect natural killer cells. However, they may be useful in the identification of neuroendocrine malignancies, especially if the cells do not express CD45, indicating a non-leucocyte origin.

Methods: A retrospective review was conducted on all solid tissue flow cytometric studies performed between January 1997 and September 2001, to identify all cases with a CD56+/CD45- immunophenotype.

Results: Twelve neuroendocrine malignancies (five metastatic small cell carcinomas, three Merkel cell carcinomas, two metastatic undifferentiated neuroendocrine carcinomas, one metastatic pancreatic neuroendocrine carcinoma, and one neuroblastoma) were identified.

Conclusions: CD56+/CD45- neuroendocrine malignancies are only rarely detected in the flow cytometric analysis of solid tissue samples. However, the recognition of this immunophenotype is important to avoid their misclassification as natural killer cell malignancies. Furthermore, flow cytometry assists in the rapid identification of such cases, so that appropriate immunohistochemical studies can be performed to facilitate their correct diagnosis.

CD56 is the cluster differentiation (CD) assignment for the neural cell adhesion antigen, a membrane glycoprotein containing immunoglobulin-like domains.¹⁻³ CD56 is widely expressed throughout the molecular and granular layers of the cerebellum and cerebral cortex, and is strongly expressed throughout the grey and white matter of the spinal cord.¹ NK cells principally express the 140 kDa isoform of CD56.¹

The use of anti-CD56 antibodies, in immunohistochemical studies, has been reported to be of value in the diagnosis of neuroendocrine⁴⁻⁵ (for example, neuroblastoma, Merkel cell, and small cell carcinoma) and neuroectodermal⁶ (for example, Ewing's sarcoma) malignancies. In contrast, anti-CD56 antibodies are primarily used in flow cytometric studies to detect NK cells, although their usefulness in the detection of neuroectodermal malignancies,⁶ and their binding to small cell carcinoma cell lines⁷ have been reported.

CD59 is expressed on a variety of cell types including natural killer cells, certain T cell subsets, large granular lymphocyte leukaemias, some myeloid leukaemias, and cells of neural origin.^{1,2}

We now report a characteristic CD56+/CD45- immunophenotype in 12 neuroendocrine malignancies, with the absence of CD45 expression consistent with their non-leucocyte origin.⁸

METHODS

Since 1997, the immunology laboratory of Queensland Health Pathology Services at the Royal Brisbane Hospital has used

Table 1 Final histological diagnoses of the CD56+/CD45- malignancies

Case	Specimen	Final diagnosis
1	Lymph node	Merkel cell carcinoma
2	Parotid gland	Metastatic small cell carcinoma (unknown primary)
3	Lymph node	Metastatic small cell carcinoma (unknown primary)
4	Lymph node	Metastatic undifferentiated neuroendocrine carcinoma
5	Lymph node	Metastatic pancreatic neuroendocrine carcinoma
6	Lymph node	Merkel cell carcinoma
7	Lymph node	Metastatic undifferentiated neuroendocrine carcinoma
8	Lymph node	Merkel cell carcinoma
9	Lymph node	Metastatic small cell carcinoma (lung primary)
10	Lymph node	Metastatic small cell carcinoma (unknown primary)
11	Chest wall mass	Metastatic small cell carcinoma (unknown primary)
12	Temple mass	Neuroblastoma

anti-CD56 antibodies conjugated to phycoerythrin (anti-CD56-PE) in the flow cytometric evaluation of tissue specimens for suspected lymphoma. Anti-CD56-PE, derived from the N901 (NKH-1) clone,⁹ was used in the following three colour fluorochrome combination on a Beckman Coulter XL (Beckman Coulter, Miami, Florida, USA) flow cytometer: anti-CD56-PE, anti-CD3-FITC (fluorescein isothiocyanate) and anti-CD45-PECY5 (phycoerythrin-cyanin 5 tandem). All three conjugated monoclonal antibodies were supplied by Beckman Coulter.

A retrospective review was conducted of all such studies performed between January 1997 and September 2001 to identify all cases with a CD56+/CD45- immunophenotype.

RESULTS

From approximately 2000 studies, we identified 12 specimens that expressed the CD56+/CD45- immunophenotype (table 1). All cases were neuroendocrine malignancies, comprising five metastatic small cell carcinomas (four from an unknown primary, one from a lung primary), three Merkel cell carcinomas, two metastatic undifferentiated neuroendocrine carcinomas, one metastatic pancreatic neuroendocrine carcinoma, and one neuroblastoma.

All 12 cases demonstrated the same immunophenotype, with expression of CD56 but no expression of T cell antigens (CD3, CD5, CD7), B cell antigens (CD19, CD20), or the

Abbreviations: CD, cluster differentiation; FITC, fluorescein isothiocyanate; NK, natural killer; PE, phycoerythrin; PECY5, phycoerythrin-cyanin 5 tandem

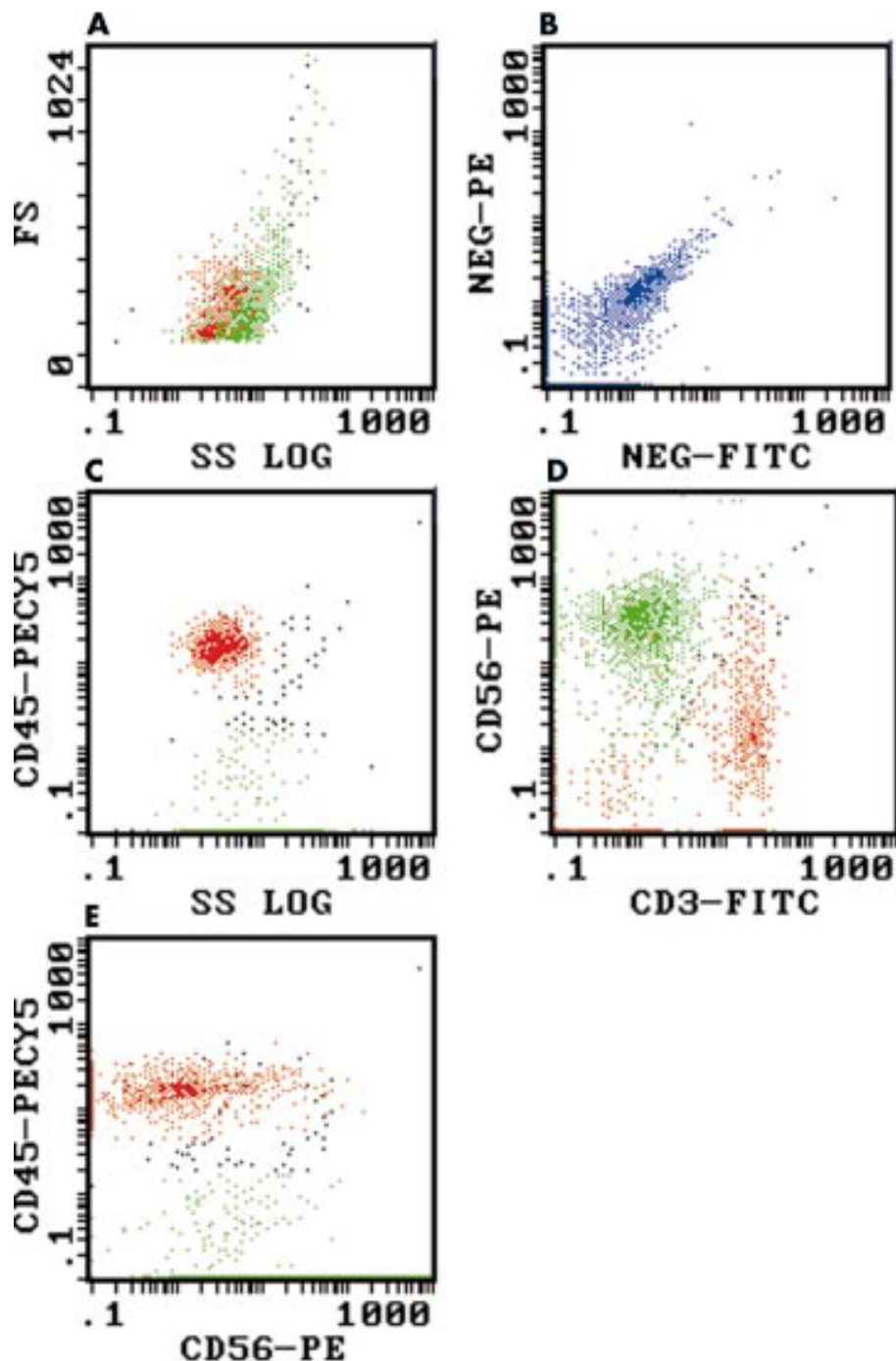


Figure 1 Flow cytometric dot plots of a metastatic small cell carcinoma of unknown primary (case 10), demonstrating CD56 expression in the absence of CD45 expression. The lymphoid (red) and small cell carcinoma populations (green) were colour backgated from the log 90° side scatter versus anti-CD45-PECY5 (phycoerythrin-cyanin 5 tandem) plot (see (C) below). (A) Log 90° side scatter (SS) versus forward scatter (FS): the lymphoid population (red) overlaps the small cell carcinoma population (green). (B) FITC (fluorescein isothiocyanate) versus PE (phycoerythrin) isotype controls: demonstrating the presence of significant autofluorescence/non-specific staining (blue) in this sample. (C) Log 90° side scatter versus anti-CD45-PECY5: the lymphoid population (red) is clearly CD45+ whereas the small cell carcinoma population (green) is CD45-, although autofluorescence/non-specific staining results in apparent weak CD45 expression. (D) Anti-CD3-FITC versus anti-CD56-PE: the small cell carcinoma population (green) is CD56+/CD3- (autofluorescence/non-specific staining again results in apparent weak CD3 expression) and clearly distinct from the lymphocytes (red). (E) Anti-CD56-PE versus anti-CD45-PECY5: the small cell carcinoma population (green) is CD56+/CD45- (apparent weak CD45 expression as a result of autofluorescence/non-specific staining), whereas the lymphocytes (red) are CD45+.

common leucocyte antigen CD45. Figure 1 shows a representative flow cytometric study from case 10 (metastatic small cell carcinoma) demonstrating the CD56+/CD45- immunophenotype. It is important to note that significant autofluorescence/non-specific staining is often exhibited by non-haematopoietic malignancies (fig 1B). Therefore, care

should be taken not to misinterpret such autofluorescence/non-specific staining as weak CD45 expression (fig 1C,E).

DISCUSSION

In our laboratory, CD56+/CD45- neuroendocrine malignancies are only rarely detected in solid tissue specimens, with

Take home messages

- Anti-CD56 antibodies should be included in flow cytometric studies of solid tissue specimens wherever possible
- Recognition of the CD56+/CD45- immunophenotype can help avoid the potential misclassification of such specimens as natural killer cell malignancies, especially if autofluorescence/non-specific staining is misinterpreted as weak CD45 expression
- The CD56+/CD45- immunophenotype is a useful rapid indicator for the presence of neuroendocrine malignancies, thus leading to the appropriate immunohistochemical studies necessary to facilitate their correct diagnosis

only 12 cases seen in approximately 2000 specimens (0.6%) over five and three quarter years. However, this figure is probably an underestimate, because the anti-CD56-PE/anti-CD3-FITC/anti-CD45-PC5 combination was not used in studies where the number of retrieved cells was limited—for example, small biopsy specimens.

Anti-CD56 antibodies have been reported to be of value in the identification of neuroendocrine malignancies by immunohistochemical studies.^{4,5} Our cases illustrate that anti-CD56 antibodies can also be used in flow cytometric studies to identify these malignancies, with the added advantage that the concurrent use of anti-CD45 and anti-CD56 antibodies in three (or more) colour fluorochrome antibody panels also enables demonstration of the non-leucocyte lineage (negative CD45 expression)⁸ of these malignancies.

Three of the 12 CD56+/CD45- malignancies were Merkel cell carcinomas, sometimes referred to as primary neuroendocrine carcinomas of the skin.⁵ These uncommon malignancies exhibit the following immunohistochemical characteristics: staining for keratin 20 (approximately 90% of cases), chromogranin A (approximately 33% of cases), CD57 (approximately 15% of cases), and synaptophysin in a minority of cases.⁵ Our study demonstrates the usefulness of the CD56+/CD45- immunophenotype in raising the possibility of Merkel cell carcinoma, although this immunophenotype is not specific for this particular neuroendocrine malignancy.

“Our study demonstrates the usefulness of the CD56+/CD45- immunophenotype in raising the possibility of Merkel cell carcinoma”

The detection of CD56 and CD57 expression on neuroectodermal malignancies by flow cytometry has been reported previously,⁶ but the expression of CD45 in these cases was not mentioned, probably because only two colour flow cytometric studies were performed. However, because neuroectodermal

malignancies are not routinely sent to our department for flow cytometric studies, we were unable to determine whether these malignancies would also demonstrate the CD56+/CD45- immunophenotype. Furthermore, because we do not routinely test for CD57 expression, we are unable to comment on whether the 12 neuroendocrine malignancies in our series would have also expressed CD57.

Our study highlights the usefulness and importance of including anti-CD56 antibodies in flow cytometric studies of solid tissue specimens wherever possible. Furthermore, the recognition of this CD56+/CD45- immunophenotype is important to avoid the potential misclassification of such specimens as NK cell malignancies, especially if autofluorescence/non-specific staining is misinterpreted as weak CD45 expression.

In conclusion, we report that flow cytometric detection of the CD56+/CD45- immunophenotype is a useful rapid indicator for the presence of neuroendocrine malignancies, thus leading to the appropriate immunohistochemical studies necessary to facilitate their correct diagnosis.

Authors' affiliations

G J Bryson, R C W Wong, Division of Immunology, Queensland Health Pathology Services, Royal Brisbane Hospital, Herston, Queensland 4029, Australia

R Williamson, Division of Anatomical Pathology, Queensland Health Pathology Services

D Lear, Sullivan Nicolaides Pathology, Taringa, Queensland 4068, Australia

Correspondence to: Dr R C W Wong, Division of Immunology, Queensland Health Pathology Services, Royal Brisbane Hospital, Herston 4029, Queensland, Australia; richard_wong@health.qld.gov.au

Accepted for publication 4 February 2002

REFERENCES

- 1 **Lanier LL**, Testi R, Bindl J, *et al*. Identity of Leu-19 (CD56) leukocyte differentiation antigen and neural cell adhesion molecule. *J Exp Med* 1989;**169**:2233–38.
- 2 **Knapp W**, Dorken B, Rieber P, *et al*. CD antigens 1989. *Blood* 1989;**74**:1448–50.
- 3 **Brackenbury R**. Expression of neural cell adhesion molecules in normal and pathologic tissues. *Ann N Y Acad Sci* 1988;**540**:39–46.
- 4 **Fischler DF**, Bauer TW, Tubbs RR. Tissue reactivity of anti-Leu19. *Histopathology* 1992;**21**:563–7.
- 5 **Wick MR**. Immunohistology of neuroendocrine and neuroectodermal tumors. *Semin Diagn Pathol* 2000;**17**:194–203.
- 6 **Gardner LJ**, Polski JM, Fallon R, *et al*. Identification of CD56 and CD57 by flow cytometry in Ewing's sarcoma or primitive neuroectodermal tumor. *Virchows Arch* 1998;**433**:35–40.
- 7 **Koros AM**, Bey EA, Conley SL, *et al*. Phenotypic differences among morphologically similar small-cell carcinomas detected with a panel of monoclonal antibodies and indirect immunofluorescence and flow cytometry. *Int J Cancer Suppl* 1994;**8**:127–31.
- 8 **Shah VO**, Civin CI, Loken MR. Flow cytometric analysis of human bone marrow. IV. Differential quantitative expression of T-200 common leukocyte antigen during normal hemopoiesis. *J Immunol* 1988;**140**:1861–7.
- 9 **Cell analysis 2000: Beckman Coulter Catalog**. 2000; Bulletin 9140:117.

PostScript

CORRESPONDENCE

If you have a burning desire to respond to a paper published in *Journal of Clinical Pathology*, why not make use of our "rapid response" option?

Log on to our website (www.jclinpath.com), find the paper that interests you, and send your response via email by clicking on the "eLetters" option in the box at the top right hand corner.

Providing it isn't libellous or obscene, it will be posted within seven days. You can retrieve it by clicking on "read eLetters" on our homepage.

The editors will decide as before whether to also publish it in a future paper issue.

Acute erythremic myelosis (true erythroleukaemia): a variant of AML FAB-M6

Our group has been actively researching the acute erythroleukaemias since the late 1980s, during which time, we have developed and extensively published our classification¹⁻³:

- acute erythroleukaemia, M6a (traditional FAB-M6, DiGuglielmo's syndrome, 1917)
- acute erythroleukaemia, M6b (pure erythroleukaemia, DiGuglielmo's disease, 1926)
- acute erythroleukaemia, M6c (mixed erythroleukaemia).

We have also published abstracts and presented this classification at meetings of the International Academy of Pathology, International Society of Haematology, and the American Society of Haematology, and our recommendations have also been cited in the recent literature. Therefore, we are surprised to find the M6b subtype now "discovered" and re-named in the article by Hasserjian *et al.*⁶ and the M6c subtype completely overlooked. Although we suspect this incongruity to be an oversight, we believe it is important to set the record straight.

This established classification of the acute erythroleukaemias is based partly on the old FAB criteria and also upon morphological, cytochemical, and immunophenotypical criteria.² All bone marrow aspirates demonstrate $\geq 50\%$ erythrocytic precursors, with erythroid dysplasia. Dysplasia of the granulocytic and megakaryocytic cell lines may or may not be present. The M6a subtype is defined as $\geq 30\%$ blasts of the non-erythrocytic component (FAB exclusion criteria); the M6b subtype is defined as $\geq 30\%$ pronormoblasts of the erythrocytic elements; and the M6c subtype has $\geq 30\%$ blasts and $\geq 30\%$ pronormoblasts by the aforementioned exclusion criteria. Because the dysplastic changes may, at times, make definitive characterisation of the blasts as erythrocytic versus non-erythrocytic difficult, the morphological features must always be confirmed by cytochemical stains, immunohistochemical stains, and/or flow cytometric analysis.

These three separate subtypes must be distinguished from one another to provide useful prognostic information for the clinician and the patient. When treated with the standard myeloid protocol, the M6a and M6c subtypes demonstrate a very high remission rate, whereas most patients with the M6b subtype remain refractory to treatment. Notably, patients with the M6c subtype remain in remission for a significantly shorter time than the M6a group. Mean survival for these subtypes is: M6a, 31.4 (SD, 32) months; M6b, 3.15 (SD, 4.2) months; M6c, 10.5 (SD, 12.7) months.

The malignant clonal cell of origin manifesting as acute erythroleukaemia of any subtype appears to be a multipotential stem cell,³ which shows varying degrees of erythrocytic and granulocytic lineage maturation. Therefore, the three distinct subtypes of acute erythroleukaemia are not three separate diseases, but rather represent a spectrum of the same disease. The poor remission rate and short survival characteristic of this disorder³ are dependent upon: (1) a high pronormoblast to myeloblast ratio within diagnostic bone marrow aspirates, (2) a high proliferative index, (3) "unfavourable" cytogenetic aberrations, and (4) a high

incidence of P-glycoprotein expression (the multidrug resistance phenotype).

F M Mazzella

Medical College of Georgia, Augusta,
30912-3605 Georgia, USA;
fmazzella@mail.mcg.edu

H R Schumacher

University of Cincinnati Medical Centre, Cincinnati,
45367 Ohio, USA

References

- 1 Kowal-Vern A, Cotelingam J, Schumacher HR. The prognostic significance of proerythroblasts in acute erythroleukemia. *Am J Clin Pathol* 1992;**98**:34-40.
- 2 Mazzella FM, Kowal-Vern A, Shrit MA, *et al.* Acute erythroleukaemia: evaluation of 48 cases with reference to classification, cell proliferation, cytogenetics and prognosis. *Am J Clin Pathol* 1998;**110**:590-8.
- 3 Mazzella FM, Tolbert D, Kowal-Vern A, *et al.* p53 gene mutation in acute erythroleukaemia: differences among subtypes M6a, M6b, and M6c. *Lab Haematol* 1999;**5**:1-9.
- 4 Mazzella FM, Kowal-Vern A, Shrit MA, *et al.* Effects of multidrug resistance gene expression in acute erythroleukaemia. *Mod Pathol* 2000;**13**:407-13.
- 5 Mazzella FM, Alvares C, Kowal-Vern A, *et al.* The acute erythroleukaemias. *Clin Lab Med* 2000;**20**:119-37.
- 6 Hasserjian RP, Howard J, Wood A, *et al.* Acute erythremic myelosis (true erythroleukaemia): a variant of AML FAB-M6. *J Clin Pathol* 2001;**54**:205-9.

CORRECTIONS

A comparison of 13 guinea pig and human anti-tissue transglutaminase antibody ELISA kits. Wong RCW, Wilson RJ, Steele RH, *et al.* *J Clin Pathol* 2002;**55**:488-95. The affiliation of Dr RH Steele should be South Western Area Pathology Service.

Detection of the CD56+/CD45- immunophenotype by flow cytometry in neuroendocrine malignancies. Bryson GJ, Lear D, Williamson R, *et al.* *J Clin Pathol* 2002;**55**:535-7. The quotation on page 535 was inadvertently cut out of the first paragraph (it should have remained there as the second sentence) and should begin with CD56 not CD59.



Detection of the CD56+/CD45- immunophenotype by flow cytometry in neuroendocrine malignancies

G J Bryson, D Lear, R Williamson, et al.

J Clin Pathol 2002 55: 535-537

doi:

Updated information and services can be found at:

<http://jcp.bmj.com/content/55/7/535.full.html>

These include:

Data Supplement

"*Publisher's Correction*"

<http://jcp.bmj.com/content/suppl/2002/09/19/55.7.535.DC1.html>

References

This article cites 8 articles, 3 of which can be accessed free at:

<http://jcp.bmj.com/content/55/7/535.full.html#ref-list-1>

Email alerting service

Receive free email alerts when new articles cite this article. Sign up in the box at the top right corner of the online article.

Topic Collections

Articles on similar topics can be found in the following collections

[Immunology \(including allergy\)](#) (1279 articles)
[Endocrine cancer](#) (65 articles)
[Cancer: dermatological](#) (87 articles)
[Dermatology](#) (185 articles)
[Paediatric oncology](#) (99 articles)
[Lung cancer \(oncology\)](#) (76 articles)
[Lung cancer \(respiratory medicine\)](#) (76 articles)
[Pancreas and biliary tract](#) (114 articles)

Notes

To request permissions go to:

<http://group.bmj.com/group/rights-licensing/permissions>

To order reprints go to:

<http://journals.bmj.com/cgi/reprintform>

To subscribe to BMJ go to:

<http://group.bmj.com/subscribe/>