

PostScript

LETTERS TO JCP

If you have a burning desire to respond to a paper published in *Journal of Clinical Pathology*, why not make use of our "rapid response" option?

Log on to our website (www.jclinpath.com), find the paper that interests you, and send your response via email by clicking on the "eLetters" option in the box at the top right hand corner.

Providing it isn't libellous or obscene, it will be posted within seven days. You can retrieve it by clicking on "read eLetters" on our homepage.

The editors will decide as before whether to also publish it in a future paper issue.

The culture of lactobacilli species in gastric carcinoma

Filamentous organisms have been reported in brushings and biopsies from both benign and malignant gastric ulcers,^{1,2} but these have not been characterised and their importance is unknown. In a preliminary study of tissue samples obtained at laparotomy from malignant gastric ulcers we cultured *Lactobacillus* spp, which are recognised commensals in the upper gastrointestinal tract,³ but not normally present in the stomach.

In view of the previous culture of *Lactobacilli* spp in surgically excised gastric tumours, we prospectively sought evidence of *Lactobacilli* spp infection of benign and malignant gastric ulcers in patients attending for gastroscopy.

Gastric mucosal biopsies were obtained from normal mucosa, erosions, and from benign and malignant ulcers in patients undergoing routine gastroscopy in our unit. The endoscopic biopsies were immediately placed into 5 ml of semisolid De Man, Rogosa, Sharpe (MRS) culture medium for transportation to the laboratory. Biopsies were then plated on to the following: (1) 5% blood agar and MRS agar incubated in CO₂ at 37°C; and (2) neomycin agar and MRS agar incubated anaerobically at 37°C. After incubation for 48 hours, any probable *Lactobacillus* spp were subcultured to blood agar and Gram staining was performed. The cultures were re-checked

at five days for slow growing strains. All Gram positive bacilli were stored at -70°C for later identification by catalase reaction and a profile using a gallery scheme (API 50 CHL) and fermentation of 49 carbohydrates.

In total, 39 patients were studied. Histology of the gastric biopsies revealed: adenocarcinoma (n = 9), gastric lymphoma (n = 2), benign gastric ulcer (n = 8), gastric erosions (n = 11), and normal mucosa (n = 9). All strains of *Lactobacillus* spp had grown at 48 hours.

Ten of 11 malignant and six of eight benign gastric ulcers grew *Lactobacillus* spp. In addition, *Lactobacillus* spp were cultured in four of 11 gastric erosions but all the normal specimens were negative for culture. Some specimens yielded more than one species. Some lactobacilli could not be speciated. Table 1 shows the numbers of specimens with each histological diagnosis that were culture positive for the individual species of lactobacillus.

These data demonstrate that *Lactobacillus* spp colonise areas of both malignant and benign gastric ulceration but not normal mucosa. It is probable, but not confirmed, that these are the filamentous organisms previously described in similar samples. Although we cannot exclude a role for these bacteria in the aetiology of gastric ulceration, it seems most likely that they opportunistically colonise the necrotic tissue in areas of ulceration of whatever cause. Clarification of the mechanisms that underlie this phenomenon might provide a means to target gastric malignancy both for diagnosis and treatment. Additional work is needed to explore the relation between gastric ulceration and *Lactobacillus* spp.

P J Roberts, R J Dickinson

Department of Gastroenterology, Hinchingsbrooke Hospital, Hinchingsbrooke Park, Huntingdon, Cambridgeshire PE29 6NT, UK

A Whitehead

Department of Histopathology, Hinchingsbrooke Hospital

C R Loughton, J E Foweraker

Department of Microbiology, Papworth Hospital, Cambridgeshire, UK

References

- Sanders DSA, Hussein KA. Filamentous organisms in gastric brushings and gastric cancer diagnosis. *Diagn Cytopathol* 1991;7:11-13
- Wilson CA, Young JA, Sanders DSA. Filamentous organisms in benign and malignant gastric cytology brushings. *Cytopathology* 1996;7:268-73.

- Sjostedt S, Kager L, Heimdahl A, et al. Microbial colonization of tumours in relation to the upper gastrointestinal tract in patients with gastric carcinoma. *Ann Surg* 1988;207:341-6.

Digital imaging of surgical specimens

Matthews and Denney recently described in this journal a method for digitally recording gross specimen images.¹ We agree that flatbed scanners are excellent for this purpose and recently outlined our findings using a similar method.² In fact, we have found that excellent images can be obtained without the need for a box to contain the specimen in fluid. The sample is simply placed on the device and scanned. Some imaging experts recommend the use of a black background rather than the white surface, which is standard on the scanner lid underside, although we have found little improvement using this modification.

It should also be noted that excellent results can be obtained from scanning histological sections mounted in 35 mm slide holders.³ However, this does require the acquisition of a 35 mm colour slide scanner, which is relatively expensive. The whole mount sections can also be used in a standard slide projector.

In laboratories already using computer technology, flatbed scanning provides a very convenient, cheap, and rapid form of recording gross images, with results obtained superior to conventional photocopying. Furthermore, annotations such as patient identification, orientation, and block site can be added to the image immediately and permanently stored.

T W Beer

Department of Anatomical Pathology, Royal Perth Hospital, GPO Box X2213 WA 6001, Australia

References

- Matthews TJ, Denney PA. Digital imaging of surgical specimens using a wet scanning technique. *J Clin Pathol* 2001;54:326-7.
- Beer TW. Scanning of gross specimens [letter]. *Am J Surg Pathol* 2000;24:1170-1.
- Ventura L, Leocata P. Digital scanning of histologic sections [letter]. *Am J Surg Pathol* 1999;23:1435.

Recurrent cellular angiofibroma of the vulva

Cellular angiofibroma is a benign mesenchymal lesion that was first described in 1997,¹ and which chiefly involves the vulval region. The original report described four cases of this distinctive lesion, all occurring in middle aged women, and the authors considered this to represent a benign neoplasm with little or no potential for local recurrence if excised with a rim of uninvolved normal tissue. Since then, an identical lesion has been described in a woman involving the subcutaneous tissue of the chest wall.² Similar lesions have also been reported in the inguinoscrotal region of men.³ Here, we describe a vulval cellular angiofibroma that, although initially excised with a rim of normal tissue, exhibited tumour recurrence in a relatively short time period.

A 49 year old woman presented with a mass in the posterior aspect of the left labia majora.

Table 1 The culture of lactobacilli species

Lactobacilli species	Histology			
	Lymphoma (n=2)	Adenocarcinoma (n=9)	Benign GU (n=8)	Erosion (n=11)
<i>L paracasei</i>	2	1	0	1
<i>L fermentum</i>	1	5	5	2
<i>L rhamnosus</i>	0	1	0	0
<i>L salivarius</i>	0	1	1	0
<i>L delbreuckii</i>	0	1	0	0
<i>L acidophilus</i>	0	0	1	0
<i>Lactobacillus</i> sp.	0	3	2	2

GU, gastric ulcer.

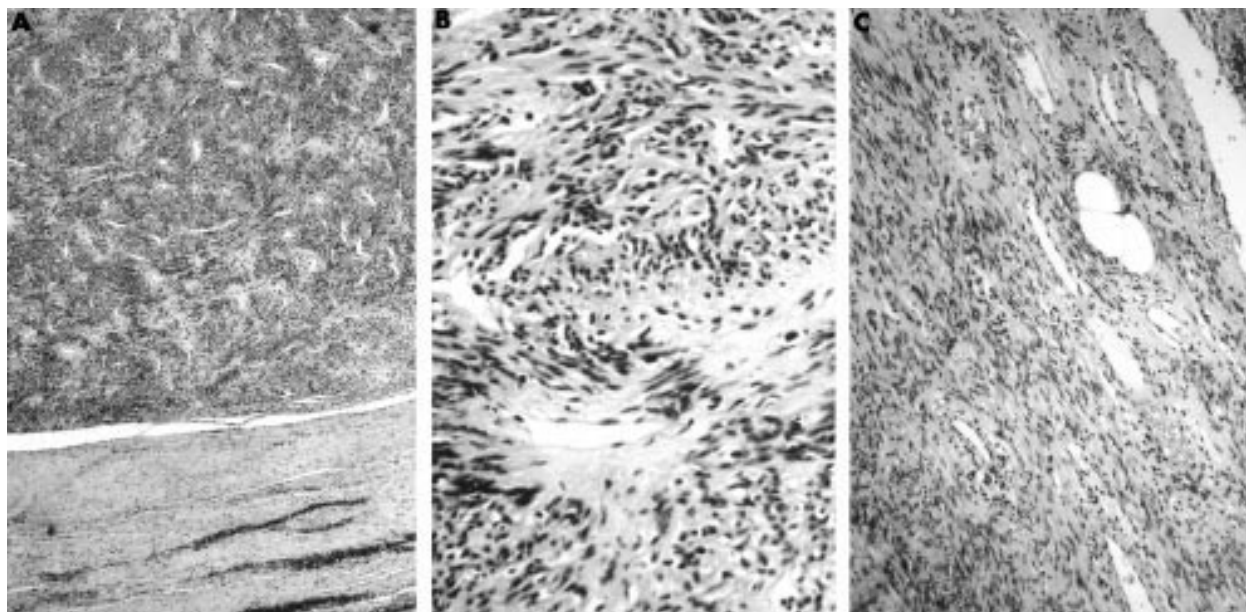


Figure 1 (A) Initial biopsy showing well circumscribed lesion composed of short interlacing bundles and fascicles of spindle shaped cells. (B) There is a prominent vasculature within the lesion with thick walled hyalinised blood vessels. (C) Small numbers of mature adipocytes are present within the lesion.

A well circumscribed lesion measuring 4 cm in diameter was excised with a rim of normal tissue. Six months later she developed a recurrent swelling at the site of the previous excision. This lay in the angle between the posterior wall of the vagina and the anterior aspect of the external anal sphincter. A magnetic resonance imaging scan confirmed the presence of a recurrent lesion and the mass was excised. The mass was well circumscribed and was dissected free without complication. Ten months after excision of the recurrent lesion the patient is well with no further evidence of local recurrence.

The original surgical specimen consisted of a well circumscribed 4 cm firm white lesion, which was completely surrounded by a rim of normal tissue. The recurrent lesion consisted of a well circumscribed 6.5 cm diameter firm white lesion.

Histology of the original biopsy showed a well circumscribed but unencapsulated lesion, which was completely surrounded by a rim of compressed uninvolved tissue. The lesion was composed of short interlacing bundles and fascicles of spindle shaped cells with bland vesicular nuclei and abundant eosinophilic cytoplasm (fig 1A). There was no necrosis and few or no mitotic figures. A notable feature was the prominent vasculature of the lesion and many of the blood vessels were characterised by thick hyalinised walls (fig 1B). Small numbers of mature adipocytes were present within the lesion, especially around the periphery (fig 1C) and there were scattered stromal mast cells and occasional small collections of mature lymphocytes. Histology of the recurrent lesion showed similar features. Again the lesion was well circumscribed. There were foci of mildly increased cellularity and decreased vascularity compared with the original lesion and scattered mitotic figures were identified, the mitotic count being < 1/10 high power fields. An additional feature was the presence of many small lymphoid aggregates throughout the lesion. These were mostly composed of mature lymphocytes with occasional germinal centres (fig 2).

Immunohistochemistry of both the original and recurrent lesion showed positivity of the

spindle shaped cells for vimentin (Dako, Copenhagen, Denmark) but no staining for desmin (Dako), α smooth muscle actin (Sigma, Poole, Dorset, UK), S-100 protein (Diagnostic Products Limited, Abingdon, UK), CD34 (Serotec, Oxford, UK), or AE1/AE3 (Dako). There was weak staining for epithelial membrane antigen (EMA; Dako). There was diffuse strong nuclear positivity for the oestrogen receptor (ER; clone ID5; Dako; fig 3) and the progesterone receptor (PR; clone 1Ab; Dako).

Electron microscopy showed spindle shaped tumour cells embedded in a collagen rich matrix containing vascular channels. Most of the tumour cells had a fibroblastic appearance with prominent cisterni of rough endoplasmic reticulum. Some of the tumour cells contained

small numbers of cytoplasmic actin filaments with focal deposits of external lamina and occasional subplasmalemmal densities, in keeping with myofibroblastic differentiation.

The lesion we describe, which exhibits identical histological features to the cases of cellular angiofibroma reported by Nucci *et al*,¹ was characterised by local recurrence in a relatively short period of six months. This was in spite of the fact that the lesion was adequately excised originally with a rim of uninvolved tissue. This is the first report of recurrence of a cellular angiofibroma and illustrates the potential for local recurrence even with adequate excision. The recurrent lesion contained foci of increased cellularity but there were no histological features to suggest malignancy. We do not feel that the fact that the neoplasm recurred is indicative of malignancy.

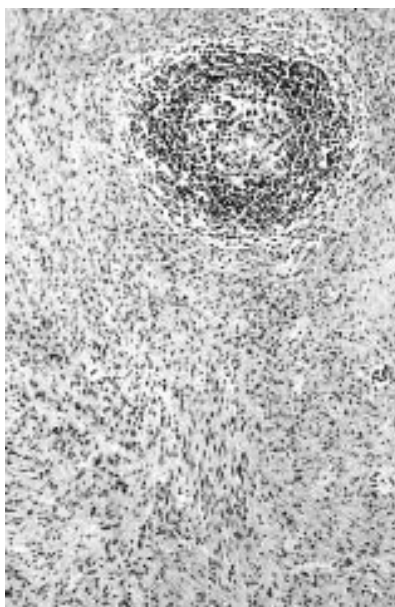


Figure 2 Recurrent lesion showing collection of lymphocytes with germinal centre formation.

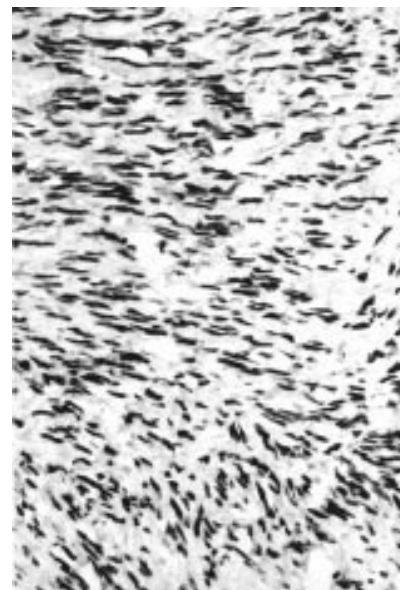


Figure 3 There is strong nuclear staining with antibody to the oestrogen receptor.

It is not our purpose here to reiterate in detail the morphological differential diagnosis of cellular angiofibroma, which has been adequately dealt with previously.^{1,4} However, in the vulval region this differential diagnosis may include neoplasms that are relatively specific to this site, such as aggressive angiomyxoma and angiomyo-fibroblastoma. Other neoplasms that are not specific to the vulva, such as solitary fibrous tumour, spindle cell lipoma, superficial angiomyxoma, smooth muscle tumours, nerve sheath tumours, and perineurioma, also enter into the differential diagnosis. The distinction of cellular angiofibroma from these lesions is predominantly by morphology, although ancillary immunohistochemical studies may contribute. Cellular angiofibroma is characterised by vimentin positivity together with negative staining for desmin, α smooth muscle actin, and S-100 protein. Negative staining for desmin and α smooth muscle actin helps to exclude aggressive angiomyxoma, angiomyo-fibroblastoma, and smooth muscle neoplasms, whereas the lack of staining for S-100 protein excludes a nerve sheath tumour. However, it should be stressed that in many of these lesions there is immunohistochemical overlap and close morphological examination remains the mainstay of diagnosis.

The present tumour was negative for CD34, excluding a solitary fibrous tumour, which has been described in this region.³ Although cellular angiofibroma was initially thought to be CD34 negative, two additional cases described in addendum to the original publication were found to be positive, with cellular angiofibroma thus joining the ever increasing list of mesenchymal lesions that may express the CD34 antigen.

The case we describe exhibited weak positive staining for EMA, which has not been described previously. EMA positivity raises the possibility of a perineurioma, a benign lesion of perineural cells.⁶ However, perineurioma characteristically exhibits a prominent storiform growth pattern and moreover ultrastructural examination in our patient revealed no evidence of perineural differentiation. Rather, electron microscopy showed fibroblastic and myofibroblastic features. The predominant fibroblastic differentiation is in keeping with a vimentin positive but desmin and α smooth muscle actin negative immunophenotype; positivity with the last two antibodies being more characteristic of myofibroblastic than fibroblastic differentiation.

The present lesion exhibited diffuse strong positivity for ER and PR. A recent study investigating the hormone status of a variety of vulvovaginal mesenchymal lesions found most of these to be positive for ER and/or PR,⁷ and positivity may simply be a reflection of the presence of these receptors normally in subepithelial mesenchymal cells of the lower female genital tract. Nucci *et al* did not perform immunostaining for ER or PR on their patients but, interestingly, the cellular angiofibroma involving the chest wall exhibited no staining for ER or PR.²

W G McCluggage

Department of Pathology, Royal Group of Hospitals Trust, Grosvenor Road, Belfast BT12 6BL, Northern Ireland, UK; glenn.mccluggage@bll.ni.nhs.uk

M Perenyi

Department of Pathology, Belfast City Hospital Trust

S T Irwin

Department of Surgery, Royal Group of Hospitals Trust

References

- 1 Nucci MR, Granter SR, Fletcher CDM. Cellular angiofibroma: a benign neoplasm

distinct from angiomyo-fibroblastoma and spindle cell lipoma. *Am J Surg Pathol* 1997;**21**:636–44.

- 2 Garijo MF, Val-Bernal JF. Extravulvar subcutaneous cellular angiofibroma. *J Cutan Pathol* 1998;**25**:327–32.
- 3 Laskin WB, Fetsch JF, Mostofi FK. Angiomyo-fibroblastoma like tumor of the male genital tract. Analysis of 11 cases with comparison to female angiomyo-fibroblastoma and spindle cell lipoma. *Am J Surg Pathol* 1998;**22**:6–16.
- 4 Nucci MR, Fletcher CDM. Vulvovaginal soft tissue tumours: update and review. *Histopathology* 2000;**36**:97–108.
- 5 Fukunaga M. Atypical solitary fibrous tumor of the vulva. *Int J Gynecol Pathol* 2000;**19**:164–8.
- 6 Robson AM, Calonje E. Cutaneous perineurioma: a poorly recognised tumour often misdiagnosed as epithelioid histiocytoma. *Histopathology* 2000;**37**:332–9.
- 7 McCluggage WG, Maxwell P. Aggressive angiomyxoma of pelvic parts exhibits oestrogen and progesterone receptor positivity. *J Clin Pathol* 2000;**53**:603–5.

CSF spectrophotometry in the diagnosis of subarachnoid haemorrhage

We note with interest the recent "Best Practice" article on cerebrospinal fluid (CSF) spectrophotometry in the diagnosis of subarachnoid haemorrhage (SAH) by Dr Cruickshank.¹ As a group that has produced a set of proposed national guidelines for the practice of spectrophotometry,² we wish to highlight several important differences between the two sets of recommendations.

Most importantly, Dr Cruickshank concludes that, as long as a CSF sample containing up to $40\,000 \times 10^6$ erythrocytes/litre is centrifuged within 15 minutes, no oxyhaemoglobin will be seen in the supernatant after centrifugation, and that within this cell count and time constraint, the presence of oxyhaemoglobin in CSF is supportive of SAH. This is entirely consistent with her *in vitro* data,³ although the only practical way of achieving CSF delivery within this time would appear to be by pneumatic tube, itself a cause of artefactual haemolysis.⁴ However, there are other *in vitro* data that allow for a longer time lapse before centrifugation. Thus, we know that variously $10\,000 \times 10^6$ erythrocytes/litre can be left for up to 30 minutes⁵ and 4000×10^6 erythrocytes/litre can be left for up to 24 hours⁶ without oxyhaemoglobin appearing in the supernatant.

It is when we come to *in vivo* work that the data are conflicting. Again, Dr Cruickshank's conclusions are consistent with her data from patients undergoing spinal anaesthesia—that red blood cell counts from < 5 to 2215×10^6 /litre in CSF samples centrifuged within 40 minutes of puncture resulted in no detectable oxyhaemoglobin³—and also with data from Barrows *et al*.⁷ Such data are nevertheless at variance with those of Fahie-Wilson and Park, who found that red blood cell counts from 64 to 705×10^6 /litre in CSF samples centrifuged as soon as possible after receipt resulted in significant oxyhaemoglobin detectable in the supernatant.⁶ This set of experiments was performed because initial observations were that many CSF specimens taken for spectrophotometry in cases of suspected SAH showed the presence of oxyhaemoglobin totally out of keeping with cell counts or time lapse before centrifugation.

A survey of spectrophotometry findings against outcome in computed tomography negative suspected SAH from four participat-

ing centres (R Beetham *et al*, unpublished data, 2001) undertaken by our group has indicated that out of scans on 740 patients, 204 showed detectable oxyhaemoglobin without increased bilirubin. Thirty of these 204 patients proceeded to angiography and only two aneurysms were found. It has to be concluded that angiography in all 204 patients on the basis of the finding of oxyhaemoglobin alone would have been unwarranted when the required resource and known complication rate are considered. It is on this evidence, more in keeping with the *in vitro* data of Fahie-Wilson and Park than that of Cruickshank, that we make our recommendation that oxyhaemoglobin is discounted as evidence to support SAH.

On a second matter, we differ on the assertion that the occurrence of bilirubin alone without oxyhaemoglobin is a rare occurrence in computed tomography negative, angiographically confirmed aneurysms. In the above series, there were 11 patients with increased bilirubin who showed aneurysms on angiography and proceeded to surgery. Two of these were negative for oxyhaemoglobin and a third demonstrated only a trace of oxyhaemoglobin (absorbance above baseline of 0.012 AU). We agree however that an increased bilirubin without oxyhaemoglobin is found more frequently in association with an increased serum bilirubin than with SAH.

Finally, although we welcome the recommendation that non-haemorrhagic bilirubin is taken into account whenever bilirubin is detected, no mention is made of a reference range for bilirubin against which a value can be judged to be normal or abnormal. Quantitation is only of use if such a reference range is provided. We recommend the net bilirubin absorbance at 476 nm, as advocated by Chalmers,⁸ and provide a reference range based on angiographic outcome. It is also our experience that the correction for non-haemorrhagic bilirubin works well when the cause of the increased CSF bilirubin is an increased serum bilirubin, and less well when the serum bilirubin is normal and the cause of the increased CSF bilirubin is an increase in CSF protein.

Our proposed guidelines are available through UKNEQAS for Immunochemistry.² They can be accessed through www.immqas.org.uk and we recommend them to your readers.

R Beetham, M N Fahie-Wilson, I Holbrook, P Thomas, A M Ward, I D Watson, P R Wenham, P A E White

Advisory group to UK NEQAS for CSF Proteins and Biochemistry, UK NEQAS, Department of Immunology, Sheffield S5 7YT, UK; robert.beetham@north-bristol.swest.nhs.uk

References

- 1 Cruickshank AM. CSF spectrophotometry in the diagnosis of subarachnoid haemorrhage. *J Clin Pathol* 2001;**54**:827–30.
- 2 Allen K, Beetham R, Fahie-Wilson MN, *et al*. Proposed national guidelines for analysis of cerebrospinal fluid for bilirubin in suspected subarachnoid haemorrhage. Sheffield: UK NEQAS for Immunology and Immunochemistry, 2001.
- 3 Smith LA, Cruickshank AM. Subarachnoid haemorrhage or traumatic tap? In: Martin SM, ed. *Proceedings of the ACB national meeting, 17–21 May 1999, Manchester*. London: Association of Clinical Biochemists, 2000:107.
- 4 Wenham PR, Hanson T, Ashby JP. Interference in spectrophotometric analysis of cerebrospinal fluid by haemolysis induced by transport through a pneumatic tube system. *Ann Clin Biochem* 2001;**38**:371–5.

- 5 **Hellström B**, Kjellin KG. The diagnostic value of spectrophotometry of the CSF in the newborn period. *Dev Med Child Neurol* 1971;13:789-97.
- 6 **Fahie-Wilson MN**, Park DM. Spectrophotometric examination of CSF in suspected subarachnoid haemorrhage—what should we look for? In: Martin SM, Halloran SP, eds. *Proceedings of the XVI International Congress of Clinical Chemistry, 8-12 July 1996, London*. London: Association of Clinical Biochemists, 1996:85.
- 7 **Barrows LJ**, Hunter FT, Banker BQ. The nature and clinical significance of pigments in the cerebrospinal fluid. *Brain* 1955;78:59-80.
- 8 **Chalmers AH**. Cerebrospinal fluid xanthochromia testing simplified. *Clin Chem* 2001;47:147-8.

Author's reply

The development of proposed national guidelines on this topic is welcome.

My principal concern regarding the guidelines proposed by the authors is their recommendation that oxyhaemoglobin is discounted as evidence to support subarachnoid haemorrhage. The authors themselves report that of the 30 patients who had haemoglobin alone detected in their cerebrospinal fluid and who proceeded to angiography, two were found to have aneurysms. In the small number of samples we receive that have few red blood cells, which are centrifuged quickly, and which show oxyhaemoglobin alone, I remain reluctant to issue a negative result.

A Cruickshank

Department of Biochemistry, Southern General Hospital, 1345 Govan Road, Glasgow G51 4TF, UK

BOOK REVIEWS



Dermatopathology in Systemic Disease

Smoller BR, Horn TD. (£110.00.) Oxford University Press, 2001. ISBN 0 19 513038 3

First, and lasting impression: what a beautiful book this is! Drs Smoller and Horn are to be congratulated on a piece of very fine work indeed. *Dermatopathology in Systemic Disease* provides a detailed, well illustrated, clearly described, and well referenced review of a difficult and often highly complex field of diagnostic dermatopathology. The wealth of data is made accessible by well subdivided texts, attractive tables, and generally excellent micrographs. The use of a similar structure of the texts for individual items enhances the accessibility of the data. The detailed index further ensures quick reference of the relevant descriptions and illustrations.

The illustrations, in colour throughout, and almost all of the same size as the text column width, are perhaps a bit smaller than would be ideal; this is however something of a general trend in modern pathology textbooks (small colour pictures), a trend that I feel is not to be applauded at all!

The emphasis of the book, and its strength, is directed towards diagnostic histopathology; texts on pathogenesis are often very brief and (for example, lupus erythematosus; various connective tissue diseases) not always do justice to the large volume of data that have become available on these subjects. But in view of the emphasis on diagnostic rather than pathobiological aspects (to such an extent that a title of *Diagnostic Dermatopathology in Systemic Diseases* might have been appropriate) this need not concern us. In sum, the book is a welcome and very well produced addition to available textbooks on dermatopathology.

W J Mooi

Radiation Pathology

Farjado LF, Berthrong M, Anderson RE. (£120.00.) Oxford University Press, 2001. ISBN 0 19 511023 4

This is an interesting and well presented book, aiming to provide a comprehensive coverage of the varied and ever expanding field of radiation pathology. The three authors are each recognised authorities in their respective fields, and their joint efforts are complemented by an interesting chapter on therapeutic applications by Dr JL Meyer.

The book is, of course, heterogeneous, ranging from diagnostic histopathology to basic aspects of radiation pathobiology and from radiation induced cancerogenesis to the tissue damaging effects of radiation. Nonetheless, the authors have succeeded in providing a reasonably homogeneous whole, where chapters complement each other. A useful glossary precedes the first chapters and illustrations are generally of excellent quality.

There were perhaps a few subjects that might have benefitted from a more in depth discussion. The short term and long term effects on the atomic bomb survivors is discussed with great clarity and authority, but the work on thyroid disease following the Chernobyl disaster, which has yielded a wealth of new data, would have fitted well into one of the chapters on radiation carcinogenesis and on the thyroid gland. Angiosarcoma, which is now a well recognised late sequel to breast conserving treatment, is only mentioned in passing. Diagnostic aspects of recurrent tumour versus radiation induced cellular atypia could have received a rather more extensive discussion and more illustrations, especially in organs where these problems are regularly encountered: breast, prostate, and urinary bladder. Aspects of fine needle aspiration cytology, a technique that commonly serves as the first line invasive diagnostic technique when recurrent tumour in an irradiated tissue is suspected, receives surprisingly little mention; in this respect, the book cannot be used as a bench book in the diagnosis of difficult cases.

Despite these few criticisms, I feel that there is much to recommend this book as a work of substantial interest, providing a good coverage of a wide and heterogeneous field of biological and clinicopathological work.

W J Mooi

Pathology of Skeletal Muscle, 2nd ed

Carpenter S, Karpati G. (£140.00.) Oxford University Press, 2001. ISBN 0 19 506364 3

The first edition of Carpenter and Karpati's *Pathology of Skeletal Muscle* has been one of the standard bench books of muscle pathology for practising neuropathologists. The second

edition is substantially extended and updated on a wide range of topics.

The book falls into two sections: the first half is devoted to structure and reactions of muscle and contains an introductory chapter and chapters on removal and preparation of biopsy samples, skeletal muscle biology, the major pathological changes encountered, and detailed descriptions of subcellular components. The second section is devoted to diseases of skeletal muscle and broadly breaks down into chapters covering genetic disease (including dystrophies), lysosomal and non-lysosomal storage disease, inflammatory myopathies, and sporadic myopathies, with several shorter sections covering a large range of the rarer or less well understood conditions. As examples of the topicality, there is an informative discussion of recent advances in the understanding of limb girdle dystrophies with references covering the sarcoglycanopathies, and deficiencies of dysferlin, calveolin, and calpain. Another example is a survey of human immunodeficiency virus and human T cell leukaemia virus 1 (HTLV-1) related myopathies, including the iatrogenic Zidovudine-related myopathy. Each section carries a comprehensive list of references, which covers the literature up to 1998-9.

The book is well produced on high quality paper with a clear, easily read typeface, and the illustrations, both black and white and colour, are of superb quality and cannot be faulted. Judiciously included line diagrams, both black and white and colour, are clear and easily understood. The price is reasonable. There are occasional infelicities as—for example, on page 54 in the section describing muscle spindles. The three types of intrafusal fibres are described and the reader is referred to table 3.3 for a survey of their features. However, table 3.3 only covers the standard type 1 and type 2 (extrafusal) muscles fibres.

This is a major text in the field and should be recommended to all practising myopathologists as a vade mecum.

P E Rose

CALENDAR OF EVENTS

Full details of events to be included should be sent to Maggie Butler, Technical Editor JCP, The Cedars, 36 Queen Street, Castle Heddingham, Essex CO9 3HA, UK; email: maggie.butler2@btopenworld.com

UK NEQAS for Blood Coagulation Annual Meeting

18, 19 June 2002, Conference Centre, Sheffield Hallam University, Sheffield, UK
Further details: TAL Woods, UK NEQAS for Blood Coagulation, Rutledge Mews, 3 Southbourne Road, Sheffield S10 2QN, UK. (Tel +44 114 267 3300; Fax +44 114 267 3309; email neqas@coageqa.demon.co.uk)

Short Course on the Autopsy

25-28 June 2002, Department of Pathology, University of Sheffield, Sheffield, UK
Further details: Mrs S Clary, Department of Pathology, University of Sheffield Medical School, Beech Hill Road, Sheffield S10 2RX, UK. (Tel; +44 0114 271 2501; Fax +44 0114 278 0059; email s.clary@shef.ac.uk)

Diagnostic Histopathology

8-19 July 2002, Department of Pathology, University of Sheffield, Sheffield, UK
Further details: Mrs S Clary, Department of Pathology, University of Sheffield Medical School, Beech Hill Road, Sheffield S10 2RX, UK. (Tel; +44 0114 271 2501; Fax +44 0114 278 0059; email s.clary@shef.ac.uk)



Recurrent cellular angiofibroma of the vulva

W G McCluggage, M Perenyi and S T Irwin

J Clin Pathol 2002 55: 477-479

doi:

Updated information and services can be found at:

<http://jcp.bmj.com/content/55/6/477.3.full.html>

These include:

References

This article cites 7 articles, 1 of which can be accessed free at:

<http://jcp.bmj.com/content/55/6/477.3.full.html#ref-list-1>

Article cited in:

<http://jcp.bmj.com/content/55/6/477.3.full.html#related-urls>

Email alerting service

Receive free email alerts when new articles cite this article. Sign up in the box at the top right corner of the online article.

Topic Collections

Articles on similar topics can be found in the following collections

[Clinical diagnostic tests](#) (637 articles)

[Morbid anatomy / surgical pathology](#) (71 articles)

[Immunology \(including allergy\)](#) (1279 articles)

Notes

To request permissions go to:

<http://group.bmj.com/group/rights-licensing/permissions>

To order reprints go to:

<http://journals.bmj.com/cgi/reprintform>

To subscribe to BMJ go to:

<http://group.bmj.com/subscribe/>