

ORIGINAL PAPER

Thromboxane synthase immunohistochemistry in inflammatory bowel disease

E Carty, C Nickols, R M Feakins, D S Rampton

J Clin Pathol 2002;55:367-370

See end of article for authors' affiliations

Correspondence to:
Dr D S Rampton,
Department of
Gastroenterology, The
Royal London Hospital,
Whitechapel Road, London
E1 1BB, UK;
d.rampton@qmul.ac.ukAccepted for publication
6 July 2001**Background:** Thromboxanes are produced in excess in inflammatory bowel disease. Preliminary reports suggest that ridogrel, a thromboxane synthase inhibitor, is anti-inflammatory and may have therapeutic benefits in patients with ulcerative colitis.**Aims:** To investigate the immunohistochemical expression of thromboxane synthase in the colorectal mucosa of patients with inflammatory bowel disease.**Methods:** Immunostaining of colonic biopsies from patients with inflammatory bowel disease (n = 13) and controls (n = 5) was performed using a monoclonal antibody to human thromboxane synthase. The extent of staining in cells of the lamina propria was compared in patient and control groups, and was assessed in relation to disease activity scored macroscopically and histologically.**Results:** The percentage of cells in the lamina propria staining for thromboxane synthase was higher in patients with active inflammatory bowel disease than in those with inactive disease or in controls (p = 0.02 and p = 0.002, respectively). There was a direct correlation between disease activity, measured endoscopically and histologically, and the percentage of lamina propria cells staining for thromboxane synthase (R = 0.71, p = 0.001 and R = 0.72, p = 0.001, respectively).**Conclusions:** Increased thromboxane synthase expression in lamina propria cells occurs in active inflammatory bowel disease. It is possible that this results in increased thromboxane synthesis, which may in turn contribute to mucosal inflammation and intramucosal thrombogenesis.

Thromboxane A₂ is a proinflammatory eicosanoid derived from arachidonic acid. Cyclooxygenase catalyses the formation of prostaglandin G₂ (PGG₂) and H₂ (PGH₂) from arachidonic acid. Thromboxane synthase (TXS) then catalyses the isomerisation of PGH₂ to thromboxane A₂. Thromboxane A₂ has a very short half life and is rapidly metabolised to stable thromboxane B₂.¹

Thromboxane production is increased in inflammatory bowel disease (IBD) and may play a role in its pathogenesis.² In animal models of IBD, mucosal production of thromboxane is increased, both in the spontaneous model of colitis in cotton top tamarin monkeys,³ and in those models of colitis induced by exogenous agents, including acetic acid⁴ and trinitrobenzene sulfonic acid⁵ in rats, and carrageenan in guinea pigs.⁶

In human IBD, thromboxane production by cultured isolated intestinal epithelial cells from patients with ulcerative colitis (UC) and those with Crohn's disease (CD) is increased; the same is true of cultured isolated intestinal mononuclear cells from patients with CD, but not of those from patients with UC.⁷ Colonic tissue homogenates from patients with UC⁸ and the culture of biopsies from both patients with UC and those with CD also demonstrate excess thromboxane production in active disease.⁹⁻¹⁰ Moreover, rectal dialysis in patients with UC and CD shows increased rectal mucosal production of thromboxane in active disease *in vivo*.¹¹

"In animal models of inflammatory bowel disease mucosal production of thromboxane is increased"

TXS inhibitors have been shown to be anti-inflammatory¹²⁻¹³ and in small preliminary trials of patients with UC have shown some therapeutic benefits.¹⁴⁻¹⁶

There appear to be no published data on the immunohistochemical expression of TXS in intestinal mucosal biopsies. Therefore, the aim of our study was to investigate whether the immunohistochemical expression of TXS is increased in the colorectal mucosa of patients with active IBD.

MATERIALS AND METHODS

Patients

Paired colorectal mucosal biopsies from 13 patients with IBD (nine with UC, four with CD) were collected at routine colonoscopy. IBD had been confirmed previously by conventional histological, endoscopic, and radiological criteria.

Five patients undergoing colonoscopy, and found to have endoscopically and histologically normal mucosa, served as controls; their diagnoses were haemorrhoids (one), irritable bowel syndrome (two), and previous colorectal carcinoma (two).

For normal controls and patients with IBD and involvement of the sigmoid colon, biopsies were taken from the sigmoid. For patients with CD without disease in the sigmoid, biopsies were taken from the involved area. Table 1 gives details of age, sex, disease type and distribution, and drug treatment.

All patients gave written informed consent and the studies were approved by the East London and City Health Authority research ethics committee.

Assessment of disease activity

Disease activity in UC was assessed endoscopically using a standard score.¹⁷ This score was adapted and used to assess endoscopic disease activity in patients with CD because of the lack of availability of a standard score. Active disease was defined as scores 2 and 3 (contact or spontaneous mucosal bleeding), and inactive disease as 0 and 1 (normal or oedematous mucosa).

Disease activity was also assessed histologically in haematoxylin and eosin (H&E) stained sections of biopsies from

Abbreviations: CD, Crohn's disease; H&E, haematoxylin and eosin; IBD, inflammatory bowel disease; IQR, interquartile range; LP, lamina propria; PG, prostaglandin; TXS, thromboxane synthase; UC, ulcerative colitis

Table 1 Patient characteristics

	UC	CD	Controls
Number	9	4	5
Median age (IQR) in years	48 (29–65)	48 (28–62)	67 (56–70)
Sex ratio (M:F)	5:4	0:4	3:2
Active disease	6	2	–
UC extent			
Extensive colitis	4	–	–
Left sided colitis	1	–	–
Distal colitis	4	–	–
CD extent			
Colonic	–	1	–
Ileocolonic	–	3	–
Oral treatment			
5ASA	6	3	–
Steroids	1	0	–
Azathioprine/6-mercaptopurine	0	1	–

CD, Crohn's disease; IBD, inflammatory bowel disease; IQR, interquartile range; UC, ulcerative colitis.

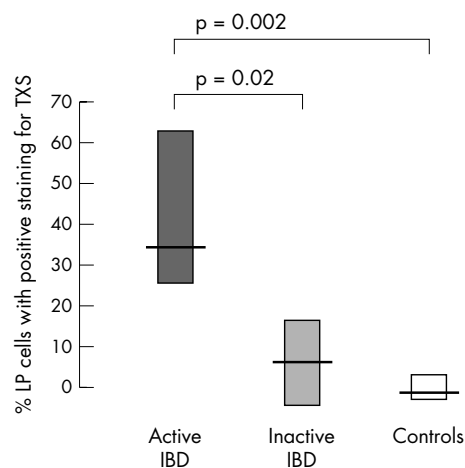


Figure 1 Percentage of lamina propria (LP) cells staining positive for thromboxane synthase (TXS) in patients with active inflammatory bowel disease (IBD; defined by endoscopic score¹⁷), inactive IBD, and controls. Median and interquartile range are shown.

patients with both UC and CD using a semiquantitative score, as previously described.¹⁸

Tissue processing

Biopsies collected at colonoscopy were immediately snap frozen in liquid nitrogen and then stored at -70°C until processed for immunostaining. Paired biopsies were placed in formalin for routine Gill's H&E staining.

Immunohistochemistry for TXS

Frozen sections of the biopsies were cut at $6\ \mu\text{m}$, picked up on silane treated microscope slides, allowed to air dry, and fixed in acetone for two minutes. A monoclonal antibody against human thromboxane synthase (Tü 300),¹⁹ as previously used in studies of placental tissue,²⁰ was applied at a dilution of 1/100 (in antibody diluent) and incubated with the tissue overnight at 4°C . Preliminary optimisation studies using an incubation time of one hour, although showing positive staining in the placenta, were unsuccessful with the colonic tissue. Bound antibody was detected by a standard biotin–streptavidin–peroxidase system using a Vector Elite kit (Vector Labs, Peterborough, UK).

In each immunohistochemistry run, placental bed tissue served as a positive control²⁰ and omission of the primary antibody served as a negative control. Appropriate non-specific staining blocks, including incubation with normal serum (twice for the double staining method), endogenous

peroxidase block, intestinal alkaline phosphatase block, and avidin/biotin block were also used as controls. For the double staining method, additional blocks were incorporated in the form of levamisole, an inhibitor of alkaline phosphatase added to the substrate solution to eliminate background.

Test and control slides were stained in one run, both for single and double staining. The amount of TXS signal in the double staining method was comparable to that of TXS alone. Controls were always included. All the staining was performed by one person (CN).

Analysis of staining

All tissue was assessed on each slide. The proportion of lamina propria cells showing positive staining, regardless of the intensity, was determined by an experienced gastrointestinal histopathologist (RMF), who was blinded to the diagnosis and disease activity.

Double immunostaining for CD68 and TXS

Double staining using the antibody to TXS as above, together with a monoclonal antibody to the human macrophage antigen CD68, KP-1 clone (Dako Ltd, Ely, Cambridgeshire, UK), was performed. Tissue sections were first incubated overnight with anti-TXS, as described previously, washed thoroughly in distilled water, then incubated for one hour with anti-CD68, diluted 1/1000 (in antibody diluent). CD68 was detected using an alkaline phosphatase detection system, Vector ABC-AP (Vector Labs). Placental bed tissue served as a positive control for the demonstration of TXS and normal appendix served as control for CD68. Omission of the primary stage served as a negative control for each antibody.

Statistical analysis

Statistical comparisons between groups were made using the Mann-Whitney U test (two tailed). Correlations were assessed by Spearman's rank correlation (two tailed).

RESULTS

Immunostaining of TXS in patients with IBD and controls

Immunohistochemical expression of TXS in lamina propria cells was cytoplasmic and often granular. No pattern of distribution within the lamina propria was discernable. The proportion of cells positive for TXS ranged from 1% to 9.5% in controls and 15% to 90% in active IBD.

The proportion of lamina propria cells staining for TXS was higher in patients with active IBD than in those with inactive IBD or controls ($p = 0.02$ and $p = 0.002$, respectively; figs 1 and 2).

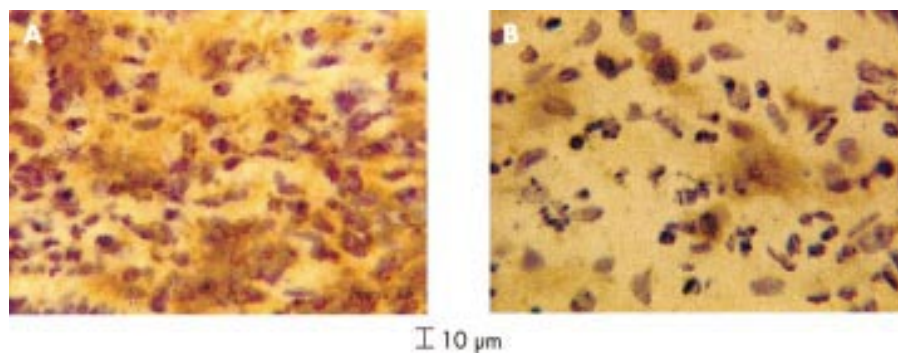


Figure 2 (A) Heavy and (B) light staining for thromboxane synthase (TXS) in lamina propria cells in (A) active and (B) inactive inflammatory bowel disease. Brown staining indicates TXS.

Correlation of immunostaining and disease activity

There was a direct correlation between the proportion of lamina propria cells staining for TXS and disease activity, as determined both by endoscopic score ($p = 0.001$) and by histological score on H&E stained biopsies ($p = 0.001$; fig 3).

Double immunostaining

Double immunostaining for TXS and CD68 showed that a proportion of the cells expressing TXS were macrophages (fig 4).

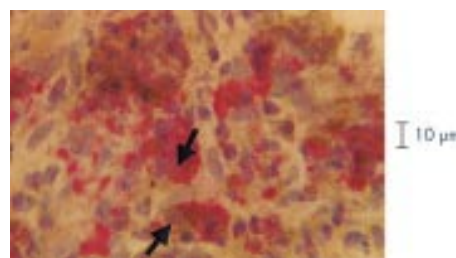


Figure 4 Double staining, with some cells positive for both thromboxane synthase (TXS) and CD68 (arrow), suggesting that some of the cells expressing TXS were macrophages. Brown staining indicates TXS and red staining indicates CD68.

DISCUSSION

We have demonstrated, for the first time, excess immunostaining for TXS in the cells of the lamina propria, including macrophages, of colorectal mucosal biopsies from patients with IBD. This upregulation of TXS expression, which correlated with disease activity, measured by endoscopic score and histology, may account for the recognised increased production of thromboxanes by inflamed intestinal mucosa⁷⁻¹¹ and in the blood of patients with IBD.²¹

In vitro studies have shown that thromboxanes have proinflammatory actions. Thromboxane induces the activation of neutrophils,²² the production of leukotriene B₄,²³ and enhanced endothelial adhesion²⁴ and subsequent diapedesis²⁵ of neutrophils. Thromboxanes also induce apoptosis²⁶ and modulate T cell function,²⁷ and may have a role in ischaemia reperfusion injury.²⁸

“Preliminary studies of thromboxane synthase inhibitors have shown some benefits in patients with ulcerative colitis”

Vasoconstriction²⁹ and platelet aggregation¹ are also induced by thromboxanes. In patients with active IBD, platelets are activated³⁰ and show abnormal aggregation.²¹ Furthermore,

platelet aggregates have been identified in the capillaries in inflamed rectal biopsies in IBD,³¹ and microvascular thrombosis has been proposed as an early pathogenic factor in CD.³² It has therefore been proposed that thromboxanes may play a role in the pathogenesis of IBD.²

Preliminary studies of thromboxane synthase inhibitors have shown some benefits in patients with UC¹⁴⁻¹⁶; however, the results of large randomised controlled trials are awaited.

TXS has been purified and is a cytochrome P450 enzyme.³³ It has been identified in kidney,³⁴ spleen,³⁵ brain,³⁶ and placenta,²⁰ in addition to platelets,³⁷ macrophages,³⁸ lung fibroblasts,³⁹ and other cell types. To our knowledge, this is the first study to investigate TXS immunostaining in intestinal mucosa.

The double staining technique confirmed that many cells in the lamina propria staining positively for TXS were also positive for the macrophage marker CD68. This is in accordance with studies in the placenta, where macrophages were identified as a source of TXS,^{20 40} and indicates that at least some of the excess TXS in inflamed IBD mucosa is located in

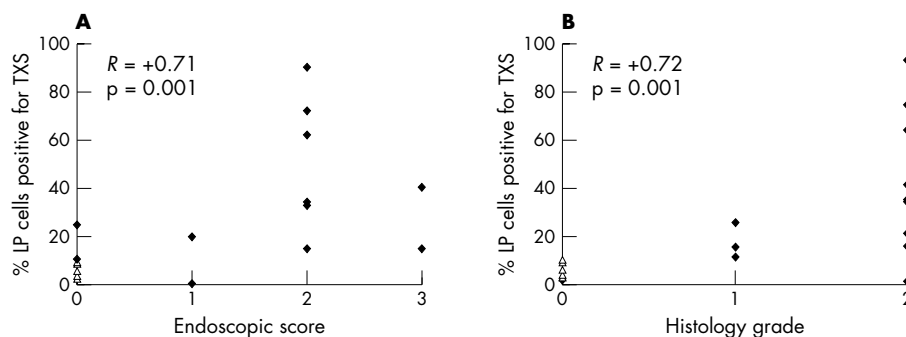


Figure 3 Correlation between the percentage of lamina propria (LP) cells staining positive for thromboxane synthase (TXS) and disease activity, as assessed by (A) endoscopic score¹⁷ and (B) histological score¹⁸ in patients with inflammatory bowel disease (closed diamonds) and controls (open triangles).

Take home messages

- There was a direct correlation between disease activity, measured endoscopically and histologically, and the percentage of lamina propria cells staining for thromboxane synthase in patients with inflammatory bowel disease
- This increased expression of thromboxane synthase might result in increased thromboxane synthesis, which may in turn contribute to mucosal inflammation and intramucosal thrombogenesis

macrophages. However, it is possible that other types of lamina propria cells, including lymphocytes and endothelial cells, were also expressing TXS in the cases studied here.

Our study has shown that increased TXS expression in lamina propria cells occurs in active IBD. As a result, increased thromboxane synthesis may occur and contribute to mucosal inflammation and intramucosal thrombogenesis.

ACKNOWLEDGEMENT

We are grateful to Dr R Nusing, Phillips University of Marburg, Germany, for kindly supplying us with the monoclonal antibody to thromboxane synthase (Tu 300) used in these studies.

Authors' affiliations

E Carty, D S Rampton, Department of Adult and Paediatric Gastroenterology, St Bartholomew's and The Royal London School of Medicine and Dentistry, Queen Mary College, London UK
C Nickols, R M Feakins, Department of Histopathology, St Bartholomew's and The Royal London School of Medicine and Dentistry

REFERENCES

- 1 **Hamberg M**, Svensson J, Samuelsson B. Thromboxanes: a new group of biologically active compounds derived from prostaglandin endoperoxides. *Proc Natl Acad Sci U S A* 1975;**72**:2994–8.
- 2 **Rampton DS**, Collins CE. Review article: thromboxanes in inflammatory bowel disease—pathogenic and therapeutic implications. *Aliment Pharmacol Ther* 1993;**7**:357–67.
- 3 **Clapp N**, Henke M, Hansard R, et al. Inflammatory mediator changes in cotton-top tamarins (CTT) after SC-41930 anti-colitic therapy. *Angens Actions* 1993;**39**Spec No:C8–10.
- 4 **Sharon P**, Stenson WF. Metabolism of arachidonic acid in acetic acid colitis in rats. Similarity to human inflammatory bowel disease. *Gastroenterology* 1985;**88**:55–63.
- 5 **Vilaseca J**, Salas A, Guarner F, et al. Participation of thromboxane and other eicosanoid synthesis in the course of experimental inflammatory colitis. *Gastroenterology* 1990;**98**:269–77.
- 6 **Kitsukawa Y**, Saito H, Suzuki Y, et al. Effect of ingestion of eicosapentaenoic acid ethyl ester on carrageenan-induced colitis in guinea pigs. *Gastroenterology* 1992;**102**:1859–66.
- 7 **Zifroni A**, Treves AJ, Sachar DB, et al. Prostanoid synthesis by cultured intestinal epithelial and mononuclear cells in inflammatory bowel disease. *Gut* 1983;**24**:659–64.
- 8 **Boughton-Smith NK**, Hawkey CJ, Whittle BJ. Biosynthesis of lipoxygenase and cyclo-oxygenase products from [¹⁴C]-arachidonic acid by human colonic mucosa. *Gut* 1983;**24**:1176–82.
- 9 **Hawkey CJ**, Rampton DS. Prostaglandins and the gastrointestinal mucosa: are they important in its function, disease, or treatment? *Gastroenterology* 1985;**89**:1162–88.
- 10 **Hawkey CJ**, Karmeli F, Rachmilewitz D. Imbalance of prostacyclin and thromboxane synthesis in Crohn's disease. *Gut* 1983;**24**:881–5.
- 11 **Lauritsen K**, Laursen LS, Bukhave K, et al. In vivo profiles of eicosanoids in ulcerative colitis, Crohn's colitis, and Clostridium difficile colitis. *Gastroenterology* 1988;**95**:11–17.
- 12 **Collins CE**, Benson MJ, Burnham WR, et al. Picotamide inhibition of excess in vitro thromboxane B2 release by colorectal mucosa in inflammatory bowel disease. *Aliment Pharmacol Ther* 1996;**10**:315–20.
- 13 **Carty E**, Macey M, McCartney SA, et al. Ridogrel, a dual thromboxane synthase inhibitor and receptor antagonist: anti-inflammatory profile in inflammatory bowel disease. *Aliment Pharmacol Ther* 2000;**14**:807–17.
- 14 **Casellas F**, Papo M, Guarner F, et al. Effects of thromboxane synthase inhibition on in vivo release of inflammatory mediators in chronic ulcerative colitis. *Eur J Gastroenterol Hepatol* 1995;**7**:221–6.
- 15 **Skandalis N**, Rotenberg A, Meuwissen S, et al. Ridogrel for the treatment of mild to moderate ulcerative colitis [abstract]. *Gastroenterology* 1996;**110**:A1016.
- 16 **Wright J**, Schenowitz G, Adler G, et al. Ridogrel for the treatment of mild to moderate ulcerative colitis. A placebo controlled trial [abstract]. *Gut* 1996;**39**:A188.
- 17 **Baron J**, Connell A, Lennard-Jones A. Variation between observers in describing mucosal changes in proctocolitis. *BMJ* 1964;**1**:89–92.
- 18 **Saverymuttu SH**, Camilleri M, Rees H, et al. Indium 111-granulocyte scanning in the assessment of disease extent and disease activity in inflammatory bowel disease. A comparison with colonoscopy, histology, and fecal indium 111-granulocyte excretion. *Gastroenterology* 1986;**90**:1121–8.
- 19 **Nusing R**, Wernet MP, Ullrich V. Production and characterization of polyclonal and monoclonal antibodies against human thromboxane synthase. *Blood* 1990;**76**:80–5.
- 20 **Wetzka B**, Schafer W, Kommoss F, et al. Immunohistochemical localisation of thromboxane synthase in human intrauterine tissue. *Placenta* 1994;**15**:389–98.
- 21 **Webberley MJ**, Hart MT, Melikun V. Thromboembolism in inflammatory bowel disease: role of platelets. *Gut* 1993;**34**:247–51.
- 22 **Kitchen EA**, Boot JR, Dawson W. Chemotactic activity of thromboxane B2, prostaglandins and their metabolites for polymorphonuclear leucocytes. *Prostaglandins* 1978;**16**:239–44.
- 23 **Goldman G**, Welbourn R, Valeri CR, et al. Thromboxane A2 induces leukotriene B4 synthesis that in turn mediates neutrophil diapedesis via CD 18 activation. *Microvasc Res* 1991;**41**:367–75.
- 24 **Wiles ME**, Welbourn R, Goldman G, et al. Thromboxane-induced neutrophil adhesion to pulmonary microvascular and aortic endothelium is regulated by CD18. *Inflammation* 1991;**15**:181–99.
- 25 **Doukas J**, Hechtman HB, Shepro D. Endothelial-secreted arachidonic acid metabolites modulate polymorphonuclear leukocyte chemotaxis and diapedesis in vitro. *Blood* 1988;**71**:771–9.
- 26 **Ushikubi F**, Aiba Y, Nakamura K, et al. Thromboxane A2 receptor is highly expressed in mouse immature thymocytes and mediates DNA fragmentation and apoptosis. *J Exp Med* 1993;**178**:1825–30.
- 27 **Kelly JP**, Johnson MC, Parker CW. Effect of inhibitors of arachidonic acid metabolism on mitogenesis in human lymphocytes: possible role of thromboxanes and products of the lipoxygenase pathway. *J Immunol* 1979;**122**:1563–71.
- 28 **Whittle BJ**, Kauffman GL, Moncada S. Vasoconstriction with thromboxane A2 induces ulceration of the gastric mucosa. *Nature* 1981;**292**:472–4.
- 29 **Zipser RD**, Patterson JB, Kao HW, et al. Hypersensitive prostaglandin and thromboxane response to hormones in rabbit colitis. *Am J Physiol* 1985;**249**:G457–63.
- 30 **Collins CE**, Cahill MR, Newland AC, et al. Platelets circulate in an activated state in inflammatory bowel disease. *Gastroenterology* 1994;**106**:840–5.
- 31 **Dhillon AP**, Anthony A, Sim R, et al. Mucosal capillary thrombi in rectal biopsies. *Histopathology* 1992;**21**:127–33.
- 32 **Wakefield AJ**, Sawyerr AM, Dhillon AP, et al. Pathogenesis of Crohn's disease: multifocal gastrointestinal infarction. *Lancet* 1989;**2**:1057–62.
- 33 **Haurand M**, Ullrich V. Isolation and characterization of thromboxane synthase from human platelets as a cytochrome P-450 enzyme. *J Biol Chem* 1985;**260**:15059–67.
- 34 **Zenser TV**, Herman CA, Gorman RR, et al. Metabolism and action of the prostaglandin endoperoxide PGH2 in rat kidney. *Biochem Biophys Res Commun* 1977;**79**:357–63.
- 35 **Nijkamp FP**, Moncada S, White HL, et al. Diversion of prostaglandin endoperoxide metabolism by selective inhibition of thromboxane A2 biosynthesis in lung, spleen or platelets. *Eur J Pharmacol* 1977;**44**:179–86.
- 36 **Wolfe LS**, Rostworowski K, Marion J. Endogenous formation of the prostaglandin endoperoxide metabolite, thromboxane B2, by brain tissue. *Biochem Biophys Res Commun* 1976;**70**:907–13.
- 37 **Needleman P**, Moncada S, Bunting S, et al. Identification of an enzyme in platelet microsomes which generates thromboxane A2 from prostaglandin endoperoxides. *Nature* 1976;**261**:558–60.
- 38 **Murota SI**, Kawamura M, Morita I. Transformation of arachidonic acid into thromboxane B2 by the homogenates of activated macrophages. *Biochim Biophys Acta* 1978;**528**:507–11.
- 39 **Hopkins NK**, Sun FF, Gorman RR. Thromboxane A2 biosynthesis in human lung fibroblasts WI-38. *Biochem Biophys Res Commun* 1978;**85**:827–36.
- 40 **Nusing R**, Sauter G, Fehr P, et al. Localization of thromboxane synthase in human tissues by monoclonal antibody Tu 300. *Virchows Arch A Pathol Anat Histopathol* 1992;**421**:249–54.



Thromboxane synthase immunohistochemistry in inflammatory bowel disease

E Carty, C Nickols, R M Feakins, et al.

J Clin Pathol 2002 55: 367-370

doi:

Updated information and services can be found at:

<http://jcp.bmj.com/content/55/5/367.full.html>

These include:

References

This article cites 37 articles, 10 of which can be accessed free at:

<http://jcp.bmj.com/content/55/5/367.full.html#ref-list-1>

Email alerting service

Receive free email alerts when new articles cite this article. Sign up in the box at the top right corner of the online article.

Topic Collections

Articles on similar topics can be found in the following collections

[Inflammatory bowel disease](#) (37 articles)
[Clinical diagnostic tests](#) (637 articles)
[Immunology \(including allergy\)](#) (1279 articles)
[Inflammation](#) (129 articles)

Notes

To request permissions go to:

<http://group.bmj.com/group/rights-licensing/permissions>

To order reprints go to:

<http://journals.bmj.com/cgi/reprintform>

To subscribe to BMJ go to:

<http://group.bmj.com/subscribe/>