

ORIGINAL ARTICLE

Multiparameter flow cytometry as a tool for the detection of micrometastatic tumour cells in the sentinel lymph node procedure of patients with breast cancer

M P G Leers, R H M G Schoffelen, J G M Hoop, P H M H Theunissen, J W A Oosterhuis, H vd Bijl, A Rahmy, W Tan, M Nap

J Clin Pathol 2002;**55**:359–366

Aim: To investigate whether multiparameter flow cytometry (MP-FCM) can be used for the detection of micrometastasis in sentinel lymph nodes (SLNs) in breast cancer.

Methods: Formalin fixed, paraffin wax embedded sentinel lymph nodes ($n = 238$) from 98 patients were analysed. For each lymph node, sections for haematoxylin and eosin (H&E) staining and immunohistochemistry (IHC) for cytokeratin (MNF116) were cut at three levels with a distance of 500 μm . The intervening material was used for MP-FCM. Cells were immunostained with MNF116, followed by an incubation with fluorescein isothiocyanate (FITC) labelled goat antimouse immunoglobulin. DNA was stained using propidium iodide. From each lymph node 100 000 cells were analysed on the flow cytometer.

Results: Thirty eight of the 98 patients with breast carcinoma showed evidence of metastatic disease in the SLN by one or more of the three methods. In 37 of 38 cases where metastatic cells were seen in the routine H&E and/or IHC, more than 1% cytokeratin positive cells were detected by MP-FCM. In 24 patients, metastatic foci were more than 2 mm (macrometastasis) and in 14 these foci were smaller than 2 mm (micrometastasis). In three of these 14 cases, MP-FCM revealed positive SLNs, although this was not seen at first glance in the H&E or IHC sections. After revision of the slides, one of these three remained negative. However, MP-FCM analysis of the cytokeratin positive cells showed an aneuploid DNA peak, which was almost identical to that of the primary breast tumour. Duplicate measurements, done in 41 cases, showed a 99% reproducibility. In five of 14 patients with micrometastasis, one or two metastatic foci were found in the non-SLN. However, in 15 of 24 macrometastases multiple non-SLNs were found to have metastatic tumour. All micrometastases except for the remaining negative one mentioned above showed only diploid tumour cells, despite the fact that their primary tumours contained both diploid and aneuploid tumour cells. In primary tumours with more than 60% aneuploid cells, predominantly aneuploid macrometastases were found, whereas diploid primary tumours only showed diploid micrometastases or macrometastases in their SLN. Aneuploid SLN macrometastases were associated with non-SLN metastases in five of seven patients, whereas diploid cases showed additional non-SLN metastases in only seven of 16 patients.

Conclusion: In all cases, MP-FCM was sufficient to detect micrometastatic tumour cells in a large volume of lymph node tissue from SLNs. In some cases it was superior to H&E and IHC staining. Approximately 30% of SLN micrometastases are accompanied by additional non-SLN metastases. The size of the aneuploid fraction ($> 60\%$) in the primary tumour may influence the risk of having both SLN and non-SLN metastases.

See end of article for authors' affiliations

Correspondence to:
Dr M P G Leers,
Department of Pathology,
Atrium Medical Centre
Heerlen, PO Box 4446,
6401 CX Heerlen, The
Netherlands;
m.leers@gozl.nl

Accepted for publication
23 November 2001

Breast cancer is an important health care problem. It is the most frequent type of cancer in women in the Netherlands and accounts for 22% of all cancer deaths. The clinical presentation has radically changed in the past 10 years. Improvements in education and mass screening programmes have had substantial effects, one of which is a reduction in the average size of the primary tumour at first diagnosis. Despite this, the most important prognostic factor for patients with breast cancer is still the axillary lymph node status.¹ Dissection and removal of most of the axillary lymph nodes is the standard procedure for obtaining this information. Despite the usefulness of axillary lymph node dissection, it frequently results in postoperative morbidity, such as pain, infections, chronic lymphoedema, limitation of shoulder function, and seroma. This fact has led to a search for a new method that can stage the axillary lymph nodes accurately, but which is associated with minor postoperative consequences. The sentinel lymph node (SLN) procedure is such a method and is emerging as an alternative for the staging of the axillary lymph nodes. The SLN is the first lymph node in a nodal basin

to drain the primary tumour.² Pharmaceutical agents such as technetium sulfur colloid^{3–5} or vital blue dye² sequentially drain to the lymph nodes in a time dependent manner, allowing the surgeon to identify the SLN, a biopsy of which can be screened by the pathologist for possible metastases. It is hypothesised that when the SLN does not contain metastatic tumour cells, the chance of finding metastatic cancer in the lymph nodes lying behind the SLN is negligible. In other words, tumour free SLNs predict the absence of tumour metastasis in the other non-SLNs, and those patients whose SLNs are tumour free could be spared an axillary lymph node dissection. Because a false negative SLN can lead to

Abbreviations: BSA, bovine serum albumin; CIRC, cytokeratin positive interstitial reticulum cells; FITC, fluorescein isothiocyanate; H&E, haematoxylin and eosin; IHC, immunohistochemistry; MP-FCM, multiparameter flow cytometry; PI, propidium iodide; RT-PCR, reverse transcriptase polymerase chain reaction; SLN, sentinel lymph node

untreatable tumour growth in tumour bearing lymph nodes that have been left behind, a high degree of sensitivity and specificity will be required for the identification assays. Although numerous studies have demonstrated that SLN biopsies can accurately determine the axillary nodal status, the sensitivity of the procedure for the detection of occult micrometastatic tumour cells in the SLN has been variable. The methods most often used for the identification of micrometastases in lymph nodes are haematoxylin and eosin (H&E) staining of serial sections and immunohistochemistry (IHC) of the SLN to identify a pan-cytokeratin epitope. More recently, single mRNA marker reverse transcriptase polymerase chain reaction (RT-PCR) assays have been tested for the detection of micrometastatic cells in SLN. However, a problem with this technique is the relatively high number of false positive reactions that result from the presence in lymph nodes of non-epithelial cytokeratin positive elements.⁶

“Because a false negative sentinel lymph node can lead to untreatable tumour growth in tumour bearing lymph nodes that have been left behind, a high degree of sensitivity and specificity will be required for the identification assays”

The purpose of our study was to investigate whether multiparameter cytokeratin/DNA flow cytometry can be used for the reliable identification of (micro)metastatic tumour cells in the SLN. This technique will be performed on routinely processed, formalin fixed, paraffin wax embedded lymph nodes and compared with H&E serial sectioning and IHC to analyse the accuracy, precision, reproducibility, and added value of this alternative approach.

MATERIALS AND METHODS

Specimen collection

During the obligatory learning curve of the SLN technique in our hospital, 98 patients enrolled in our study. In all patients, SLN biopsy was performed before a complete axillary dissection. From those 98 patients, 238 lymph nodes were marked as SLNs. The lymph node samples were immediately fixed in 4% buffered formalin for a minimum of 24 hours, lamellated along the longitudinal axis, and then routinely processed for complete paraffin wax embedding. When the lymph node was too large for one cassette, the lamellated pieces were divided into several embedding cassettes. The paraffin wax embedded SLNs were examined at three step section levels separated by 500 μ m and stained at each level by routine H&E and cytokeratin IHC. The two intervening levels of 500 μ m were collected in a glass tube as thick paraffin wax sections of 500 μ m for dual parameter flow cytometric analysis (fig 1). The non-SLNs were also lamellated along the longitudinal axis and routinely processed for paraffin wax embedding. From these lymph nodes only one section was stained for routine H&E.

From our patients the following information about the primary tumour was available: tumour size, histological type and grade, flow cytometric data about oestrogen receptor and progesterone receptor status, DNA index, and S phase fraction of the total epithelial compartment of the tumour, in addition to that of the different subpopulations within the tumour. The primary breast tumour was obtained during surgery of those patients undergoing either elective mastectomy or lumpectomy. These tumours were diagnosed according to the World Health Organisation classification and graded according to Bloom and Richardson.⁷ Tumour stage was assigned according to the TNM classification.⁸ Table 1 gives a summary of the histological evaluation. The flow cytometric methodology for analysing the primary breast tumour has been described previously.^{9,10}

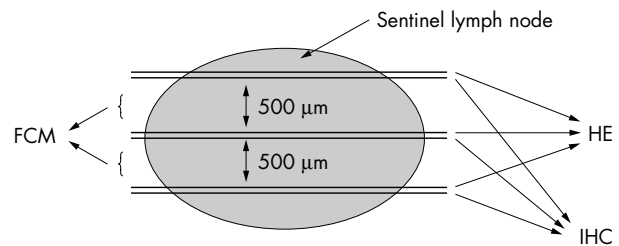


Figure 1 Schematic representation of the sentinel lymph node procedure. On three levels, a routine haematoxylin and eosin (HE) and immunohistochemical (IHC) section (3 μ m thick), for staining with anticytokeratin, are prepared. The two intervening sections (500 μ m thick) are used for multiparameter cytokeratin/DNA flow cytometric analysis (FCM).

Immunohistochemical staining procedure on paraffin wax sections

The 3 μ m thick paraffin wax sections from at least three levels were mounted on APES coated slides and air dried overnight at 37°C. For immunostaining the sections were dewaxed in xylene and rehydrated in a descending ethanol series. Endogenous peroxidase activity was blocked by immersion for 10 minutes in 3% hydrogen peroxide in methanol, after which the slides were rinsed in phosphate buffered saline (PBS; pH 7.2–7.4). The slides were placed in a pepsin solution (1 mg/ml in 0.1N HCl; Sigma, St Louis, Missouri, USA) for 10 minutes at 37°C. After preincubation with 1% bovine serum albumin (BSA; Sigma)/PBS for 10 minutes, the pan-cytokeratin monoclonal antibody (MNF116; 1/50 dilution; Dako A/S, Glostrup, Denmark) was applied for one hour at room temperature. After washing in PBS, the secondary antibody (biotin labelled goat antimouse Ig; 1/400 dilution; Dako A/S) was applied for 45 minutes at room temperature. After washing in PBS, these slides were incubated with streptavidin conjugated with horseradish peroxidase (1/600 dilution; Dako A/S) for 30 minutes at room temperature. After washing in PBS, peroxidase activity was detected with 3,3'-diaminobenzidine/0.002% H₂O₂ solution (Sigma). Finally, the sections were counterstained with Harris's haematoxylin, dehydrated, cleared in xylene, and cover-slipped with an automated coverslipper (Takahara, Japan).

Table 1 Histopathological evaluation of the primary breast tumours (n=98)

Tumour characteristics	n
Histological type	
Ductal carcinoma	85
Lobular carcinoma	9
Other	4
Grade	
G1	25
G2	54
G3	17
Unknown	2
T stage	
T1	70
T2	23
T3	1
T4	2
Tx	2
N stage	
N0	54
N1	29
N1a	9
Nx	6

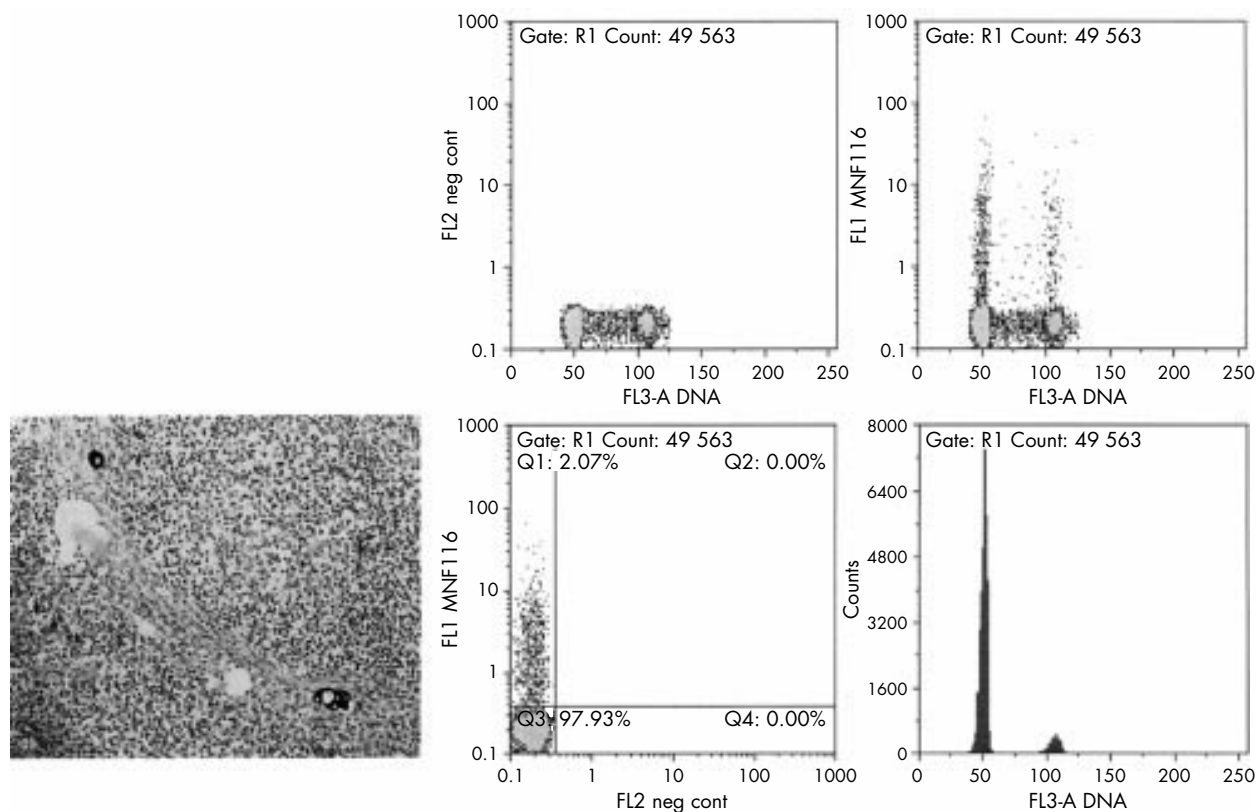


Figure 2 Example of a positive sentinel lymph node (SLN). In the immunohistochemical staining with MNF116 a few solitary tumour cells could be found in a sinus of the lymph node. Multiparameter flow cytometry analysis of this SLN revealed a diploid MNF116 positive fraction of 2.07%.

Preparation of cell suspensions

The preparation of the single cell suspension has been described previously.¹¹ Briefly, for every assay 20 sections (50 μm thick) were cut from each paraffin wax block. Subsequently, these tissue sections were dewaxed twice in xylene, for 30 minutes each, and then rehydrated in a descending ethanol series. Sections were then rinsed in PBS (pH 7.2–7.4). The sections were then placed in a glass tube with cold citrate solution (2 mg citric acid/ml distilled water; pH 6.0), and then subjected to a 120 minute heating step in an 80°C water bath. After a short cooling down period, a freshly prepared solution of 1 mg/ml pepsin (Sigma) in 0.1N HCl was added at room temperature and allowed to digest for 10 minutes at 37°C. A single cell suspension was obtained by vortexing and filtration of the sample through a 50 μm mesh nylon filter. The cell suspension was then centrifuged at 400 $\times g$ and the cell pellet was resuspended in 200 μl PBS, supplemented with 1% BSA (BSA/PBS buffer; Sigma).

Multiparameter flow cytometry

The single cell suspension was aliquoted into 100 μl samples (approximately 10^6 cells/100 μl PBS). The pan-cytokeratin monoclonal antibody (clone MNF116; diluted 1/50; Dako A/S) was added to each sample to label any epithelial metastatic cells that were present. An overnight incubation at room temperature was followed by a double PBS rinsing step. The reaction of the primary antibody was visualised by incubating the cell pellet with the secondary antibody—fluorescein isothiocyanate (FITC) labelled goat antimouse Ig (Dako A/S; 1/10 dilution) for 90 minutes at room temperature. The samples were rinsed in PBS twice and finally DNA was stained using propidium iodide (PI; 1.0 $\mu\text{g}/\text{ml}$; Sigma) in PBS containing 0.1 mg/ml RNase (Serva, Heidelberg, Germany). The samples were allowed to stand for a minimum of one hour in the dark

at 4°C before flow cytometric analysis. As a negative control for background staining by the primary antibody, a portion of the cell suspension was incubated with a non-relevant mouse Ig (Dako A/S).

To obtain some impression of the correlation of this approach between the “actual” concentration of epithelial cells and the flow cytometric determined fraction of cytokeratin positive cells, we included the following experiment. Cell suspensions were prepared from negative lymph nodes and tumour cells from a known breast carcinoma were added in an increasing cell concentration from 0.1% up to 5%. Cell count assessments were performed using a haemocytometer. These artificially created samples were treated and analysed in the same way as described above. This experiment was performed in triplicate.

Flow cytometric analysis

Samples were analysed using a Dako Galaxy flow cytometer (kindly provided for this study by Dako). Cells were excited with a single 488 nm air cooled argon ion laser. FITC fluorescence was detected through a 520 nm BP filter and PI fluorescence through a 630 nm LP filter. At least 100 000 relevant events were collected for each sample. FITC signals were recorded as logarithmic amplified data, whereas the PI signals were recorded as linear amplified data. The following settings were used: 512 V and 438 V on photomultiplier tubes for FL1 (FITC) and FL3 (PI), respectively. A software based compensation was performed afterwards using the FloMax Software (Partec GmbH, Münster, Germany). Cell cycle analysis was performed using Modfit LT 2.0 (Verity Software House Inc, Topsham, Maine, USA). The following data were collected: (1) the percentage of MNF116 positive cells and (2) the DNA index of the MNF116 positive cell populations.

Table 2 Comparison of the sensitivity and specificity of the techniques used

Technique	Sensitivity	Specificity	
H&E v IHC	89	100	Patients (n=98)
	81	100	Lymph nodes (n=238)
H&E v FCM	82	100	Patients (n=98)
	74	100	Lymph nodes (n=238)
IHC v FCM	92	100	Patients (n=98)
	89	100	Lymph nodes (n=238)

FCM, flow cytometry; H&E, haematoxylin and eosin; IHC, immunohistochemistry.

The number of positive cells was determined in the cell suspension by a threshold setting allowing not more than 1% positive counts in the negative control.

The data were analysed using the statistical software package SPSS for Windows (version 8.0; SPSS Inc Chicago, Illinois, USA).

RESULTS

Evaluation of the SLN

Of the 98 patients analysed, 31 had metastases detected in one or more of the serial H&E stained sections. On examination of all cases with immunohistochemical staining of three additional sections for pan-cytokeratin, four additional patients were found to have occult metastatic disease (a total of 35 patients). In each of these additional cases the metastasis was smaller than 2 mm. Another three patients (total 38 patients) had metastatic cells in their SLN when analysed by MP-FCM. In two of these three extra positive cases found by MP-FCM, the finding was confirmed when re-examining the immunohistochemically stained sections: in the subcapsular sinus of the lymph node a small group of tumour cells was found (fig 2). In the remaining case, re-examination of the H&E and immunohistochemically stained sections yielded no confirmation of the positive reaction. However, the cytokeratin positive population found in the SLN with the flow cytometric assay had an aneuploid DNA content with a DNA index (1.20) that was similar to that of the corresponding primary breast tumour in that patient (1.16). This finding supports the assumption that the case identified by MP-FCM only is not a false positive result. The remaining 60 patients had tumour free SLNs. The mean fraction of cytokeratin positive cells in these tumour free lymph nodes (a total of 105 examined lymph nodes) was 0.43% (range 0.07–0.83%).

Sensitivity, specificity, and reproducibility of the MP-FCM assay

When comparing the different detection techniques all assays appeared to have an equal specificity (100%; table 2). As a technique for finding occult micrometastases, H&E staining had the lowest sensitivity. MP-FCM had the highest sensitivity, even when compared with IHC. In all cases where more than 1% cytokeratin positive cells were found in the MP-FCM assay, the SLN appeared to be involved by metastatic tumour cells. In all cases where the fraction of cytokeratin positive cells in the SLN was $\leq 1\%$, the SLN was also negative using the other detection techniques (H&E and IHC). When analysing the samples in duplicate on the flow cytometer (n = 41), we found a highly significant reproducibility ($p < 0.0001$) with an almost perfect correlation coefficient ($r = 0.9942$; fig 3).

The data from the artificially created samples showed in all three cases a signal above 1%, even after the addition of 0.1% of tumour cells. Although not linear, there is an increased fraction of positive cells with the addition of more epithelial

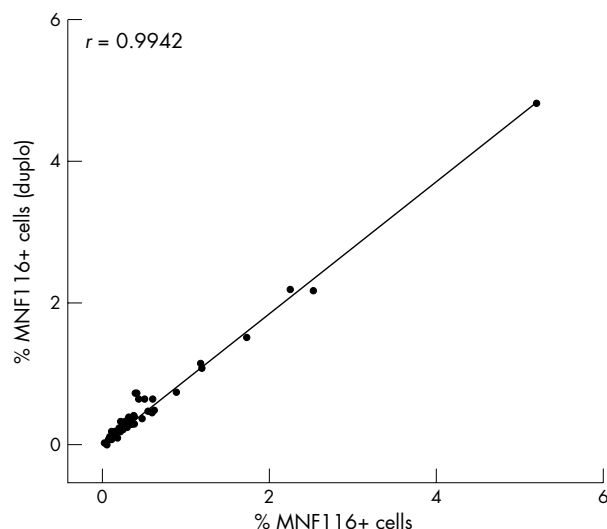


Figure 3 Reproducibility of the multiparameter flow cytometry assay (n = 41).

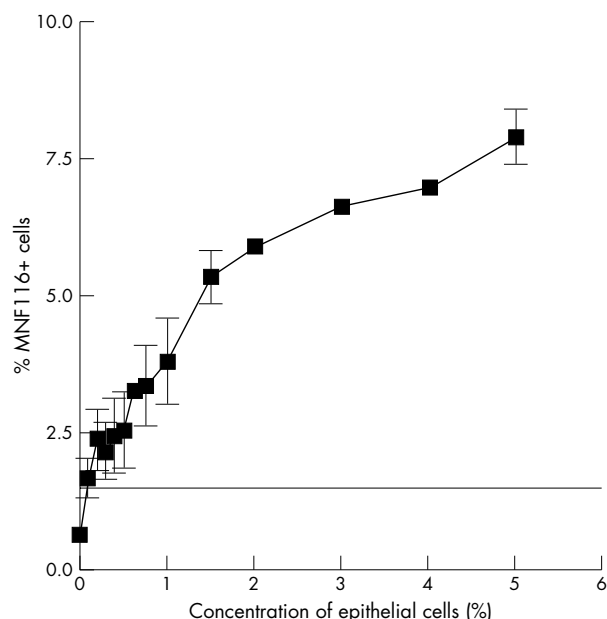


Figure 4 Correlation between the artificially created concentration of a gradient of epithelial cells in a single cell suspension of a lymph node and the flow cytometrically detected MNF116 positive fraction ($y = 1.34 \times +2.05$; $p < 0.0001$). The line and the error bars in this figure represents the average values and the SE of the mean, respectively, of three separate experiments.

cells ($y = 1.34 \times +2.05$; $p < 0.0001$). Figure 4 shows a graphical representation of this experiment.

Relation to non-SLN in axillary dissection specimen and T stage

In none of the patients with a negative SLN was a metastasis found in a non-SLN. Therefore, the predictive value of SLNs by final axillary lymph node status, the true negative rate, was 100%.

Thirteen of the 38 patients with primary tumours smaller than 2.0 cm presented with micrometastases (≤ 2.0 mm) to the SLN. Four of these patients had additional metastases in non-SLNs (table 3). As expected, the incidence of finding additional non-SLN metastases in SLN positive patients increased with increasing tumour size (table 3). In 30 of 38

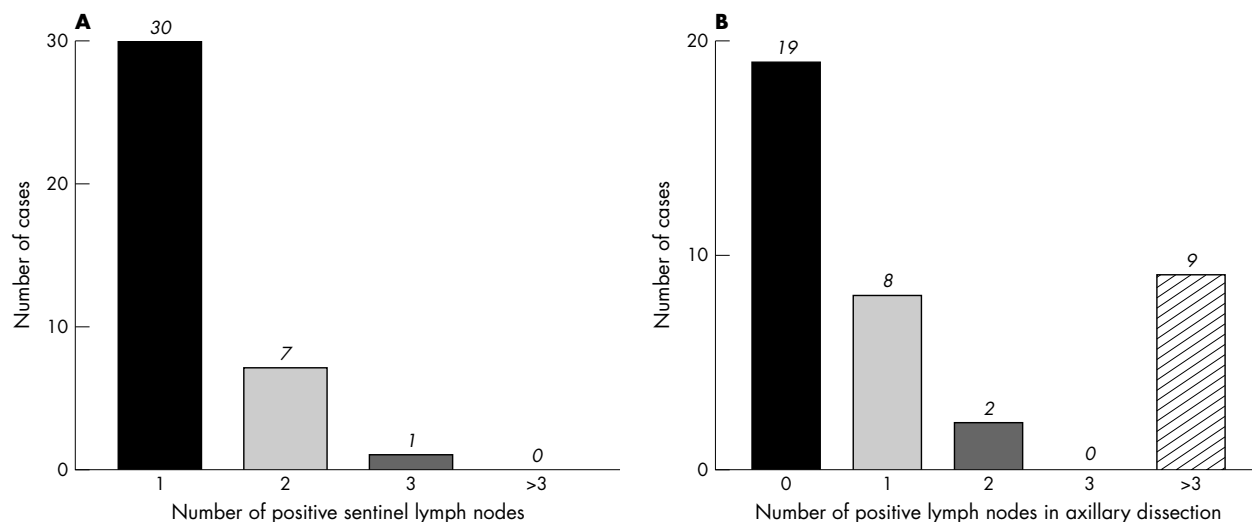


Figure 5 Bar histograms representing (A) the number of positive sentinel lymph nodes and (B) the number of positive lymph nodes found in the axillary fat in the group of patients with metastatic tumour cells in their sentinel lymph node ($n = 38$).

positive cases only one SLN was affected by metastatic tumour cells. In 19 patients none of the non-SLNs was affected, whereas nine patients showed more than three positive non-SLNs (fig 5).

Relation to DNA profile in primary tumour and SLN metastasis

As part of a routine procedure in our hospital, we also collected MP-FCM DNA data of the primary breast tumour. Thirty five of the 98 patients had a diploid and 63 an aneuploid primary breast tumour. Because more patients had an aneuploid primary breast tumour than a diploid tumour it was remarkable that in 29 of 38 positive SLNs a diploid metastasis was detected. In all cases of an aneuploid lymph node metastasis ($n = 8$) a tumour cell population was found that had a DNA index identical or close to that of the primary breast tumour.

To examine more closely the relation of the size of the aneuploid tumour fraction in the primary tumour and the size of the SLN metastasis to the incidence of aneuploid metastasis, we created a plot using both parameters (fig 6). This graph shows that in diploid breast tumours (in which the fraction of aneuploid cells in the primary tumour is 0%) no indications could be found that could help in predicting the status of the SLN and non-SLN with respect to the absence or presence of metastatic tumour cells. However, in aneuploid tumours in which the fraction of aneuploid epithelial cells was greater than 60%, the chance of finding aneuploid SLN macrometastases and also metastases in non-SLNs is higher compared with aneuploid tumours with a smaller aneuploid epithelial fraction. In the 60 patients with a negative SLN only five had a primary breast tumour that contained an aneuploid fraction greater than 60%.

DISCUSSION

The sentinel lymph node procedure has become very widely adopted in the relatively few years since the technique was first described for application to melanoma.¹² The usefulness of this procedure is based on the assumption that tumours first metastasise to regional lymph nodes, and subsequently to systemic sites. Many studies have confirmed the proposition that the SLN is predictive of the final axillary lymph node status.^{13–15} In our present study the SLN procedure as performed in our institute was found to be a highly sensitive, specific, and accurate technique: no patient with a negative SLN was found to have a metastasis in a non-SLN.

There are several methods to evaluate SLNs for occult metastatic tumour cells, including histopathological evaluation (H&E), imprint cytology,¹⁶ IHC,^{17–19} and molecular biological techniques (RT-PCR).²⁰ In addition, H&E and IHC staining can be performed on frozen and formalin fixed, paraffin wax embedded sections. The ability to use frozen sections allows an intraoperative assessment of the SLN. However, some of these techniques only have a relatively low sensitivity (H&E), whereas molecular techniques (such as RT-PCR) are encumbered by the fact that no specific gene has been described that is specific for breast cancer or cancer in general. Most molecular biological tests make use of the expression of certain genes, such as the genes encoding keratin 19^{21, 22} or carcinoembryonic antigen (CEA),²³ as markers for the presence of epithelial tumour cells. However, both genes are of low specificity for tumour cells, because transcripts of these genes are often found in the blood,²⁴ bone marrow,²⁵ and also in lymph nodes of healthy volunteers.⁶ Another pitfall of RT-PCR is the presence of benign epithelial or mesothelial inclusions.²⁶

Table 3 Incidence of positive non-SLN relative to size of primary tumour and size of metastasis in SLN

Primary tumour size (cm)	Size of SLN metastasis	No. of patients SLN positive	No of patients non-SLN positive	Non-SLN positive SLN positive (%)
≤2 cm	Micrometastasis	13	4	31
≤2 cm	Macrometastasis	15	6	40
>2 cm	Micrometastasis	2	1	50
>2 cm	Macrometastasis	8	7	88

SLN, sentinel lymph node.

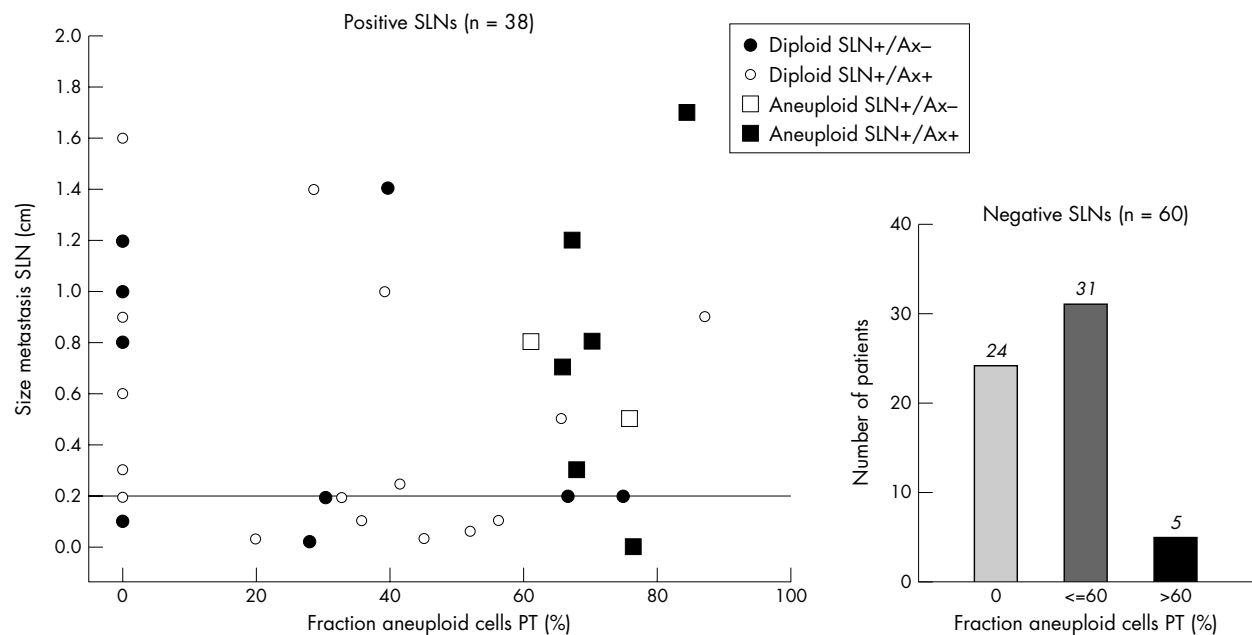


Figure 6 Comparison of the size and ploidy of the sentinel lymph node (SLN) metastasis with the fraction of aneuploid tumour cells and N stage of the primary tumour (Ax, axillary dissection; PT, primary tumour).

In our present study we investigated whether MP-FCM could be used for the detection of occult metastatic cells in lymph nodes. Flow cytometry is a technique in which many cells (thousands and more) can be analysed for one or more parameters in a relatively short time. This technique is based on a combination of IHC (using the same antibody against cytokeratin as for IHC coupled with a fluorescent label (FITC)) and DNA staining with a chemical compound (PI) that binds stoichiometrically to DNA. By using interactively defined gates the flow cytometric DNA analysis can be restricted to the cytokeratin positive fraction. In 1988, Joensuu and co-workers used single parameter flow cytometry for the detection of metastatic tumour cells in fresh material taken from fine needle aspiration biopsies of palpable lymph nodes.²⁷ In a recent study, we have described a new technique for the isolation and subsequent flow cytometric analysis of single cells from formalin fixed, paraffin wax embedded tissue.¹¹ Using this method, cell recovery was doubled compared with commonly used protocols, the quality of the DNA histograms was significantly improved, and the accessibility of several antigen epitopes, including those from cytokeratins,¹¹ steroid hormone receptors,¹⁰ and membrane surface antigens,²⁸ was restored. In our present study we applied this protocol to routinely processed formalin fixed, paraffin wax embedded lymph nodes offered to our department as part of the SLN procedure. The MP-FCM technique was compared with the histopathological evaluation and the immunohistochemical staining of the SLN. We found that with histopathological evaluation using the standard H&E staining seven patients were missed who had metastatic cells in their SLN. In six of these seven cases those tumour cells could be identified with IHC and flow cytometry. The one remaining case, which remained negative in the immunohistochemical staining, showed a DNA aneuploid population with almost the same deviation in DNA content as the corresponding primary breast tumour when analysed by MP-FCM. Because the chance of finding a clonal tumour cell population with almost the same DNA content deviation is very small, those cytokeratin positive cells found by means of MP-FCM were probably occult metastatic tumour cells originating from the primary breast tumour. In our protocol, we use two levels of 500 μ m thick lymph node tissue for the MP-FCM analysis, whereas only three levels of 2–3 μ m

thick lymph node tissue were analysed in the H&E and immunohistochemically stained sections. The chance of finding occult metastatic cells is greatest in the MP-FCM assay, where 1 mm tissue is analysed. Thus, it is likely that in the aneuploid case described above the micrometastasis was situated in one of the intervening 500 μ m thick sections cut for the MP-FCM assay.

“With histopathological evaluation using the standard haematoxylin and eosin staining seven patients were missed who had metastatic cells in their sentinel lymph node”

Microscopic evaluation of the IHC stained sections revealed many cases with cytokeratin positive interstitial reticulum cells (CIRC), a false positive staining of sinus lining cells for cytokeratin (with MNF116). Such staining can easily be recognised morphologically.²⁹ Because no morphological checks can be made to control for false positive staining for cytokeratin in the MP-FCM assay, a threshold must be built into this assay. We found that when using a threshold of 1% in the MP-FCM assay a highly specific and sensitive distinction could be made between negative and positive SLNs. In routine MP-FCM assays we usually collect 20 000 cells for a proper analysis. However, because in the SLN procedure the number of relevant epithelial tumour cells can be very low we raised the minimum of collected cells to 100 000. By using this high number of cells the reproducibility of this assay was increased (fig 3; $r = 0.9942$; $p < 0.0001$). We also found a perfect linear correlation in the “dilution experiment” between the real concentration of epithelial cells and the flow cytometric detected MNF116 positive fraction (fig 4). Low concentrations (in the range of 0.1–1%) showed a slightly higher deviation of the average number of MNF116 positive cells detected than did higher concentrations. However, even when analysing a single cell suspension with a concentration of 0.1% epithelial cells, an MNF116 positive fraction above the threshold of 1% was found. We do not have a good explanation for this remarkable finding. The first of two possibilities is that it results in part from “background staining” of CIRC (see above) and sinus lining endothelial cells, which were almost always present in the immunohistochemically

examined sections of the lymph nodes in our study. Second, it could be because the haemocytometer counting method used for this part of the study is less accurate. We are aware that this experiment is not precise enough to determine the minimal real concentration of epithelial cells that can be picked up by the MP-FCM approach. However, the linearity of the slope indicates that we are on the right track. Further research will be directed towards a flow cytometry based volumetric approach.

In a recent study by Reynolds *et al*, no non-SLN metastases were found in situations where the metastasis in the SLN was smaller than 2 mm (micrometastases) and the primary tumour smaller or equal to 2 cm (T1).³⁰ However, in our study, four of 13 patients with a T1 breast tumour showed involvement of one or two non-SLNs when a micrometastasis was detected in the SLN. Leong showed that when large numbers of patients were followed up for longer periods, micrometastasis was shown to be a significantly poor prognostic parameter, with patients having a survival rate similar to those with macrometastases.³¹ All these findings confirm the notion that there are no compelling reasons to treat patients with micrometastases in a different manner to those with macrometastases.

"The chance of finding aneuploid lymph node metastases and/or macrometastases is directly related to the size of the aneuploid fraction in the primary tumour: when this fraction increases, the chance of developing aneuploid and/or lymph node metastases also increases"

A remarkable finding was that in most cases the SLN metastasis was diploid, even when the primary breast tumour showed a DNA aneuploid tumour population. In a recent study, we have found, using a three parameter cytokeratin/steroid hormone/DNA flow cytometric analysis that a diploid cytokeratin positive cell population can also be found in most aneuploid primary breast tumours.⁹ In most of the earlier flow cytometric studies, this diploid peak was related to admixture with inflammatory cells, stromal components, and even normal duct epithelium. A major advantage of the present approach is that it allows the specific selection of the area of interest based on the information of the H&E stained section from the same tissue block, so the potential contribution of normal ductal epithelium to the cell suspension can be prevented or minimised. Bonsing and co-workers reported similar findings in their study, where they found a diploid tumour cell population in 11 of 12 aneuploid breast tumours using allelotyping analysis after flow sorting of the epithelial compartment of that tumour.³² They also demonstrated the recurrence of the diploid tumour clone in all lymph node metastases. They suggested that acquisition of metastatic propensity is an early event in the genetic progression of breast cancer. In our series of SLN metastases it was shown that the chance of finding aneuploid lymph node metastases was related to the size of the fraction of aneuploid epithelial cells in the primary tumour: primary tumours in which the aneuploid epithelial fraction was larger than 60% more often showed macrometastases (> 2 mm). Furthermore, in this group additional metastases were more often found in non-SLNs. It seems that the chance of finding aneuploid lymph node metastases and/or macrometastases is directly related to the size of the aneuploid fraction in the primary tumour: when this fraction increases, the chance of developing aneuploid and/or lymph node metastases also increases.

In conclusion, our study supports the SLN theory. Our data indicate that MP-FCM was sufficient in all cases for the detection of occult metastatic tumour cells in lymph nodes. In some cases MP-FCM was even superior to H&E and ICH and was found to be a highly specific and sensitive non-morphological technique. Although this approach is slightly more costly and

Take home messages

- In all cases, multiparameter flow cytometry (MP-FCM) could detect micrometastatic tumour cells in a large volume of lymph node tissue from sentinel lymph nodes (SLNs)
- It was sometimes superior to haematoxylin and eosin and immunohistochemical staining
- Approximately 30% of SLN micrometastases are accompanied by additional non-SLN metastases
- The size of the aneuploid fraction (> 60%) in the primary tumour may influence the risk of having both SLN and non-SLN metastases

labourious than IHC and H&E, it has several advantages, namely: (1) almost the entire lymph node is investigated, (2) it provides information about DNA ploidy, and (3) it may be possible to introduce sorting of metastatic tumour cells for further molecular studies. This technique allows the phenotypical characteristics of the lymph node metastasis and the primary breast tumour concerning DNA ploidy and sizes of the different DNA ploidy subfractions to be related to one another. However, further studies are necessary to clarify the relation found between the size of the aneuploid epithelial fraction in the primary tumour and the size and ploidy of the lymph node metastasis.

Authors' affiliations

M P G Leers, R H M G Schoffelen, J G M Hoop, P H M H Theunissen, M Nap, Department of Pathology, Atrium Medical Centre Heerlen, PO Box 4446, 6401 CX Heerlen, The Netherlands
J W A Oosterhuis, H vd Bijl, Department of Surgery, Atrium Medical Centre Heerlen
A Rahmy, W Tan, Department of Nuclear Medicine, Atrium Medical Centre Heerlen

REFERENCES

- 1 **Jatoi I**, Hilsenbeck SG, Clark GM, *et al*. Significance of axillary lymph node metastasis in primary breast cancer [published erratum appears in *J Clin Oncol* 1999;17:3365]. *J Clin Oncol* 1999;17:2334-40.
- 2 **Giuliano AE**, Kirgan DM, Guenther JM, *et al*. Lymphatic mapping and sentinel lymphadenectomy for breast cancer [see comments]. *Ann Surg* 1994;220:391-8;discussion 398-401.
- 3 **Alex JC**, Weaver DL, Fairbank JT, *et al*. Gamma-probe-guided lymph node localization in malignant melanoma. *Surg Oncol* 1993;2:303-8.
- 4 **Alex JC**, Krag DN. Gamma-probe guided localization of lymph nodes. *Surg Oncol* 1993;2:137-43.
- 5 **Terui S**, Kato H, Hirashima T, *et al*. An evaluation of the mediastinal lymphoscintigram for carcinoma of the esophagus studied with 99mTc rhenium sulfur colloid. *Eur J Nucl Med* 1982;7:99-101.
- 6 **Bostick PJ**, Chatterjee S, Chi DD, *et al*. Limitations of specific reverse-transcriptase polymerase chain reaction markers in the detection of metastases in the lymph nodes and blood of breast cancer patients. *J Clin Oncol* 1998;16:2632-40.
- 7 **Bloom HJG**, Richardson W. Histological grading and prognosis in breast cancer. *Br J Cancer* 1957;11:359-77.
- 8 **Sobin LH**, Wittekind Ch, eds. *UICC TNM classification of malignant tumours*, 5th ed. Berlin: Springer Verlag, 1997.
- 9 **Leers MPG**, Nap M. Steroid receptor heterogeneity in relation to DNA-index in breast cancer: a multiparameter flow cytometric approach on paraffin embedded tumor samples. *Breast J* 2001;7:249-59.
- 10 **Leers MPG**, Schutte B, Theunissen PH, *et al*. A novel flow cytometric steroid hormone receptor assay for paraffin-embedded breast carcinomas: an objective quantification of the steroid hormone receptors and direct correlation to ploidy status and proliferative capacity in a single-tube assay [in process citation]. *Hum Pathol* 2000;31:584-92.
- 11 **Leers MPG**, Schutte B, Theunissen PH, *et al*. Heat pretreatment increases resolution in DNA flow cytometry of paraffin-embedded tumor tissue. *Cytometry* 1999;35:260-6.
- 12 **Reintgen D**. More rational and conservative surgical strategies for malignant melanoma using lymphatic mapping and sentinel node biopsy techniques. *Curr Opin Oncol* 1996;8:152-8.
- 13 **Weaver DL**, Krag DN, Ashikaga T, *et al*. Pathologic analysis of sentinel and nonsentinel lymph nodes in breast carcinoma: a multicenter study [see comments]. *Cancer* 2000;88:1099-107.
- 14 **Liberman L**. Pathologic analysis of sentinel lymph nodes in breast carcinoma [editorial; comment]. *Cancer* 2000;88:971-7.
- 15 **Cserni G**. Axillary staging of breast cancer and the sentinel node. *J Clin Pathol* 2000;53:733-41.

- 16 **Fisher CJ**, Boyle S, Burke M, *et al*. Intraoperative assessment of nodal status in the selection of patients with breast cancer for axillary clearance. *Br J Surg* 1993;**80**:457-8.
- 17 **McGuckin MA**, Cummings MC, Walsh MD, *et al*. Occult axillary node metastases in breast cancer: their detection and prognostic significance. *Br J Cancer* 1996;**73**:88-95.
- 18 **Torrenga H**, Rahusen FD, Meijer S, *et al*. Sentinel node investigation in breast cancer: detailed analysis of the yield from step sectioning and immunohistochemistry. *J Clin Pathol* 2001;**54**:550-2.
- 19 **Torrenga H**, Rahusen FD, Borgstein PJ, *et al*. Immunohistochemical detection of lymph-node metastases. *Lancet* 2000;**355**:144.
- 20 **Schoenfeld A**, Luqmani Y, Smith D, *et al*. Detection of breast cancer micrometastases in axillary lymph nodes by using polymerase chain reaction. *Cancer Res* 1994;**54**:2986-90.
- 21 **Hildebrandt M**, Mapara MY, Korner U, *et al*. Reverse transcriptase-polymerase chain reaction (RT-PCR)-controlled immunomagnetic purging of breast cancer cells using the magnetic cell separation (MACS) system: a sensitive method for monitoring purging efficiency. *Exp Hematol* 1997;**25**:57-65.
- 22 **Datta YH**, Adams PT, Drobyski WR, *et al*. Sensitive detection of occult breast cancer by the reverse-transcriptase polymerase chain reaction. *J Clin Oncol* 1994;**12**:475-82.
- 23 **Neumaier M**, Gerhard M, Wagener C. Diagnosis of micrometastases by the amplification of tissue-specific genes. *Gene* 1995;**159**:43-7.
- 24 **Lopez-Guerrero JA**, Bolufer-Gilabert P, Sanz-Alonso M, *et al*. Minimal illegitimate levels of cytokeratin K19 expression in mononucleated blood cells detected by a reverse transcription PCR method (RT-PCR). *Clin Chim Acta* 1997;**263**:105-16.
- 25 **Zippelius A**, Kufer P, Honold G, *et al*. Limitations of reverse-transcriptase polymerase chain reaction analyses for detection of micrometastatic epithelial cancer cells in bone marrow [see comments]. *J Clin Oncol* 1997;**15**:2701-8.
- 26 **van Diest PJ**, Peterse HL, Borgstein PJ, *et al*. Pathological investigation of sentinel lymph nodes. *Eur J Nucl Med* 1999;**26**:S43-9.
- 27 **Joensuu H**, Klemi PJ, Eerola E. Flow cytometric DNA analysis combined with fine needle aspiration biopsy in the diagnosis of palpable metastases. *Anal Quant Cytol Histol* 1988;**10**:256-60.
- 28 **Leers MP**, Theunissen PH, Ramaekers FC, *et al*. Clonality assessment of lymphoproliferative disorders by multiparameter flow cytometry of paraffin-embedded tissue: an additional diagnostic tool in surgical pathology. *Hum Pathol* 2000;**31**:422-7.
- 29 **Gould VE**, Bloom KJ, Franke WW, *et al*. Increased numbers of cytokeratin-positive interstitial reticulum cells (CIRC) in reactive, inflammatory and neoplastic lymphadenopathies: hyperplasia or induced expression? *Virchows Arch* 1995;**425**:617-29.
- 30 **Reynolds C**, Mick R, Donohue JH, *et al*. Sentinel lymph node biopsy with metastasis: can axillary dissection be avoided in some patients with breast cancer? *J Clin Oncol* 1999;**17**:1720-6.
- 31 **Leong AS**. The prognostic dilemma of nodal micrometastases in breast carcinoma. *Gan To Kagaku Ryoho* 2000;**27**(suppl 2):315-20.
- 32 **Bonsing BA**, Corver WE, Fleuren GJ, *et al*. Allelotype analysis of flow-sorted breast cancer cells demonstrates genetically related diploid and aneuploid subpopulations in primary tumors and lymph node metastases. *Genes Chromosomes Cancer* 2000;**28**:173-83.

Find out what's in the latest issue
the moment it's published

Email Alerts

Sign up to receive the table of contents by email every month. You can select from three alerts: Table of Contents (full), TOC Awareness (notice only); *Journal of Clinical Pathology* related announcements.

www.jclinpath.com



Multiparameter flow cytometry as a tool for the detection of micrometastatic tumour cells in the sentinel lymph node procedure of patients with breast cancer

M P G Leers, R H M G Schoffelen, J G M Hoop, et al.

J Clin Pathol 2002 55: 359-366

doi:

Updated information and services can be found at:

<http://jcp.bmj.com/content/55/5/359.full.html>

References

These include:

This article cites 31 articles, 8 of which can be accessed free at:

<http://jcp.bmj.com/content/55/5/359.full.html#ref-list-1>

Article cited in:

<http://jcp.bmj.com/content/55/5/359.full.html#related-urls>

Email alerting service

Receive free email alerts when new articles cite this article. Sign up in the box at the top right corner of the online article.

Topic Collections

Articles on similar topics can be found in the following collections

[Immunology \(including allergy\)](#) (1279 articles)

[Breast cancer](#) (378 articles)

Notes

To request permissions go to:

<http://group.bmj.com/group/rights-licensing/permissions>

To order reprints go to:

<http://journals.bmj.com/cgi/reprintform>

To subscribe to BMJ go to:

<http://group.bmj.com/subscribe/>