

ORIGINAL ARTICLE

Foveolar hyperplasia at the gastric cardia: prevalence and associations

M Voutilainen, M Juhola, M Färkkilä, P Sipponen

J Clin Pathol 2002;55:352–354

See end of article for authors' affiliations

Correspondence to:
Dr M Voutilainen,
Jyväskylä Central Hospital,
Department of Medicine,
FIN-40620 Jyväskylä,
Finland;
markku.voutilainen@ksshp.fiAccepted for publication
27 November 2001

Aims: In the gastric antrum and body, foveolar hyperplasia is a feature of reactive gastritis resulting from—for example, duodenogastric bile reflux and the use of non-steroidal anti-inflammatory drugs (NSAIDs). The aim of this study was to examine the occurrence and clinical relevance of gastric cardiac foveolar hyperplasia.

Methods: The study population was drawn from a consecutive series of 1698 patients sent for upper gastrointestinal endoscopy. Only cases without chronic gastritis or Barrett's oesophagus were included. The final study population consisted of 307 patients.

Results: Foveolar hyperplasia was seen in the gastric cardiac mucosa in 31 (10%) patients with histologically normal stomach mucosa, but none had endoscopically noticeable hyperplastic polyps. Compared with patients without gastric cardiac hyperplasia, those with hyperplasia more often had chronic inflammation and complete intestinal metaplasia in the junctional biopsies (48% v 77% and 9% v 26%, respectively). Logistic regression analysis revealed that chronic cardiac inflammation (odds ratio (OR), 3.2; 95% confidence interval (CI), 1.3 to 7.8) and intestinal metaplasia of the complete type (OR, 2.8; 95% CI, 1.1 to 7.1) were independent risk factors for cardiac foveolar hyperplasia. In univariate analysis, endoscopic erosive oesophagitis (endoscopy positive gastro-oesophageal reflux disease) and the use of NSAIDs were not related to the presence of foveolar hyperplasia.

Conclusions: Foveolar hyperplasia in the gastric cardiac mucosa occurs in patients with histologically normal non-gastritic stomachs and may develop as a consequence of chronic inflammation limited to the gastro-oesophageal junction ("junctitis"). It is not associated directly with endoscopy positive gastro-oesophageal reflux disease or the use of NSAIDs.

Reactive or chemical gastritis is defined as foveolar elongation, tortuosity, and hypercellularity of the gastric surface epithelium, together with oedema, vasodilatation, congestion of gastric lamina propria, and a paucity of inflammatory cells.¹ This type of gastritis has been thought to result from duodenogastric bile reflux or the use of non-steroidal anti-inflammatory drugs (NSAIDs).^{1–5} A Japanese study indicated that foveolar hyperplasia and inflammatory oedema are essential for the formation of hyperplastic polyps with intraluminal projections.⁶

A study from the 1980s suggested that hyperplastic polyps and foveolar hyperplasia in patients with atrophic corpus gastritis indicate an increased risk of gastric cancer.⁷ Large hyperplastic polyps may harbour carcinoma.⁸ Genetic analyses have suggested that simultaneous large gastric hyperplastic polyps have a clonal origin and may therefore be neoplastic tumours.⁹ Furthermore, hyperplastic polyps may have a replication error phenotype that has been linked to various cancers.¹⁰ These observations indicate that hyperplastic polyps harbour a risk of developing into carcinoma—although the risk is considerably lower than that of adenomas.

"Genetic analyses have suggested that simultaneous large gastric hyperplastic polyps have a clonal origin and may therefore be neoplastic tumours"

Gastro-oesophageal reflux disease (GORD) induces inflammation and intestinal metaplasia in both oesophageal and cardiac mucosa at the gastro-oesophageal junction.^{11–14} The aim of our present study was to examine the prevalence and association of gastric cardiac mucosal hyperplasia with hyperplastic polyps. Our hypothesis was that these lesions are positively associated with GORD.

METHODS

Our study population was drawn from 1698 consecutive patients referred for upper gastrointestinal endoscopy as a result of dyspepsia or GORD symptoms. A more detailed description of the study population has been published elsewhere.¹⁵ Those with chronic gastritis of any type, previous *Helicobacter pylori* eradication treatment, gastric surgery, or Barrett's oesophagus were excluded. When only cases with adequate biopsy specimens from the gastric antrum, corpus, and cardia were included, the final study population consisted of 307 patients.

The demographic, clinical, and endoscopic data were collected via structured questionnaires from the general practitioners referring the patients for endoscopy, and the doctors performing upper gastrointestinal endoscopies. At endoscopy, the proximal margin of gastric folds was identified as the junction between the oesophagus and stomach. The normal squamocolumnar junction, or Z-line, is coincident with the oesophagogastric junction. The presence of one or more mucosal breaks (erosions or ulcerations) in the distal oesophagus was considered diagnostic for endoscopic erosive oesophagitis (endoscopy positive GORD). Biopsy specimens were obtained from just distal to or across the normal appearing Z-line, from gastric antrum and body (two biopsy specimens from each site).

Biopsy specimens were stained with haematoxylin and eosin, alcian blue periodic acid Schiff pH 2.5 (AB-PAS), and modified Giemsa. Only cases with histologically typical gastric

Abbreviations: AB-PAS, alcian blue periodic acid Schiff; CI, confidence interval; GORD, gastro-oesophageal reflux disease; NSAIDs, non-steroidal anti-inflammatory drugs; OR, odds ratio

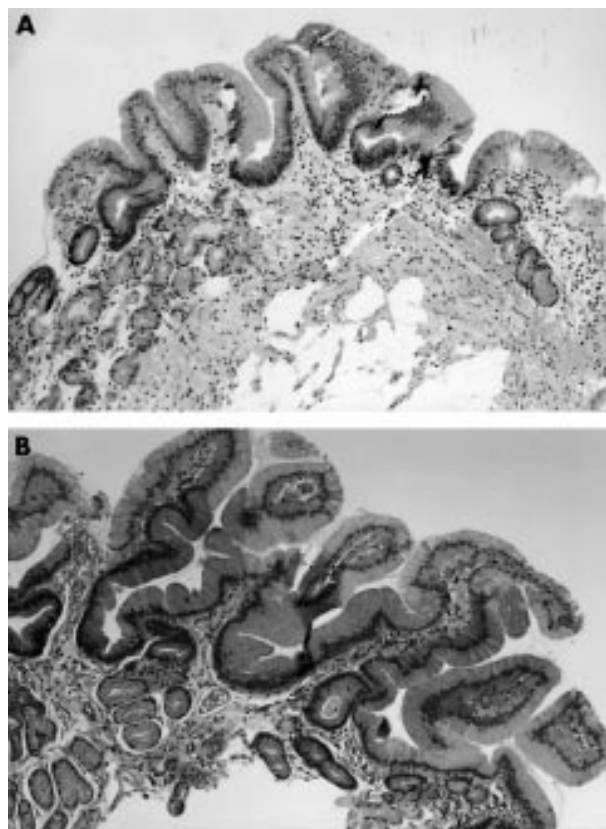


Figure 1 (A) Normal gastric cardiac foveolae are lined by loosely packed mucus secreting cells. (B) Abnormal branching and twisting, and at least a twofold elongation of foveolae was considered the diagnostic criterion for gastric cardiac foveolar hyperplasia.

cardiac mucosa were included in our analysis. Foveolar hyperplasia was defined as the presence of abnormal branching and twisting and at least a twofold elongation of gastric cardiac foveolae and pits. Before the study, the five pathologists participating in the investigation agreed on the histological criteria for foveolar hyperplasia (fig 1). Chronic inflammation of the gastric cardia was defined as the infiltration of the cardiac mucosa by mononuclear inflammatory cells. Complete and incomplete intestinal metaplasia of the gastric cardia were detected and differentiated by means of the AB-PAS stain.

Statistics

Mann-Whitney U and χ^2 tests were used to compare continuous and non-continuous variables, respectively, and p values < 0.05 were considered to be significant. Multiple stepwise logistic regression analysis (forward) was used to determine the independent risk factors for GORD. The statistical analyses were performed by SPSS 10.0 for Windows® software.

Ethics

Our study was approved by the ethics committee of Jyväskylä Central Hospital.

RESULTS

Our study population consisted of 307 patients, with a mean age of 53 years (95% confidence interval (CI), 51 to 55) and a male to female ratio of 1 : 1.8. A total of 31 (10%) patients had gastric foveolar hyperplasia of the cardiac mucosa on histological examination. The presence of hyperplasia was significantly associated with chronic inflammation and intestinal metaplasia of the complete type, whereas endoscopic erosive oesophagitis or the use of NSAIDs showed no

Table 1 Results of the comparison between the gastric cardiac hyperplasia group and those without cardiac hyperplasia

	Hyperplasia (n=31)	No hyperplasia (n=276)
Mean age (years, 95% CI)	55 (49 to 60)	53 (51 to 55)
Male : female ratio	1 : 1.2	1 : 1.8
NSAID use	19%	19%
Cardia incomplete IM	13%	7%
Cardia complete IM	26%	9%**
Carditis	77%	48%**
Endoscopy positive GORD	19%	14%

**p < 0.01.

CI, confidence interval; GORD, gastro-oesophageal reflux disease; IM, intestinal metaplasia; NSAID, non-steroidal anti-inflammatory drug.

association with hyperplasia (table 1). In logistic regression analysis, the presence of foveolar hyperplasia was significantly associated with chronic inflammation (odds ratio (OR), 3.2; 95% CI, 1.3 to 7.8) and intestinal metaplasia of the complete type (OR, 2.8; 95% CI, 1.1 to 7.1) in the cardiac mucosa. In multivariate analysis, gastric cardiac hyperplasia was not associated with either age, sex, or intestinal metaplasia of the incomplete type at the gastro-oesophageal junction.

Nine patients (3%) had a hamartomatous polyp in the gastric body, but no polyps of any type were observed in the gastric cardia or in the gastric antrum. The presence of hamartomatous cystic polyps in the gastric corpus was not associated with cardiac foveolar hyperplasia: one patient (3%) with cardiac foveolar hyperplasia and eight patients (3%) without had hamartomatous polyps in the gastric body.

DISCUSSION

Foveolar hyperplasia in the gastric cardiac mucosa and hyperplastic polyps could theoretically be associated with GORD. We excluded those patients with chronic gastritis from our study, and limited the analysis to patients with normal, non-gastric gastric mucosa. This was done because chronic inflammation at the gastro-oesophageal junction in the gastric cardia is related to *H pylori* infection in most cases and is, in fact, just an extension of gastritis into the gastric cardia.^{13 16 17} Therefore, in subjects with *H pylori* associated gastritis, possible cardia specific lesions are intermixed with those related to gastritis. In addition, we only investigated foveolar hyperplasia, not all morphological alterations of classic reactive or chemical gastritis.¹ This was because gastric cardiac inflammation is a very common finding,^{12 13} and not all criteria of reactive gastritis may be applicable to cardiac mucosa.

Our study revealed that cardia specific foveolar hyperplasia is not an uncommon finding, having a prevalence of 10%, and that it is related to chronic inflammation in the gastric cardia. This frequency is somewhat lower than that found by El-Zimaity *et al*, who reported a 30% prevalence of cardia foveolar hyperplasia. In their study, *H pylori* positive patients were included, which certainly affected their results.¹⁸ An even higher prevalence of 77% of foveolar hyperplasia (*H pylori* positive cases included) has also been reported.¹⁹ In our study, foveolar hyperplasia was examined by five pathologists and this may have resulted in variations in the scoring of hyperplasia and may have reduced the reproducibility of the results.

“We found no significant association between gastric cardiac foveolar hyperplasia and endoscopy positive gastro-oesophageal reflux disease”

Noxious agents other than *H pylori* (bile, NSAIDs) induce reactive changes in the gastric mucosa,^{3 4} although results vary

Take home messages

- Foveolar hyperplasia in the gastric cardiac mucosa is found in patients with histologically normal non-gastritic stomachs and may develop as a consequence of chronic inflammation limited to the gastro-oesophageal junction ("junctionitis")
- Foveolar hyperplasia in the gastric cardiac mucosa is not associated directly with endoscopy positive gastro-oesophageal reflux disease or the use of non-steroidal anti-inflammatory drugs

and are conflicting.²⁰ Because the exposure of the gastric cardia to acid must be a frequent, perhaps normal phenomenon,²¹ which is increased in reflux disease, we wanted to examine whether GORD would induce foveolar hyperplasia at the cardiac mucosa. We found no significant association between gastric cardiac foveolar hyperplasia and endoscopy positive GORD, a result which agrees with that reported by El-Zimaity *et al.*¹⁸ However, endoscopy positive GORD comprises less than half of all GORD cases and a closer study of the associations of cardiac foveolar hyperplasia with non-erosive GORD determined by 24 hour pH monitoring is needed. Our results may also be biased as a result of the exclusion of most of the original study population from our analysis. We excluded patients with Barrett's oesophagus, because most of them underwent endoscopy as part of a surveillance programme and their inclusion in our present study might have biased our results.

However, chronic cardiac inflammation, which reportedly is associated with GORD,^{12 13 22} was an independent risk factor for cardiac foveolar hyperplasia. This finding suggests that foveolar hyperplasia may at least indirectly be related to GORD. We suggest that—analogue to *H pylori* induced foveolar hyperplasia²³—chronic inflammation at the gastric cardia may induce interleukin production, leading to the development of foveolar hyperplasia in some cases.

Foveolar hyperplasia may be the precursor lesion for hyperplastic polyps,⁶ although this view is not uniformly accepted.²⁴ We found no gastric cardiac hyperplastic polyps, but a cross sectional study does not exclude the possibility that foveolar hyperplasia may in time progress to hyperplastic polyps. Hyperplastic cardiac polyps reportedly occur, although most are seen in the gastric corpus or antrum.^{6 24} However, hyperplastic nodules at the gastro-oesophageal junction may progress to high grade dysplasia.²⁵ The risk of gastric cardiac hyperplastic changes developing into dysplasia and carcinoma is obviously very low.

In conclusion, foveolar hyperplasia of the gastric cardiac mucosa occurs in subjects with normal, non-gastritic stomachs and is closely related to chronic inflammation of the gastric cardiac mucosa. Gastric cardiac foveolar hyperplasia does not seem to be a direct objective marker for GORD.

ACKNOWLEDGEMENTS

In addition to the authors, the following investigators participated in the present study: L Ahlskog-Muraja, T Antikainen, S Antila, J Antinen, M Hallikas, K-P Hämäläinen, H Janhonen, M Kairaluoma, K Karjalainen, P Kauranen, M Kolu, H Korhonen, J Korhonen, R Koskela, R Krees, I Kunnamo, V Kärjä, P Laaksonen, M Laukkanen, R Liisanantti, M Lohman, T Mäntynen, K Nuorva, A Palmu, U Palmu, M Pellinen, P Särkkä, H Selänne, T Tervo, M Udd, and J Viinikka. M Voutilainen has received research funding from Jyväskylä Central Hospital. A part of this study was presented in poster form and awarded Poster of Distinction prize during the 8th United European Gastroenterology Week, Brussels, 2000.

Authors' affiliations

M Voutilainen, M Juhola, Department of Medicine and Pathology, Jyväskylä Central Hospital, FIN-40620 Jyväskylä, Finland
M Färkkilä, Department of Medicine, Helsinki University Hospital, FIN-00029 Helsinki, Finland
P Sipponen, Department of Pathology, Jorvi Hospital, FIN-02740 Espoo, Finland

REFERENCES

- 1 Dixon MF, O'Connor HJ, Axon ATR, *et al.* Reflux gastritis: distinct histopathological entity? *J Clin Pathol* 1986;**39**:524–30.
- 2 Sobala GM, King RFG, Axon ATR, *et al.* Reflux gastritis in the intact stomach. *J Clin Pathol* 1990;**43**:303–6.
- 3 Sobala GM, O'Connor HJ, Dewar EP, *et al.* Bile reflux and intestinal metaplasia in gastric mucosa. *J Clin Pathol* 1993;**46**:235–40.
- 4 Quinn CM, Bjarnason I, Price AB. Gastritis in patients on non-steroidal anti-inflammatory drugs. *Histopathology* 1993;**23**:341–8.
- 5 McCarthy CJ, McDermott M, Hourihane D, *et al.* Chemical gastritis induced by naproxen in the absence of *Helicobacter pylori* infection. *J Clin Pathol* 1995;**48**:61–3.
- 6 Mitsufuji S, Tsuchihashi Y, Kodama T. Histogenesis of hyperplastic polyps of the stomach in terms of cellular proliferation. *J Gastroenterol* 1994;**29**:559–68.
- 7 Laxén F. Gastric carcinoma and pernicious anaemia in long-term endoscopic follow-up of subjects with gastric polyps. *Scand J Gastroenterol* 1984;**19**:535–40.
- 8 Zea-Iriarte W-L, Sekine I, Iitsuno M, *et al.* Carcinoma in gastric hyperplastic polyps. A phenotypic study. *Dig Dis Sci* 1996;**41**:377–86.
- 9 Dijkhuizen SMM, Entius MM, Clement MJ, *et al.* Multiple hyperplastic polyps in the stomach: evidence for clonality and neoplastic potential. *Gastroenterology* 1997;**112**:561–6.
- 10 Nogueira AMMF, Carneiro F, Secura R, *et al.* Microsatellite instability in hyperplastic and adenomatous polyps of the stomach. *Cancer* 1999;**86**:1649–56.
- 11 Riddell RH. The biopsy diagnosis of gastroesophageal reflux disease, "carditis", and Barrett's esophagus, and sequelae of therapy. *Am J Surg* 1996;**20**(suppl 1):S31–50.
- 12 Bowrey DJ, Clark GW, Williams GT. Patterns of gastritis in patients with gastro-oesophageal reflux disease. *Gut* 1999;**45**:798–803.
- 13 Voutilainen M, Färkkilä M, Mecklin JP, *et al.* Chronic inflammation at the gastroesophageal junction (carditis) appears to be a specific finding related to *Helicobacter pylori* infection and gastroesophageal reflux disease. *Am J Gastroenterol* 1999;**94**:3175–80.
- 14 Voutilainen M, Färkkilä M, Juhola M, *et al.* Complete and incomplete intestinal metaplasia at the oesophagogastric junction: prevalences and associations with endoscopic erosive oesophagitis and gastritis. *Gut* 1999;**45**:644–8.
- 15 Voutilainen M, Sipponen P, Mecklin JP, *et al.* Gastroesophageal reflux disease: prevalence, clinical, endoscopic and histopathological findings in 1128 consecutive patients referred for endoscopy due to dyspeptic and reflux symptoms. *Digestion* 2000;**61**:6–13.
- 16 Genta RM, Huberman RM, Graham DY. The gastric cardia in *Helicobacter pylori* infection. *Hum Pathol* 1994;**25**:915–19.
- 17 Chen YY, Antonioli DA, Spechler SJ, *et al.* Gastroesophageal reflux disease versus *Helicobacter pylori* infection as the cause of gastric carditis. *Mod Pathol* 1998;**11**:950–6.
- 18 El-Zimaity HMT, Vergheze VJ, Ramchatesingh J, *et al.* The gastric cardia in gastro-oesophageal disease. *J Clin Pathol* 2000;**53**:619–25.
- 19 Peck-Radosavljevic M, Püspök A, Pätzl R, *et al.* Histological findings after routine biopsy at the gastro-oesophageal junction. *Eur J Gastroenterol Hepatol* 1999;**11**:1265–70.
- 20 El-Zimaity HMT, Genta RM, Graham DY. Histological features do not define NSAID-induced gastritis. *Hum Pathol* 1996;**27**:1348–54.
- 21 Katzka DA, Gideon RM, Castell DO. Normal patterns of acid exposure at the gastric cardia: a functional midpoint between the esophagus and stomach. *Am J Gastroenterol* 1998;**93**:1236–42.
- 22 Lembo T, Ippoliti AF, Ramers C, *et al.* Inflammation of the gastro-oesophageal junction (carditis) in patients with symptomatic gastro-oesophageal reflux disease: a prospective study. *Gut* 1999;**45**:484–8.
- 23 Yasunaga Y, Shinomura Y, Kanayama S, *et al.* Increased production of interleukin 1 β and hepatocyte growth factor may contribute to foveolar hyperplasia in enlarged fold gastritis. *Gut* 1996;**39**:787–94.
- 24 Stolte M, Bethke B, Sticht T, *et al.* Differentiation of focal foveolar hyperplasia from hyperplastic polyps in gastric biopsy material. *Pathol Res Pract* 1995;**191**:1198–202.
- 25 Gangarosa L, Halter S, Mertz H. Dysplastic gastroesophageal junction nodules—a precursor to junctional adenocarcinoma. *Am J Gastroenterol* 1999;**94**:835–8.



Foveolar hyperplasia at the gastric cardia: prevalence and associations

M Voutilainen, M Juhola, M Färkkilä, et al.

J Clin Pathol 2002 55: 352-354

doi:

Updated information and services can be found at:

<http://jcp.bmj.com/content/55/5/352.full.html>

These include:

References

This article cites 25 articles, 9 of which can be accessed free at:

<http://jcp.bmj.com/content/55/5/352.full.html#ref-list-1>

Email alerting service

Receive free email alerts when new articles cite this article. Sign up in the box at the top right corner of the online article.

Topic Collections

Articles on similar topics can be found in the following collections

[Immunology \(including allergy\)](#) (1279 articles)

[Inflammation](#) (129 articles)

[Stomach and duodenum](#) (90 articles)

[Oesophagus](#) (28 articles)

[Biological agents](#) (10 articles)

[Clinical diagnostic tests](#) (637 articles)

[Endoscopy](#) (21 articles)

[Oesophageal cancer](#) (44 articles)

[Pancreas and biliary tract](#) (114 articles)

Notes

To request permissions go to:

<http://group.bmj.com/group/rights-licensing/permissions>

To order reprints go to:

<http://journals.bmj.com/cgi/reprintform>

To subscribe to BMJ go to:

<http://group.bmj.com/subscribe/>