

ORIGINAL ARTICLE

Chlamydia pneumoniae in infrequently examined blood vessels

D Taylor-Robinson, B J Thomas, R Goldin, R Stanbridge

J Clin Pathol 2002;55:218-220

See end of article for authors' affiliations

Correspondence to:
Professor D Taylor-Robinson, 6 Vache Mews, Vache Lane, Chalfont St Giles, Buckinghamshire HP8 4UT, UK

Accepted for publication 20 September 2001

Aim: To determine the prevalence of *Chlamydia pneumoniae* DNA in infrequently examined blood vessels.**Methods:** Vessels obtained from 15 men and six women at coronary artery bypass surgery were tested by a nested polymerase chain reaction (PCR) assay for *C pneumoniae* DNA.**Results:** *Chlamydia pneumoniae* DNA was detected in four of six atheromatous ascending aorta specimens but in none of eight non-atheromatous aorta specimens, in six of 11 atheromatous internal mammary artery specimens but in none of seven non-atheromatous internal mammary artery specimens, in five of seven long saphenous vein specimens showing evidence of disease but in none of 12 specimens without evidence of disease, and in two of three previously grafted veins. Overall, *C pneumoniae* occurred significantly more often in diseased than in normal vessels ($p = < 0.00001$).**Conclusions:** *Chlamydia pneumoniae* is often present in diseased areas of arteries, including the internal mammary arteries, and even in diseased areas of veins. It is not present in apparently healthy areas of either type of vessel.

Chlamydia pneumoniae, an obligately intracellular micro-organism, commonly causes a spectrum of upper and lower respiratory tract diseases in humans.¹ It was first associated with coronary heart disease on the basis of a serological study in Finland.² Although this and further serological data that have accrued in the past 12 years have elicited general interest and dispute,³⁻⁵ the finding of *C pneumoniae* in the atheromatous lesions of coronary arteries eight years ago⁶ intensified interest in the association. Since then, the organisms have been detected by various techniques in the atheromatous lesions of various major arteries that have been examined in more than 30 studies,⁷ and of the various micro-organisms that could be involved in the pathogenesis of atherosclerosis, evidence for the role of *C pneumoniae* is relatively strong.⁸

"*Chlamydia pneumoniae* was first associated with coronary heart disease on the basis of a serological study in Finland"

We have examined normal and abnormal portions of ascending aortas, internal mammary arteries, and long saphenous veins for the following reasons. First, overall, these vessels have been examined least frequently for *C pneumoniae*,⁷ although they may be obtained readily at coronary artery bypass surgery. Second, internal mammary arteries contain atheromatous lesions less often than many other arteries, so that obtaining normal tissue from them should be easy. Third, veins that are to be used in bypass surgery are not subject to atheromatous changes and yet some have been recorded as *C pneumoniae* positive.^{9, 10}

METHODS

Vessels were obtained from 21 patients (15 men and six women) at coronary artery bypass surgery. Their ages ranged from 52 to 81 years (mean, 65). Specimens of ascending aorta, internal mammary artery (right or left), and long saphenous vein from the upper leg were obtained from each of 14 patients. A sample of internal mammary artery and long saphenous vein, but not aorta, was taken from a further four

patients and saphenous vein alone from one patient. In addition, three failed grafted veins were removed and examined.

Some artery and vein specimens appeared macroscopically normal, whereas others on sectioning appeared to have fatty areas or areas that seemed not as soft on pressure with a scalpel blade. In this last case, an abnormal area of vessel was sampled, and in the former, a normal area. Each piece was divided into two portions. One portion was fixed in 10% phosphate buffered formalin, embedded in paraffin wax, and sections stained with haematoxylin and eosin and elastic van Gieson stains for histopathological examination, on which evidence of atheroma was based. The adjacent portion was frozen at -70°C before being tested by a nested polymerase chain reaction (PCR) assay for *C pneumoniae* DNA. The PCR assay was conducted with appropriate controls and with precautions to prevent DNA cross contamination, according to a method described previously.⁹

RESULTS

Chlamydia pneumoniae in arteries

Of 14 aortic specimens examined, six showed atheromatous lesions that histologically comprised infiltration of the intimal and muscle layers by chronic inflammatory cells, mainly lymphocytes; of these six specimens, four were PCR positive for *C pneumoniae*. In contrast, of eight specimens that showed no evidence of atheroma, that is without evidence of inflammatory cell infiltration, none was PCR positive. Similarly, of 18 internal mammary artery specimens examined, 11 showed atheromatous lesions histologically; of these 11, six were PCR positive for *C pneumoniae*. In contrast, of seven internal mammary artery specimens for which there was no evidence of atheroma, none was PCR positive. In total, 10 of 17 atheromatous artery specimens were PCR positive in contrast to none of 15 specimens without disease (Fisher's exact test, two tailed: $p = 0.00035$). Advanced atheromatous lesions¹¹ of the aorta and internal mammary artery were not seen, so that an association between the degree of atheroma and *C pneumoniae* positivity was not assessable.

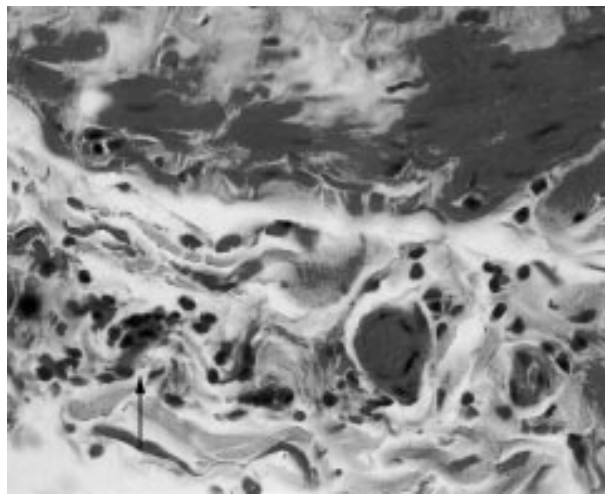


Figure 1 Section of chlamydia positive long saphenous vein showing sparse focal lymphocytic infiltration of the muscle. Haematoxylin and eosin; original magnification, $\times 400$.

Chlamydia pneumoniae in veins

Of 19 long saphenous vein specimens examined, seven showed sparse infiltration of the intimal and muscle layers by chronic inflammatory cells (fig 1); of these seven specimens, five were PCR positive for *C pneumoniae*. Intimal fibrosis was also seen in 11 of the 19 specimens and in all of the seven with inflammatory changes. Because infiltration and fibrosis were mild in all cases, it was not feasible to relate a degree of severity with *C pneumoniae* positivity. In contrast to inflamed tissues, of 12 specimens without evidence of infiltration histologically, none was PCR positive (Fisher's exact test, two tailed: $p = 0.002$). Specimens of three failed grafted veins that had been removed all showed gross intimal and subintimal thickening; two of these were PCR positive for *C pneumoniae*.

When considering both arteries and veins, of the 27 specimens that had signs of disease histologically, 17 were PCR positive for *C pneumoniae*. In contrast, of the 27 specimens for which no signs of disease were apparent histologically, none was PCR positive (χ^2 test, $p = < 0.00001$).

DISCUSSION

We chose to use the PCR technique because of its sensitivity and specificity. We did not use immunocytochemistry because previous experience has shown that spurious staining can occur,^{11 12} and neither did we use electron microscopy, which we have used previously to demonstrate *C pneumoniae* in tissues,¹¹ but which is insensitive as a means of detection. In addition, although serology is arguably of value in large scale studies as an epidemiological tool,³⁻⁵ in a small study it is not rewarding to attempt to relate *C pneumoniae* antibody titres to the PCR positivity of vessels.^{7 13}

All of the three types of vessel from some subjects were *C pneumoniae* positive, whereas only a proportion or none from other subjects was positive. However, this is a spurious observation because examination of multiple sections of long segments of vessels would be required to make valid comparisons of positivity between vessels and between subjects. In reality, unlike the large amount of abdominal aortic tissue that may be obtained at the time of aneurysm repair,⁹ only thin slivers of ascending aorta were available for examination in our study. Despite this, a considerable proportion showed atheromatous changes histologically, of which two thirds were *C pneumoniae* positive by the PCR.

"Arteries that showed no signs of atheroma histologically were never *C pneumoniae* positive"

Take home messages

- *Chlamydia pneumoniae* is often present in diseased areas of arteries and veins, although it is not present in apparently healthy areas of either type of vessel
- Vessels used for bypass surgery, whether internal mammary artery or saphenous vein or both, are often *C pneumoniae* positive
- It is possible that those subjects who fail bypass surgery earliest are those who have been grafted with *C pneumoniae* positive vessels

Internal mammary artery specimens were examined by Wong *et al*,¹⁰ who found that two of five of these arteries that were being used for the first time in coronary artery bypass surgery were *C pneumoniae* positive by a PCR assay, and that four of 15 that were old grafts were positive also. Overall, 30% of the arteries were positive. Despite internal mammary arteries being favoured for coronary artery bypass surgery, about 60% of the specimens we examined showed atheromatous changes. Of all the internal mammary artery specimens, about a third were *C pneumoniae* positive, but of those that showed atheromatous changes just over a half were *C pneumoniae* positive. Arteries that showed no signs of atheroma histologically were never *C pneumoniae* positive. Our overall results are an endorsement of *C pneumoniae* being associated strongly with atheromatous lesions in arteries.

Wong *et al* found that 12% of saphenous vein specimens before grafting were *C pneumoniae* positive, whereas 38% of failed grafts were positive.¹⁰ Surprisingly, we found that, although no long saphenous vein specimen had an atheromatous appearance, more than a third of such specimens before grafting had evidence of disease in the form of focal chronic inflammatory cell infiltration. About a quarter of all the vein specimens were *C pneumoniae* positive but almost three quarters of the diseased specimens were *C pneumoniae* positive. A similar proportion of failed grafts were *C pneumoniae* positive also. In contrast, no specimen that was apparently infiltrate free histologically was *C pneumoniae* positive. Intimal fibrosis was also seen in veins, but is considered a "normal" age related change.¹⁴ The significance of the association of *C pneumoniae* with inflammatory lesions in veins, particularly in those before grafting, is unclear. Perhaps *C pneumoniae* positive lymphocytes (see below) are attracted to areas of inflammation that, for unknown reasons, already exist. On the other hand, there would certainly seem to be no a priori reason why *C pneumoniae* should not produce a vasculitis in these vessels, possibly as a consequence of reinfection, as suggested for other vasculitides.¹⁵ Interestingly, *C pneumoniae* IgG antibody titres of 256 or greater have been associated with deep vein thrombosis,¹⁶ although the association has been questioned.¹⁷ Nevertheless, the idea that *C pneumoniae* in veins might produce lesions, which sometimes aid thrombosis, is sufficiently plausible to deserve further consideration.

We assume that the source of *C pneumoniae* in the lesions (whether of arteries or veins) is *C pneumoniae* positive peripheral blood monocytes,¹⁸ which must have easy access to the lesions. It is interesting that internal mammary arteries are used for coronary artery bypass surgery because of their anatomical location and because they are considered to be relatively atheroma free. Of course, the same may be said in terms of disease for saphenous veins. Nevertheless, our results indicate that vessels used for bypass surgery, whether internal mammary artery or saphenous vein or both, are often *C pneumoniae* positive. This raises the intriguing question of whether those subjects who fail bypass surgery earliest are those who have been grafted with *C pneumoniae* positive vessels, a question based, of course, on the so far unconfirmed notion that *C pneumoniae* has a role in the development of atheromatous changes or atheromatous-like changes in veins.

.....

Authors' affiliations

D Taylor-Robinson, B J Thomas, Department of Genitourinary Medicine, Imperial College School of Medicine, St Mary's Campus, Paddington, London, UK

R Goldin, Department of Histopathology, Imperial College School of Medicine

R Stanbridge, Department of Cardiovascular Surgery, St Mary's Hospital, Paddington, London W2 1NY, UK

REFERENCES

- 1 **Grayston JT**. Infections caused by Chlamydia pneumoniae strain TWAR. *Clin Infect Dis* 1992;**15**:757-63.
- 2 **Saikku P**, Leinonen M, Mattila K, *et al*. Serological evidence of an association of a novel Chlamydia, TWAR, with chronic coronary heart disease and acute myocardial infarction. *Lancet* 1988;ii:983-6.
- 3 **Wald NJ**, Law MR, Morris JK, *et al*. Chlamydia pneumoniae infection and mortality from ischaemic heart disease: a large prospective study. *BMJ* 2000;**321**:204-7.
- 4 **Danesh J**, Whincup P, Walker M, *et al*. Chlamydia pneumoniae IgG titres and coronary heart disease: prospective study and meta-analysis. *BMJ* 2000;**321**:208-12.
- 5 **Taylor-Robinson D**. Chlamydia pneumoniae and ischaemic heart disease. Electronic response to: Chlamydia pneumoniae infection and mortality from ischaemic heart disease: a large prospective study. *Bmj.com* 2000;**321** www.bmj.com/cgi/content/short/321/7255/204#responses (accessed 18 December 2001).
- 6 **Shor A**, Kuo C-C, Patton DL. Detection of Chlamydia pneumoniae in coronary arterial fatty streaks and atheromatous plaques. *S Afr Med J* 1992;**82**:158-61.
- 7 **Taylor-Robinson D**, Thomas BJ. Chlamydia pneumoniae in atherosclerotic tissue. *J Infect Dis* 2000;**181**(suppl 3):437-40.
- 8 **Morré SA**, Stoker W, Lagrand WK, *et al*. Microorganisms in the aetiology of atherosclerosis. *J Clin Pathol* 2000;**53**:647-54.
- 9 **Ong G**, Thomas BJ, Mansfield AO, *et al*. Detection and widespread distribution of Chlamydia pneumoniae in the vascular system and its possible implications. *J Clin Pathol* 1996;**49**:102-6.
- 10 **Wong Y**, Thomas M, Tsang V, *et al*. The prevalence of Chlamydia pneumoniae in atherosclerotic and nonatherosclerotic blood vessels of patients attending for redo and first time coronary artery bypass graft surgery. *J Am Coll Cardiol* 1999;**33**:152-6.
- 11 **Shor A**, Phillips JI, Ong G, *et al*. Chlamydia pneumoniae in atheroma: consideration of criteria for causality. *J Clin Pathol* 1998;**51**:812-17.
- 12 **Taylor-Robinson D**, Thomas BJ. Chlamydia pneumoniae in arteries: the facts, their interpretation, and future studies. *J Clin Pathol* 1998;**51**:793-7.
- 13 **Wong Y-k**, Dawkins KD, Ward ME. Circulating Chlamydia pneumoniae DNA as a predictor of coronary artery disease. *J Am Coll Cardiol* 1999;**34**:1435-9.
- 14 **Milroy CM**, Scott DJA, Beard JD, *et al*. Histological appearance of the long saphenous vein. *J Pathol* 1989;**159**:311-16.
- 15 **Ljungström L**, Franzén C, Schlaug M, *et al*. Reinfection with Chlamydia pneumoniae may induce isolated and systemic vasculitis in small and larger vessels. *Scand J Infect Dis* 1997;**104**(suppl):37-40.
- 16 **Loziquez O**, Arnaud E, Belec L, *et al*. Demonstration of an association between Chlamydia pneumoniae infection and venous thromboembolic disease. *Thromb Haemostat* 2000;**83**:887-91.
- 17 **Koster T**, Rosendaal FR, Lieuw-A-Len DD, *et al*. Chlamydia pneumoniae IgG seropositivity and risk of deep-vein thrombosis. *Lancet* 2000;**355**:1694-5.
- 18 **Boman J**, Söderberg S, Forsberg J, *et al*. High prevalence of Chlamydia pneumoniae DNA in peripheral blood mononuclear cells in patients with cardiovascular disease and in middle-aged blood donors. *J Infect Dis* 1998;**178**:274-7.



Find out what's in the latest issue
the moment it's published

Email Alerts

Sign up to receive the table of contents by email every month. You can select from three alerts: Table of Contents (full), TOC Awareness (notice only); *Journal of Clinical Pathology* related announcements.

www.jclinpath.com



***Chlamydia pneumoniae* in infrequently examined blood vessels**

D Taylor-Robinson, B J Thomas, R Goldin, et al.

J Clin Pathol 2002 55: 218-220

doi:

Updated information and services can be found at:

<http://jcp.bmj.com/content/55/3/218.full.html>

References

These include:

This article cites 16 articles, 9 of which can be accessed free at:

<http://jcp.bmj.com/content/55/3/218.full.html#ref-list-1>

Article cited in:

<http://jcp.bmj.com/content/55/3/218.full.html#related-urls>

Email alerting service

Receive free email alerts when new articles cite this article. Sign up in the box at the top right corner of the online article.

Topic Collections

Articles on similar topics can be found in the following collections

[Sexual transmitted infections \(bacterial\)](#) (23 articles)

Notes

To request permissions go to:

<http://group.bmj.com/group/rights-licensing/permissions>

To order reprints go to:

<http://journals.bmj.com/cgi/reprintform>

To subscribe to BMJ go to:

<http://group.bmj.com/subscribe/>