

ORIGINAL ARTICLE

Thrombospondin 1 protein expression relates to good prognostic indices in ductal carcinoma in situ of the breast

A J Rice, M A Steward, C M Quinn

J Clin Pathol 2002;**55**:921–925

Aim: Angiogenesis plays an important role in tumour growth and has been shown to occur around both in situ and invasive tumours. The degree of angiogenesis within tumours depends on the balance of pro-angiogenic and anti-angiogenic factors. One such anti-angiogenic factor is thrombospondin 1 (TSP-1). This study investigates the pattern of expression of TSP-1 in ductal carcinoma in situ (DCIS) of the breast and its relation to the surrounding microvessel pattern and density.

Materials/Methods: The expression of TSP-1 was studied in formalin fixed, paraffin wax embedded sections from 58 cases of pure DCIS, using a monoclonal antibody against TSP-1 and the avidin–biotin–diaminobenzidine immunoperoxidase detection system. Vessels were stained with a monoclonal antibody to the endothelial cell marker CD31. Stromal microvessel density was assessed by counting “hot spots” within 500 µm of the basement membrane of involved ducts using a 25 point Chalkey graticule.

Results: TSP-1 staining of the basement membrane around duct spaces with DCIS was seen in 69% of cases. In addition, staining of the stroma between involved duct spaces was seen in 31% of cases, with a fibrillary pattern identical to that seen in invasive breast carcinomas. In 12% of cases no staining for TSP-1 was seen. Two patterns of vascularity were identified. A cuff of vessels immediately adjacent to the basement membrane of ducts with DCIS was seen in 71% of cases. The presence of stromal TSP-1 was significantly associated with DCIS showing no/little necrosis ($p = 0.01$) and no/little periductal inflammation ($p = 0.04$). There was a trend between the presence of stromal TSP-1 and tumour cell negativity for p53 ($p = 0.087$). The stromal microvessel Chalkey point count ranged between 3.33 and 16. An increased stromal microvessel count was associated with high histological grade ($p = 0.02$), extensive necrosis ($p = 0.047$), and pronounced periductal inflammation ($p = 0.049$). There was no association between the presence of stromal TSP-1 and stromal microvessel density.

Conclusions: TSP-1 is expressed in the stroma around DCIS and in the immediately adjacent basement membrane. Expression of stromal TSP-1 is lost in DCIS with more aggressive histological features. The absence of a relation with microvessel density suggests that other angiogenic factors may play an important role in DCIS.

See end of article for authors' affiliations

Correspondence to:
Dr A Rice, Department of
Histopathology, Royal
Brompton Hospital, Sydney
Street, London, SW3 6NP,
UK; ricealex@hotmail.com

Accepted for publication
9 May 2002

Angiogenesis, the formation of new blood vessels, is known to play an important role in tumour progression by facilitating the growth and dissemination of invasive tumours.^{1,2} Recent studies suggest that the angiogenic phenotype may be acquired early in tumour development and that in situ lesions show increased angiogenic activity.^{3,9} The development of new blood vessels within a tumour depends upon the local balance between angiogenic and anti-angiogenic factors. These factors may be produced by the tumour cells themselves or by associated stromal and inflammatory cells.¹⁰

“Studies of invasive tumours have demonstrated TSP-1 in the tumour stroma and have reported an inverse correlation between the presence of TSP-1 and tumour angiogenesis, as assessed by microvessel density”

Thrombospondin 1 (TSP-1) was the first naturally occurring inhibitor of angiogenesis identified. It is a 420 kDa trimeric glycoprotein, and is one of a family of related proteins including TSP-2, TSP-3, TSP-4, and TSP-5. TSP-1 is present in the extracellular matrix of many normal tissues and is produced by a variety of cells including macrophages, fibroblasts, and endothelial cells. TSP-1 protein expression is upregulated by growth factors such as platelet derived growth factor, transforming growth factor β (TGF-β), and basic fibroblast

growth factor (bFGF), and by wild-type p53. Loss of normal p53 activity is associated with the loss of TSP-1 expression. Studies of invasive tumours have demonstrated TSP-1 in the tumour stroma and have reported an inverse correlation between the presence of TSP-1 and tumour angiogenesis, as assessed by microvessel density.^{11–14} Breast cancer studies have also localised TSP-1 to the basement membrane of benign breast ducts showing fibrocystic change and ducts involved by ductal carcinoma in situ (DCIS), and to the stroma around invasive ductal carcinoma.^{15–17}

Two patterns of angiogenesis have been described in DCIS^{8,18–20}—a cuff of microvessels lying immediately adjacent to the basement membrane of involved ducts, and an increase in the number of microvessels in the stroma surrounding involved ducts. An increase in stromal microvessels has been associated with high grade DCIS¹⁹ and comedo necrosis.⁸ Previous studies have investigated the relation between inflammation²⁰ and the expression of angiogenic factors, such

Abbreviations: bFGF, basic fibroblast growth factor; DCIS, ductal carcinoma in situ; Hif-1α, hypoxia inducible factor 1α; TBS, Tris buffered saline; TGF-β, transforming growth factor β; TSP-1, thrombospondin 1; VEGF, vascular endothelial growth factor

as vascular endothelial growth factor (VEGF)^{21–23} and thymidine phosphorylase,^{23–25} and new vessel formation in DCIS. To date, there are no data on the role of anti-angiogenic factors in angiogenesis in DCIS.

The aims of our study were: (1) to study the patterns of TSP-1 protein expression in a series of 58 cases of pure DCIS with particular emphasis on stromal staining, (2) to study the relation between stromal TSP-1 expression and angiogenesis (assessed immunohistochemically) in DCIS, and (3) to evaluate the relation between stromal TSP-1 expression and other biological parameters of DCIS including histological grade, necrosis, periductal inflammation, and aberrant p53 expression.

MATERIALS AND METHODS

Study group

Our study group comprised 58 patients with pure DCIS. All patients were diagnosed and treated at the General Infirmary at Leeds between 1984 and 1996 and were identified using the SNOMED diagnostic retrieval system. The age at presentation ranged from 28 to 81 years (median, 58). Eleven women were premenopausal and 47 were postmenopausal. Thirty five patients were symptomatic and in 23 DCIS was detected by mammography. All patients were treated surgically by wide local excision or mastectomy. This study group was part of a larger series of patients with DCIS in whom the results of p53 and bcl-2 studies were reported previously.²⁶

DCIS characteristics

DCIS was graded as low (seven), intermediate (12), or high grade (39) according to the criteria of Holland *et al.*²⁷ In view of discrepancies over the definition of comedo,²⁸ necrosis was scored as absent (14), focal (15), or extensive (29). Periductal inflammation was absent (nine), mild (23), or pronounced (26).

p53 characteristics

In an earlier study,²⁶ p53 status was determined immunohistochemically on formalin fixed, paraffin wax embedded tissue using p53 specific antibody from Biomen Ltd, Finchampstead, UK. Each case was assessed independently by two observers. Cases were considered positive when at least 10% of the cells showed clear cut positive staining. Thirteen patients had p53 positive DCIS, 44 had p53 negative DCIS, and in one patient p53 data were not available.

TSP-1 and CD31 immunohistochemical studies

Immunohistochemistry was performed on formalin fixed, paraffin wax embedded tissue using the streptavidin–biotin–peroxidase complex (ABC) method. Sections (5 µm thick) were cut, dewaxed in xylene, and hydrated in graded alcohols. Endogenous peroxidase activity was blocked by incubation with 1% hydrogen peroxide in methanol for 30 minutes followed by rinsing in Tris buffered saline (TBS). Non-specific staining was blocked by incubation with normal goat serum (1/5 dilution) for five minutes. Immunostaining for CD31 was performed using a monoclonal antibody (clone JC70; Dako, Ely, Cambridgeshire, UK), at a 1/20 dilution, following predigestion with trypsin. TSP-1 expression was demonstrated using a mouse monoclonal antibody (clone A6.1; Neomarkers, California, USA), at a 1/30 dilution, after predigestion with pronase E. Sections were then incubated sequentially with a biotinylated antimouse/antirabbit antibody at a dilution of 1/100 for 30 minutes, and streptavidin–biotin complex–horseradish peroxidase for 30 minutes. Between each incubation slides were rinsed with TBS. A solution of 3,3'-diaminobenzidine tetrahydrochloride was used as chromogen in the presence of hydrogen peroxide and slides were stained with haematoxylin.

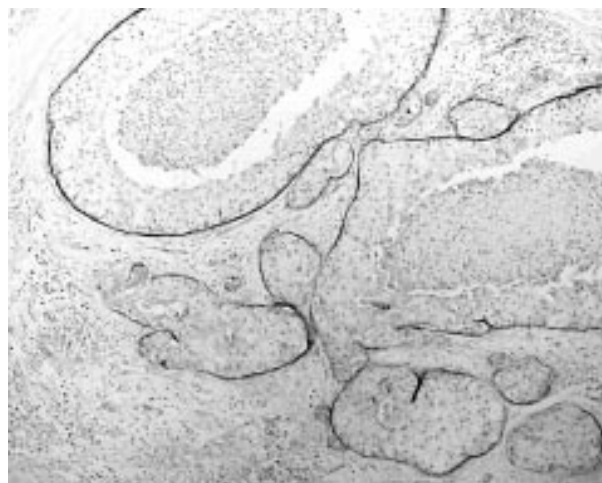


Figure 1 Basement membrane staining for thrombospondin 1 (TSP-1) (immunostain for TSP-1).

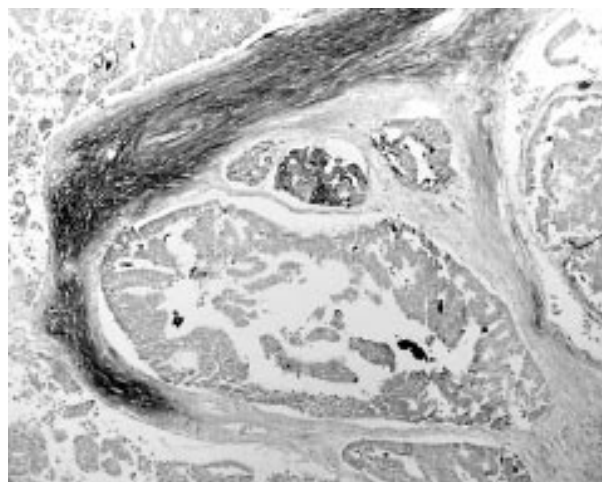


Figure 2 Stromal staining for thrombospondin 1 (TSP-1) (immunostain for TSP-1).

Immunohistochemistry for TSP-1 in the positive control (invasive ductal carcinoma of breast) showed fine fibrillary staining of the desmoplastic stroma as described. Normal identifiable vessels within the sections provided an internal control for CD31.

Negative controls were performed by replacing the primary antibody with TBS.

Staining for p53 had been performed and quantified previously.²⁶

Assessment of TSP-1 staining

Two patterns of TSP-1 staining were identified: staining of the basement membrane of ducts affected by DCIS (fig 1) and fibrillary staining of the stroma around and between involved ducts (fig 2). Staining was assessed by two observers (AR, MS) over a conference microscope as follows: no staining identified; basement membrane staining of involved ducts only; staining of basement membrane and stroma; stromal staining only.

Assessment of vascularity

Microvessels were defined as CD31 positive endothelial cells or endothelial cell aggregates with or without discrete lumina. Vessels with muscular walls were excluded. Sections were examined by two observers (AR, MS) simultaneously over a conference microscope.

A cuff of microvessels was scored as present if a minimum of one duct with DCIS was completely surrounded by a dense rim of microvessels, or if more than one duct with DCIS was at least 50% surrounded by microvessels.⁸

Stromal vascularity was quantified using the Chalkey point counting method to assess the three most vascular areas, "hot spots", within a 500 µm radius of ducts containing DCIS. The 25 point eyepiece graticule was orientated, at ×250 magnification, such that the maximum number of points were on or within areas of stained vessels. The mean of the three "hot spot" counts was used for statistical analysis.

Statistics

The χ^2 and exact Fisher tests were used to examine the relation between categorical features and the Mann Whitney U to examine the relation between categorical and quantitative features; p values of less than 0.05 were considered significant.

RESULTS

TSP-1 staining in DCIS

TSP-1 staining was seen in the basement membrane of involved duct spaces in 40 of 58 cases (fig 1), a pattern previously described using immunohistochemistry, electron microscopy, and in situ hybridisation.^{15-17 29-31} TSP-1 expression was identified in the stroma around and between involved duct spaces in 18 of 58 cases (fig 2). This constituted the typical fine fibrillary stromal staining described in invasive ductal carcinoma and other tumours.¹⁷ Both patterns were noted in seven of 58 cases. In seven of 58 cases no staining for TSP-1 was seen.

Patterns of vascularity in DCIS

Two patterns of vascularity in DCIS were seen, as described previously; a cuff of vessels immediately adjacent to the basement membrane of ducts involved by DCIS was observed in 41 of 58 cases. Stromal microvessels were seen in all 58 cases, with the Chalkey point count ranging from 3.33 to 16.00.

Comparison of TSP-1 staining with vascularity

There was no relation between basement membrane or stromal TSP-1 staining and the presence of either a cuff of vessels or increased stromal microvessel density in DCIS.

Comparison of TSP-1 staining with histological grade, necrosis, periductal inflammation, and p53 expression in DCIS (table 1)

Stromal TSP-1 staining was seen in one of seven cases of low grade, eight of 12 intermediate grade, and nine of 39 cases of high grade DCIS. Stromal TSP-1 staining was therefore present in nine of 19 cases of low and intermediate grade DCIS compared with nine of 39 cases of high grade DCIS ($\chi^2 = 2.478$; p = 0.1154).

Table 1 Stromal thrombospondin 1 (TSP-1) expression according to histological features and p53

DCIS characteristics	Stromal TSP-1	p Value
Histological grade		
Low/intermediate	9/19 (47%)	0.1154 (NS)
High	9/39 (23%)	
Necrosis		
None/focal	14/29 (48%)	0.0106
Extensive	4/29 (14%)	
Periductal inflammation		
None/mild	14/32 (44%)	0.0417
Pronounced	4/26 (15%)	
p53		
Negative	16/44 (36%)	0.0874 (NS)
Positive	1/13 (8%)	

Stromal TSP-1 staining was present in seven of 14 cases with no necrosis, seven of 15 with focal necrosis, and four of 29 with extensive necrosis. Therefore, stromal TSP-1 staining was present in significantly more cases of DCIS with no/focal necrosis compared with cases with extensive necrosis ($\chi^2 = 6.525$; p = 0.0106).

Stromal TSP-1 staining was present in five of nine DCIS cases with no periductal inflammation, nine of 23 with mild periductal inflammation, and four of 26 with pronounced periductal inflammation. Therefore, stromal TSP-1 staining was present in significantly more DCIS cases with no/mild periductal inflammation compared with those showing pronounced periductal inflammation ($\chi^2 = 4.15$; p = 0.0417).

Stromal TSP-1 staining was present in one of 13 p53 positive cases compared with 16 of 44 p53 negative cases (Fisher exact probability; p = 0.0874).

Relation between vascularity and DCIS characteristics

Increased stromal microvessel density was seen in association with high histological grade (Mann Whitney U; p = 0.0205), extensive necrosis (Mann Whitney U; p = 0.0047), and pronounced periductal inflammation (Mann Whitney U; p = 0.049).

A cuff of vessels was present in 41 of 58 cases. The presence of a cuff of vessels was unrelated to the histological grade of DCIS, the extent of necrosis, or the presence of periductal inflammation.

DISCUSSION

The presence of TSP-1 protein in the basement membrane of ducts involved by DCIS was confirmed in our study, and was seen in 69% of cases of pure DCIS. The myoepithelial cell population around ducts involved by DCIS has been proposed as a likely source of TSP-1 protein at this site.^{15 30} We found no association between basement membrane TSP-1 staining in DCIS and the presence of a cuff of vessels, stromal vascularity, or DCIS biological parameters. This suggests that other angiogenic factors, such as thymidine phosphorylase, may be more important in the acquisition of a cuff of vessels.²⁴ The restricted location of basement membrane TSP-1 may account for the absence of an association with stromal vascularity. The presence of TSP-1 protein in the basement membrane of ducts with fibrocystic change also raises the possibility that basement membrane TSP-1 merely represents a non-specific reaction to duct pathology.^{15 16}

TSP-1 protein was also detected in the stroma around and between DCIS ducts, with a pattern of staining identical to that described in the stroma of invasive breast carcinomas. This is a new finding and is supported by recent work showing TSP-1 mRNA expression in DCIS stroma,³⁰ which was localised to stromal cells adjacent to the DCIS, although the nature of these cells was not elucidated. The absence of an association between stromal TSP-1 and periductal inflammation in our present study suggests that inflammatory cells are not the main source of TSP-1. Stromal TSP-1 expression has not been reported in normal or benign breast tissue, suggesting that its presence is elicited in response to the presence of DCIS, possibly secondary to a factor produced by the DCIS cells, rather than representing a non-specific response to duct pathology. In our study, stromal TSP-1 expression was associated with p53 negative DCIS of low or intermediate nuclear grade and was significantly associated with DCIS showing no/little necrosis and no/little periductal inflammation. Stromal TSP-1 is reduced or lost around DCIS with the aggressive biological characteristics of aberrant p53 expression, high histological grade, and necrosis. Loss of TSP-1 expression may be a factor in facilitating the transition to invasive carcinoma in this higher risk group.

Two patterns of vascularity in DCIS were observed. In agreement with previous studies, a higher stromal microvessel

density was seen in association with high histological grade,¹⁹ comedo necrosis,²² and the presence of periductal inflammation.²⁰ A cuff of vessels was seen in 71% of cases. This incidence is higher than previously reported, possibly reflecting the greater sensitivity of CD31 compared with factor VIII as a marker of endothelial cells.^{32, 33} As in previous studies,^{8, 20} there was no association between the presence of a cuff of vessels and biological parameters, such as grade and necrosis.

"The absence of an association between stromal TSP-1 and periductal inflammation in our present study suggests that inflammatory cells are not the main source of TSP-1"

Our group previously reported an inverse correlation between stromal TSP-1 expression and microvessel density in invasive ductal carcinoma of the breast,³⁴ consistent with the proposed anti-angiogenic properties of TSP-1. In our present DCIS study, no relation was seen between stromal TSP-1 staining and microvessel density. TSP-1 is a single element in the angiogenesis process that depends on the interplay between pro-angiogenic and anti-angiogenic factors. DCIS tumour cells produce VEGF and thymidine phosphorylase (platelet derived endothelial cell growth factor), molecules that are associated with increased stromal microvessels²² and the presence of a cuff of vessels,²⁴ respectively. Thymidine phosphorylase is also expressed by stromal cells around DCIS, and is associated with stromal microvessel density.²⁵ VEGF expression is regulated by hypoxia inducible factor 1 α (Hif-1 α). Hif-1 α expression is increased in DCIS and positively associated with both VEGF expression and intratumoral microvessel density.³⁵ It is possible that the anti-angiogenic effects of stromal TSP-1 are suppressed in DCIS producing high concentrations of pro-angiogenic factors.

The TSP-1 molecule has multiple functional domains and appears to have a complex role in angiogenesis. The N-terminal end of the molecule bears a heparin binding domain, which can prevent bFGF and other heparin dependent growth factors from binding heparin, thereby inhibiting their angiogenic activity.^{36, 37} The type III repeat domain contains an integrin binding site, which mediates adhesion of TSP-1 to cells expressing the integrin $\alpha\beta 3$,³⁸ possibly modulating the influence of this integrin on angiogenesis.³⁹ The type I repeat activates latent TGF- β ,⁴⁰ which has both pro-angiogenic and anti-angiogenic effects. Endothelial cells are stimulated by TSP-1 to release increased amounts of plasminogen activator inhibitor 1, thereby regulating enzyme mediated endothelial cell invasion, which is essential in the sprouting of new vessels.⁴¹ Cell transfection studies have demonstrated a TSP-1 anti-angiogenic effect in melanoma cells⁴² and an angiogenic effect in squamous cell carcinoma. The effect of TSP-1 on vessel growth also depends on concentration⁴³ and on whether it is in soluble or substrate form.⁴⁴

The cumulative evidence suggests that the angiogenic switch occurs in high grade DCIS and that factors such as VEGF, thymidine phosphorylase, or periductal inflammation play the dominant role in controlling angiogenesis. The role of TSP-1 in DCIS angiogenesis may be permissive or dependent on local variables, such as TSP-1 concentration, TGF- β concentrations, and the nature of the extracellular matrix.

In conclusion, we report a new pattern of TSP-1 protein expression in DCIS. Although there was no clear association between this pattern of stromal TSP-1 expression and DCIS vascularity, expression was correlated with markers of better DCIS differentiation and features associated with a lower likelihood of progression to invasive carcinoma.

ACKNOWLEDGEMENT

This work was carried out in the department of histopathology at the Leeds General Infirmary.

Take home messages

- We report a new pattern of thrombospondin 1 (TSP-1) protein expression in the stroma around ductal carcinoma in situ (DCIS) of the breast
- This stromal TSP-1 expression was associated with p53 negative DCIS of low or intermediate nuclear grade and was significantly associated with DCIS showing no/little necrosis and no/little periductal inflammation
- Stromal TSP-1 is reduced or lost around DCIS with the aggressive biological characteristics of aberrant p53 expression, high histological grade, and necrosis
- Thus, loss of TSP-1 expression may be a factor in facilitating the transition to invasive carcinoma in this higher risk group
- However, the lack of a relation between TSP-1 expression and microvessel density suggests that other angiogenic factors may play important roles in DCIS

Authors' affiliations

A J Rice, Department of Histopathology, Royal Brompton Hospital, Sydney Street, London, SW3 6NP, UK

M A Steward, Department of Surgery, Christie Hospital, Wilmslow Road, Withington, Manchester M20 9BX, UK

C M Quinn, Irish National Screening Programme and Department of Histopathology, St Vincent's University Hospital, Elm Park, Dublin 4, Ireland

REFERENCES

- 1 Folkman J. Angiogenesis research: from laboratory to clinic. *Forum (Genova)* 1999;**9**:59-62.
- 2 Carmeliet P, Jain RK. Angiogenesis in cancer and other diseases. *Nature* 2000;**407**:249-57.
- 3 Bancher-Todesca D, Obermair A, Bilgi S, et al. Angiogenesis in vulvar intraepithelial neoplasia. *Gynecol Oncol* 1997;**64**:496-500.
- 4 Chodak GW, Haudenschild C, Gittes RF, et al. Angiogenic activity as a marker of neoplastic and preneoplastic lesions of the human bladder. *Ann Surg* 1980;**192**:762-71.
- 5 Fontanini G, Vignati S, Bigini D, et al. Neoangiogenesis: a putative marker of malignancy in non-small-cell lung cancer (NSCLC) development. *Int J Cancer* 1996;**67**:615-19.
- 6 Obermair A, Bancher-Todesca D, Bilgi S, et al. Correlation of vascular endothelial growth factor expression and microvessel density in cervical intraepithelial neoplasia. *J Natl Cancer Inst* 1997;**89**:1212-17.
- 7 Pazouki S, Chisholm DM, Adi MM, et al. The association between tumour progression and vascularity in the oral mucosa. *J Pathol* 1997;**183**:39-43.
- 8 Guidi AJ, Fischer L, Harris JR, et al. Microvessel density and distribution in ductal carcinoma in situ of the breast. *J Natl Cancer Inst* 1994;**86**:614-19.
- 9 Weidner N, Folkman J, Pozza F, et al. Tumor angiogenesis: a new significant and independent prognostic indicator in early-stage breast carcinoma. *J Natl Cancer Inst* 1992;**84**:1875-87.
- 10 Rice A J, Quinn CM. Angiogenesis and ductal carcinoma in situ of the breast. *J Clin Pathol* 2002;**55**:569-74.
- 11 Campbell SC, Volpert OV, Ivanovich M, et al. Molecular mediators of angiogenesis in bladder cancer. *Cancer Res* 1998;**58**:1298-304.
- 12 Grant SW, Kyshoobayeva AS, Kurosaki T, et al. Mutant p53 correlates with reduced expression of thrombospondin-1, increased angiogenesis, and metastatic progression in melanoma. *Cancer Detect Prev* 1998;**22**:185-94.
- 13 Kawahara N, Ono M, Taguchi K, et al. Enhanced expression of thrombospondin-1 and hypovascularity in human cholangiocarcinoma. *Hepatology* 1998;**28**:1512-17.
- 14 Volm M, Koomagi R, Mattern J. Angiogenesis and cigarette smoking in squamous cell lung carcinomas: an immunohistochemical study of 28 cases. *Anticancer Res* 1999;**19**:333-6.
- 15 Clezardin P, Frappart L, Clerget M, et al. Expression of thrombospondin (TSP1) and its receptors (CD36 and CD51) in normal, hyperplastic, and neoplastic human breast. *Cancer Res* 1993;**53**:1421-30.
- 16 Tuszyński GP, Nicosia RF. Localization of thrombospondin and its cysteine-serine-valine-threonine-cysteine-glycine-specific receptor in human breast carcinoma. *Lab Invest* 1994;**70**:228-33.
- 17 Wong SY, Purdie AT, Han P. Thrombospondin and other possible related matrix proteins in malignant and benign breast disease. An immunohistochemical study. *Am J Pathol* 1992;**140**:1473-82.
- 18 Weidner N, Semple JP, Welch WR, et al. Tumor angiogenesis and metastasis—correlation in invasive breast carcinoma. *N Engl J Med* 1991;**324**:1-8.
- 19 Engels K, Fox SB, Whitehouse RM, et al. Distinct angiogenic patterns are associated with high-grade in situ ductal carcinomas of the breast. *J Pathol* 1997;**181**:207-12.

- 20 Lee AH, Happerfield LC, Bobrow LG, *et al.* Angiogenesis and inflammation in ductal carcinoma in situ of the breast. *J Pathol* 1997;**181**:200–6.
- 21 Brown LF, Berse B, Jackman RW, *et al.* Expression of vascular permeability factor (vascular endothelial growth factor) and its receptors in breast cancer. *Hum Pathol* 1995;**26**:86–91.
- 22 Guidi AJ, Schnitt SJ, Fischer L, *et al.* Vascular permeability factor (vascular endothelial growth factor) expression and angiogenesis in patients with ductal carcinoma in situ of the breast. *Cancer* 1997;**80**:1945–53.
- 23 Heffelfinger SC, Miller MA, Yassin R, *et al.* Angiogenic growth factors in preinvasive breast disease. *Clin Cancer Res* 1999;**5**:2867–76.
- 24 Engels K, Fox SB, Whitehouse RM, *et al.* Up-regulation of thymidine phosphorylase expression is associated with a discrete pattern of angiogenesis in ductal carcinomas in situ of the breast. *J Pathol* 1997;**182**:414–20.
- 25 Lee AH, Dublin EA, Bobrow LG. Angiogenesis and expression of thymidine phosphorylase by inflammatory and carcinoma cells in ductal carcinoma in situ of the breast. *J Pathol* 1999;**187**:285–90.
- 26 Quinn CM, Ostrowski JL, Harkins L, *et al.* Loss of bcl-2 expression in ductal carcinoma in situ of the breast relates to poor histological differentiation and to expression of p53 and c-erbB-2 proteins. *Histopathology* 1998;**33**:531–6.
- 27 Holland R, Peterse JL, Millis RR, *et al.* Ductal carcinoma in situ: a proposal for a new classification. *Semin Diagn Pathol* 1994;**11**:167–80.
- 28 Bobrow LG, Happerfield LC, Gregory WM, *et al.* Ductal carcinoma in situ: assessment of necrosis and nuclear morphology and their association with biological markers. *J Pathol* 1995;**176**:333–41.
- 29 Bertin N, Clezardin P, Kubiak R, *et al.* Thrombospondin-1 and -2 messenger RNA expression in normal, benign, and neoplastic human breast tissues: correlation with prognostic factors, tumor angiogenesis, and fibroblastic desmoplasia. *Cancer Res* 1997;**57**:396–9.
- 30 Brown LF, Guidi AJ, Schnitt SJ, *et al.* Vascular stroma formation in carcinoma in situ, invasive carcinoma, and metastatic carcinoma of the breast. *Clin Cancer Res* 1999;**5**:1041–56.
- 31 Serre CM, Clezardin P, Frappart L, *et al.* Distribution of thrombospondin and integrin alpha V in DCIS, invasive ductal and lobular human breast carcinomas. Analysis by electron microscopy. *Virchows Arch* 1995;**427**:365–72.
- 32 Gasparini G, Weidner N, Bevilacqua P, *et al.* Tumor microvessel density, p53 expression, tumor size, and peritumoral lymphatic vessel invasion are relevant prognostic markers in node-negative breast carcinoma. *J Clin Oncol* 1994;**12**:454–66.
- 33 Horak ER, Leek R, Klenk N, *et al.* Angiogenesis, assessed by platelet/endothelial cell adhesion molecule antibodies, as indicator of node metastases and survival in breast cancer. *Lancet* 1992;**340**:1120–4.
- 34 Steward MA, Rice AJ, Horgan K, *et al.* Thrombospondin-1 in invasive breast cancer and its association with p53 expression, microvessel density and clinical outcome. *J Pathol* 1998;**184**:5A.
- 35 Bos R, Zhong H, Hanrahan CF, *et al.* Levels of hypoxia-inducible factor-1 alpha during breast carcinogenesis. *J Natl Cancer Inst* 2001;**93**:309–14.
- 36 Taraboletti G, Roberts D, Liotta LA, *et al.* Platelet thrombospondin modulates endothelial cell adhesion, motility, and growth: a potential angiogenesis regulatory factor. *J Cell Biol* 1990;**111**:765–72.
- 37 Vogel T, Guo NH, Krutzsch HC, *et al.* Modulation of endothelial cell proliferation, adhesion, and motility by recombinant heparin-binding domain and synthetic peptides from the type I repeats of thrombospondin. *J Cell Biochem* 1993;**53**:74–84.
- 38 Lawler J. The interactions of thrombospondin with integrins. In: Lahav J, ed. *Thrombospondin*. Florida: CRC Press, 1993:275–82.
- 39 Brooks PC, Montgomery AM, Rosenfeld M, *et al.* Integrin alpha v beta 3 antagonists promote tumor regression by inducing apoptosis of angiogenic blood vessels. *Cell* 1994;**79**:1157–64.
- 40 Murphy-Ullrich JE, Schultz-Cherry S, Hook M. Transforming growth factor-beta complexes with thrombospondin. *Mol Biol Cell* 1992;**3**:181–8.
- 41 Sheibani N, Frazier WA. Thrombospondin 1 expression in transformed endothelial cells restores a normal phenotype and suppresses their tumorigenesis. *Proc Natl Acad Sci U S A* 1995;**92**:6788–92.
- 42 Zabrenetzky V, Harris CC, Steeg PS, *et al.* Expression of the extracellular matrix molecule thrombospondin inversely correlates with malignant progression in melanoma, lung and breast carcinoma cell lines. *Int J Cancer* 1994;**59**:191–5.
- 43 Pazouki S, Pendleton N, Heerkens E, *et al.* Biphasic effect of thrombospondin-1 [TSP-1] in the regulation of angiogenesis in human breast carcinoma. *Biochem Soc Trans* 1996;**24**:368S.
- 44 Murphy-Ullrich JE, Hook M. Thrombospondin modulates focal adhesions in endothelial cells. *J Cell Biol* 1989;**109**:1309–19.

ECHO

TGF- β 1 gene shows no link with Alzheimer's



Please visit the Molecular Pathology website [www.molpath.com] for link to this full article.

A study of variation in the gene for transforming growth factor β 1 (TGF- β 1), has failed to confirm a role for this cytokine in the development of Alzheimer's disease. The case-control study looked for association between the disease and three variants in the coding region of the TGF- β 1 gene—one at codon +25 and two in the promoter region at codons –800 and –509.

These variants occurred in a Hardy-Weinberg distribution in the controls. None showed any difference in frequency between the cases and controls, nor were there any allelic differences. Additionally, brain tissue from other patients with Alzheimer's disease showed no differences in amyloid β (A β) content according to TGF- β 1 genotype. These variants also did not affect age of onset of the disease—for the cases or the brain samples.

The study included 678 cases of sporadic Alzheimer's disease and 667 controls, all of European origin, from France. The gene variants were identified by PCR amplification and restriction fragment analysis. Brains from 81 confirmed cases of Alzheimer's disease from Manchester, UK, underwent DNA extraction and genotyping. The proportion of the tissue taken up with A β was estimated from immunohistochemical staining of thin sections.

Research has suggested that cytokines may have a role in Alzheimer's disease, supporting an inflammatory model of pathogenesis. TGF- β 1 in particular looked a promising candidate, possibly triggering the accumulation of A β in the brain, according to molecular and animal studies.

▲ *Journal of Neurology, Neurosurgery, and Psychiatry* 2002;**73**:62–64



Thrombospondin 1 protein expression relates to good prognostic indices in ductal carcinoma in situ of the breast

A J Rice, M A Steward and C M Quinn

J Clin Pathol 2002 55: 921-925
doi: 10.1136/jcp.55.12.921

Updated information and services can be found at:
<http://jcp.bmj.com/content/55/12/921.full.html>

-
- References** *These include:*
This article cites 43 articles, 15 of which can be accessed free at:
<http://jcp.bmj.com/content/55/12/921.full.html#ref-list-1>
- Article cited in:
<http://jcp.bmj.com/content/55/12/921.full.html#related-urls>
- Email alerting service** Receive free email alerts when new articles cite this article. Sign up in the box at the top right corner of the online article.

-
- Topic Collections** Articles on similar topics can be found in the following collections
- [Immunology \(including allergy\)](#) (1279 articles)
 - [Inflammation](#) (129 articles)
 - [Breast cancer](#) (378 articles)

Notes

To request permissions go to:
<http://group.bmj.com/group/rights-licensing/permissions>

To order reprints go to:
<http://journals.bmj.com/cgi/reprintform>

To subscribe to BMJ go to:
<http://group.bmj.com/subscribe/>