

LETTERS TO JCP

Multiple fibroadenomas harbouring carcinoma in situ in a woman with a family history of breast/ovarian cancer

A Kuijper, S S Preisler-Adams, F D Rahusen, J J P Gille, E van der Wall, P J van Diest

J Clin Pathol 2002;55:795-797

A 46 year old woman with a family history of breast and ovarian cancer presented with multiple fibroadenomas in both breasts. From three fibroadenomas removed from the left breast carcinoma in situ (CIS) had developed. One fibroadenoma gave rise to ductal CIS, whereas the other two harboured lobular CIS. This is the first report of three fibroadenomas simultaneously giving rise to CIS. In addition, synchronous fibroadenomas harbouring different types of CIS from one fibroadenoma to the other have never been described. Direct sequencing revealed a mutation (5075G→A) in the BRCA1 gene, but retention of BRCA1 immunohistochemical staining and no loss of heterozygosity at the BRCA1 locus by polymerase chain reaction made a pathogenic mutation in BRCA1 unlikely. Furthermore, in this family no cosegregation of breast cancer with this BRCA1 mutation was seen. Indeed, this mutation is now regarded as a polymorphism. This case stresses the need for histological evaluation of all breast masses in women with a strong positive family history for breast and/or ovarian cancer.

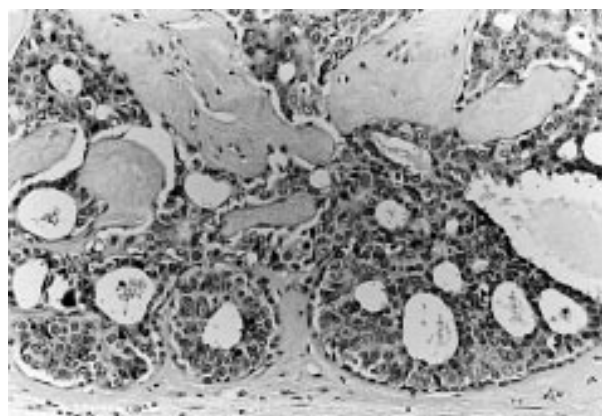


Figure 1 Well differentiated ductal carcinoma in situ in a sclerosed fibroadenoma (haematoxylin and eosin stained; original magnification, $\times 25$).

Fibroadenoma of the breast is relatively frequent. Women can present at any age, but the peak incidence is in the 2nd and 3rd decades.¹ Fibroadenoma is a biphasic tumour, composed of a stromal and an epithelial component. Although generally considered benign there is evidence for an association with an increased risk of invasive breast cancer.²⁻⁴ Dupont *et al* describe a relative risk from 2 to 4, depending on complex histology, hyperplasia in adjacent tissue, and family history.⁵

In addition to being associated with an increased relative risk for invasive breast cancer, fibroadenoma itself can display malignant progression. Epithelial hyperplasia is frequently found in fibroadenomas.⁵ Furthermore, progression of the epithelial component to carcinoma in situ (CIS) and invasive carcinoma has been documented in the literature. Ozello and Gump found an incidence of 0.3% for CIS and invasive carcinoma taken together,⁶ and Buzanowski *et al* found five cases of lobular carcinoma in situ (LCIS) arising within fibroadenoma in a series of 4000 tumours.⁷ This progression is usually found in women over 40 years of age, which is nearly a decade older than those with the usual type of fibroadenoma.⁶⁻⁸ We report a rare finding of three in situ carcinomas (one ductal, two lobular) arising simultaneously within three fibroadenomas.

“Although fibroadenoma is generally considered benign there is evidence for an association with an increased risk of invasive breast cancer”

CASE REPORT

A 46 year old woman, with one first degree family member with breast cancer and one with both breast and ovarian cancer, presented at our hospital with multiple palpable masses in both breasts. Fine needle aspiration of one of the lesions in the left breast was inconclusive, a subsequent core biopsy was

compatible with fibroadenoma. Because of clinical and radiological suspicion, excisional biopsy was performed of both breasts. On pathological examination of the haematoxylin and eosin (H&E) stained sections the breast masses were found to be fibroadenomas. Three fibroadenomas removed from the left breast showed CIS. Well differentiated (low grade) ductal carcinoma in situ (DCIS) (fig 1) had developed from one of the fibroadenomas, whereas the other two had given rise to LCIS (fig 2). Immunohistochemical staining for E-cadherin (clone HECD-1; Zymed Laboratories, San Francisco, California, USA; working dilution, 1/200) was performed to confirm these diagnoses.⁹ As expected, the LCIS samples showed complete loss of E-cadherin expression, which was retained by the DCIS specimen. Two fibroadenomas in the right breast showed no conspicuous changes. Because of the positive family history of breast and ovarian cancer, a suspicion for a BRCA mutation existed. Routine mutation screening (BRCA1: protein truncation test on exon 11; single strand conformation analysis on exons 2, 20, and 24; polymerase chain reaction (PCR) screening for genomic deletions of exon 13 and 22. BRCA2: protein truncation test on exons 10 and 11) did not reveal mutation in the BRCA1 or BRCA2 genes. Because of the multiple fibroadenomas with CIS, the strong positive family history, and our patient's wish, a bilateral mastectomy was performed. Fourteen blocks from the right breast and 21 blocks from the left breast were examined. Apart from foci of usual ductal hyperplasia and fibrocystic changes in both breasts, the H&E sections revealed no other aberrations. No residual CIS was present and no further fibroadenomas were identified. Later,

Abbreviations: CIS, carcinoma in situ; DCIS, ductal carcinoma in situ; H&E, haematoxylin and eosin; LCIS, lobular carcinoma in situ; LOH, loss of heterozygosity; PCR, polymerase chain reaction

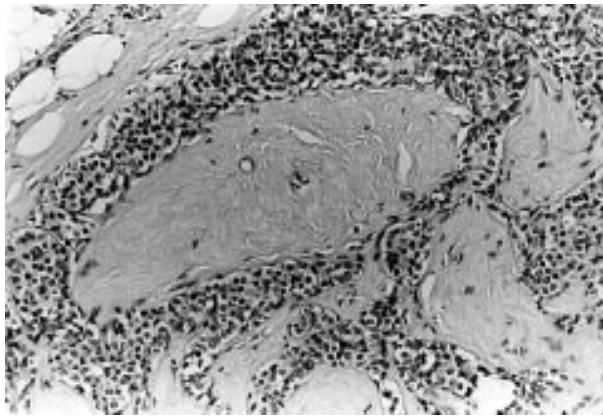


Figure 2 Lobular carcinoma in situ arising within a fibroadenoma (haematoxylin and eosin stained; original magnification, $\times 25$).

by direct sequencing of the full BRCA1 and BRCA2 genes, we found a missense germline mutation in exon 16 of the BRCA1 gene. This mutation, 5075G→A, leads to an amino acid substitution of methionine for isoleucine. The mother of our patient, herself a patient with breast cancer, did not carry this mutation. Expression of the BRCA1 protein in the fibroadenomas was demonstrated by immunohistochemical staining (Ab-1; Oncogene, San Diego, California, USA; working dilution, 1/500). Loss of heterozygosity (LOH) for BRCA1 could not be demonstrated by PCR using three polymorphic markers (D17S855, D17S1323, and D17S1322).

DISCUSSION

To the best of our knowledge this is the first report of three fibroadenomas synchronously giving rise to CIS. In addition, synchronous fibroadenomas harbouring different types of CIS (DCIS or LCIS) from one fibroadenoma to the other have never been described. Complete sequencing of the BRCA1 and BRCA2 genes revealed a BRCA1 mutation. This mutation, 5075G→A in exon 16 was first described by Couch *et al.*¹⁰ Later, Wagner (ASHG 1999, Breast Cancer Linkage Consortium 1999) reported that this mutation is a polymorphism occurring in the Indo-European population with a frequency of about 3%. In the family of our patient, we found no cosegregation of this mutation with breast cancer predisposition, indicating that this mutation is not responsible for the predisposition to breast cancer seen in this family. However, because even complete sequencing does not reveal all mutations and can especially miss larger genomic deletions and promoter mutations, it is still possible that this patient and her family members carry an undetected mutation of one of the BRCA genes. For BRCA1 this was made unlikely by the presence of the BRCA1 protein and by the absence of BRCA1 LOH. However, for BRCA2 we cannot exclude this, and another gene implicated in familial breast/ovarian cancer may also be affected.

“Although malignant transformation of a fibroadenoma is infrequent, the presence of this tumour in a woman with a positive family history may have greater clinical importance than fibroadenomas arising in women with no additional risk factors”

It is not known whether fibroadenomas occur more often in women with a strong family history for breast cancer or a BRCA mutation, or whether these tumours are more prone to malignant transformation. Searching the archives of the department of pathology, Free University Medical Centre, Amsterdam, The Netherlands revealed two more fibroadenomas removed from two women with a BRCA1 mutation. Both these fibroadenomas lacked lesions associated with an

Take home messages

- This is the first report of three fibroadenomas simultaneously giving rise to carcinoma in situ (CIS) and of synchronous fibroadenomas harbouring different types of CIS from one fibroadenoma to the other
- Physicians should be aware of the progression capabilities of breast fibroadenomas, in particular in women with a known BRCA mutation or a strong family history for breast/ovarian cancer
- This case stresses the need for histological evaluation of all breast masses in women with a strong positive family history for breast and/or ovarian cancer

increased relative risk for breast cancer—that is, there were no complex changes or CIS.

There are two reports on the simultaneous occurrence of CIS arising within multiple fibroadenomas. In both reports a patient is described with two fibroadenomas containing LCIS.^{7,8} Our report is the first describing CIS arising in three fibroadenomas. In addition, synchronous fibroadenomas harbouring different types of CIS from one fibroadenoma to the other have never been described. Reviewing 400 fibroadenomas at the Free University Medical Centre yielded eight fibroadenomas with CIS,⁵ with the patient described here being the only one with multiple fibroadenomas with CIS. Therefore, CIS within multiple fibroadenomas seems to be an extremely rare event. In the otherwise normal breast CIS is associated with a relative risk for invasive breast cancer of approximately 10.¹¹ The exact relative risk associated with CIS arising within fibroadenoma is not known, but Ozello and Gump advise that it should be treated as if it arose from an otherwise normal breast.⁶

Although malignant transformation of a fibroadenoma is infrequent, the presence of this tumour in a woman with a positive family history may have greater clinical importance than fibroadenomas arising in women with no additional risk factors. The detection of malignancy developing within a fibroadenoma can be difficult. Clinical and radiological signs may be masked until breach of the false capsule.¹² Physicians should be aware of the progression capabilities of breast fibroadenomas, in particular in women with a known BRCA mutation or a strong family history for breast/ovarian cancer. This case report supports the need for a more aggressive diagnostic approach towards solid benign appearing breast lesions in women with a strong positive family history of breast and/or ovarian cancer.

ACKNOWLEDGEMENTS

We thank Dr A Taets-van Amerongen for radiological evaluation of the mammographic images, Dr H Bürger for his help with the detection of the BRCA mutation, and Dr J Piek for immunohistochemical staining for BRCA1.

Authors' affiliations

A Kuijper, P J van Diest, Department of Pathology, Free University Medical Centre, 1007 MB Amsterdam, The Netherlands
F D Rahusen, Department of Surgical Oncology, Free University Medical Centre
J J P Gille, Department of Human Genetics, Free University Medical Centre
E van der Wall, Department of Medical Oncology, Free University Medical Centre
S S Preisler-Adams, Department of Human Genetics, Westfälische Wilhelms University, Münster, Germany

Correspondence to: Professor P J van Diest, Department of Pathology, Free University Medical Centre, PO Box 7057, 1007 MB Amsterdam, The Netherlands; pj.vandiest@vumc.nl

Accepted for publication 27 May 2002

REFERENCES

- 1 **Foster ME**, Garrahan N, Williams S. Fibroadenoma of the breast. *J R Coll Surg Edinb* 1988;**33**:16–19.
- 2 **Carter CL**, Corle DK, Micozzi MS, *et al*. A prospective study of the development of breast cancer in 16,692 women with benign breast disease. *Am J Epidemiol* 1988;**128**:467–77.
- 3 **Dupont WD**, Page DL, Parl FF, *et al*. Long-term risk of breast cancer in women with fibroadenoma. *N Engl J Med* 1994;**331**:10–15.
- 4 **McDivitt RW**, Stevens JA, Lee NC, *et al*. Histologic types of benign breast disease and the risk for breast cancer. *Cancer* 1992;**69**:1408–14.
- 5 **Kuijper A**, Mommers ECM, van der Wall E, *et al*. Histopathology of fibroadenoma of the breast. *Am J Clin Pathol* 2001;**115**:736–42.
- 6 **Ozello L**, Gump FE. The management of patients with carcinomas in fibroadenomatous tumors of the breast. *Surg Gynecol Obstet* 1985;**160**:99–104.
- 7 **Buzanowski-Konakry K**, Harrison EG, Jr, Payne WS. Lobular carcinoma arising in fibroadenoma of the breast. *Cancer* 1975;**35**:450–6.
- 8 **McDivitt RW**, Stewart FW, Farrow JH. Breast carcinoma arising in solitary fibroadenomas. *Surg Gynecol Obstet* 1967;**125**:572–6.
- 9 **De Leeuw WJ**, Berx G, Vos CB, *et al*. Simultaneous loss of E-cadherin and catenins in invasive lobular breast cancer and lobular carcinoma in situ. *J Pathol* 1997;**183**:404–11.
- 10 **Couch FJ**, Weber BL. Mutations and polymorphisms in the familial early-onset breast cancer (BRCA1) gene. *Hum Mut* 1996;**8**:8–18.
- 11 **Page DL**, Dupont WD, Rogers LW, *et al*. Intraductal carcinoma of the breast: follow-up after biopsy only. *Cancer* 1982;**49**:751–8.
- 12 **Baker KS**, Monsees BS, Diaz NM, *et al*. Carcinoma within fibroadenomas: mammographic features. *Radiology* 1990;**176**:371–4.

ECHO

New test will help diagnosis of autoimmune hepatitis



Please visit the
Journal of Clinical
Pathology website
[www.jclinpath.com]
for link to this full
article.

Diagnosing autoimmune hepatitis (AIH) should be improved with a standardised assay using a cloned marker antigen to detect telltale antibodies in patients. The results of the assay using recombinant soluble liver antigen/liver pancreas antigen (SLA/LP) (rELISA) were impressive when compared with confirmatory western blots and an inhibition ELISA (iELISA) test. Among 454 serum samples from 419 patients with AIH from four different countries only one false positive result was recorded with the new test. Twenty one were borderline positive (13 positive by western blotting; therefore considered positive by rELISA) and eight were negative (also by western blotting; therefore considered negative by rELISA). Sixty seven were positive by rELISA and western blotting, of which 61 were positive by iELISA.

Overall specificity of rELISA, when results from this cohort were combined with those for 1026 sera used to validate the test, was 99% and sensitivity 87% at the upper limit of borderline reactivity. Combining results for rELISA and western blotting on borderline sera gave 99% specificity, 100% sensitivity. Positive results were obtained at similar rates in patients from different countries and races.

The test was standardised against a high titre SLA/LP serum. It was calibrated with serum from 200 healthy blood donors and 195 patients with AIH and validated against 1026 non-selected sera from patients with liver disease.

Antibodies to SLA/LP are specific for AIH. Until now a reliable test, suitable for general testing for AIH has not been available.

▲ *Gut* 2002;**51**:259–264.



Multiple fibroadenomas harbouring carcinoma in situ in a woman with a family history of breast/ovarian cancer

A Kuijper, S S Preisler-Adams, F D Rahusen, et al.

J Clin Pathol 2002 55: 795-797
doi: 10.1136/jcp.55.10.795

Updated information and services can be found at:
<http://jcp.bmj.com/content/55/10/795.full.html>

These include:

References

This article cites 12 articles, 3 of which can be accessed free at:
<http://jcp.bmj.com/content/55/10/795.full.html#ref-list-1>

Email alerting service

Receive free email alerts when new articles cite this article. Sign up in the box at the top right corner of the online article.

Topic Collections

Articles on similar topics can be found in the following collections

[Breast cancer](#) (378 articles)
[Gynecological cancer](#) (150 articles)

Notes

To request permissions go to:
<http://group.bmj.com/group/rights-licensing/permissions>

To order reprints go to:
<http://journals.bmj.com/cgi/reprintform>

To subscribe to BMJ go to:
<http://group.bmj.com/subscribe/>