

## REVIEW

## Cryoglobulins

C Ferri, A L Zignego, S A Pileri

*J Clin Pathol* 2002;55:4-13

Serum cryoglobulins are found in a wide spectrum of disorders but are often transient and without clinical implications. Monoclonal cryoglobulins are usually associated with haematological disorders, whereas mixed cryoglobulins are found in many infectious and systemic disorders. So called essential mixed cryoglobulinaemia shows a striking association with hepatitis C virus (HCV) infection (> 90%). It is a systemic vasculitis (leucocytoclastic vasculitis) with cutaneous and multiple visceral organ involvement. Chronic HCV infection can lead to a constellation of autoimmune and neoplastic disorders. In this review, the aetiology, diagnosis, disease heterogeneity, and treatment of cryoglobulinaemia are discussed.

The term cryoglobulinaemia refers to the presence in the serum of one (monoclonal cryoimmunoglobulinaemia) or more (mixed cryoglobulinaemia) immunoglobulins, which precipitate at temperatures below 37°C and redissolve on rewarming.<sup>1,2</sup> This is an *in vitro* phenomenon; the real mechanism(s) of cryoprecipitation remains obscure; it could be secondary to the intrinsic characteristics of both monoclonal and polyclonal immunoglobulin (Ig) components and can also be caused by interaction among single components of the cryoprecipitate. Different hypotheses have been suggested to explain this phenomenon, namely: (1) structural modification of the variable portions of Ig heavy (H) and light (L) chains<sup>3</sup>; (2) a reduced concentration of sialic acid; (3) reduced amounts of galactose in the Fc portion of the Ig<sup>4</sup>; and (4) the presence of *N*-linked glycosylation sites in the CH3 domain as a result of somatic Ig mutations during autoimmune responses.<sup>5</sup> Moreover, non-specific Fc-Fc interactions might explain the self aggregation of some Igs,<sup>6</sup> in addition to specific interactions involving the IgM cryoprecipitable rheumatoid factor (RF) and the Fc portion of IgG, the corresponding autoantigen.

Monoclonal cryoimmunoglobulinaemia is almost invariably associated with a well known haematological disorder and is frequently asymptomatic. Similarly, circulating mixed cryoglobulins are often detected in many infectious and systemic disorders.<sup>7-9</sup> On the contrary, "essential" mixed cryoglobulinaemia (MC) is a distinct disorder,<sup>7-9</sup> characterised by leucocytoclastic vasculitis of small and medium sized vessels, and frequent multiple organ involvement (table 1).

**HCV AND MIXED CRYOGLOBULINAEMIA**

Because chronic hepatitis is frequently observed during the clinical course of MC, a possible role for hepatotropic viruses in the pathogenesis of the disease has long been suggested.<sup>9-11</sup> A role for hepatitis B virus (HBV) in MC was investigated during the 1970s, when the association of this virus with another systemic vasculitis—polyarteritis nodosa—had been demonstrated.<sup>12</sup> However, HBV antigenaemia was rarely recorded, and anti-HBV antibodies varied greatly among different patient populations with MC.<sup>11,13</sup> It is estimated that HBV is a causative factor of MC in less than 5% of individuals (table 1). After the discovery of hepatitis C virus (HCV) as the major aetiological agent of non-A/non-B chronic hepatitis,<sup>14</sup> an increasing number of epidemiological studies suggested an important role for HCV in the pathogenesis of MC.<sup>15,16</sup> In 1990, antibodies against HCV (first generation enzyme linked immunosorbent assay (ELISA); Chiron, Emeryville, California, USA) were demonstrated by two separate studies in 30% and 54% of patients with MC.<sup>15,16</sup> By means of second generation ELISA and recombinant based immunoblot assay, the prevalence of serum anti-HCV in patients with MC in different patient populations ranged from 70% to 100%<sup>17</sup>; these percentages were significantly higher when compared with other systemic immune mediated diseases (Sjögren's syndrome, systemic lupus, rheumatoid arthritis, and systemic sclerosis).<sup>17</sup> The first study evaluating the prevalence of HCV infection by a polymerase chain reaction (PCR) technique in a large series of Italian patients with MC showed a striking correlation between HCV seropositivity (91%) and HCV viraemia (86%).<sup>18</sup> A subsequent study from the USA confirmed the significantly high prevalence of HCV in patients with MC, together with the much higher (1000 fold) concentration of viral genome in the cryoprecipitate than in the supernatant.<sup>19</sup> During the past decade, clinico-epidemiological evidence and laboratory investigations have established the pathogenic role of HCV infection in MC. A direct involvement of HCV antigens in immune complex mediated cryoglobulinaemic vasculitis has been

See end of article for authors' affiliations

Correspondence to:  
Professor C Ferri,  
Dipartimento Medicina  
Interna-Reumatologia, Via  
Roma 67, 56126 Pisa,  
Italy; c.ferri@  
int.med.unipi.it

Accepted for publication  
31 May 2001

**Abbreviations:** APAAP, alkaline phosphatase anti-alkaline phosphatase; B-CLL, B cell chronic lymphocytic leukaemia/small lymphocytic lymphoma; BCL, B cell non-Hodgkin's lymphoma; ELISA, enzyme linked immunosorbent assay; Ig, immunoglobulin; LAC, low antigen content; MC, mixed cryoglobulinaemia; HBV, hepatitis B virus; HCV, hepatitis C virus; I<sub>c</sub>, immunocytoma; MLDUS, monotypic lymphoproliferative disorder of undetermined significance; PCR, polymerase chain reaction; RF, rheumatoid factor;

**Table 1** Demographic, clinicoserological, and virological features of 170 patients with mixed cryoglobulinaemia

Mean (SD; range) age (years)*	51 (11; 29–73)
Female/male ratio	2.8
Mean (SD; range) disease duration (years)	11.9 (6.4; 1–34)
Purpura	91%
Weakness	89%
Arthralgias	83%
Arthritis (non-erosive)	10%
Raynaud's phenomenon	34%
Sicca syndrome	36%
Peripheral neuropathy	36%
Renal involvement†	31%
Liver involvement	70%
B cell non-Hodgkin's lymphoma	7.5%
Hepatocellular carcinoma	2.4%
Mean (SD) cryocrit (%)	3.7 (7.0)
Type II/type III mixed cryoglobulins	2/1
Mean (SD) CH50 (units; normal, 160–220)	83 (58)
Mean (SD) C3 (mg/l; normal, 600–1300)	770 (280)
Mean (SD) C4 (mg/l; normal, 200–550)	100 (150)
Antinuclear antibodies	24%
Antimitochondrial antibodies	10%
Antismooth muscle antibodies	23%
Anti-extractable nuclear antigen antibodies	7%
Anti-HCV antibodies	90%
HCV RNA	86%
Anti-HBV antibodies	40%
HbsAg	3.5%

\* At presumed disease onset; † invariably membranoproliferative glomerulonephritis. HbsAg, hepatitis B surface antigen; HBV, hepatitis B virus; HCV, hepatitis C virus.

also suggested, on the basis of immunohistochemical and molecular biology studies, including HCV RNA detection by in situ hybridisation.<sup>17–20–22</sup> Therefore, the term essential no longer seems to be appropriate for most patients with MC.<sup>23</sup> Numerous epidemiological studies have found only low concentrations of circulating mixed cryoglobulins in over 50% of HCV infected individuals, and overt cryoglobulinaemic syndrome develops in only a minority.<sup>24–25</sup> The worldwide distribution of HCV infection contrasts with the geographical heterogeneity observed in the prevalence of HCV related MC.<sup>17–20–26–28</sup> Thus, particular HCV genotypes and unknown environmental and/or genetic factors may contribute to the pathogenesis of MC (fig 1); however, few and often contrasting studies are available, and a role for the above cofactors remains to be demonstrated.<sup>20–28–31</sup>

## HCV AND AUTOIMMUNITY

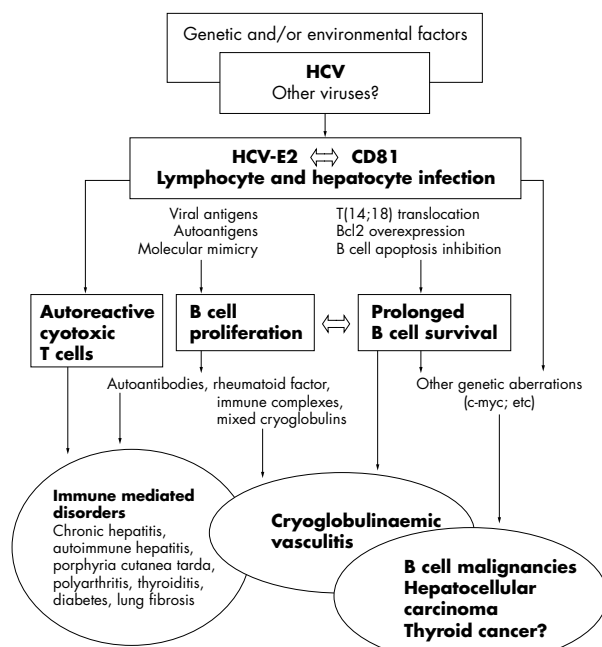
An increasing number of immunological alterations have been observed in individuals with chronic HCV infection,<sup>24–25–28–32</sup> suggesting that the same virus might be responsible for different hepatic and extrahepatic immune mediated disorders. Table 2 summarises the main organ or systemic diseases variably associated with HCV infection. Apart from MC syndrome, other important HCV associated disorders are porphyria cutanea tarda, autoimmune hepatitis, membranoproliferative glomerulonephritis, and malignancies.<sup>20–27–28–33–39</sup> In patients with the sporadic variant of porphyria cutanea tarda, a metabolic disorder characterised by reduced hepatic activity of uroporphyrinogen decarboxylase, a clear cut association with HCV infection has been demonstrated.<sup>33–34</sup> Most patients with porphyria cutanea tarda present with chronic liver involvement in addition to some type of HCV driven clinicoserological autoimmune phenomenon.<sup>34</sup> For certain patient subsets and in some geographical areas, epidemiological and clinicoserological studies support a causative role for HCV in various immune system disorders.<sup>28–35</sup> Interestingly, different HCV related diseases show a clinicoserological overlap<sup>27–28–35–38</sup>, in particular, MC can

represent a crossroad between a classic autoimmune disorder (such as autoimmune hepatitis, sicca syndrome, glomerulonephritis, thyroiditis, etc) and malignancy (such as B cell lymphoma, hepatocellular carcinoma) (fig 1).<sup>27–28–38</sup>

**“Mixed cryoglobulinaemia can represent a crossroad between a classic autoimmune disorder and malignancy”**

Because of possible methodological bias, mainly in patient selection among different studies, it is difficult to verify whether the suggested association between HCV and some immunological disorders (table 2) is coincidental or whether a pathogenetic link really exists. Classic rheumatoid arthritis seems to be uncommon in HCV positive patients, whereas an intermittent, generally non-erosive oligoarthritis, involving large and medium sized joints, is often seen.<sup>28</sup> In general, HCV associated chronic arthritis in patients with or without cryoglobulinaemic syndrome is characterised by a more benign clinical course and a good response to low dose steroids and hydroxychloroquine treatment.<sup>28–40</sup> Isolated HCV positive membranoproliferative glomerulonephritis has been described<sup>36</sup>; more frequently, nephropathy is one of the visceral complications of HCV associated MC.<sup>28</sup> In these patients renal involvement can be secondary to the glomerular deposition of HCV containing cryoglobulins and/or the in situ formation of immune complexes.<sup>27–28–36–41</sup>

Some HCV related autoimmune manifestations, namely polyarthritis, glomerulonephritis, or alveolitis, may be an isolated symptom, often in patients with very mild or subclinical MC. Therefore, in these patients the concomitant presence of HCV related severe complications such as hepatitis, systemic vasculitis, or lymphoma should be carefully investigated. As observed for MC, the association between HCV and other autoimmune diseases shows a geographically heterogeneous distribution,<sup>27–28–32–35</sup> suggesting the role of important cofactors in these conditions also.



**Figure 1** Possible aetiopathogenesis of mixed cryoglobulinaemia (MC) and other hepatitis C virus (HCV) related disorders. HCV infection may exert a chronic stimulus on the immune system. The interaction between HCV envelope protein E2 and CD81 on both hepatocytes and lymphocytes may be an important step in the cascade of events. T(14;18) translocation is commonly found in HCV infected individuals, particularly in patients with MC. The activation of the Bcl2 proto-oncogene may lead to prolonged B cell survival. B cell expansion is responsible for the production of various autoantibodies, including rheumatoid factor and cryoprecipitable immune complexes. Consequently, various autoimmune disorders and cryoglobulinaemic vasculitis may develop. In a minority of cases, indolent B cell proliferation may be complicated by frank malignant lymphoma. HCV is the major causative factor of hepatocellular carcinoma; moreover, a possible link between HCV and thyroid cancer has been hypothesised. There is a clinicoserological and pathological overlap among different HCV related diseases; mixed cryoglobulinaemia syndrome represents a crossroad between these autoimmune and neoplastic disorders.

## HCV AND LYMPHOPROLIFERATION

HCV has been recognised to be both a hepatotropic and lymphotropic virus, as suggested by the presence of active or latent viral replication in the peripheral lymphocytes of patients with type C hepatitis or MC.<sup>42-43</sup> The infection of lymphoid tissues could represent an HCV reservoir that contributes greatly to viral persistence; moreover, the quasispecies nature of HCV<sup>44</sup> permits it to escape immune surveillance and favours the persistence of infection in the host. These biological characteristics may explain the appearance of a constellation of both autoimmune and lymphoproliferative disorders in HCV infected individuals.<sup>17 26-28 32</sup> A possible causative link between hepatotropic viruses and malignant lymphomas has been hypothesised since the early 1970s.<sup>45</sup> In 1994, HCV infection was first demonstrated in a large proportion of Italian patients with unselected B cell non-Hodgkin's lymphoma (BCL), regardless of their histotype.<sup>46</sup> This association was confirmed in patients with BCL from different countries.<sup>20 38 47-49</sup> A further clue to the possible direct involvement of HCV in lymphomagenesis was provided by investigations showing the presence of HCV related proteins and/or HCV replicative particles, mainly intermediates, in peripheral lymphocytes and tissue biopsy specimens of patients with lymphoma by means of immunohistochemistry, reverse transcription PCR, or in situ hybridisation studies.<sup>20-22 43</sup> However, the lymphomagenic role of HCV is still a matter of debate, for several reasons. First, there is remarkable geographical and racial variability in the incidence of HCV infection in patients with BCL, as underlined by the existence of a gradient from northern to southern Europe and by the differences observed between southern California, with a prevalent Hispanic population, and the midwestern USA.<sup>20 46-51</sup> Because the prevalence of HCV infection in Western countries is quite homogeneous, this variability suggests that HCV per se may be insufficient to drive malignant lymphoma, and that genetic and environmental cofactors are possibly required for the full expression of malignancy.<sup>20</sup> Second, HCV is a positive, single stranded RNA virus without a DNA intermediate in its replicative cycle, so that viral genomic sequences cannot be integrated into the host genome. Therefore, it has been proposed that HCV infection exerts a chronic stimulus on the immune system, which facilitates the development and selection of abnormal clones.<sup>20</sup>

Patients with type II MC can develop a B cell lymphoma, usually after long term follow up.<sup>52-53</sup> This complication may be related to peripheral B cell expansion<sup>54</sup> and to the lymphoid infiltrates observed in the liver and bone marrow of patients with MC.<sup>55 56</sup> In particular, these infiltrates have been regarded by some authors as "early lymphomas", because they are sustained by lymphoid components indistinguishable from those of B cell chronic lymphocytic leukaemia/small lymphocytic lymphoma (B-CLL) and immunocytoma (Ic).<sup>57</sup> However, unlike frank malignant lymphomas, they tend to remain unmodified for years or even decades, and are followed by overt lymphoid tumours in about 10% of cases only.<sup>20 57</sup> These characteristics justify the recently proposed term of "monotypic lymphoproliferative disorder of undetermined significance (MLDUS)".<sup>20 57</sup> Interestingly, type II MC related MLDUS has its highest incidence in the same geographical areas where about 30% of patients with "idiopathic" BCL also display HCV positivity, and where an increased prevalence of the HCV genotype 2a/c has been observed in both MC and BCL.<sup>20 29</sup>

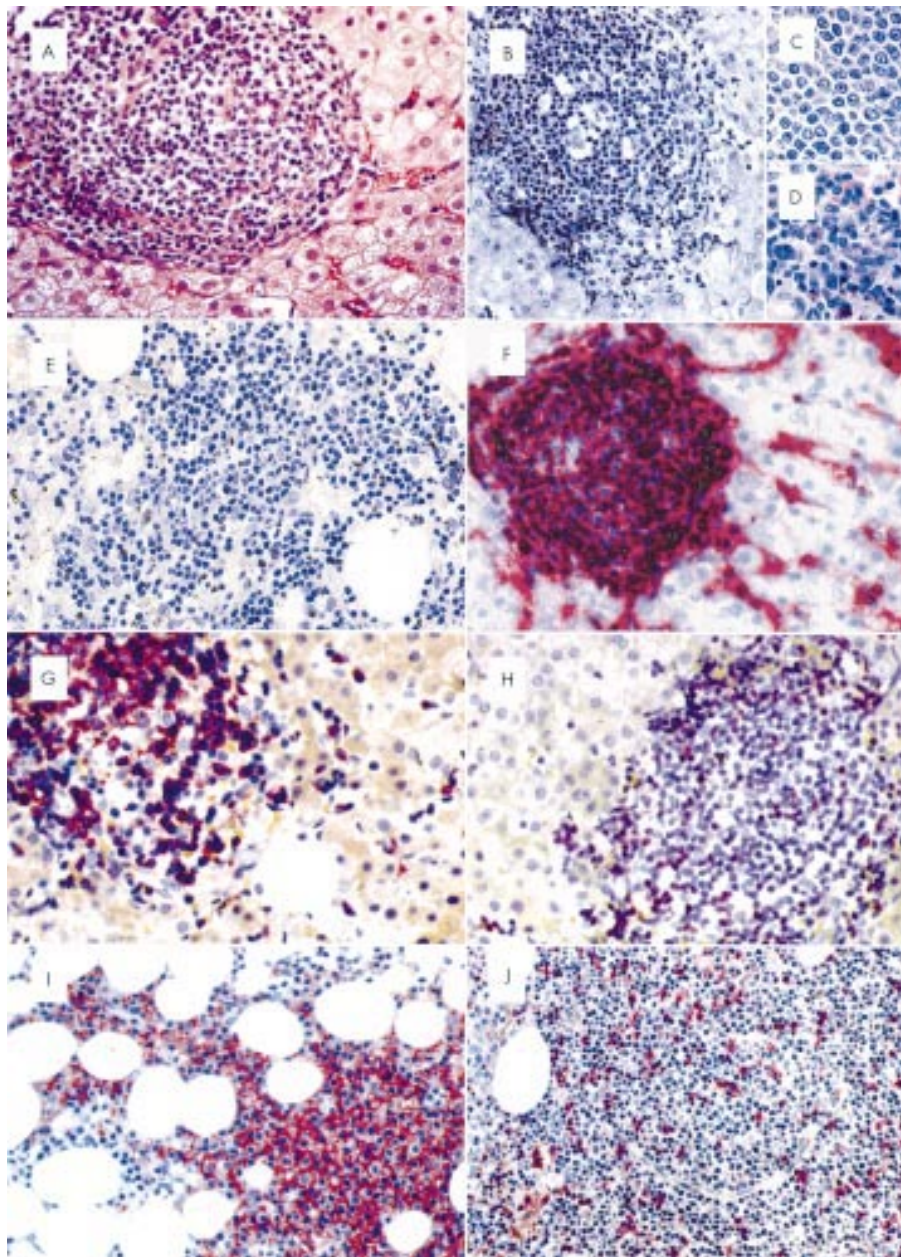
Type II MC associated MLDUS presents two main pathological patterns; namely, B-CLL-like and Ic-like patterns (fig 2).<sup>20</sup>

The lymphoid infiltrates of B-CLL-like MLDUS observed in needle biopsies taken from the liver and bone marrow are characterised by a mixture of small lymphocytes, prolymphocytes, and para-immunoblasts.<sup>58</sup> Repeated biopsies do not usually show expansion of the monotypic B cell infiltrates in the bone marrow, and in the liver these can even undergo histological regression, in the case of cirrhotic evolution.<sup>57</sup> In particular, Monteverde *et al* reported that in 14 patients with

**Table 2** Association between hepatitis C virus (HCV) infection and diseases

Established association*
Mixed cryoglobulinaemia (MC) (complete or incomplete MC syndrome)
Porphyria cutanea tarda
Significant association†
Autoimmune hepatitis
B cell non Hodgkin's lymphoma
Monoclonal gammopathies
Possible association‡
Chronic polyarthritis
Sicca syndrome
Lung fibrosis
Polyarteritis nodosa
Poly/dermatomyositis
Thyroiditis/thyroid cancer
Diabetes mellitus
Lichen planus
Mooren corneal ulcers

\*HCV infection in 80–90% of cases; †HCV infection in a significant percentage of patients when compared with the general population; ‡suggested but unconfirmed association.



**Figure 2** Type II mixed cryoglobulinaemia (MC) associated monotypic lymphoproliferative disorder of undetermined significance (MLDUS) shows two main pathological patterns: B cell chronic lymphocytic leukaemia/small lymphocytic lymphoma (B-CLL)-like and immunocytoma (Ic)-like MLDUS. (A) lymphoid infiltrate in a portal tract of the liver; note the substantial lack of activity (haematoxylin and eosin; original magnification,  $\times 100$ ); (B) lymphoid infiltrate in a portal tract of the liver with moderate activity (Giemsa; original magnification  $\times 100$ ); at higher magnification, the infiltrate shows either B-CLL-like (C) or Ic-like (D) morphology (Giemsa; original magnification,  $\times 400$ ); (E) nodular lymphoid infiltrate in the bone marrow showing indistinct borders (Giemsa; original magnification,  $\times 100$ ). (F–H) B-CLL-like MLDUS: the lymphoid population of a liver infiltrate strongly expresses the CD22 antigen (F) and is in turn CD5 positive (G) and CD3 negative (H); CD3 is expressed by some T cells. Immunocytochemistry in frozen (F) and paraffin wax embedded sections (G,H) (alkaline phosphatase anti-alkaline phosphatase (APAAP) technique; Gill's haematoxylin counterstaining; original magnification,  $\times 150$ ). (I,J) Ic-like-MLDUS: the lymphoid infiltrate in the bone marrow shows a clear cut positivity for CD20 and turns out to be negative for CD5, which is confined to reactive T cells (immunocytochemistry in paraffin wax embedded sections; APAAP technique; Gill's haematoxylin counterstaining; original magnification,  $\times 150$ ).

MLDUS and type II MC, who received serial liver biopsies and showed evolution of their HCV related hepatitis to frank cirrhosis, the augmentation of the inflammatory component paralleled the reduction of monotypic infiltrates.<sup>37</sup> Notably, in a few patients with MLDUS, who received repeated bone marrow biopsies before and after interferon administration, regression of the lymphoid infiltrates has been observed in conjunction with the clearance of the virus.<sup>59</sup>

Only a few studies have been performed at the molecular level. Magalini *et al* first reported on the analysis by microdissection PCR of the B cell component in 35 portal lymphoid

infiltrates from 11 HCV positive patients (seven with and four without type II MC).<sup>60</sup> IgH PCR showed a single band in 21 infiltrates, two bands in 10, and three bands in four. Comparison of the IgH PCR amplified samples obtained from different lymphoid aggregates of the same biopsy revealed that they differed in size. These findings suggest that in the liver each aggregate derives from the proliferation of one or a few unrelated founder B cells. Thus, in spite of the monotypic pattern shown by immunohistochemistry, it seems likely that the lymphoproliferation is sustained by more than one clone. This hypothesis has found further support in a recent report by De

Vita *et al*, who showed that the pattern of B cell expansion in 12 of 15 bone marrow biopsies from HCV positive patients with type II MC was indeed oligoclonal.<sup>61</sup>

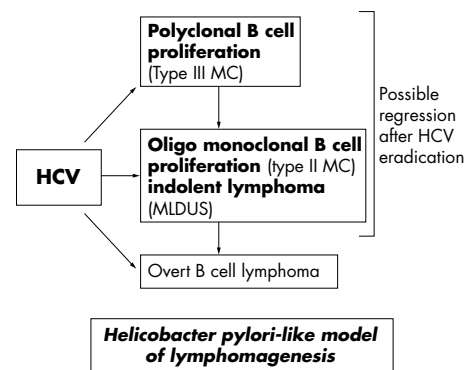
Some groups have reported that MLDUS often shows immunocytic morphology (for a comprehensive review of the topic see Ferri and colleagues<sup>20</sup>). However, this has not been our experience, and the discrepancy may result from the differences in terminology existing between the updated Kiel classification<sup>62</sup> and the REAL classification.<sup>58</sup> A critical review of reports in the literature reveals that most of the immunocytoma-like proliferations described by others do not satisfy the criteria of the REAL classification.<sup>62</sup>

In spite of morphology and monotypic Ig light chain expression, the lymphoproliferation occurring in HCV positive patients with type II MC cannot be regarded as a real lymphomatous condition because: (1) it is usually characterised by oligoclonality, and (2) the overt malignant lymphoma that eventually develops during follow up usually stems from a B cell clone other than those sustaining MLDUS.

Further findings reported in the literature during the past two years have increased the interest in lymphoproliferative disorders in HCV positive patients with MC. In particular, in 1997 the presence of the t(14;18) translocation in peripheral blood lymphocytes detected by PCR was first demonstrated in HCV infected individuals.<sup>63</sup> This was later evaluated on a larger patient series,<sup>64</sup> and showed a significantly high percentage of Bcl2 recombination and overexpression in both type C hepatitis (26%) and HCV related type II MC (71%) when compared with HCV negative chronic liver diseases (4%). T(14;18) translocation correlated with the presence of the HCV genotype 2c.<sup>64</sup> The above findings are supported by two recent studies using the same techniques (A L Zignego *et al*, unpublished, 2000) and cytogenetic analysis and fluorescence in situ hybridisation (FISH) with painting probes<sup>65</sup>; in both studies, most patients with HCV related MC, especially type II, had t(14;18) positive circulating B cells.

The HCV related lymphoproliferation, varying from the benign poly/oligoclonal B cell expansion frequently seen in MC to overt malignant lymphoma, is a multifactorial and multistep process for which multiple genetic aberrations are probably necessary.<sup>20</sup> Moreover, the recent identification of HCV envelop protein E2, which can bind the CD81 molecule expressed on both hepatocytes and B cells,<sup>66</sup> might help to clarify the pathogenesis of HCV related autoimmune and lymphoproliferative diseases (fig 1). In fact, CD81 is a cell surface protein, which, on B cells, is complexed with CD21, CD19, and Leu 13. This complex reduces the threshold for B cell activation by bridging antigen specific recognition and CD21 mediated complement recognition. It can be hypothesised that the interaction between HCV-E2 and CD81 may increase the frequency of VDJ rearrangement in antigen reactive B cells. One possible consequence could be the bcl2 recombination seen in an appreciable number of HCV infected individuals, and particularly in patients with MC.<sup>63-64</sup> This proto-oncogene can inhibit apoptosis, leading to extended cell survival.<sup>67</sup> The bcl2 aberration may explain, at least in part, the B cell expansion and the wide autoantibody production seen in HCV infected individuals.<sup>20-28</sup> Other mechanisms, such as molecular mimicry, may be involved in the B cell activation responsible for different autoimmune disorders. Conversely, prolonged B cell survival can expose these cells to other genetic aberrations,<sup>20-38-68-69</sup> leading to overt malignant lymphoma (fig 1). The oncogenic potential of HCV for hepatocellular carcinoma is well known, regardless of the intermediate cirrhosis<sup>70</sup>; the same virus might also be involved in other malignancies, such as thyroid cancer.<sup>20-38-39</sup>

"The hepatitis C virus related lymphoproliferation, varying from the benign poly/oligoclonal B cell expansion frequently seen in mixed cryoglobulinaemia



**Figure 3** Hepatitis C virus (HCV) related lymphoproliferation shows consistent similarities with the model of lymphomagenesis already accepted for subjects with *Helicobacter pylori* positive gastritis.

to overt malignant lymphoma, is a multifactorial and multistep process for which multiple genetic aberrations are probably necessary"

Although limited in the context of MC and some cases of idiopathic BCL (20–30%), HCV related lymphomagenesis might be of great pathogenetic interest. In fact, the monotypic/oligoclonal lymphoproliferation might arise within the context of the HCV driven inflammatory process because of the frequent (virus related?) occurrence of the t(14;18) translocation, which favours the proliferation of some clones over others by inducing protection against apoptosis.<sup>20-63-65</sup> These selected clones might need the persistence of an HCV antigen driven stimulus<sup>71</sup> and T cell cooperation for their maintenance; thus, appropriate treatments can induce both clearance of the virus and MLDUS regression, at least in some cases.<sup>59-72</sup> The chronic stimulation of the B cell system exerted by HCV infection and possible concurrent autoimmune phenomena, along with the occurrence of the above mentioned clonal selection, is a favourable background for the development of an overt malignant lymphoma.<sup>20</sup> Thus, reactive lymphoproliferation occurring in HCV positive patients with type II MC shows consistent similarities to the models of lymphomagenesis already accepted in HIV positive patients and in subjects with *Helicobacter pylori* positive gastritis (fig 3).<sup>20-38-73-75</sup> Further molecular studies are needed to evaluate this possible pathogenetic mechanism, which can also be postulated in the development of lymphoid tumours occurring in HCV positive patients without type II MC.

## CLASSIFICATION

Cryoglobulinaemia is usually classified into three subgroups, according to Brouet and colleagues<sup>8</sup>: type I, composed of a single monoclonal immunoglobulin, usually a paraprotein; types II and III, characterised by polyclonal IgG and monoclonal or polyclonal IgM RF, respectively. Table 3 shows the main biological and clinicopathological characteristics of these subgroups. Cryoglobulinaemia type I is found mainly in patients with overt lymphoid tumours (that is, immunocytoma/Waldenstrom's macroglobulinaemia, multiple myeloma, etc); MC types II and III can be associated with different infectious, immunological, or neoplastic diseases.<sup>7-9</sup> In general, the analysis of cryoprecipitates is carried out by means of immunoelectrophoresis or immunofixation. Using more sensitive methodologies, such as immunoblotting or two dimensional polyacrylamide gel electrophoresis, type II MC shows a microheterogeneous composition; in particular, oligoclonal IgM or a mixture of polyclonal and monoclonal IgM can be detected.<sup>76</sup> This particular serological subset, termed type II–III MC, could represent an intermediate state in the evolution from type III to type II. This serological condition agrees with the most

**Table 3** Classification of cryoglobulins

	Type I cryoglobulinaemia	Type II mixed cryoglobulinaemia	Type III mixed cryoglobulinaemia
Composition	Single monoclonal Ig mainly IgG, IgM, or IgA, or monoclonal free light chains	Presence of monoclonal component: usually IgM, IgG, or IgA and polyclonal Ig (mainly IgG)	Polyclonal mixed Ig (all isotypes)
Biological characteristics	Self aggregation through Fc fragment of Ig	RF activity of monoclonal component against Fc portion of polyclonal Ig predominant, cross idiotype Wa mRF	RF activity of one polyclonal component (usually IgM)
Pathological characteristics	Tissue histological alterations of underlying disorder	Leucocytoclastic vasculitis, B cell expansion, and tissue B cell infiltrates	Leucocytoclastic vasculitis, B cell expansion, and tissue B cell infiltrates
Clinical associations	Lymphoproliferative disorders: multiple myeloma, Waldenstrom's macroglobulinaemia, chronic lymphocytic leukaemia, B cell NHL	Viral, bacterial, parasitic infections (mainly HCV, less HBV, others), autoimmune diseases, lymphoproliferative disorders rare in essential form	Viral, bacterial, parasitic infections (mainly HCV, less HBV, others), autoimmune diseases, lymphoproliferative disorders rare in essential form

HBV, hepatitis B virus; HCV, hepatitis C virus; Ig, immunoglobulin; m, monoclonal; NHL, non-Hodgkin's lymphoma; RF, rheumatoid factor.

**Table 4** Proposed criteria for the classification of patients with mixed cryoglobulinaemia

Criteria	Major	Minor
Serological	Mixed cryoglobulins Low C4	Rheumatoid factor+ HCV+ HBV+
Pathological	Leucocytoclastic vasculitis	Clonal B cell infiltrates (liver and/or bone marrow)
Clinical	Purpura	Chronic hepatitis Membranoproliferative glomerulonephritis Peripheral neuropathy Skin ulcers

HCV+ or HBV+: markers of hepatitis C virus or hepatitis B virus infection (anti-HCV  $\pm$  HCV RNA; HBV DNA or HBV surface antigen).

**"Definite" mixed cryoglobulinaemia syndrome:**

(a) Serum mixed cryoglobulins ( $\pm$ low C4) + purpura + leucocytoclastic vasculitis.

(b) Serum mixed cryoglobulins ( $\pm$ low C4) + 2 minor clinical symptoms + 2 minor serological/pathological findings.

**"Incomplete" or "possible" mixed cryoglobulinaemia syndrome:**

(a) Mixed cryoglobulins or low C4 + 1 minor clinical symptom + 1 minor serological  $\pm$  pathological findings.

(b) Purpura and/or leucocytoclastic vasculitis + 1 minor clinical symptom + 1 minor serological  $\pm$  pathological findings.

(c) Two minor clinical symptoms + 2 minor serological  $\pm$  pathological findings.

**"Essential" or "secondary" mixed cryoglobulinaemia:**

Absence or presence of well known disorders (infectious, immunological, or neoplastic) at the time of the diagnosis.

recent molecular studies showing the presence of oligoclonal B cell proliferation in liver and bone marrow biopsies in most patients with type II MC.<sup>60 61</sup>

In two thirds of patients with type II MC, serum monoclonal RFs have been found. Like natural autoantibodies, monoclonal RFs share a major complementary determining region named Wa, and they invariably express a Vk light chain derived from a single germinal gene, the human Kv 325 gene.<sup>26 77</sup>

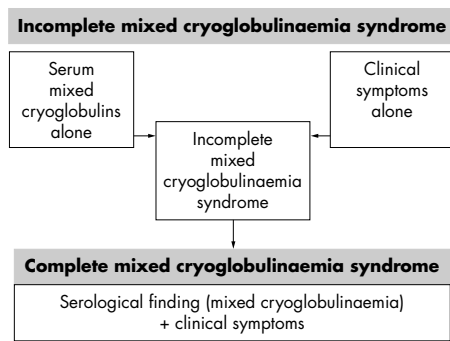
Cross idiotype Wa monoclonal RF has also been demonstrated in other B cell lymphoproliferative disorders, with or without type II MC, probably an expression of antigen independent clonal B cell lymphoproliferation.<sup>26</sup> This suggests that the same antigen might be the triggering factor of both primary and lymphoma associated type II MC. Because type II and type III MC occur in a variety of infectious diseases, we could speculate that they are the result of chronic stimulation of the immune system by complexes composed of autologous IgG and antigen(s) of the involved infectious agent. When complexed, the IgG becomes autoantigenic and it can elicit the Wa or other RFs.<sup>26</sup>

There are no available diagnostic criteria for MC; in 1989 the Italian group for the study of cryoglobulinaemias proposed preliminary criteria for MC classification (C Ferri for the Ital-

ian Group for the Study of Cryoglobulinemias. Proceedings of 10th Congresso Società Italiana di Immunologia e Immunopatologia, S. Margherita di Pula, Cagliari, 12 May, 1989). Table 4 gives a revised version of these criteria, including pathological and virological findings. Circulating mixed cryoglobulins, low C4, and orthostatic skin purpura are the hallmarks of the disease; moreover, leucocytoclastic vasculitis, involving medium and, more often, small sized blood vessels (arterioles, capillaries, and venules) is responsible for MC tissue injury.<sup>9</sup> Cryoglobulinaemic vasculitis is secondary to vascular deposition of circulating immune complexes, mainly cryoglobulins, and complement, with the possible contribution of both haemorheological and local factors.<sup>9 26 79</sup> Because of its clinical and histological features, MC is classified among systemic vasculitides, in the subgroup of small vessel vasculitides, which also includes cutaneous leucocytoclastic vasculitis and Schonlein-Henoch purpura.<sup>80</sup>

**CLINICAL AND LABORATORY INVESTIGATIONS**

Essential MC was first described by Meltzer *et al* in 1966<sup>7</sup>; originally, this term referred to autonomous disease when other well known systemic, infectious, or neoplastic disorders had been ruled out by means of a wide clinicoserological investigation. The MC syndrome is characterised clinically by



**Figure 4** Different clinicoserological patterns of mixed cryoglobulinaemia (MC) at presentation; complete MC syndrome is a combination of serological findings (mixed cryoglobulins with rheumatoid factor activity and frequent low C4) and clinicopathological features (purpura, leucocytoclastic vasculitis with multiple organ involvement; tables 1, 4). MC can appear as an incomplete syndrome, mainly in the early stages of the disease.

a triad—purpura, weakness, arthralgias—and by a series of pathological conditions (table 1), including chronic hepatitis, membranoproliferative glomerulonephritis, peripheral neuropathy, skin ulcers, diffuse vasculitis, and less frequently, lymphatic and hepatic malignancies.<sup>7-9 26-28 81</sup> The prevalence of MC manifestations reported in table 1 describes an Italian patient population referred to a rheumatology/immunology division; variable patient recruitment at different specialist centres, together with racial differences among patient series, are responsible for contrasting data in the literature.<sup>26-28 81</sup> As observed for HCV related BCL, the prevalence of MC shows much geographical heterogeneity; the disease is more common in southern Europe than in northern Europe or North America. The disease is considered to be a relatively rare disorder; however, as yet there are no adequate epidemiological studies regarding its overall prevalence. Given its clinical polymorphism, a single manifestation (skin vasculitis, hepatitis, nephritis, peripheral neuropathy, etc) is often the only apparent or clinically predominant feature, so that patients with MC are often referred to different specialties. A correct diagnosis might thus be delayed or overlooked entirely; consequently, the prevalence of MC is probably underestimated.

At initial observation, MC can present with different clinicoserological patterns (fig 4), varying from isolated serum mixed cryoglobulins, probably an expression of the early stage of disease, to complete cryoglobulinaemic syndrome. This is a combination of serological findings (mixed cryoglobulins with RF activity and frequent low C4) and clinicopathological features (purpura, leucocytoclastic vasculitis with multiple organ involvement). Moreover, incomplete MC—that is, mixed cryoglobulinaemia with one or two typical MC features (arthralgias, peripheral paresthesias, mild hepatitis, RF seropositivity, low C4, etc)—is frequently found, mainly in the rheumatic outpatient clinic. In these subjects, an overt MC syndrome can develop during long term follow up. Alternatively, some patients have typical MC syndrome, but without serum cryoglobulins, the hallmark of the disease (fig 4). This is usually a transient phenomenon, resulting from the wide variability of amounts of cryoprecipitable circulating immune complexes.<sup>82</sup> Repeated cryoglobulin determinations are necessary for a correct diagnosis in these subjects; obviously, it is necessary to avoid false negative results as a result of Ig cold precipitation occurring at room temperature. For a correct evaluation of serum cryoglobulins, the first steps (blood sampling, clotting, and serum separation by centrifugation) should always be carried out at 37°C and the cryocrit determination and cryoglobulin characterisation at 4°C (after seven days). Moreover, cryocrit determinations should be done on blood samples without anticoagulation to avoid false positive

results caused by cryofibrinogen. Unfortunately, there are no standardised methodologies for cryoglobulin measurements that are accepted worldwide. Serum cryoglobulin values usually do not correlate with the severity and prognosis of the disease. Very low cryocrit values, often difficult to quantify, can be associated with severe, active cryoglobulinaemic syndrome; on the contrary, high serum cryoglobulin concentrations may characterise an oligosymptomatic or asymptomatic disease course. In these subjects, particularly in the presence of a cryogel phenomenon, rheological alterations caused by blood hyperviscosity can be observed.<sup>79</sup> Finally, a sudden decrease or disappearance of serum mixed cryoglobulins, sometimes associated with abnormally high C4 values, can be the presenting manifestation of complicating B cell malignancy.<sup>83</sup>

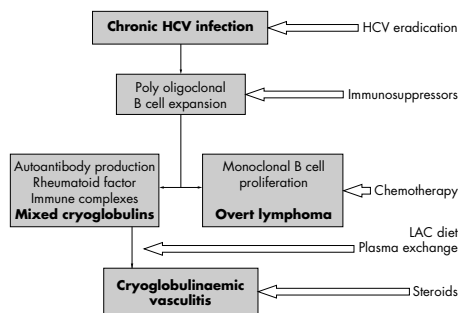
## MANAGEMENT

The clinical course, treatment, and prognosis of type I cryoglobulinaemias largely depend on the underlying disorder, varying from benign MLDUS to malignant B cell neoplasia. Hyperviscosity syndrome is a direct consequence of type I cryoglobulinaemia and plasma exchange treatment is often necessary for this haemorheological disorder. On the contrary, MC is often responsible for a more or less severe clinical syndrome, including vasculitic damage of the skin and visceral organs, chronic liver disease, B cell neoplasms, and other cancers.<sup>7-9 17 20 27 28</sup> Because of its complex aetiopathogenesis, the treatment of MC is particularly challenging. For a correct therapeutic approach we must deal with three important factors: HCV infection, autoimmune disorders, and neoplastic complications. Following the cascade of events leading from HCV infection to cryoglobulinaemic vasculitis (fig 5), we can treat the disease at different levels by means of different—etiopathological, pathogenetic, symptomatic—treatments. Because HCV is the triggering factor of the disease, and probably exerts a chronic stimulus on the immune system (figs 1, 5), HCV eradication should be attempted in all cases of HCV associated MC. In this respect, encouraging data came from anecdotal observations: in patients with MLDUS repeated bone marrow biopsies, before and after interferon treatment, showed a regression of lymphoid infiltrates along with HCV clearance.<sup>84</sup> Unfortunately, the beneficial effect seen with this drug is often transient and sometimes associated with important immune mediated complications, in particular, peripheral sensory motor neuropathy.<sup>85-90</sup> There are no parameters available for predicting this harmful complication; thus,  $\alpha$  interferon treatment should be avoided at least in those patients with clinically evident peripheral neuropathy. Similarly, in patients treated by  $\alpha$  interferon for type C hepatitis, it is not rare to encounter complications such as peripheral neuropathy, thyroiditis, and rheumatoid-like polyarthritis. Probably, in predisposed subjects  $\alpha$  interferon, both an antiviral and immunomodulating agent, can trigger or exacerbate some pre-existing, often subclinical, symptoms.

The usefulness of  $\alpha$  interferon treatment in patients with MC is limited by the low rate of responders and frequent side effects. However, treatment with a combination of  $\alpha$  interferon and ribavirin might eradicate HCV infection in a considerable number of subjects, as recently demonstrated in patients with type C chronic hepatitis.<sup>91-93</sup> Controlled clinical trials are necessary to evaluate the usefulness of such combination treatment in HCV associated MC.

“The usefulness of  $\alpha$  interferon treatment in patients with mixed cryoglobulinaemia is limited by the low rate of responders and frequent side effects”

Hopefully, with the rapid growth of molecular biology a vaccine against HCV may be available in the near future. The recent identification of the interaction between HCV envelope



**Figure 5** Mixed cryoglobulinaemia is a combination of three main clinicopathological alterations: chronic hepatitis C virus (HCV) infection, B cell lymphoproliferation, and immune complex vasculitis. We can treat the disease at different levels and by means of combined—ætiological, pathogenetic, and symptomatic—treatments. LAC, low antigen content.

protein E2 and CD81 on both hepatocytes and lymphocytes<sup>66</sup> suggests the possibility of interfering with HCV binding to target cells. A vaccine based treatment<sup>94</sup> with recombinant HCV proteins in HCV infected individuals might prevent the evolution from viral infection to both severe hepatic and extrahepatic complications, and could possibly interrupt the self perpetuating autoimmune mechanism underlying HCV related disorders.

Immunosuppressive treatment is still the first line intervention in cases of non-HCV associated MC. For HCV positive patients with MC, immunosuppressive treatment should be considered, particularly in subjects who have failed to respond to  $\alpha$  interferon. This includes steroids, a low antigen content (LAC) diet, plasma exchange, and immunosuppressors, mainly cyclophosphamide.<sup>9 27 28 95–99</sup> A reduction in circulating immune complexes can be achieved by means of plasmapheresis treatment, including both traditional plasma exchange and double filtration plasma exchange.<sup>100</sup> The use of oral cyclophosphamide (50–100 mg/day for two to six weeks) during the tapering of apheresis sessions can reinforce the beneficial effect of plasma exchange; moreover, it can prevent the rebound phenomenon that may be observed after the discontinuation of apheresis. Plasma exchange is useful in severe MC complications, particularly in active cryoglobulinaemic nephropathy (table 5). A LAC diet has been used for some immune complex mediated disorders, such as MC and IgA nephropathy.<sup>95 98</sup> In patients with MC, this particular treatment can improve circulating immune complex clearance by restoring the activity of the reticuloendothelial system,

overloaded by large amounts of circulating cryoglobulins.<sup>95</sup> A LAC diet and/or low dose of steroids may be sufficient to improve mild–moderate manifestations of MC (table 5). As often observed, patients with MC and mild–moderate symptoms, such as palpable purpura, are particularly sensitive to the smallest variations of daily steroid dosage (1–2 mg). In general, the treatment of MC should be tailored for the single patient according to the severity of clinical symptoms. Therefore, patients with severe vasculitic manifestations must be treated promptly with high doses of steroids and/or plasma exchange and/or cyclophosphamide, whereas clinically asymptomatic patients usually need no treatment, even in the presence of high cryocrit values. Careful clinical monitoring of the disease is mandatory in all cases, with particular attention to neoplastic complications.

## CONCLUSIONS

Cryoglobulinaemia is a frequent laboratory finding, often with no clinical relevance. Low concentrations of serum mixed cryoglobulins are detectable in a large number of acute or chronic infections, and in autoimmune or lymphoproliferative diseases.<sup>1 2 7–9</sup> Their presence in the course of infectious diseases can be regarded as transient insufficiency of circulating immune complex clearance; in these conditions, infectious particles or antigens can be directly involved in immune complex mediated systemic manifestations. In some instances, a persistent production of cryoimmunoglobulins and RF long after the disappearance of the eliciting agent may constitute an autonomous condition, so called essential MC.<sup>2</sup> This is an immune complex mediated systemic vasculitis caused by the deposition of cryoprecipitable circulating immune complexes.

Because of the striking association between MC and HCV infection, the term essential should be referred to in only a minority of cases.<sup>17 23 26–28</sup>

HCV related MC can be considered an interesting model of virus driven autoimmune and neoplastic disease.

For decades, cryoglobulins have fascinated investigators and clinicians. The research into this intriguing disorder weaves together the history of medicine during the last century: from the observation of a simple in vitro phenomenon<sup>100</sup> to a definite disease, cryoglobulinaemic vasculitis.<sup>7–9</sup> Finally, the striking association between MC and HCV infection,<sup>17</sup> along with the multifaceted clinical expression of this infection,<sup>27 28</sup> relaunch the challenge.

## ACKNOWLEDGEMENTS

Thanks to the following people who actively contributed to our studies mentioned in the present work: L La Civita, G Longombardo,

**Table 5** Treatment of HCV associated mixed cryoglobulinaemia

	Proposed treatments
Asymptomatic	None
Mild–moderate manifestations Purpura, weakness, arthralgias, arthritis, peripheral sensory neuropathy	Low dose steroids and/or LAC diet, other symptomatics
Severe manifestations Nephropathy, skin ulcers, sensory motor neuropathy, widespread vasculitis	Steroids, and/or plasma exchange, and/or cyclophosphamide
Active hepatitis	$\alpha$ Interferon + ribavirin
Cancer B cell NHL, HCC	Chemotherapy, surgery

\*  $\alpha$  Interferon + ribavirin.

NHL, non-Hodgkin's lymphoma; HCC, hepatocellular carcinoma; HCV, hepatitis C virus; LAC, low antigen content.

Attempt at HCV eradication\*

G Porciello, P Fadda, R Cecchetti, S Bombardieri, and G Pasero from the Rheumatology Unit, Department of Internal Medicine, University of Pisa, Italy; M Monti, C Giannini, and P Gentilini, from the Istituto Medicina Interna, University of Florence, Italy; E Sabatini, S Poggi, and M Piccioli from the Pathologic Anatomy and Haematopathology Unit, University of Bologna, Italy; F Caracciolo and M Petrini from the Cattedra di Ematologia, University of Pisa, Italy; F Greco and A Mazzoni, from the Blood Center, Ospedale S. Chiara, Pisa, Italy; S Marchi and F Costa at the Clinica Medica I, University of Pisa, Italy; P Highfield and T Corbishley from Wellcome Diagnostic, Beckenham, UK; and MP Manns from the Department of Gastroenterology and Hepatology, Zentrum Innere Medizin, Medizinische Hochschule, Hannover, Germany. This work was supported in part by MURST, AIRC, ISS, the Italian Liver Foundation and the Fondazione Istituto di Ricerca Virologica O.B. Corsi.

#### Authors' affiliations

**C Ferri**, Dipartimento di Medicina Interna, Università di Pisa, Pisa 56126, Italy

**A L Zignego**, Dipartimento di Medicina Interna, Università di Firenze, Firenze 50134, Italy

**S A Pileri**, Servizio di Anatomia Patologica ed Ematopatologia, Università di Bologna, Bologna 40100, Italy

#### REFERENCES

- 1 **Wintrobe M**, Buell M. Hyperproteinemia associated with multiple myeloma. With report of a case in which an extraordinary hyperproteinemia was associated with thrombosis of the retinal veins and symptoms suggesting Raynaud's disease. *Bulletin of the John Hopkins Hospital* 1933;**52**:156-65.
- 2 **Lospalluto J**, Dorward B, Miller W, Jr, et al. Cryoglobulinemia based on interaction between a gamma macroglobulin and 7S gamma globulin. *Am J Med* 1962;**32**:142-5.
- 3 **Middaugh CR**, Litman GW. Atypical glycosylation of an IgG monoclonal cryoimmunoglobulin. *J Biol Chem* 1987;**262**:3671-3.
- 4 **Tomana M**, Schrohenloher RE, Koopman WJ, et al. Abnormal glycosylation of serum IgG from patients with chronic inflammatory diseases. *Arthritis Rheum* 1988;**31**:333-8.
- 5 **Shlomchik M**, Mascelli M, Shan H, et al. Anti-DNA antibodies from autoimmune mice arise by clonal expansion and somatic mutation. *J Exp Med* 1990;**171**:265-92.
- 6 **Gyotoku Y**, Abdelmoula M, Spertini F, et al. Cryoglobulinemia induced by monoclonal immunoglobulin G rheumatoid factor derived from autoimmune MRL/MpJpr/lpr mice. *J Immunol* 1987;**138**:3785-92.
- 7 **Meltzer M**, Franklin EC, Elias K, et al. Cryoglobulinemia. A clinical and laboratory study. II. Cryoglobulins with rheumatoid factor activity. *Am J Med* 1966;**40**:837-56.
- 8 **Brouet JC**, Clouvet JP, Danon F, et al. Biologic and clinical significance of cryoglobulins. *Am J Med* 1974;**57**:775-88.
- 9 **Gorevic PD**, Kassab HJ, Levo Y, et al. Mixed cryoglobulinemia: clinical aspects and long-term follow-up of 40 patients. *Am J Med* 1980;**69**:287-308.
- 10 **Levo Y**, Gorevic PD, Kassab HJ, et al. Association between hepatitis B virus and essential mixed cryoglobulinemia. *N Engl J Med* 1977;**296**:1501-4.
- 11 **Bombardieri S**, Ferri C, Di Munno O, et al. Liver involvement in essential mixed cryoglobulinemia. *Ric Clin Lab* 1979;**9**:361-8.
- 12 **Gocke DJ**, Hsu K, Morgan C, et al. Association between polyarteritis and Australia antigen. *Lancet* 1970;**2**:1149-53.
- 13 **Popp JW**, Dienstag JL, Wands JR, et al. Essential mixed cryoglobulinemia without evidence for hepatitis B virus infection. *Ann Intern Med* 1980;**92**:379-83.
- 14 **Choo GL**, Kuo G, Weiner AJ, et al. Isolation of a cDNA clone derived from a blood-borne non-A non-B viral hepatitis genome. *Science* 1989;**244**:359-61.
- 15 **Pascual M**, Perrin L, Giostira E, et al. Hepatitis C virus in patients with cryoglobulinemia type II. *J Infect Dis* 1990;**162**:569-70.
- 16 **Ferri C**, Marzo E, Longombardo G, et al. Alpha-interferon in the treatment of mixed cryoglobulinemia patients. Proceedings of International Cancer Update. Focus on interferon alfa 2b. Cannes, France, November 1-4, 1990. *Eur J Cancer* 1991;**27**:81-2.
- 17 **Ferri C**, La Civita L, Longombardo G, et al. Hepatitis C virus and mixed cryoglobulinemia [review]. *Eur J Clin Invest* 1993;**23**:399-405.
- 18 **Ferri C**, Greco F, Longombardo G, et al. Association between hepatitis C virus and mixed cryoglobulinemia. *Clin Exp Rheumatol* 1991;**9**:621-4.
- 19 **Agnello V**, Chung RT, Kaplan LM. A role for hepatitis C virus infection in type II cryoglobulinemia. *N Engl J Med* 1992;**327**:1490-5.
- 20 **Ferri C**, Pileri S, Zignego AL. Hepatitis C virus, B-cell disorders, and non-Hodgkin's lymphoma. In: Goedert JJ, ed. *Infectious causes of cancer. Targets for intervention*. Totowa, New Jersey: Humana Press, 2000:349-68.
- 21 **Sansonno D**, De Vito S, Cornacchiolo V, et al. Detection and distribution of hepatitis C-related proteins in lymph nodes of patients with type II cryoglobulinemia and neoplastic or non-neoplastic lymphoproliferation. *Blood* 1996;**88**:4638-45.
- 22 **Agnello V**, Abel G. Localization of hepatitis C virus in cutaneous vasculitic lesions in patients with type II cryoglobulinemia. *Arthritis Rheum* 1997;**40**:2007-15.
- 23 **Trendelenburg M**, Schifferli JA. Cryoglobulins are not essential. *Ann Rheum Dis* 1998;**57**:3-5.
- 24 **Lunel F**, Musset L, Cacoub P, et al. Cryoglobulinemia in chronic liver diseases: role of hepatitis C virus and liver damage. *Gastroenterology* 1994;**106**:1291-300.
- 25 **Pawlotsky J**, Mustapha B, Andre C, et al. Immunological disorders in C virus chronic active hepatitis: a prospective case-control study. *Hepatology* 1994;**19**:841-8.
- 26 **Abel G**, Zhang QX, Agnello V. Hepatitis C virus infection in type II mixed cryoglobulinemia [review]. *Arthritis Rheum* 1993;**36**:1341-9.
- 27 **Ferri C**, La Civita L, Longombardo G, et al. Mixed cryoglobulinemia: a cross-road between autoimmune and lymphoproliferative disorders. *Lupus* 1998;**7**:275-9.
- 28 **Ferri C**, Zignego AL. Relation between infection and autoimmunity in mixed cryoglobulinemia. *Curr Opin Rheumatol* 2000;**12**:53-60.
- 29 **Zignego AL**, Ferri C, Giannini C, et al. Hepatitis C virus genotype analysis in patients with type II mixed cryoglobulinemia. *Ann Intern Med* 1996;**124**:31-4.
- 30 **Ossi E**, Bordin MC, Businaro MA, et al. HLA expression in type II mixed cryoglobulinemia and chronic hepatitis C virus. *Clin Exp Rheumatol* 1995;**13**(suppl 13):S91-3.
- 31 **Lenzi M**, Frisoni M, Mantovani V, et al. Haplotype HLA-B8-DR3 confers susceptibility to hepatitis C virus-related mixed cryoglobulinemia. *Blood* 1998;**91**:2062-6.
- 32 **Gumber S**, Chopra S. Hepatitis C: a multifaceted disease. Review of extrahepatic manifestations [review]. *Ann Intern Med* 1995;**123**:615-20.
- 33 **Fargion S**, Piperno A, Cappellini MD, et al. Hepatitis C virus and porphyria cutanea tarda: evidence of a strong association. *Hepatology* 1992;**16**:1322-6.
- 34 **Ferri C**, Baicchi U, La Civita L, et al. Hepatitis C virus-related autoimmunity in patients with porphyria cutanea tarda. *Eur J Clin Invest* 1993;**23**:851-5.
- 35 **Lenzi M**, Johnson PJ, McFarlane IG, et al. Antibodies to hepatitis C virus in autoimmune liver disease: evidence for geographical heterogeneity. *Lancet* 1991;**338**:277-80.
- 36 **Stehman-Breen C**, Willson R, Alpers CE, et al. Hepatitis C virus-associated glomerulonephritis. *Curr Opin Nephrol Hypertens* 1995;**4**:287-94.
- 37 **Ferri C**, Longombardo G, La Civita L, et al. Hepatitis C virus as common cause of mixed cryoglobulinemia and chronic liver disease. *J Intern Med* 1994;**236**:31-6.
- 38 **Ferri C**, La Civita L, Zignego AL, et al. Viruses and cancers: possible role of hepatitis C virus [review]. *Eur J Clin Invest* 1997;**27**:711-18.
- 39 **Antonelli A**, Ferri C, Fallahi P. Thyroid cancer in patients with hepatitis C infection. *JAMA* 1999;**281**:1588.
- 40 **Lovy MR**, Starkebaum G, Uberoi S. Hepatitis C infection presenting with rheumatic manifestations: a mimic of rheumatoid arthritis. *J Rheumatol* 1996;**23**:979-83.
- 41 **Lamprecht P**, Gause A, Gross WL. Cryoglobulinemic vasculitis [review]. *Arthritis Rheum* 1999;**42**:2507-16.
- 42 **Zignego AL**, Macchia D, Monti M, et al. Infection of peripheral mononuclear blood cells by hepatitis C virus. *J Hepatol* 1992;**15**:382-6.
- 43 **Ferri C**, Monti M, La Civita L, et al. Infection of peripheral blood mononuclear cells by hepatitis C virus in mixed cryoglobulinemia. *Blood* 1993;**82**:3701-4.
- 44 **Martell M**, Esteban JI, Quer J. Hepatitis C virus (HCV) circulates as a population of different but closely related genomes: quasispecies nature of HCV genome distribution. *J Virol* 1992;**66**:3225-9.
- 45 **Heimann R**, Lespagnard L, Dargent JL, et al. Is there a link between viral hepatitis and lymphoproliferative disorders? From the autopsy room to the PCR thermal cycler [review]. *Curr Diagn Pathol* 1996;**3**:177-81.
- 46 **Ferri C**, Caracciolo F, Zignego AL, et al. Hepatitis C virus infection in patients with non-Hodgkin's lymphoma. *Br J Haematol* 1994;**88**:392-4.
- 47 **Luppi M**, Grazia FM, Bonaccorsi G, et al. Hepatitis C virus infection in a subset of neoplastic lymphoproliferations not associated with cryoglobulinemia. *Leukemia* 1996;**10**:351-5.
- 48 **Izumi T**, Sasaki R, Tsunoda S, et al. B-cell malignancy and hepatitis C virus infection. *Leukemia* 1997;**11**:516-18.
- 49 **Zuckerman E**, Zuckerman T, Levine AM, et al. Hepatitis C virus infection in patients with B-cell non-Hodgkin's lymphoma. *Ann Intern Med* 1997;**127**:423-8.
- 50 **McColl MD**, Singer IO, Tait RC, et al. The role of hepatitis C virus in the aetiology of non-Hodgkin's lymphoma—a regional association [letter]? *Leuk Lymphoma* 1997;**26**:127-30.
- 51 **King PD**, Wilkes JD, Diaz-Arias AA. Hepatitis C virus infection in non-Hodgkin's lymphoma. *Clin Lab Haematol* 1998;**20**:107-10.
- 52 **Ferri C**, Monti M, La Civita L, et al. Hepatitis C virus infection in non-Hodgkin's B-cell lymphoma complicating mixed cryoglobulinemia. *Eur J Clin Invest* 1994;**24**:781-4.
- 53 **Pozzato G**, Mazzaro C, Crovatto M, et al. Low-grade malignant lymphoma, hepatitis C virus infection, and mixed cryoglobulinemia. *Blood* 1994;**84**:3047-53.
- 54 **Perl A**, Gorevic PD, Ryan DH, et al. Clonal B cell expansion in patients with essential mixed cryoglobulinemia. *Clin Exp Immunol* 1989;**76**:54-60.
- 55 **Monteverde A**, Rivano MT, Allegra GC, et al. Essential mixed cryoglobulinemia, type II: a manifestation of low malignant lymphoma? Clinical-morphological study of 12 cases with special reference to immunohistochemical findings in liver frozen sections. *Acta Haematol* 1988;**79**:20-5.

- 56 **Monteverde A**, Sabatini E, Poggi S, *et al*. Bone marrow findings further support the hypothesis that essential mixed cryoglobulinemia type II is characterized by a monoclonal B-cell proliferation. *Leuk Lymphoma* 1995;**20**:119–24.
- 57 **Monteverde A**, Ballarè M, Pileri S. Hepatic lymphoid aggregates in chronic hepatitis C and mixed cryoglobulinemia. *Springer Semin Immunopathol* 1997;**19**:99–110.
- 58 **Harris N**, Jaffe E, Stein H, *et al*. A revised European–American classification of lymphoid neoplasms: a proposal from the international lymphoma study group. *Blood* 1994;**84**:1361–92.
- 59 **Lai R**, Weiss LM. Hepatitis C virus and non-Hodgkin's lymphoma. *Am J Clin Pathol* 1998;**109**:508–10.
- 60 **Magalini AR**, Facchetti F, Salvi L, *et al*. Clonality of B-cells in portal lymphoid infiltrates of HCV-infected livers. *J Pathol* 1998;**185**:86–90.
- 61 **De Vita S**, De Re V, Gasparotto D, *et al*. Type II mixed cryoglobulinemia is a non-malignant B-cell disorder. Clinical and molecular findings do not support bone marrow pathologic diagnosis of low grade B-cell lymphoma. *Arthritis Rheum* 2000;**43**:94–102.
- 62 **Lennert K**, Feller AC. *Histopathology of non-Hodgkin's lymphomas (based on the updated Kiel classification)*. Berlin: Springer-Verlag, 1992.
- 63 **Zignego AL**, Giannelli F, Marrocchi F, *et al*. Frequency of bcl-2 rearrangement in patients with mixed cryoglobulinemia and HCV-positive liver diseases. *Clin Exp Rheumatol* 1997;**15**:711–12.
- 64 **Zignego AL**, Giannelli F, Marrocchi ME, *et al*. T(14;18) translocation in chronic hepatitis C virus infection. *Hepatology* 2000;**31**:474–9.
- 65 **Kitay-Cohen Y**, Amiel A, Hilzenrat N, *et al*. Bcl-2 rearrangement in patients with chronic hepatitis C associated with essential mixed cryoglobulinemia type II. *Blood* 2000;**15**:2910–12.
- 66 **Pileri P**, Uematsu Y, Campagnoli S, *et al*. Binding of hepatitis C virus to CD81. *Science* 1998;**282**:938–41.
- 67 **Korsmeyer SJ**. Bcl-2: a repressor of lymphocyte death. *Immunol Today* 1992;**13**:285–7.
- 68 **Ellis M**, Rathaus M, Amiel A, *et al*. Monoclonal lymphocyte proliferation and bcl-2 rearrangement in essential mixed cryoglobulinemia. *Eur J Clin Invest* 1995;**25**:833–7.
- 69 **Strasser A**, Harris AW, Bath ML, *et al*. Novel primitive lymphoid tumors induced in transgenic mice by cooperation between myc and bcl-2. *Nature* 1990;**348**:331–4.
- 70 **De Mitri MS**, Poussin K, Baccarini P, *et al*. HCV-associated liver cancer without cirrhosis. *Lancet* 1995;**345**:413–15.
- 71 **De Re V**, De Vita S, Marzotto A, *et al*. Pre-malignant and malignant lymphoproliferations in an HCV-infected type II mixed cryoglobulinemic patient are sequential phases of an antigen-driven pathological process. *Int J Cancer* 2000;**87**:211–16.
- 72 **Mazzaro C**, Franzin F, Tulissi P, *et al*. Regression of monoclonal B-cell expansion in patients affected by mixed cryoglobulinemia responsive to  $\alpha$ -interferon therapy. *Cancer* 1996;**77**:2604–13.
- 73 **Stolte M**. Helicobacter pylori gastritis and gastric MALT-lymphoma. *Lancet* 1992;**339**:745–6.
- 74 **Carlson SJ**, Yokoo H, Vanagunas A. Progression of gastritis to monoclonal B-cell lymphoma with resolution and recurrence following eradication of Helicobacter pylori. *JAMA* 1996;**275**:937–9.
- 75 **Hande KR**. Principles and pharmacology of chemotherapy. In: Lee GR, Foerster J, Lukens J, *et al*, eds. *Wintrobe's clinical hematology*, 10th ed. Baltimore: Williams & Wilkins, 1998:2076–101.
- 76 **Tissot JD**, Schifferli JA, Hochstrasser DF, *et al*. Two-dimensional polyacrylamide gel electrophoresis analysis of cryoglobulins and identification of an IgM-associated peptide. *J Immunol Methods* 1994;**173**:63–75.
- 77 **Gorevic PD**, Frangione B. Mixed cryoglobulinemia cross-reactive idiotypes: implication for relationship of MC to rheumatic and lymphoproliferative diseases. *Semin Hematol* 1991;**28**:79–94. Withdrawn.
- 78 **Ferri C**, Mannini L, Bartoli V, *et al*. Blood viscosity and filtration abnormalities in mixed cryoglobulinemia patients. *Clin Exp Rheumatol* 1990;**8**:271–81.
- 79 **Jennette JC**, Falk RJ, Andrassy K, *et al*. Nomenclature of systemic vasculitides: proposal of an international consensus conference. *Arthritis Rheum* 1994;**37**:187–92.
- 80 **Monti G**, Galli M, Invernizzi F, and GISC (Italian group for the study of cryoglobulinaemias). Cryoglobulinaemias: a multi-centre study of the early clinical and laboratory manifestations of primary and secondary disease. *QJM* 1995;**88**:115–26.
- 81 **Bombardieri S**, Ferri C, Migliorini P, *et al*. Cryoglobulins and immune complexes in essential mixed cryoglobulinemia. *Ric Clin Lab* 1986;**16**:281–8.
- 82 **Vitali C**, Ferri C, Nasti P, *et al*. Hypercomplementaemia as a marker of the evolution from benign to malignant B-cell proliferation in patients with type II mixed cryoglobulinemia. *Br J Rheumatol* 1994;**33**:791–2.
- 83 **Mazzaro C**, Franzin F, Tulissi P, *et al*. Regression of monoclonal B-cell expansion in patients affected by mixed cryoglobulinemia responsive to  $\alpha$ -interferon therapy. *Cancer* 1996;**77**:2604–13.
- 84 **Ferri C**, Marzo E, Longombardo G, *et al*. Alpha-interferon in mixed cryoglobulinemia patients: a randomized crossover controlled trial. *Blood* 1993;**81**:1132–6.
- 85 **Misiani R**, Bellavita P, Fenili D, *et al*. Interferon  $\alpha$ -2a therapy in cryoglobulinemia associated with hepatitis C virus. *N Engl J Med* 1994;**330**:751–6.
- 86 **Casato M**, Lagana B, Antonelli G, *et al*. Long-term results of therapy with interferon- $\alpha$  for type II essential mixed cryoglobulinemia. *Blood* 1991;**78**:3142–7.
- 87 **Di Lullo L**, De Rosa FG, Coviello R, *et al*. Interferon toxicity in hepatitis C virus-associated type II cryoglobulinemia. *Clin Exp Rheumatol* 1998;**16**:506.
- 88 **La Civita L**, Zignego AL, Lombardini F, *et al*. Exacerbation of peripheral neuropathy during alpha-interferon therapy in a patient with mixed cryoglobulinemia and hepatitis B virus infection. *J Rheumatol* 1996;**23**:1641–3.
- 89 **Lidove O**, Cacoub P, Hausfater P, *et al*. Cryoglobulinemia and hepatitis C: worsening of peripheral neuropathy after interferon  $\alpha$  treatment. *Gastroenterol Clin Biol* 1999;**23**:403–6.
- 90 **Misiani R**, Bellavita P, Baio P, *et al*. Successful treatment of HCV-associated cryoglobulinaemic glomerulonephritis with a combination of interferon- $\alpha$  and ribavirin. *Nephrol Dial Transplant* 1999;**14**:1558–60.
- 91 **Zuckerman E**, Keren D, Slobodin G, *et al*. Treatment of refractory, symptomatic, hepatitis C virus related mixed cryoglobulinemia with ribavirin and interferon- $\alpha$ . *J Rheumatol* 2000;**27**:2172–8.
- 92 **McHutchison JG**, Gordon SC, Schiff ER, *et al*. Interferon  $\alpha$ -2b alone or in combination with ribavirin as initial treatment for chronic hepatitis C. Hepatitis interventional therapy group. *N Engl J Med* 1998;**339**:1485–92.
- 93 **Abrignani S**, Rosa D. Perspectives for a hepatitis C virus vaccine. *Clin Diagn Viral* 1998;**10**:181–5.
- 94 **Ferri C**, Pietrogrande M, Cecchetti C, *et al*. Low-antigen-content diet in the treatment of mixed cryoglobulinemia patients. *Am J Med* 1989;**87**:519–24.
- 95 **Ferri C**, Moriconi L, Gremignai G, *et al*. Treatment of renal involvement in essential mixed cryoglobulinemia with prolonged plasma exchange. *Nephron* 1986;**43**:246–51.
- 96 **Moriconi L**, Ferri C, Puccini R, *et al*. Double filtration plasmapheresis in the treatment of cryoglobulinemic glomerulonephritis. *Int J Artif Organs* 1989;**12**(suppl 4):83–6.
- 97 **Ferri C**, Puccini R, Longombardo G, *et al*. Low-antigen-content diet in the treatment of patients with IgA nephropathy. *Nephrol Dial Transplant* 1993;**8**:1193–8.
- 98 **Kaplan AA**. Apheresis for renal disease. *Ther Apher* 2001;**5**:134–41.
- 99 **Heidelberger M**, Kendall F. A quantitative study of the precipitin reactions between type III pneumococcus polysaccharide and purified homologous antibody. *J Exp Med* 1929;**50**:809–23.



## Cryoglobulins

C Ferri, A L Zignego and S A Pileri

*J Clin Pathol* 2002 55: 4-13

doi:

---

Updated information and services can be found at:

<http://jcp.bmj.com/content/55/1/4.full.html>

---

### References

*These include:*

This article cites 88 articles, 24 of which can be accessed free at:

<http://jcp.bmj.com/content/55/1/4.full.html#ref-list-1>

Article cited in:

<http://jcp.bmj.com/content/55/1/4.full.html#related-urls>

### Email alerting service

Receive free email alerts when new articles cite this article. Sign up in the box at the top right corner of the online article.

---

### Notes

---

To request permissions go to:

<http://group.bmj.com/group/rights-licensing/permissions>

To order reprints go to:

<http://journals.bmj.com/cgi/reprintform>

To subscribe to BMJ go to:

<http://group.bmj.com/subscribe/>