

## ORIGINAL ARTICLE

## Conclusions from a study of venous invasion in stage IV colorectal adenocarcinoma

A Sternberg, M Amar, R Alfici, G Groisman

*J Clin Pathol* 2002;**55**:17–21

**Aims:** Venous invasion is an established predictor of prognosis in colorectal cancer (CRC). The reported incidence of venous invasion in CRC specimens varies between 10% and 89.5%, mainly as a result of interobserver variability and differences in specimen processing (for example, staining with haematoxylin and eosin (H+E) alone versus the addition of an elastic fibre stain). This study was performed with three purposes in mind, namely: (1) To assess and compare the incidence of venous invasion diagnosed on H+E stained tissue versus tissue stained with both H+E and an elastic fibre stain. (2) To estimate the inherent false negative rate associated with the diagnosis of venous invasion by histopathological evaluation of resected CRC specimens. (3) To compare the resulting data regarding incidence, quantity, site, and type of venous invasion to the pertinent literature.

**Methods:** Venous invasion was assessed on sections from 81 CRCs resected from patients with synchronous distant metastases (hepatic and non-hepatic). Only stage IV tumours were studied for the following reasons: (1) it can be assumed that in all patients with distant haematogenous metastases venous invasion had occurred, thus enabling the false negative rate to be calculated; (2) there can be no dispute about the clinical relevance of the various characteristics of venous invasion identified in the tumours of patients with synchronous distant haematogenous metastases; and (3) to eliminate the effect of variance in tumour stage on the incidence of venous invasion. Initially, H+E stained sections were studied for venous invasion. Sections that were negative or questionable with regard to venous invasion were then stained with an elastic fibre stain, and a second search for venous invasion was carried out. Venous invasion was characterised by incidence, quantity, type, and site. The  $\chi^2$  test for independence was used to compare the incidence of venous invasion in colonic versus rectal and rectosigmoid primary tumours, and in patients with hepatic versus non-hepatic metastases.

**Results:** Venous invasion was identified in 42 (51.9%) (of the 81 specimens on H+E stained sections. The addition of the elastic fibre stain enabled the diagnosis of venous invasion in 15 (38.5%) of the remaining 39 specimens, increasing the overall incidence to 57 of 81 cases (70.4%). Of the 57 positive specimens, venous invasion was minimal in 27 (47.4%), intermediate in five, (8.8%) and massive in 25 (43.9%). Only intramural veins were involved in 18 (31.6%), only extramural veins in 26 (45.6%), and both intramural and extramural veins in 13 (22.8%) of the 57 positive specimens. The filling type of venous invasion was found in 41 (71.9%), the floating type in 28 (49.1%), and the infiltrating type in six (10.5%) of the 57 positive specimens. There was no significant difference between the incidence of venous invasion in the colon (42 of 60; 70%) versus rectal and rectosigmoid tumours (15 of 21; 71.4%;  $p = 0.8539$ ), nor in the incidence of venous invasion in patients with hepatic (49 of 70; 70%) versus non-hepatic (eight of 11; 72.7%) metastases ( $p = 0.9018$ ).

**Conclusions:** The addition of an elastic fibre stain enables the identification of venous invasion in a considerable proportion of sections from CRC tumours that are falsely negative for venous invasion on H+E stain alone. The inherent chance of missing venous invasion on histopathological evaluation of CRC tumours stained with H+E and elastic fibre stains is at least 10.5%, and may be as high as 29.6%. In a large proportion of stage IV CRCs, despite the presence of synchronous distant metastases, only a minimal extent of venous invasion (that is, one to two involved veins) is demonstrable in the primary tumour. This suggests that only minimal venous invasion is required for the seeding of clinically relevant haematogenous metastases, and emphasises the careful, dedicated search for venous invasion that is required from the pathologist. Although extramural venous invasion was predominant in stage IV CRCs, in a considerable proportion of tumours (about a third) only intramural venous invasion was found. This suggests that intramural venous invasion may also seed clinically relevant haematogenous metastases, and should therefore also be considered as an indicator of poor prognosis.

See end of article for authors' affiliations

Correspondence to:  
Dr A Sternberg,  
Department of Surgery A,  
Hillel Yaffe Medical  
Center, Hadera 38100,  
Israel;  
surgery\_a@  
hillel-yaffe.health.gov.il

Accepted for publication  
6 July 2001

Venous invasion is an established predictor of prognosis in colorectal cancer (CRC). It is associated with an increased incidence of recurrence (especially visceral metastases) and decreased survival. The incidence of venous invasion is directly related to tumour stage, and inversely related to tumour differentiation. The reported incidence of venous invasion in CRC specimens varies between 10% and 89.5%.<sup>1–20</sup> To a certain extent, this variance may indicate currently unidentified inherent differences between patient populations, and it obviously reflects differences in tumour

differentiation and stage among the reported cohorts. Owing to the focal nature of vein invasion and to the non-continuous nature of the process of tumour embolism, it appears that pure chance also influences the identification of venous invasion. However, the most decisive factors influencing the identification and reporting of venous invasion are probably variations

**Abbreviations:** CRC, colorectal cancer; H+E, haematoxylin and eosin

in specimen processing (for example, staining with Meyer's haematoxylin and eosin (H+E) alone versus the addition of elastic fibre stain) and in the awareness and dedication of the pathologist involved.

"The incidence of venous invasion is directly related to tumour stage, and inversely related to tumour differentiation"

Because of the element of chance mentioned previously, and the destruction of some of the involved veins beyond recognition, the identification of venous invasion by histopathological evaluation of resected colorectal tumours has an inherent (and probably peremptory) false negative rate.

Our histopathological study was performed with three purposes in mind, namely:

(1) To assess and compare the incidence of venous invasion diagnosed on H+E stained tissue compared with tissue stained with both H+E and an elastic fibre stain.

(2) To estimate the inherent false-negative rate associated with the diagnosis of venous invasion by histopathological evaluation of resected CRC specimens.

(3) To compare our data regarding incidence, quantity, site, and type of venous invasion with data reported in the pertinent recent literature.

We chose to study only tumours of patients with stage IV disease for the following reasons: (1) we may assume that venous invasion had occurred in all patients with synchronous distant haematogenous metastases, thus enabling the false negative rate to be calculated; (2) there can be no dispute as to the clinical relevance of the various characteristics of venous invasion identified in the tumours of patients with synchronous distant haematogenous metastases; (3) the effect of variance in tumour stage on the incidence of venous invasion will be eliminated in these patients.

There is no apparent reason why the findings and conclusions from this study should not be applicable to patients with colorectal tumours of any stage.

## PATIENTS AND METHODS

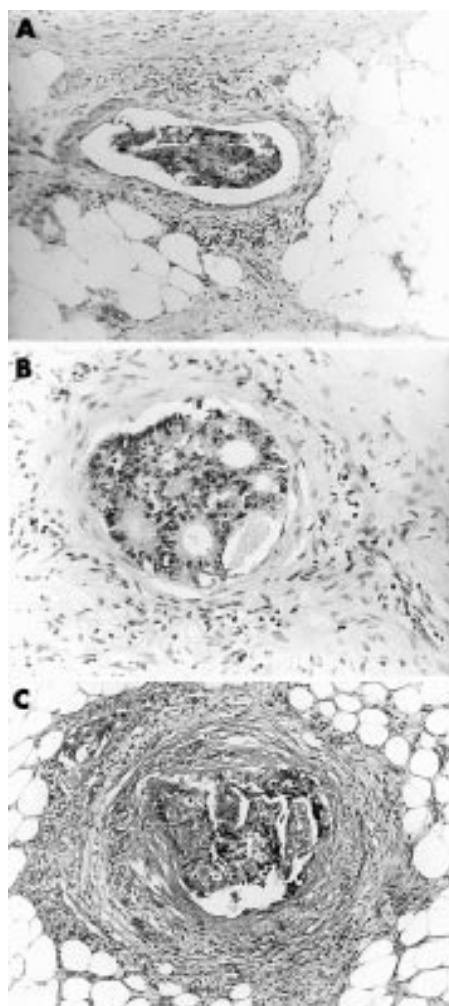
During the period 1988–97 we performed 81 palliative tumour resections in patients with CRC with synchronous distant metastases. Review and analysis of the clinical and histological data of these patients constitute the basis for our study.

### Characteristics of the studied cohort

Locations of the primary tumours: rectum, 12; rectosigmoid, nine; sigmoid, 27; all other colonic sites, 33. Locations of documented distant metastases: liver, 70; peritoneum, 18; lung, four; ovary, four; bone, three; skin, breast, adrenal, spleen, and kidney, one each. Nineteen patients had confirmed distant metastases in multiple sites.

### Specimen processing

CRC specimens were opened, washed, and fixed in 10% formaldehyde solution. After macroscopic description and measurement of the specimen, the tumour and the longitudinal resection margins, four to seven (mean, five) representative sections from the primary tumour were submitted for microscopic examination. Tangential sections from the periphery of the tumour, sections from the deepest point of tumour penetration, and from the area of transition between tumour and non-tumoral mucosa were studied in all cases. Specimens were also submitted from the proximal, distal, and radial resection margins. Mesocolic and mesorectal lymph nodes were identified and harvested by the manual dissection technique, without chemical clearing of mesocolic fat, and were submitted for microscopic evaluation. Mesocolic blood vessels were also trimmed for histological evaluation.



**Figure 1** Types of venous invasion identified in tissue sections stained by haematoxylin and eosin (H+E) alone. (A) Floating type (H+E; original magnification,  $\times 40$ ); (B) filling type (H+E; original magnification,  $\times 100$ ); (C) combined infiltrating and filling types (H+E; original magnification,  $\times 40$ ).

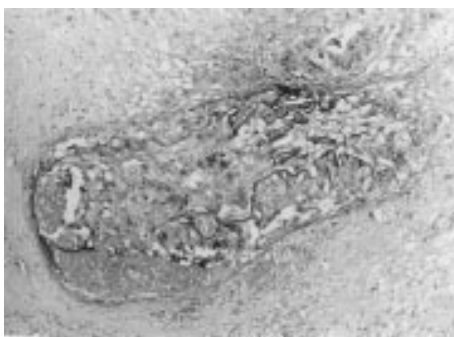
All sections were fixed in formalin, embedded in paraffin wax, and stained with Meyer's H+E.

The microscopic diagnosis of venous invasion on H+E stained tissue was based on the identification of tumour cells within an endothelium lined space, surrounded by a rim of smooth muscle, and/or containing red blood cells. When present, an adjacent artery of similar size verified that the involved vascular structure was indeed a vein.

H+E stained sections in which venous invasion was not identified or was questionable were stained with Weigert's stain for elastic fibres, and a second search for venous invasion was carried out.

The extent of venous invasion (minimal, one to two involved veins; intermediate, three to four involved veins; massive, five or more involved veins), and the anatomical sites of the involved veins (intramural, extramural, or both) were recorded. Venous invasion was classified into three types: (1) filling, when tumour cells filled the vascular lumen; (2) floating, when tumour cells were located in the centre of the vascular lumen; and (3) infiltrating, when tumour cells were seen infiltrating the wall of the vessel. Combinations of the various types of venous invasion are common (fig 1A–C).

All specimens were independently evaluated by two senior pathologists (MA and GG), who then compared their results



**Figure 2** A small vein with combined infiltrating and filling types of venous invasion, not identified by haematoxylin and eosin (H+E) stain alone, but clearly demonstrated after the addition of an elastic fibre stain (H+E and elastic stain; original magnification,  $\times 40$ ).

**Table 1** The types and combinations of types of venous invasion in the 57 positive specimens

Type(s) of venous invasion	Number (%)
Filling	25 (43.9)
Floating	14 (24.6)
Infiltrating	1 (1.8)
Filling + floating	12 (21.1)
Filling + infiltrating	3 (5.3)
Floating + infiltrating	1 (1.8)
Filling + floating + infiltrating	1 (1.8)
Total	57
All specimens with the filling type	41 (71.9)
All specimens with the floating type	28 (49.1)
All specimens with the infiltrating type	6 (10.5)

and jointly reviewed questionable sections. Only cases on which they both agreed were listed as positive for venous invasion.

### Statistical analysis

The  $\chi^2$  test for independence was used to compare the incidence of venous invasion in the colon with rectal and rectosigmoid tumours, and to compare patients with hepatic versus non-hepatic metastases. A p value < 0.05 was considered to be significant.

### RESULTS

Venous invasion was found in 42 (51.9%) of the 81 specimens on sections stained with H+E only. The addition of an elastic fibre stain enabled the identification of venous invasion in 15 (38.5%) of the remaining 39 specimens, in which venous invasion had not been evident by H+E stain only (fig 2), bringing the total incidence of venous invasion in this cohort to 70.4% (51.9% by H+E alone, 18.5% by H+E and elastic fibre stain).

Overall, the extent of venous invasion was minimal in 27 (47.4%), intermediate in five (8.8%), and massive in 25 (43.9%) of the 57 positive specimens. The respective rates for venous invasion identified on H+E stain alone were: 48.6%, 5.7%, and 45.7%, whereas the respective figures for venous invasion identified after the addition of an elastic fibre stain were: 46.2%, 15.4%, and 38.5%.

Venous invasion was identified only in intramural veins in 18 (31.6%), only in extramural veins in 26 (45.6%), and in both intramural and extramural veins in 13 (22.8%) of the 57 positive specimens.

Table 1 presents the types of venous invasion (and combinations of types) identified in the 57 positive specimens.

Overall (alone and in combination), the filling type of venous invasion was found in 41 (71.9%), the floating type was seen in 28 (49.1%), and the infiltrating type was seen in six (10.5%) of the 57 positive specimens.

There was no significant difference between the incidence of venous invasion in colonic tumours (42 of 60) and in rectal and rectosigmoid tumours (15 of 21; 71.4%; p = 0.8539). Similarly, there was no significant difference between the incidence of venous invasion in patients with documented liver metastases (alone or combined with other metastatic sites) (49 of 70; 70%) and the incidence of venous invasion in patients with non-hepatic stage IV tumours (eight of 11; 72.7%; p = 0.9018).

### DISCUSSION

A study of venous invasion in stage IV CRC solely has not been reported in recent years. However, of the 61 patients with CRC studied by Ouchi *et al*, 19 had synchronous liver metastases,<sup>19</sup> and 18 of the 103 patients reported by Dirschmid *et al* had stage IV tumours, 12 of them with synchronous liver metastases.<sup>20</sup> The data from these authors can be meaningfully compared with ours.

Dirschmid *et al* found venous invasion in 13 (72.2%) of 18 patients with Dukes's stage D disease, and in 10 (83.3%) of the 12 patients in whom the distant metastases were hepatic.<sup>20</sup> Our data indicate that the incidence of venous invasion associated with hepatic versus non-hepatic metastases is not significantly different. Inoue *et al* identified venous invasion in 30 (61.2%) of 49 patients with CRC who had died within two years of potentially curative resection; the incidence of venous invasion increased to 26 of 32 (81.3%) when they looked only at those patients who had documented evidence of haematogenous metastases.<sup>18</sup> Ouchi *et al* found venous invasion in 17 (89.5%) of 19 patients with CRC who had synchronous liver metastases. This is the highest reported incidence of venous invasion in CRC, and the authors attribute it to the routine use of elastic fibre stains.<sup>19</sup> Minsky and colleagues<sup>14, 15</sup> and Dirschmid and colleagues<sup>20</sup> also routinely use the elastic fibre stain to differentiate between lymph vessels and veins. Inoue *et al* conclude that the elastic fibre stain increases the incidence of diagnosing venous invasion when compared with the use of H+E alone.<sup>18</sup> Conversely, Talbot *et al* report that the various elastic tissue stains that they used were rarely found to be helpful.<sup>10, 12</sup> Horn *et al* also do not use an elastic fibre stain.<sup>16, 17</sup>

Our findings support the proponents of elastic fibre stain. We found that the addition of an elastic fibre stain to H+E staining not only enabled the identification of venous invasion in 38.5% of the sections that were falsely negative for venous invasion by H+E alone, but that it greatly facilitated the pathologist's search for venous invasion, shortened the time required for the histopathological evaluation of the tissue sections, and prevented false negative and false positive diagnoses of venous invasion in some of the cases that were questionable or unrecognisable by the H+E stain alone (for example, identification of elastic fibres of veins destroyed beyond recognition by infiltrating/filling venous invasion, that are easily missed on H+E stain alone; and lymphatic invasion, which in some instances can be falsely mistaken for venous invasion).

Inoue *et al* have shown that factor VIII related antigen is not a good stain for identifying venous invasion, possibly because the endothelium of involved veins is destroyed.<sup>18</sup>

"Some veins are destroyed beyond recognition by the invading tumour cells"

Assuming that haematogenous spread has occurred in all patients who present with synchronous distant metastases,

and that access to the bloodstream is by invasion of veins by tumour cells, the inherent chance of missing venous invasion during histological evaluation of the primary tumour (using both H+E and elastic fibre stains) is 10.5%, according to Ouchi *et al.*<sup>19</sup> and 29.6%, according to our data. (Inoue and colleagues<sup>18</sup> and Dirschmid and colleagues<sup>20</sup> found intermediate rates.) Because the data of Ouchi *et al.* are based on 19 patients only, we believe it is reasonable to conclude that the inherent chance of missing venous invasion on histological examination of primary colorectal tumours is at least 10.5%, and is possibly as high as 29.6%.

We believe that the main reason that there is an inherent false negative rate with regard to the identification of intramural venous invasion is that some veins are destroyed beyond recognition by the invading tumour cells. This is more likely to occur in small, thin walled veins (such as intramural veins) than in larger veins with thicker walls (such as extramural veins). Owing to the larger circumference of the extramural tissues, we believe that false negative diagnoses regarding extramural venous invasion are mainly the result of sampling errors. Talbot and colleagues<sup>10</sup> and Dirschmid and colleagues<sup>20</sup> emphasise the importance of cutting multiple tangential blocks from the periphery of the tumour to facilitate the diagnosis of extramural venous invasion. The number of blocks is directly related to the size of the tumour; therefore, minimum standards for declaring a specimen negative for venous invasion have not been clearly defined in the literature.

Both in our data and in those of Ouchi *et al.*<sup>19</sup> only minimal venous invasion was demonstrable in 27 of 57 (47.4%) and in eight of 17 (47.1%), respectively, of the tumours from patients with synchronous distant metastases in whom venous invasion was identified. This suggests that only minimal venous invasion is required for the seeding of clinically important distant metastases, and emphasises the careful and dedicated effort required from the pathologist when evaluating CRC specimens for the presence of venous invasion. Although the number of cases is small, our data indicate that the addition of an elastic fibre stain to staining with H+E triples the rate of detection of intermediate venous invasion, whereas the rate of detection of massive venous invasion decreases. Neither Talbot *et al.*<sup>10-12</sup> Dirschmid *et al.*<sup>20</sup> Inoue *et al.*<sup>18</sup> Horn *et al.*<sup>16, 17</sup> nor Minsky and colleagues<sup>14, 15</sup> refer to the extent of venous invasion. Our present study cannot indicate whether the extent of venous invasion has an effect on the chances of development of clinically relevant distant metastases; therefore, we cannot state whether the extent of venous invasion should be regarded as an indicator of prognosis and reported routinely.

Similar to Ouchi *et al.*<sup>19</sup> we found a predominance of extramural venous invasion in stage IV CRC. According to the those authors, Talbot *et al.*<sup>10-12</sup> and Dirschmid *et al.*<sup>20</sup> extramural venous invasion is predominant in other stages of colorectal cancer also. Conversely, Minsky *et al.* found a predominance of intramural venous invasion.<sup>14, 15</sup> Inoue *et al.*<sup>18</sup> like Talbot *et al.*<sup>10-12</sup> conclude that extramural venous invasion is an indicator of poor prognosis. Because only intramural venous invasion was demonstrable in about a third of our patients (all with synchronous distant metastases), intramural venous invasion may also seed clinically relevant haematogenous metastases, and should therefore also be regarded as an indicator of poor prognosis. Consequently, the diagnosis of venous invasion per se should suffice as an indicator of the risk of haematogenous metastases, irrespective of the site of venous invasion.

With regard to the type of venous invasion, we used a terminology that is similar to that of Ouchi *et al.*<sup>19</sup> and like them we found a preponderance of the filling type (71.9%); the floating type was the second most prevalent (49.1%). Destruction of involved veins beyond recognition (especially those with the combined infiltrating and filling type of venous invasion) is possibly the reason that the infiltrating type is the

### Take home messages

- The addition of an elastic fibre stain enables the identification of venous invasion in a large proportion of colorectal carcinomas that are falsely negative on haematoxylin and eosin alone
- It is probable that only minimal venous invasion is needed to seed clinically important distant metastases
- Both extramural and intramural venous invasion may seed clinically important haematogenous metastases

least prevalent of the various types of venous invasion, and it is probably the main reason that venous invasion is not diagnosable in all tumours in which it has occurred.

Talbot *et al.* stress the prognostic relevance of the thickness of the wall of the involved vein.<sup>10-12</sup> Because of the largely subjective nature of this criterion, we decided against examining wall thickness in our present study. Another prognostic indicator stressed by these authors is the interface between the invading tumour cells and the bloodstream. Their data indicate that direct contact adversely affects prognosis, whereas a thrombus cap or endothelial cell mantle exerts a protective influence. This makes sense if we assume that the establishment of distant, haematogenous metastases is dependent on embolism of free floating tumour cells.

From a clinical/therapeutic standpoint, the application of these findings is in two areas: staging and adjuvant treatment of CRC. Venous invasion may be used to enhance the power of existing staging systems as predictors of individual prognosis by subdividing stages according to the presence or absence of venous invasion,<sup>21</sup> or it may be combined with other variables to form a completely new classification of CRC.<sup>22</sup> According to the National Institutes of Health consensus statement on adjuvant treatment of CRC, regional lymph node status is currently the main indicator for the administration of systemic adjuvant treatment.<sup>23</sup> Dirschmid *et al.*<sup>20</sup> Horn *et al.*<sup>16, 17</sup> and Blumberg and colleagues<sup>24</sup> recommend considering venous invasion as an indicator for the administration of systemic adjuvant treatment. Based on our study of 231 consecutive curatively resected patients with CRC,<sup>22</sup> in which we found that distant metastases developed in 50% of the venous invasion positive patients, and in only 36% of the node-positive patients, we are inclined to agree with these authors.

### CONCLUSIONS

(1) Although most instances of venous invasion in CRC can be identified on H+E stained tissue sections (in our study, 51.9%), the addition of an elastic fibre stain enables the identification of venous invasion in a large proportion of the sections that are falsely negative on H+E stain alone (in our study, 38.5%). By the addition of an elastic fibre stain the incidence of venous invasion in our present study was increased to 70.4%. This suggests that an elastic fibre stain should be used before declaring a CRC specimen negative for venous invasion.

(2) The inherent chance of missing venous invasion on histological evaluation of resected CRC specimens stained with H+E and elastic tissue stains is at least 10.5% (according to Ouchi *et al.*<sup>19</sup> and may be as high as 29.6% (according to our data).

(3) In a considerable proportion of stage IV CRCs only a minimal extent of venous invasion (one to two involved veins) is demonstrable in the resected primary tumour. This suggests that only minimal venous invasion is required to seed clinically important distant metastases. If venous invasion is regarded as an indicator for the administration of adjuvant systemic treatment, this finding also emphasises the careful, dedicated work required from the pathologist in the evaluation of CRC specimens of all stages for the presence of venous invasion.

(4) Although extramural venous invasion was predominant in stage IV CRCs, in a considerable proportion of tumours (about a third) only intramural venous invasion was found. This finding suggests that intramural venous invasion may also seed clinically important haematogenous metastases, and should therefore also be considered as an indicator of poor prognosis.

#### ACKNOWLEDGEMENT

The authors thank Dr Y Villa, of the Faculty of Mathematics, Tel Aviv University, for the statistical analysis in this study.

.....

#### Authors' affiliations

**A Sternberg, R Alfici**, Department of Surgery, Hillel Yaffe Medical Center, Hadera, and the Bruce Rappaport School of Medicine, The Technion, Haifa, Israel

**M Amar, G Groisman**, Department of Pathology, Hillel Yaffe Medical Center, Hadera, and the Bruce Rappaport School of Medicine

#### REFERENCES

- Brown CE**, Warren S. Visceral metastasis from rectal carcinoma. *Surg Gynecol Obstet* 1938;**66**:611–21.
- Dukes CE**, Bussey HJR. Venous spread in rectal cancer. *Proceedings of the Royal Society of Medicine* 1941;**34**:571–81.
- Sunderland DA**. The significance of vein invasion by cancer of the rectum and sigmoid: a microscopic study of 210 cases. *Cancer* 1949;**2**:429–37.
- Grinnell RS**. Lymphatic metastases of carcinoma of the colon and rectum. *Ann Surg* 1950;**131**:494–506.
- Dukes CE**, Bussey HJR. The spread of rectal cancer and its effect on prognosis. *Br J Cancer* 1958;**12**:309–20.
- Moore G**, Sako K. The spread of carcinoma of the colon and rectum: a study of invasion of blood vessels, lymph nodes and the peritoneum by tumor cells. *Dis Colon Rectum* 1959;**2**:92–7.
- Swinton NW**. Cancer of the colon and rectum: a statistical study of 608 patients. *Surg Clin North Am* 1959;**39**:745–53.
- Spratt JS, Jr**, Spjut HJ. Prevalence and prognosis of individual, clinic and pathologic variables associated with colorectal carcinoma. *Cancer* 1967;**20**:1976–85.
- Copeland EM**, Miller LD, Jones RS. Prognostic factors in carcinoma of the colon and rectum. *Am J Surg* 1968;**116**:875–81.
- Talbot IC**, Ritchie S, Leighton MH, *et al*. The clinical significance of invasion of veins by rectal cancer. *Br J Surg* 1980;**67**:439–42.
- Talbot IC**, Ritchie S, Leighton MH, *et al*. Spread of rectal cancer within veins. Histologic features and clinical significance. *Am J Surg* 1981;**141**:15–17.
- Talbot IC**, Ritchie S, Leighton MH, *et al*. Invasion of veins by carcinoma of rectum: method of detection, histological features and significance. *Histopathology* 1981;**5**:141–63.
- Steinberg SM**, Barkin JS, Kaplan RS, *et al*. Prognostic indicators of colon tumors. The gastrointestinal tumor study group experience. *Cancer* 1986;**57**:1866–70.
- Minsky BD**, Mies C, Recht A, *et al*. Resectable adenocarcinoma of the rectosigmoid and rectum: the influence of blood vessel invasion. *Cancer* 1988;**61**:1417–24.
- Minsky BD**, Mies C, Rich TA, *et al*. Potentially curative surgery of colon cancer: 2. The influence of blood vessel invasion. *J Clin Oncol* 1988;**6**:119–27.
- Horn A**, Dahl O, Morild I. The role of venous and neural invasion on survival in rectal adenocarcinoma. *Dis Colon Rectum* 1990;**33**:598–601.
- Horn A**, Dahl O, Morild I. Venous and neural invasion as predictors of recurrence in rectal adenocarcinoma. *Dis Colon Rectum* 1991;**34**:798–804.
- Inoue T**, Mori M, Shimono R, *et al*. Vascular invasion of colorectal carcinoma readily visible with certain stains. *Dis Colon Rectum* 1992;**35**:34–9.
- Ouchi K**, Sugawara T, Ono H, *et al*. Histologic features and clinical significance of venous invasion in colorectal carcinoma with hepatic metastases. *Cancer* 1996;**78**:2313–17.
- Dirschmid K**, Lang A, Mathis G, *et al*. Incidence of extramural venous invasion in colorectal carcinoma: findings with a new technique. *Hum Pathol* 1996;**27**:1227–30.
- Sternberg A**, Sibirsky O, Cohen D, *et al*. New approach to the sub staging of node-positive colorectal adenocarcinoma. *Ann Surg Oncol* 1999;**6**:161–5.
- Sternberg A**, Sibirsky O, Cohen D, *et al*. Validation of a new classification system for curatively resected colorectal adenocarcinoma. *Cancer* 1999;**86**:782–92.
- National Institutes of Health Consensus Development Statement**. Adjuvant therapy for patients with colon and rectal cancer. *JAMA* 1990;**264**:1444–50.
- Blumberg D**, Paty PB, Picon AI, *et al*. Stage I rectal cancer: identification of high-risk patients. *J Am Coll Surg* 1998;**186**:574–80.



## Conclusions from a study of venous invasion in stage IV colorectal adenocarcinoma

A Sternberg, M Amar, R Alfici, et al.

*J Clin Pathol* 2002 55: 17-21

doi:

---

Updated information and services can be found at:

<http://jcp.bmj.com/content/55/1/17.full.html>

---

### References

*These include:*

This article cites 23 articles, 2 of which can be accessed free at:

<http://jcp.bmj.com/content/55/1/17.full.html#ref-list-1>

Article cited in:

<http://jcp.bmj.com/content/55/1/17.full.html#related-urls>

### Email alerting service

Receive free email alerts when new articles cite this article. Sign up in the box at the top right corner of the online article.

---

### Topic Collections

Articles on similar topics can be found in the following collections

[Colon cancer](#) (146 articles)

---

### Notes

---

To request permissions go to:

<http://group.bmj.com/group/rights-licensing/permissions>

To order reprints go to:

<http://journals.bmj.com/cgi/reprintform>

To subscribe to BMJ go to:

<http://group.bmj.com/subscribe/>