

Short reports

Angiosarcoma arising from skeletal haemangiomas in an atomic bomb survivor

T Yamamoto, Y Iwasaki, M Kurosaka, R Minami

Abstract

The authors report a unique case in which an angiosarcoma arose from skeletal haemangiomas in a 72 year old man. This patient had a history of atomic bomb irradiation more than 50 years ago. Radiographically, the patient had multiple sclerotic foci of benign haemangiomas in the pelvis, the sacrum, and the left femur. The patient developed a high grade angiosarcoma in the left pubic bone. It is thought that atomic bomb irradiation played an important role in the development of the malignant lesion.

(*J Clin Pathol* 2001;54:716-717)

Keywords: angiosarcoma; haemangioma; atomic bomb

Malignant transformation of benign haemangiomas is rare. We describe a patient with skeletal haemangiomas who developed a secondary angiosarcoma in the pelvis.

Case report

In March 1996, a 72 year old Japanese man presented with a five month history of left hip pain. This patient had been exposed to atomic bomb irradiation at Hiroshima near the end of the Second World War. His medical history included diabetes mellitus, liver cirrhosis, and colon polyps. The patient underwent colon polypectomy at 71 years of age. On admission, radiographs of the pelvis revealed multiple sclerotic foci in iliums, the sacrum, and left proximal femur, and an extensive osteolytic lesion in the left pubic bone (fig 1). Computed

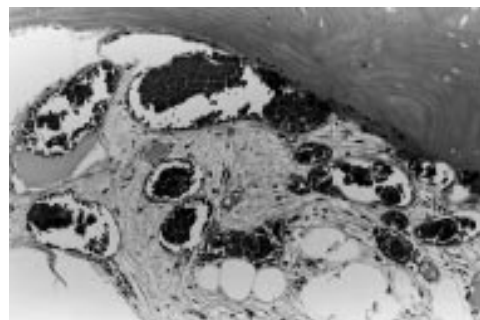


Figure 2 Specimens obtained from the left ilium showed benign cavernous haemangiomas of bone (haematoxylin and eosin stained).

tomography showed multiple irregular osteosclerosis in the pelvis. A ^{99m}technetium scintigraphic scan showed increased uptake only in the left pubic bone. A systemic investigation failed to find other lesions. The patient subsequently underwent an open biopsy. Specimens obtained from the sclerotic area of the left ilium consisted of sclerotic bony trabeculi and cavernous haemangiomas (fig 2). Specimens obtained from the left pubic bone were composed of spindle pleomorphic cells with nuclear atypia and massive interstitial haemorrhage (fig 3). A pronounced vascular formation lined by the atypical cells was noted. Mitotic figures were common (7-8/10 high power fields). The cells were found to have positive immunoreactivity for factor VIII associated antigen (using a monoclonal antibody from Dako Japan, Kyoto, Japan). Based on the radiographic and histological findings, a diagnosis of angiosarcoma arising from benign

Department of Orthopaedic Surgery, Kobe University School of Medicine, 7-5-1 Kusunoki-cho, Chuo-ku, Kobe 650-0017, Japan
T Yamamoto
Y Iwasaki
M Kurosaka

Department of Pathology, Kobe University School of Medicine
R Minami

Correspondence to: Dr Yamamoto
yamatetu@med.kobe-u.ac.jp

Accepted for publication 16 February 2001

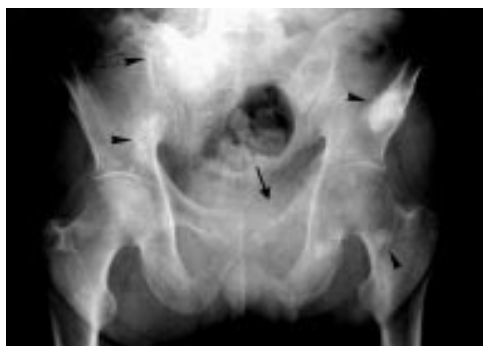

Figure 1 Anteroposterior radiograph of the pelvis in a 72 year old atomic bomb survivor shows the multiple sclerotic foci of haemangiomas (arrowheads) and an extensive osteolytic lesion in the left pubic bone (arrow). Biopsy specimens obtained from the pubic bone revealed a high grade angiosarcoma.

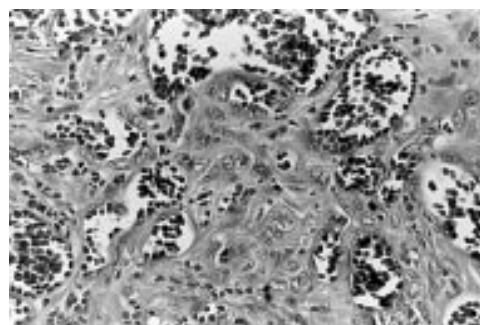


Figure 3 Specimens obtained from the left pubic bone showed a high grade angiosarcoma. There were numerous blood filled spaces lined by atypical, large cells (haematoxylin and eosin stained). Immunohistochemical study confirmed positivity of the cells for factor VIII associated antigen.

haemangiomas was made. Despite intensive chemotherapy and 50 Gy of irradiation, the tumour continued to increase in size. The patient died of massive retroperitoneal bleeding in April 1997. Radiographic changes in multiple sclerotic areas concordant with haemangiomas were not seen until the patient's death.

Discussion

Atomic bomb survivors are known to have a high risk of developing various malignant and benign tumours. A significant excess risk for cancers of the digestive system, breast, gastrointestinal tract, lung, skin, liver, ovary, urinary bladder, and other organs has been demonstrated.¹ Sarcomas with a haematopoietic origin, such as leukaemia, lymphoma, and multiple myeloma are also frequently seen in atomic bomb survivors.² Malignant bone tumours in these patients are less common.³ In addition, the incidence of non-cancer diseases such as liver cirrhosis and myocardial infarction is increased.⁴ Our patient had a medical history of liver cirrhosis and colon polyps.

Skeletal haemangiomas is recognised as a rare, congenital, or developmental disorder. It is defined as multiple haemangiomas lesions that involve two or more non-contiguous osseous sites.⁵ Skeletal haemangiomas can be associated with cutaneous, soft tissue and/or visceral haemangiomas. The histological findings are identical to capillary and cavernous haemangiomas of other sites. Patients with systemic haemangiomas have high morbidity because of massive bleeding; however, the prognosis for patients with haemangiomas confined to the bone is more favourable.⁵ Some patients with skeletal haemangiomas develop local pain and deformity, but others are asymptomatic. Radiographs of skeletal haemangiomas show mixed osteolytic and osteoblastic to pure osteoblastic lesions in the axial and appendicular bones.^{5,6}

Our patient had a benign haemangiomas confined to the bone. De novo angiosarcomatous transformation from skeletal haemangiomas is extremely unusual. To our knowledge, only one such case, reported by Wallis *et al* in 1964, has been published.⁶ They reported a 31 year old woman with diffuse skeletal haemangiomas who developed malignant lesions in the pelvis. In contrast, angiosarcomas arising from cutaneous haemangiomas in Maffucci and Kasabach-Merritt syndromes have occasionally been described in the literature.^{7,8}

However, it should be remembered that there is a close association between irradiation and the occurrence of angiosarcoma. There

have been some reports on secondary angiosarcomas developing from benign haemangiomas that had previously been treated by irradiation.⁹

Furthermore, several cutaneous angiosarcomas have occurred in patients who have been treated for malignant lesions with therapeutic irradiation. These most commonly occur in patients with uterine cervix and breast carcinomas. Secondary cutaneous angiosarcomas often arise on the skin in the anterior abdominal wall and mastectomy scars. They usually develop many years after initial radiotherapy. However, osseous angiosarcoma secondary to therapeutic irradiation has been described infrequently. The most common radiation induced sarcoma of bone is osteogenic sarcoma.¹⁰

The differential diagnosis of our present case includes epithelioid haemangioendothelioma of bone. This disease occurs in multiple osseous sites. Histologically, epithelioid haemangioendothelioma is characterised by the presence of epithelioid endothelial cells. Cytoplasmic vacuoles of various sizes are reported to be present in all cases. Signet ring cell-like structures also are identified in most epithelioid haemangioendotheliomas. These pathological findings were not found in our case.

Our patient developed a secondary angiosarcoma from a benign skeletal haemangiomas more than 50 years after being exposed to irradiation from the atomic bomb. Because of the patient's clinical history and the rarity of de novo malignant transformation of skeletal haemangiomas, we believe that the radiation played an important role in the development of the malignant lesion. A careful search of the literature revealed no similar reports.

- 1 Ron E, Preston DL, Mabuchi K, *et al*. Cancer incidence in atomic bomb survivors. Part IV: comparison of cancer incidence and mortality. *Radiat Res* 1994;137(suppl 2):98-112.
- 2 Preston, DL, Kusumi S, Tomonaga M, *et al*. Cancer incidence in atomic bomb survivors. Part III: leukemia, lymphoma and multiple myeloma. *Radiat Res* 1994; 137(suppl 2):68-97.
- 3 Yamamoto T, Wakabayashi T. Bone tumors among the atomic bomb survivors of Hiroshima and Nagasaki. *Acta Pathol Jpn* 1969;19:201-12.
- 4 Wong FL, Yamada M, Sasaki H, *et al*. Noncancer disease incidence in the atomic bomb survivors: 1958-1986. *Radiat Res* 1993;135:418-30.
- 5 Mirra JM. Hemangiomas of bone. In: Mirra JM, ed. *Bone tumors. Clinical, radiologic, and pathologic correlations*. Philadelphia: Lea and Febiger, 1989:1370-81.
- 6 Wallis LA, Asch T, Maisel BW. Diffuse skeletal hemangiomas. Report of two cases and review of literature. *Am J Med* 1964;37:545-63.
- 7 Bach CD, Walgenbach KJ, Horch RE. Hemangiosarcoma of the left hand in a patient with the rare combination of Maffucci's and Stewart Treves syndrome. *Vasa* 2000;29:71-3.
- 8 Mazzocchi A, Foschini MP, Marconi F, *et al*. Kasabach-Merritt syndrome associated to angiosarcoma of the breast. A case report and review of the literature. *Tumori* 1993;79: 137-40.
- 9 Costello SA, Seywright M. Postirradiation malignant transformation in benign hemangioma. *Eur J Surg Oncol* 1990;16:517-19.
- 10 Chan LL, Czerniak BA, Ginsberg LE. Radiation-induced osteosarcoma after bilateral childhood retinoblastoma. *Am J Roentgenol* 2000;174:1288.



Angiosarcoma arising from skeletal haemangiomatosis in an atomic bomb survivor

T Yamamoto, Y Iwasaki, M Kurosaka, et al.

J Clin Pathol 2001 54: 716-717

doi:

Updated information and services can be found at:

<http://jcp.bmj.com/content/54/9/716.full.html>

These include:

References

This article cites 9 articles, 1 of which can be accessed free at:

<http://jcp.bmj.com/content/54/9/716.full.html#ref-list-1>

Email alerting service

Receive free email alerts when new articles cite this article. Sign up in the box at the top right corner of the online article.

Notes

To request permissions go to:

<http://group.bmj.com/group/rights-licensing/permissions>

To order reprints go to:

<http://journals.bmj.com/cgi/reprintform>

To subscribe to BMJ go to:

<http://group.bmj.com/subscribe/>