

## Leaders



### Best Practice No 164

## Necropsy techniques in ophthalmic pathology

M A Parsons, R D Start

### Abstract

**Much important information can be obtained at necropsy by the pathological examination of the eye and its adnexal structures in adults and children. This information may be related to the cause of death (for example, violent shaking trauma in physical child abuse), or may pertain to disease processes affecting the eye, the orbit, and surrounding structures outside the orbit. This article reviews the technical methods used to remove the following: the vitreous (for example, for biochemistry); the eye itself (anterior approach); the eye and orbital contents (posterior approach); the eye, orbit and orbital walls; and the eye, orbital walls, and surrounding structures. The removal of the eye and adnexal ocular structures must be recognised as a “culturally sensitive” issue, which must be approached cautiously. It should only be undertaken for sound scientific reasons, with the fully informed consent of the relatives and/or the coroner (or equivalent authority), and with properly agreed procedures for the eventual retention or disposal of the ocular tissues. For this reason, this article reviews not only the scientific indications and methods for the removal of such tissues, but also the legal and ethical issues that must underpin this pathology “best practice”.**

(*J Clin Pathol* 2001;54:417-427)

Keywords: necropsy; ophthalmic pathology; enucleation

The eye and its adnexal structures can be affected by primary ophthalmic disease and diseases outside the eye, by direct extension from adjacent structures, or by secondary involvement in malignant or non-malignant systemic diseases. Some of these diseases are relatively common, and the pathology is well known; other diseases are rare, or their pathology is poorly understood. In some common

conditions there is little opportunity to examine human tissues because the conditions may not require biopsy, surgical intervention, or enucleation of the eye. For example, the opportunity to examine eyes in the early stages of documented primary open angle glaucoma (the most common form of glaucoma) very rarely occurs, except when:

- The eye is removed for incidental disease—for example, primary ocular malignancy.
- The patient dies relatively young as a result of accident or disease, and when the eyes are removed at necropsy.

Therefore, a valuable research opportunity may be missed if the eyes are not removed for examination.

Many of the patients who die of non-ophthalmic diseases and undergo necropsy have had ocular surgery, laser treatment, or other forms of management of primary or secondary ocular disease. Some patients may have systemic diseases that affect the eyes, or unsuspected or unreported eye disease. Examination of the eye at necropsy provides potentially important feedback to ophthalmic practitioners as part of the process of clinical audit<sup>1,2</sup>; this examination allows assessment of the accuracy of diagnosis and organ imaging, detection of unsuspected diagnoses such as infection,<sup>3</sup> and the determination of responses to medical or surgical treatment.<sup>4-6</sup>

Eye tumour tissue (such as primary malignant melanoma), and metastatic tumour tissue removed at necropsy from other organs such as the liver, are important for research into the growth, progression, and treatment of eye cancer. An example of this is research into changes in the cytogenetics and molecular genetic changes in ocular malignant melanomas,<sup>7</sup> where useful research can be done on both viable and non-viable tumour tissue.

Eye tissues removed at necropsy are an important source of viable cells for tissue culture (for example, of retinal pigment epithelial (RPE) cells, trabecular cells) in research into non-tumorous conditions, such as proliferative vitreoretinopathy (a proliferation of RPE

Ophthalmic Sciences Unit, Royal Hallamshire Hospital (Floor O), Glossop Road, Sheffield S10 2JF, UK  
M A Parsons

Department of Pathology, Chesterfield and North Derbyshire Royal Hospital, Calow, Chesterfield S44 5BL, UK  
R D Start

Correspondence to:  
Dr Parsons  
[a.parsons@sheffield.ac.uk](mailto:a.parsons@sheffield.ac.uk)

Accepted for publication  
9 November 2000

cells that occurs after retinal detachment, and which can prevent successful surgery to reattach the retina). Eyes obtained at necropsy have also been used by ophthalmologists in the evaluation of new treatment modalities, such as determining whether the effects of YAG laser cryoablation could be detected by ultrasound biomicroscopy.<sup>8</sup>

Examination of the eyes can be vital in forensic investigations, as in the case of non-accidental injury in infants, where examination of the eyes and optic nerves is required to demonstrate the characteristic distribution of haemorrhages and focal areas of retinal detachment.<sup>9</sup> Road traffic and other accidental deaths can be related to poor vision, and the assessment of ocular pathology may help in understanding the cause of the accident. Sampling of vitreous fluid at necropsy is an important means of obtaining diagnostic biochemical and toxicological information pertaining to the cause and time of death.<sup>10-13</sup> However, care must be taken when identifying a body from eye colour at necropsy because postmortem clouding of the cornea and other changes tend to make the eyes appear more brown after the first 24 hours.<sup>14</sup>

The examination of the eyes at necropsy is often neglected, or may be felt to be mutilation without good cause. Removal of the eyes is particularly emotive, although many of the patients who have suffered from defective vision are keen to have the causes investigated after their death, for the benefit of others. After appropriate training it is easy for the pathologist to remove an eye, with or without the orbital contents, leaving no external signs that this has been done. In extreme and important cases, and with care, the orbits and large areas of the facial and skull bones can be removed and the face reconstructed, to leave an externally unchanged face for later viewing by relatives.

Here, we aim to provide a series of best practice guidelines for general pathologists on the indications for, and methods of, obtaining a range of ocular tissues and fluids for subsequent biochemical or histopathological examination, and for teaching and research. We also identify specific legal, ethical, and health and safety considerations that are applicable to ophthalmic necropsy practice. The aim is to encourage pathologists to gain experience in this field, and to contribute to scientific and clinical knowledge of important but rarely studied ocular diseases.

### Legal considerations

It is legal to remove the eyes at necropsy in the UK under three circumstances,<sup>15</sup> namely:

- (1) In any necropsy performed under the provisions of the Human Tissue Act,<sup>16</sup> where there is a validly completed written consent form, and where there is no objection to the removal of the eyes. It is vitally important, however, to obtain specific written consent both for the removal of the eye and/or adnexal structures, and for the retention of these tissues, in accordance with the Royal College of Pathologists' guidelines for the retention of tissues and organs at postmortem examinations.<sup>17</sup>

- (2) In a necropsy performed for the coroner or equivalent authority, when the eyes are required for diagnostic purposes (for example, in suspected cases of non-accidental injury in infants), or to determine the possible contribution of suspected eye disease to the cause of death (for example, retinitis pigmentosa or diabetic retinopathy in a road traffic accident). Again, the coroner and pathologist should have a policy on the eventual treatment of the eye tissues that reflects the Royal College of Pathologists' guidelines for the retention of tissues and organs at postmortem examination.<sup>17</sup>
- (3) From patients who have donated their eyes for corneal transplantation. These eyes are usually removed by ophthalmologists after arrangement through eye banks, and pathologists are rarely involved. Specific authorisation must be confirmed before the eyes are removed.

The pathologist has an ethical duty to ensure that the wishes of the patient when alive (if known) and the wishes of the patient's family have been fully investigated. Under the new Royal College of Pathologists' guidelines<sup>17</sup> it is important to obtain fully informed specific consent both for the removal of ocular tissues, and for the retention and eventual means of disposal of these tissues. Note that a considerable portion, or the whole, of an eye will be retained and used to prepare tissue sections, using conventional ophthalmic pathological processing methods.

It might seem that the new procedures to obtain specific consent to remove and retain ocular tissues would inevitably mean a reduction in the availability of these tissues. In our experience, however, the relatives of even very young patients readily give their consent for such procedures. It is obviously extremely important for the clinicians and pathologist to be very sensitive and take time to inform the relatives of the reasons that the procedure should be undertaken. Under such circumstances, relatives might feel that at least some benefit may have come from the death of their family member.

Note that, under the specific provisions of the Human Tissue Act, 1961 (as modified by the Corneal Tissue Act, 1986<sup>18</sup> and by the National Health Service and Community Care Act, 1990<sup>19</sup>), an eye (or part of the eye—for example, the vitreous) must be removed by a registered medical practitioner, who must be satisfied that life is extinct by personal examination of the body (or on the basis of a statement by a registered medical practitioner who has satisfied himself by personal examination of the body that life is extinct). Removal of an eye (or part thereof) can also be performed by an appropriately trained person (such as an anatomical pathology technician) acting on the instructions of a registered medical practitioner (who has examined the body, as above). However, such a trained delegated person must be "in the employment of a health authority (or NHS trust)", and therefore technical staff employed solely by universities cannot perform this task legally.

The law relating to the removal of tissues after death varies considerably in different countries in the world. Pathologists working in countries outside the UK should contact their professional organisations and institutional legal advisers for specific written legal advice before they contemplate removing any tissues from the eyes or ocular adnexae.

### Ethical considerations

We believe that pathologists have an ethical duty to avoid any procedure that is likely to add to the distress of relatives of the deceased, and the removal of “culturally sensitive” ocular tissues should be considered to be more than usually emotive under these circumstances. Ocular tissues should only be removed for sound scientific purposes, which we believe include audit of clinical practices, continuing medical education, and sound scientific research. This reflects the recommended policy for the uses of these tissues issued by the Royal College of Pathologists and the Institute of Biomedical Science.<sup>20</sup>

Whenever the removal of tissues is likely to alter the facial appearance of the deceased specific signed consent from relatives, or consent from the coroner or equivalent authority must be obtained for any procedure, and ethically the reasons for the procedure must be important enough to warrant the possibility of further distress to relatives. Arrangements might need to be made to ensure that the body is only viewed by the relatives before the procedure. Removal of tissues to this extent must be viewed as most exceptional, and discussions with the coroner or local ethical committee might be advisable before relatives are consulted or informed. Under such circumstances, it is probably advisable for a senior ophthalmologist (possibly accompanied by a senior pathologist) to explain the circumstances to the relatives to ensure truly informed consent. It must always be assumed that a close relative will view the body after the necropsy procedure has been performed, unless specific arrangements have been made with the consent of the relatives to prevent this.

### Health and safety considerations

The same health and safety considerations apply to ophthalmic necropsy practice as to any other necropsy practices.<sup>21</sup> Microdroplets and aerosols of blood and tissues may be formed when orbital/skull bone is cut with a mechanical saw, and jagged edges of bone can lead to glove puncture or injury. Sharp dissection (using a scalpel) is not required for most ophthalmic necropsy procedures, and can be dangerous if two handed methods are used (as when the orbital contents are removed via the base of the skull—see below). Even removal of the vitreous carries a small risk of needle stick injuries, and the vitreous is known to harbour pathogens such as human immunodeficiency virus.<sup>22</sup>

In addition to the usual infectious agents potentially encountered at necropsy,<sup>3</sup> the eye is one of the tissues with the highest titres of infectivity for the human and animal transmissible spongiform encephalopathies, and infectivity is present in unfixed or routinely fixed tissues.<sup>23</sup> In

view of the small risk of infection of necropsy workers, the advisory committee on dangerous pathogens and Department of Health have issued guidelines for the UK, which are considered to represent “good practice”.<sup>23 24</sup> These guidelines state that: “as an extreme precaution”, the eyes should not normally be removed from humans or animals known or suspected to have suffered from transmissible spongiform encephalopathies, such as Creutzfeldt-Jakob disease (CJD) and Gerstmann-Straussler-Scheinker syndrome (GSS), or who fall into one of the following groups:

- Recipient of hormone derived from human pituitary glands, such as growth hormone and gonadotrophin.
- Recipient of human dura mater grafts.
- Member of recognised CJD or GSS families.

If, under exceptional circumstances, and after consideration of the above guidelines and ethical points, the eyes were to be removed from such patients, extreme precautions are mandatory; and we advise adoption of those devised by Bell and Ironside.<sup>25</sup> After removal, the eyes must be fixed using the formalin formic acid procedure of Brown *et al*,<sup>26</sup> or the formalin/hypochlorite method,<sup>27</sup> before subsequent treatment for histology.

### Aims of ophthalmic necropsy examination

The aims of the procedures to obtain ophthalmic pathological samples at necropsy are:

- To obtain appropriate good quality tissues for pathology, research, and education.
- To achieve a cosmetic result identical to (or better than) that pertaining before tissues were removed at necropsy.

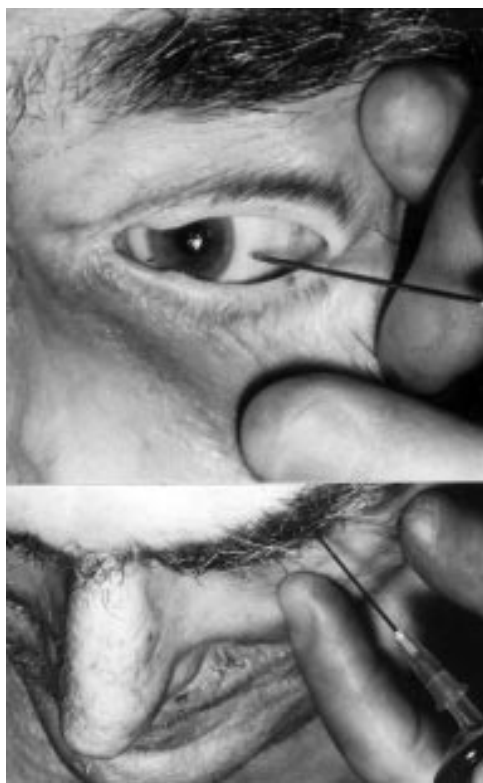### Techniques for the removal of ocular tissues at necropsy

Before any tissues are removed at necropsy, it is important to examine the external surface of the eyelids and surrounding skin and eyebrow, the conjunctival surface of the eyelids (by gentle traction), the conjunctival surface of the eye, the cornea, and the iris. The examination should be gentle, taking care not to scratch the delicate mucosal surfaces. We strongly advise against the practice of manipulating the eyes from the anterior in an attempt to see the more posterior aspects of the conjunctiva and globe, because this can cause external and internal eye damage.

Any abnormal findings should be recorded and photographed, where appropriate (for example, where non-accidental injury or petechial haemorrhages in suspected smothering are present). When photographing eyes (at this stage or in subsequent dissection) it is important to ensure that good, well lit, close up photographs are taken.

#### THE VITREOUS

The most common reason for vitreous removal at necropsy is for biochemical analysis to assist in determining the cause and time of death.<sup>10 11</sup> Vitreous may be removed in a limited necropsy procedure to determine the presence of infection or malignancy (if cloudy vitreous was noted in life), but we advise strongly that the intact globe should be removed under such



*Figure 1* Vitreous is removed from the left eye by inserting a needle (with attached syringe) at a point not less than 5 mm lateral (temporal) to the corneo-scleral junction (limbus), in both the horizontal plane (top), and 60° lateral to the median (sagittal) plane (bottom).

circumstances, for the retina and other ocular tissues are often involved, and examination of the intact eye is much more informative.

We believe that only “normal” vitreous should be sampled for biochemical analysis because disease affecting the vitreous can greatly alter its biochemical and cellular composition, with misleading results. We recommend that vitreous is not sampled for biochemistry from eyes with a history of retinal detachment, surgical manipulation, or posterior chamber disease affecting the vitreous. Non-vitreous fluids encountered in some eyes include blood, subretinal proteinaceous fluid, inflammatory exudates, and artificial vitreous (for example, silicone oil) used in some vitreo-retinal surgery. Note that the eye might be calcified or even ossified in some pathological conditions, and vitreous sampling may be impossible. Vitreous sampling should be aborted in eyes that are small, wrinkled, and hard, or when there is firm (or gritty) resistance to puncture. A good practical test is to determine before puncture whether the eye is fluctuant—easily accomplished in the slightly flaccid postmortem eye by feeling transmitted pressure on the thumb and index finger of one hand placed medially and laterally on the sclera, when slight pressure is exerted on the superior sclera with the other index finger.

The vitreous is obtained by needle puncture of the posterior chamber of the eye using a 15 or 17 gauge needle on a 5 ml or 10 ml syringe, taking care to avoid cosmetically unsightly disruption of the iris and the pupil.

#### Method

- (1) After determining that the eye is fluctuant, the needle is inserted into the sclera (fig 1) at a point not less than 5 mm lateral (temporal) to the corneo-scleral junction (limbus), in both the horizontal plane passing through the centre of the pupil and at 60° lateral to the median (sagittal) plane (pointing to the centre of the posterior chamber). It might be useful to put slight pressure on the eye with the index finger and thumb of the other hand while puncturing the globe. If the needle is initially pointed slightly posteriorly so that it penetrates the sclera at an oblique angle (before final alignment as above) this will help to prevent leakage of fluid when the eye is reinflated at the end of the procedure.
- (2) The needle is inserted about 10–15 mm into the eye before fluid is removed, and may be withdrawn slightly during the procedure to facilitate vitreous removal (up to 2–3 ml of vitreous, but often less than this). The eye collapses during this procedure, which requires only gentle traction, and is complete when resistance is felt.
- (3) The needle is kept in situ while the syringe is detached, and clean water or saline from another syringe is injected through the needle into the eye until there is resistance to flow and the eye is firm. It is important not to over inflate the eye, as this risks iris/lens disruption or rupture of the eye.

The vitreous removed for biochemical analysis should be placed in labelled 2 ml sample tubes containing fluoride for optimum results and sent for immediate analysis (or kept at 4°C until analysis can be performed).

#### THE INTACT EYE (ANTERIOR APPROACH)

The simple and rapid anterior approach is the method of choice for removal of the intact eye (globe) and part of the optic nerve where the pathology is intraocular, and where the optic nerve is normal.

This method should not be used under the following circumstances:

- When the optic nerve is (or could be) abnormal.
- In intraocular vascular disease affecting the central retinal artery or vein and/or ciliary vessels.
- When intraocular tumours extend through the sclera into the orbit.
- When orbital disease affecting fat and/or extraocular muscles is present.

We also recommend that this method is not used to remove the eyes of children or adults when non-accidental injury is suspected, because important orbital pathology can easily be missed unless the entire orbital contents are removed together.

#### Method

- (1) Retract the eyelids manually or using eyelid retractors, and keep the eyelids and eyelashes in direct vision throughout the procedure to avoid irreparable cosmetic damage.
- (2) Insert long, blunt ended (and preferably curved) scissors between the globe and the



*Figure 2* To remove the right eye using the anterior approach, the eyelids are first retracted using the index finger and thumb to prevent eyelid damage. Curved scissors are inserted between the eyelid and the eye to divide the conjunctiva in a circle around the eye.

eyelids (fig 2) and use blunt dissection whenever possible to divide the conjunctiva as far posteriorly as possible in a circle around the eye, 10–20 mm behind the corneo-scleral junction (limbus). This manoeuvre can be accomplished with sharp dissection, but with increased risk of damage to eyelids or the eye.

- (3) Use blunt dissection to move posteriorly and circumferentially to free the globe from the orbital wall, keeping as far from the eye as possible. Toothed forceps may be used to exert gentle traction on the globe by gripping one of the extraocular muscles (at this stage a suture inserted into an identified rectus muscle close to its insertion helps orientation later). The extraocular muscles can be divided during this procedure if desired, leaving about 5 mm of their insertions into the globe to aid orientation later.
- (4) Retract the eye laterally and dissect it from the medial wall of the orbit towards its apex, then cut the optic nerve with sharp scissors as far posteriorly as possible. This allows the eye to prolapse forward and laterally, and any attached structures can be divided.

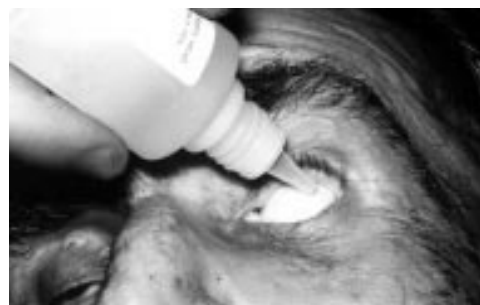Unwanted orbital tissue can be trimmed off before fixation, taking care not to remove muscle insertions, as these are needed to orientate the eye so that appropriate tissue blocks can be taken for histology.

Note, some modifications of this basic technique involve more detailed dissection and division of intraocular muscles and orbital structures,<sup>28</sup> but these are more time consuming and less suitable for general use by pathologists.

#### *Reconstruction*

This is best done after the necropsy has been completed, the body and head incisions have been sutured, and the body washed.

- (1) Dry the face. Push any protruding orbital contents such as fat into the orbit.



*Figure 3* Reconstruction of the left eye for cosmetic effect, after washing the body and drying the face. A clear domed plastic eyecap has been inserted into the orbit after packing with cotton wool. The surface of the plastic eyecap and the inner surface of the eyelids are dried before superglue is applied to the surface of the eyecap, and the eyelids are placed in position (for important details see text).

- (2) Place a wad of wet, squeezed cotton wool (approximately 2 cm diameter) into the orbit and press firmly, then cover with dry cotton wool.
- (3) Insert a 2 cm diameter clear domed plastic eyecap (Dodge Chemical Company, Whitchurch, UK) into the orbit; this should approximate the normal position of the anterior (corneo-scleral) surface of the eye (fig 3). The final position of the eyecap can be modified by adding or removing the underlying cotton wool.
- (4) After ensuring that the eyelids can close normally over the plastic eyecap, dry the eyecap and undersurface of the eyelids.
- (5) With the lids open, place superglue (Pacer RX-100 instant adhesive; Dodge Chemical Company, or an equivalent) on the front of the plastic eyecap (fig 3), then rapidly position first the lower then the upper eyelids, ensuring that the eyelids are closed with no gap.

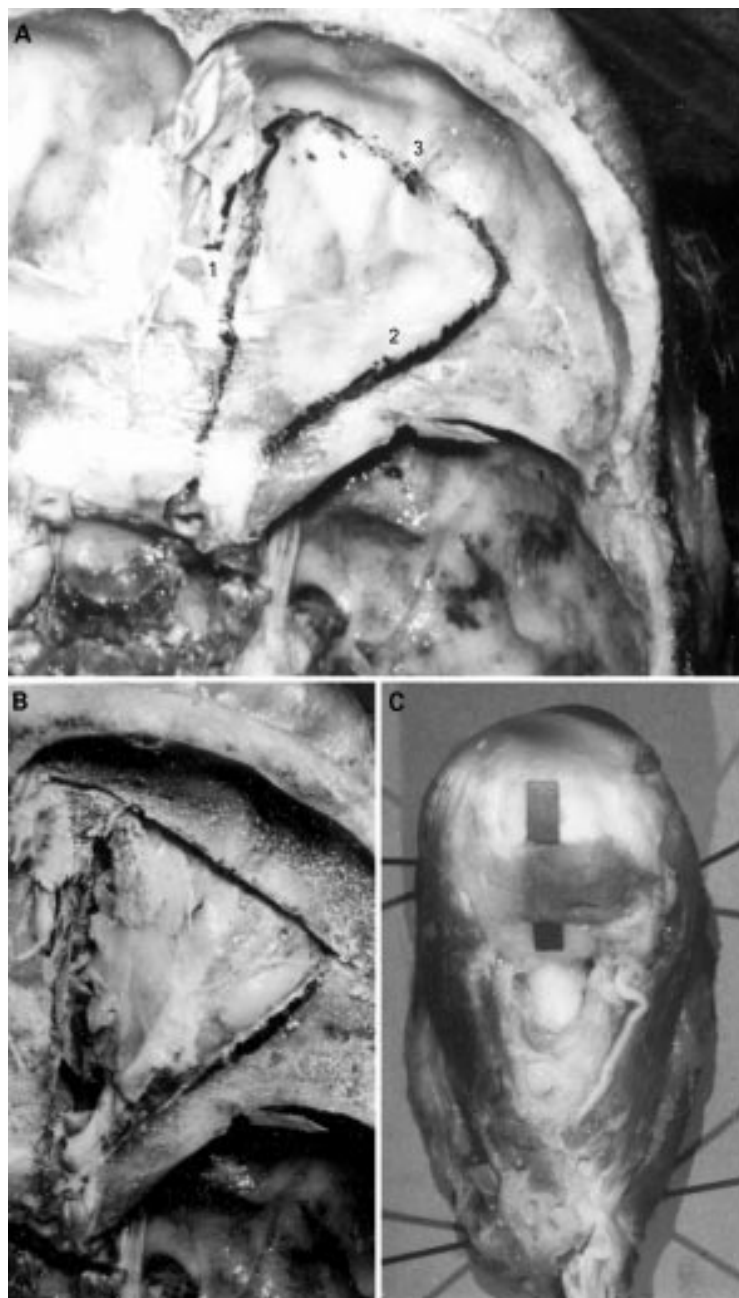
#### THE INTACT EYE AND ORBITAL CONTENTS (POSTERIOR APPROACH)

The posterior approach via the cranial cavity<sup>28</sup> is the method of choice for removing the eye and the contents of the orbit where there is:

- Ocular disease that extends into the orbit (ocular neoplasms with posterior invasion).
- Vascular disease affecting the eye (where the ophthalmic and/or ciliary arteries and veins may be involved).
- Optic nerve pathology.
- Orbital disease affecting orbital fat or extraocular muscles.
- Disease with eye and lacrimal gland involvement.
- Non-accidental injury to the eye and/or orbit in children and adults.

This method can be modified to remove the posterior part of the eye (behind the iris and lens) as part of a limited procedure, if this is requested (see below).

The method should not be used if ocular or orbital disease extends into the bony wall of the orbit or beyond, and into the frontal, ethmoid, or maxillary sinuses or the nasopharynx.



**Figure 4** Removal of right orbital contents through the base of the skull (posterior approach). (A) After removal of the brain and dura, the triangle of bone forming the roof of the orbit is marked: note the optic nerve at its posterior apex. A mechanical saw is used to cut carefully into the orbit along cuts 1, 2, and 3 (see text for details). (B) The orbital contents, with the superior rectus muscle and orbital fat, are exposed after lifting the very thin bone of the orbital roof. (C) The right orbital contents (inferior surface), after the removal of some fat, are pinned gently to a board for fixation. A piece of card lies under the muscular insertion of the inferior oblique muscle, which marks the inferior surface of the specimen (see also fig 8).

#### Method

- (1) Enter the cranial cavity and remove the brain by conventional means, then strip the dura from the anterior fossa of the skull.
- (2) Mark or identify the edges of the triangular piece of bone (fig 4A) that forms the roof of the orbit; its posterior apex is formed by the optic nerve where it emerges from the optic canal. The medial edge of the triangle runs anteriorly from the medial aspect of the optic canal in a

line that extends just lateral to the outer (lateral) aspect of the cribriform plate of the ethmoid bone. The lateral edge of the triangle runs anterolaterally from the lateral aspect of the optic canal just inside and parallel to the edge of the lesser wing of the sphenoid bone.

- (3) Using a pneumatic oscillating mechanical saw make cuts along the medial and lateral edges of this triangle (Fig 4A; cuts 1 and 2), taking care to withdraw pressure from the saw as soon as the orbit is entered to avoid damage to the soft orbital contents (the roof of the orbit is only about 2 mm thick, and there is sudden loss of resistance to the saw when this happens).
- (4) Extend the cuts anteriorly to a point about 10 mm from the inner original sawn edge of the frontal bone (take care not to extend the cut too far anteriorly because the roof of the orbit is not far from the skin beneath the eyebrows at this point).
- (5) Saw into the orbit between the two anterior ends of the two cuts (fig 4A; cut 3).
- (6) Insert a bone chisel into the cuts to break small points of attached bone, and lift the bony triangle by twisting the bone chisel, dissecting off any soft tissues. The orbital contents are now exposed (fig 4B).
- (7) Using blunt dissection wherever possible, separate the optic nerve and orbital contents from the bony walls of the orbit, working anteriorly to a point about half the distance between the apex of the orbit (at the posterior point of the triangle of removed bone) and the anterior base of the triangle.
- (8) At this stage it is vital to reflect the frontal skin of the face back to expose the eyelids, and to dissect the eye from the eyelids using the anterior approach (fig 2), carefully avoiding damage to the eyelids (which would almost certainly occur if an attempt were made to do this from the posterior orbital route alone).
- (9) When the conjunctiva has been cut circumferentially, dissect towards the bony walls of the orbit, using blunt dissection, taking care to avoid the soft skin of the eyelids anteriorly. The anterior and posterior dissections along the bony orbital walls will eventually connect, and the eye and orbital contents can be delivered posteriorly, aided by a gentle push with a finger between the eyelids.
- (10) After removal, orientate the orbital contents, which can then be pinned gently to a cork board for fixation without distortion (fig 4C). (For orientation details, see "Preparation for histological examination" below.)

#### Reconstruction

- (1) Pack the orbit with a core of squeezed wet cotton wool surrounded by dry cotton wool. If desired, a 2 cm diameter plastic eyecap can be used in the posterior orbit, followed by packing with dry cotton wool, and reattachment of the bony roof of the orbit using superglue.

- (2) Pack the cranial cavity with cotton wool, replace the skull cap, and close all skin incisions.
- (3) After washing the body (and as the last procedure performed on the body), the anterior orbit is packed, a plastic eyecap is inserted, and the eyelids are stuck down using instant adhesive (as for reconstruction following removal of the eyes via the anterior approach, above).

#### THE POSTERIOR PART OF THE EYE ONLY

Occasionally, permission is obtained only to remove the posterior part of the eye, leaving the cornea, anterior chamber, and the iris–lens diaphragm undisturbed. The obvious reason is that the eye is left cosmetically normal for viewing by relatives, although important macular or retinal disease can be examined by the pathologist. We advise, however, that the eye should be removed intact using other methods, if at all possible.

This method has been used in necropsies involving infants or children, when a good cosmetic result is particularly important. However, if there is the remotest possibility of non-accidental injury, the transverse cut across the equator of the eye will either disrupt or leave behind (with the retained anterior half of the eye) peripheral retinal haemorrhages and focal areas of retinal detachment; these may be the earliest and/or the most characteristic diagnostic features of the shaken baby.<sup>9</sup> Therefore, we advise that both eyes and orbital contents should be removed and fixed intact in such cases, and in any death of uncertain cause involving the central nervous system in children.

#### Method

This method is relatively difficult, and requires some skill not to damage the iris and produce cosmetic defects. It may also disrupt the retina severely by traction on the vitreous and direct trauma. For this reason, fixative (we prefer 0.5 ml of 3% glutaraldehyde) is introduced into the vitreous before the procedure, as soon as possible after death, but a minimum of 30 minutes before the remainder of the procedure. This makes the eye firmer, and reduces the risk of artefactual retinal detachment.

- (1) At least 30 minutes before the remainder of the procedure, introduce a needle slightly obliquely into the vitreous, as for step 1 of the procedure for removing the vitreous, and inject approximately 0.5 ml of 3% glutaraldehyde into the vitreous.
- (2) Use the cranial posterior approach to remove the bone of the superior aspect of the orbit, as for steps 1–6 of the procedure for removing the intact eye and orbital contents.
- (3) Dissect and divide or remove the orbital muscles and fat in layers to expose the optic nerve from above, and divide the nerve as posteriorly as possible.
- (4) The eye can now be cut along the equator (in the coronal plane), superiorly initially with a sharp knife, then with scissors, to separate the posterior half of the eye. Ensure that the initial cut extends through the retina as well as the sclera and choroid. You might wish to place a small suture or V

cut in the superior aspect of the cut edge of the sclera to aid subsequent orientation.

- (5) The inferior rectus muscle must be divided to free the posterior half of the eye.

#### Reconstruction

- (1) Gently place a pad of damp (not wet) cotton wool dyed with black ink behind the exposed iris–lens diaphragm, and pack the orbit gently with more cotton wool. Too much pressure at this stage could disrupt the iris and pupil.
- (2) Replace the bony roof of the orbit (stick with superglue).
- (3) Pack the cranial cavity, replace the skull cap, and suture all skin incisions.

#### THE INTACT EYE, ORBITAL CONTENTS, AND BONY WALLS OF THE ORBIT

If the eye and orbital pathology extends to involve the bony wall(s) of the orbit, it is possible to remove the eye and orbital contents within the intact bony wall of the orbit. Specific consent from relatives, or the coroner (or equivalent authority) is advised, although there should be no cosmetic abnormality after this procedure.

#### ethod

The best approach under these exceptional circumstances is:

- (1) Use a conventional Y shaped skin incision for dissection of the neck, combined with a conventional incision for entering the cranial cavity.
- (2) Open the cranial cavity and remove the brain. On the side from which the orbit is to be removed extend the neck incision superiorly behind the ears to connect with the scalp incision.
- (3) Starting from this new incision, reflect a flap of skin and underlying soft tissue anteriorly off the skull, lifting the pinna, and dividing the external auditory meatus where it enters the skull.
- (4) Dissect the flap medially over the frontal and maxillary bones to the lateral aspect of the nose, lifting the eyelids (with great care) from the anterior orbital rim, cutting the conjunctiva circumferentially at the fornix, and exposing the anterior aspect of the eye. This dissection will also expose the upper jaw and teeth (taking care not to cut the skin around the lips. The lower face (over the mandible) is reflected as little as possible.
- (5) With the cranial cavity opened and the brain removed, remove a large segment of the bone of the floor of the skull around the orbital wall using two cuts through bone (fig 5). The resulting wedge of bone is bordered medially by the maxilla and frontal bone just lateral to the nose, and laterally by part of the zygomatic arch and greater wing of the sphenoid bone (from above the cranial cavity the cuts fall outside those made for the posterior approach to removal of orbital contents, with an additional coronal cut just posterior to the optic foramen). If desired, the maxilla can be cut in a horizontal plane at the level of the lower part of the zygomatic arch, which avoids removal of one or more upper teeth (molars).

- (6) The excised block of bone and orbit may be fixed intact, but further cuts can be made through the bone into the orbit to aid rapid fixation (fig 6).

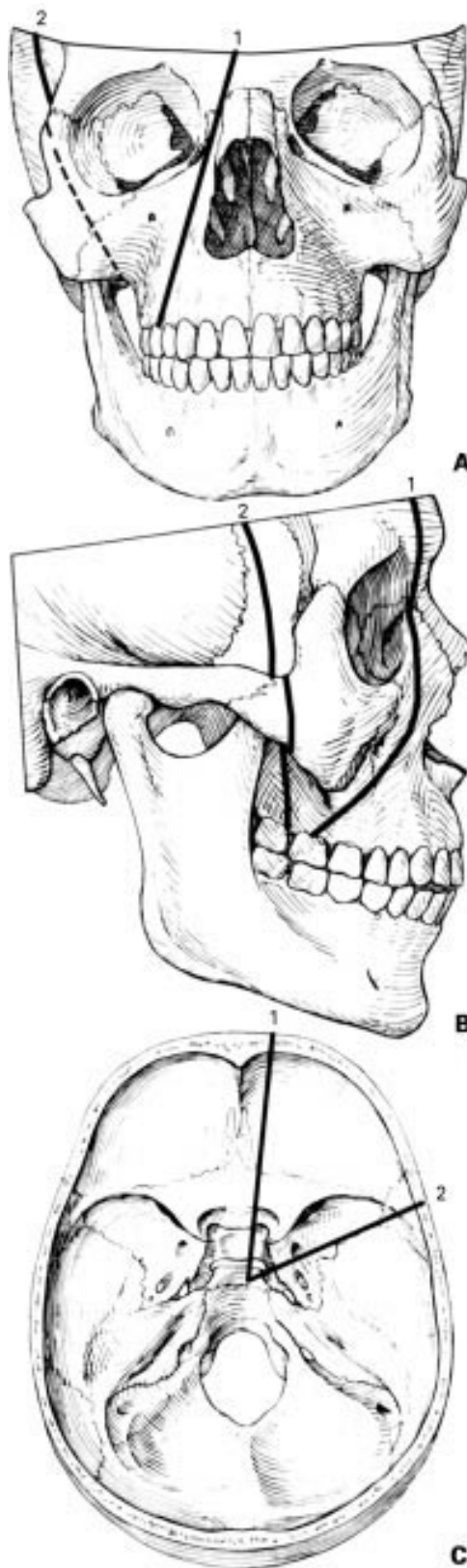


Figure 5 Removal of the right orbit with intact bony orbital walls requires two mechanical saw cuts (marked 1 and 2), seen from (A) anteriorly, (B) the right side, and (C) above (the top of the skull and brain have been removed after reflection of soft tissues: see text for important details).

### Reconstruction

The skull is stable after this procedure, and the cavity is easily packed with squeezed wet cotton wool alone, or with orthopaedic bandages impregnated with plaster of Paris. The eye is best reconstructed after all of the scalp and neck skin incisions have been sutured (when the eyelids fall into place), using the method described for the anterior approach for eye removal.

### THE ORBIT(S), NASAL PASSAGES, AND SINUSES

Under very exceptional circumstances it might be necessary to remove one (or both) orbits with midline structures including the upper jaw and the palate. Examples include the investigation of malignant or granulomatous disease involving combinations of the eye or orbit, midline nasal or nasopharyngeal structures, the frontal, ethmoid or maxillary sinuses, or the base of the skull. We recommend that you obtain specific consent from the relatives or coroner (or equivalent authority) (see also "Ethical considerations", above), although with care there should be little or no residual cosmetic alteration. Discussion with involved clinical colleagues, and careful planning is required before undertaking such procedures, and modifications can be planned according to the extent of the disease process. It may be very valuable for the surgeon to attend (or assist with) this part of the necropsy, always assuming that the coroner (or equivalent authority) has approved in cases under their jurisdiction.

### Method

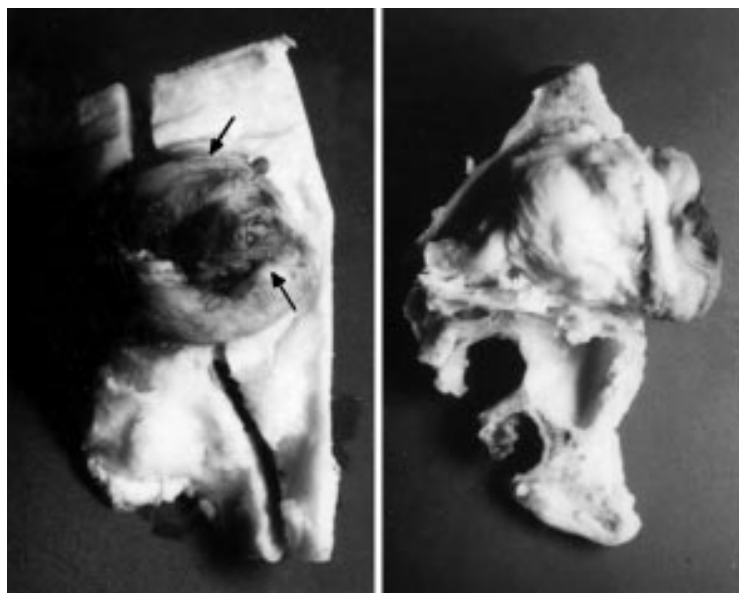- (1) The approach requires a Y shaped neck incision, extended superiorly behind the ear(s) to connect with the scalp incision(s), as for the removal of the orbit with bony walls.
- (2) Reflect the skin on the affected side, as for removal of one orbit, and lift the skin carefully from the nose. If both orbits are to be removed, reflect the tissues inferiorly from the whole of the upper face, including the nose (retaining attachments over the mandible).
- (3) Remove the block of skull and facial bones, including most of the frontal bone and all of the upper jaw and both orbits in one piece (one uninvolved orbit may be retained, as in fig 7, and the block modified according to the known extent of the disease process).

### Reconstruction

Careful reconstruction is accomplished using plaster of Paris impregnated orthopaedic bandages and wet/dry cotton wool. The remaining skull is stable, and replacement of the top of the skull provides the shape of the front of the face when skin sutures are inserted. In practice the shaping of the nose with plaster of Paris is not particularly difficult, and plaster of Paris impregnated bandages are easily removed when wet if the first attempt does not have a satisfactory result. The final cosmetic effect is likely to be excellent.

### INDIVIDUAL ADNEXAL OCULAR STRUCTURES

The eyelids are easily removed, but with obvious cosmetic defects requiring specific consent



**Figure 6** The intact orbit, with bony walls and attached eyelids, has been removed (left), and the bone bisected vertically. The patient died of causes unrelated to the extensive conjunctival malignant melanoma with infiltration of the eyelids and orbital extension. Dissection of the orbital contents from the lateral wall of the orbit (right) exposed the lateral aspect of the orbital contents (and sinuses inferiorly) to fixation. Specific permission was given by a relative for removal of the eyelids and orbit, and the use of an eye patch was agreed in reconstruction (because this had been used in life).

from the relatives or the coroner or equivalent authority, with attendant ethical considerations. An eye patch will be required if the body is to be viewed. In practice it is best to involve an ophthalmic surgeon if individual lacrimal glands, nasolacrimal ducts, Meibomian glands, and other adnexal structures need to be removed. The surgeon might perform the procedure for you (this is the ideal scenario), but should at least advise about probable cosmetic effects, and arrangements can be made accordingly.

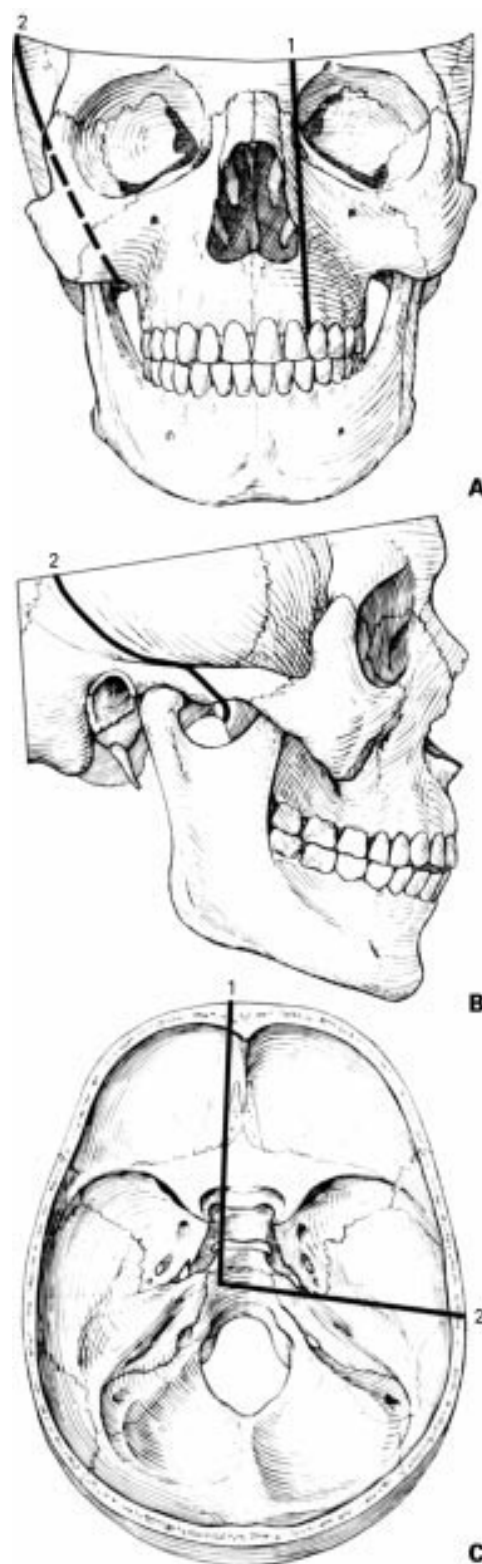
#### Fixation of ocular tissues

We find that in ideal circumstances it is best to fix the intact globe in 3% buffered glutaraldehyde for 12 hours, followed by 10% formalin for at least 24 hours, both at room temperature. The use of formalin alone tends to discolour the specimen but, more importantly, it may cause artefactual retinal detachment in the intact eye during fixation. However, there are disadvantages to the use of glutaraldehyde (for example, if immunohistochemistry is required), and this step may be omitted without major detrimental effects.

Do not inject fixative into the eye without thought for the consequences because this can cause serious displacement of intraocular tissues. However, injection of 0.5 ml of 3% glutaraldehyde into the vitreous may be justified in the following circumstances:

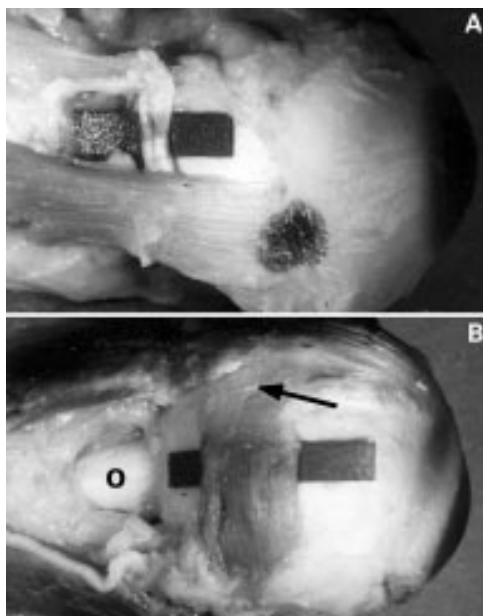
- If necropsy is likely to be delayed (to prevent autolysis).
- If the vitreous is essentially normal, or is of little interest.
- If there is a particular interest in the pathology of the retina or macula.
- If only the posterior half of the eye is to be removed.

For larger specimens, such as the whole orbital contents with the globe, we advise



**Figure 7** The right orbit, with nasal passages and sinuses, and part of the maxilla, may be removed using left paramedian (line 1) and right temporal (line 2) mechanical saw cuts, seen from (A) anteriorly, (B) the right side, and (C) above (the top of the skull and the brain have been removed after reflection of soft tissues: see text for important details).

fixation in 10% formalin. We find that orientation and pinning to a cork board before fixation (floating upside down) prevents distortion of the orbital anatomy. Specimens with the eye



**Figure 8** Orientation of the removed right eye. (A) The superior aspect of the right globe, showing that the superior oblique muscle forms a tendon (over a piece of card) as it runs towards its insertion beneath the superior rectus muscle. The insertion of the superior rectus muscle (marked with ink dot) orientates the eye. (B) The inferior aspect of the right globe, showing (by contrast) the muscular insertion of the inferior oblique muscle, running over a piece of card close to the optic nerve (O). The point of insertion of the inferior oblique muscle (arrow), close to the lateral rectus muscle border (above), forms the external scleral marker of the macula within the eye.

surrounded by bony orbit can be fixed intact before further dissection, or may be partially dissected to aid fixation of the orbital contents (possibly changing the buffered formalin for optimal effect).

Eyes from patients with known or suspected spongiform encephalopathies (or high risk cases) must be fixed using the formalin formic acid or the formalin/hypochlorite procedures<sup>26 27</sup> before subsequent treatment for histology (but see above for guidelines).

### Orientation of the eye and preparation for histological examination

A detailed description of the examination of the eye and adnexal structures and their preparation for histological examination is beyond the scope of this paper, and the reader should refer to more detailed published texts for further information relating to technical methods,<sup>29 30</sup> and to the interpretation of macroscopic and microscopic findings.<sup>31</sup>

For most purposes, a horizontal section is taken for histological examination because this is the only plane in which the centre of the pupil and the optic nerve appear in the same histological section (note that the fovea centralis, at the centre of the macula, lies in this horizontal plane approximately 2 mm inferior to the centre of the optic disc). The eye is oriented using the attachments of the extraocular muscles (fig 8), but an easier approach is to place a suture in the insertion of the superior rectus (or another) muscle before removing the eye (with the attached suture).

The superior oblique muscle has a tendinous insertion beneath the anterior part of the superior rectus muscle (fig 8A). The inferior oblique muscle is, by contrast, muscular to its insertion; this point of insertion lies close to the lateral rectus muscle, and the muscle insertion is the external scleral marker of the position of the macula within the eye (fig 8B). The posterior margin of the lateral rectus muscle lies close to the optic nerve, whereas the superior oblique muscle has a more anterior insertion.

To distinguish between the right and left eyes there is a useful rule that can be used when both unlabelled eyes are put into a fixative container together, or if there is doubt about the labelling of an eye. Identify the superior oblique muscle, and the insertion or the superior rectus muscle, and then orientate the eye so that the superior aspect of the eye is uppermost; the posterior view of the eye will now have the optic nerve just off centre medially (nasally). Thus the left eye has the insertion of the inferior oblique muscle to the left of the optic nerve, and in the right eye it is to the right of the optic nerve.

In our hands the best instrument to cut open the eye is a disposable low profile microtome blade (for example, Accu-Edge; Sakura Finetek USA Inc, Torrance, California, USA) held in a microknife blade holder (CellPath, Hemel Hempstead, UK). We use a fresh blade for each eye because the fixed sclera is extremely hard, and it blunts any blade rapidly.

As a good general rule, the eye is never cut through its centre because this disrupts the delicate zonules of the lens, causing dislocation. Therefore, two parallel horizontal cuts are made about 1 mm below the limbus superiorly and above the limbus inferiorly,<sup>29</sup> removing the two calottes (or "caps"). The resulting central block (incorporating the whole lens and the optic nerve) is processed into wax intact for later sectioning to the midline. Some pathologists would make a possible exception to this rule, and cut a tissue block of "normal" thickness in disorganised and phthisical eyes, when the lens has been lost or is fused in a mass of fibrous or bony tissue (often caused by osseous metaplasia of RPE cells). In inexperienced hands, however, we recommend great care and a two stage approach under such circumstances: first open the eye by removing a calotte (as described above), to ensure that there is nothing in the eye (such as a plastic intraocular lens) that will be damaged at the next stage. After decalcification (if required), a central thin block can be cut for subsequent processing.

Vertical cuts may have to be made if an artificial lens has been inserted (these plastic lenses dissolve during tissue processing without the damage caused if they are removed mechanically). If a tumour is present, determined by transillumination of the eye through the pupil,<sup>30</sup> mark its edges on the sclera with a pen, and cut vertically into the tumour (at 90° to the underlying sclera), in a plane that also passes through the centre of the pupil (again, plan to cut either side of the lens).

Note that cutting sections of the paraffin wax embedded eye is much easier (particularly

when fixed in glutaraldehyde) if the sclera has been softened during a tissue processing regimen that includes stages in phenol and chloroform.

Gilliland and Folberg<sup>32</sup> described a technique for examining the eyes of children in suspected child abuse by removing the anterior segment of the eye (cornea, anterior chamber, iris, lens, and pars plicata of the ciliary body) in the coronal plane. The aim was to expose any retinal haemorrhages in these children, so that photographs would show the fundus (to a jury) as it would be seen in life by an ophthalmologist. This technique is fraught with potential dangers for all but experienced ophthalmic pathologists, and we do not use this method because it destroys the continuity between anterior and posterior segment findings in non-accidental ocular injury.

### Obtaining fresh (unfixed) intraocular tissues

In some circumstances (for example, if there is an intraocular tumour) it can be worthwhile to sample the tumour fresh, accepting that this will inevitably cause damage to the eye, and perhaps contamination of intraocular and extraocular tissues with tumour cells. If this is the case, the eye should be orientated (see above), and the position of the tumour determined by transillumination before opening the eye by removing a calotte adjacent to the tumour (see above). After a tumour sample has been removed, the eye can be gently lowered into formalin, (the freshly opened eye retains its shape without further treatment).

### Conclusion

The key to the successful collection of valuable ocular tissues at necropsy is careful planning and preparation. It is vital to choose the method that provides the greatest opportunity for obtaining the pathologically important tissues. Consultation with the ophthalmic surgeon, and examination of the clinical notes and imaging pictures, will probably establish the anatomical extent of the disease; once this has been done the method of obtaining the tissues can be chosen, with full consideration of reconstruction methods. The legality and ethics related to the procedure should also be considered before permission is requested for the specific procedure from the relatives of the deceased and the coroner (or equivalent authority).

Examination of the eye and adnexal structures at necropsy is performed infrequently, but it may yield important information about basic ophthalmic disease processes. Necropsy might also be the only means of providing information on the long term effects of surgical treatments, and thus is important in surgical audit and to manufacturers of artificial intraocular lenses or other prostheses. With a little practice it becomes easy for the pathologist to remove the eye, which may be sent subsequently to a specialist ophthalmic pathologist if the general histopathologist is inexperienced in this specialist field.

We are grateful to Professor ARW Forrest and Professor JCE Underwood for their helpful advice during the preparation of this paper and to Mr R Farr for his assistance with graphics.

- Underwood JCE. Autopsies and clinical audit. In: Cotton DWK, Cross SS, eds. *The hospital autopsy*. Oxford: Butterworth-Heinemann, 1993:163-72.
- The autopsy and audit*. Report of the joint working party of The Royal College of Pathologists, The Royal College of Physicians of London and The Royal College of Surgeons of England. London: The Royal College of Pathologists, London 1991.
- Spencer RC. The microbiology of the autopsy. In: Cotton DWK, Cross SS, eds. *The hospital autopsy*. Oxford: Butterworth-Heinemann, 1993:144-57.
- Blotnick CA, Powers TP, Newland T, et al. Pathology of silicone intraocular lenses in human eyes obtained postmortem. *J Cataract Refract Surg* 1995;21:447-52.
- Hansen SO, Tetz MR, Solomon KD, et al. Decentration of flexible loop posterior chamber intraocular lenses in a series of 222 postmortem eyes. *Ophthalmology* 1988;95:344-9.
- Apple DJ, Park SB, Merkle KH, et al. Posterior chamber intraocular lenses in a series of 75 autopsy eyes. Part 1: Loop location. *J Cataract Refract Surg* 1986;12:358-62.
- Sisley K, Rennie IG, Parsons MA, et al. Abnormalities of chromosomes 3 and 8 in posterior uveal melanoma correlate with prognosis. *Genes Chromosomes Cancer* 1997;19:22-8.
- Pavlin CJ, Machen P, Trope GE, et al. Ultrasound biomicroscopic imaging of the effects of YAG laser cycloablation in postmortem eyes and living patients. *Ophthalmology* 1995;102:334-41.
- Green MA, Lieberman G, Milroy CM, et al. Ocular and cerebral trauma in non-accidental injury in infancy: underlying mechanisms and implications for paediatric practice. *Br J Ophthalmol* 1996;80:282-7.
- Forrest ARW. Toxicological and biochemical analysis. In: Cotton DWK, Cross SS, eds. *The hospital autopsy*. Oxford: Butterworth-Heinemann, 1993:134-40.
- Forrest ARW. Obtaining samples at post mortem examination for toxicological and biochemical analyses. *J Clin Pathol* 1993;46:292-6.
- Mittleman RE, Steele B, Moskowitz L. Postmortem vitreous humor in fatal acute iron poisoning. *J Forensic Sci* 1982;27:955-7.
- McKinney PE, Phillips S, Gomez HF, et al. Vitreous humor cocaine and metabolite concentrations: do postmortem specimens reflect blood levels at the time of death? *J Forensic Sci* 1995;40:102-7.
- Knight B. *The coroner's autopsy. A guide to non-criminal autopsies for the general pathologist*. Edinburgh: Churchill Livingstone, 1983.
- Cross SS. Autopsies, the deceased's relatives and the law. In: Cotton DWK, Cross SS, eds. *The hospital autopsy*. Oxford: Butterworth-Heinemann, 1993:8-14.
- Human Tissue Act, 1961 s.1.
- Guidelines for the retention of tissues and organs at post-mortem examination*. London: The Royal College of Pathologists, March 2000.
- Corneal Tissue Act, 1986 s.1.
- National Health Service and Community Care Act 1990, s.9.
- Consensus statement of recommended policies for uses of human tissue in research, education and quality control*. London: Royal College of Pathologists, 1999.
- Harris DM. Biological safety. In: Cotton DWK, Cross SS, eds. *The hospital autopsy*. Oxford: Butterworth-Heinemann, 1993:15-31.
- Mietz H, Heimann K, Kuhn J, et al. Detection of HIV in human vitreous. *Int Ophthalmol* 1993;17:101-4.
- Advisory Committee on Dangerous Pathogens. *Precautions for work with human and animal transmissible spongiform encephalopathies. Second impression*. London: HMSO, 1994.
- Advisory Committee on Dangerous Pathogens. *Anatomy procedures on donor bodies suspected to have had, or to have been at risk of developing, Creutzfeldt-Jakob disease (CJD) or Gerstmann-Straussler-Scheinker Syndrome (GSS)*. Department of Health Circular PL(92)CO/4. London: Department of Health, 1994.
- Bell JE, Ironside JW. How to tackle a possible Creutzfeldt-Jakob disease autopsy. *J Clin Pathol* 1993;46:193-7.
- Brown P, Wolff A, Gajdusek DC. A simple and effective method for inactivating virus infectivity in formalin-fixed tissue samples from patients with Creutzfeldt-Jakob disease. *Neurology* 1990;40:887-90.
- Van der Valk P. Prion diseases: what will be next? *J Clin Pathol* 1998;51:265-9.
- Adams JH, Murray MF. *Atlas of post-mortem techniques in neuropathology*. Cambridge: Cambridge University Press, 1982.
- Lee WR. Examination of the globe: technical aspects. In: Lee WR. *Ophthalmic histopathology*. London: Springer-Verlag 1993:1-23.
- Lowe DG, Jeffrey IJM. Central nervous system and eye. In: Lowe DG, Jeffrey IJM. *Macro techniques in diagnostic histopathology*. Ipswich UK: Wolfe Medical Publications, 1990:136-40.
- Lee WR. *Ophthalmic histopathology*. London: Springer-Verlag, 1993.
- Gilliland MGF, Folberg R. Retinal hemorrhages: replicating the clinician's view of the eye. *Forensic Sci Int* 1992;56:77-80.



## ACP Best Practice No 164 : Necropsy techniques in ophthalmic pathology

M A Parsons and R D Start

*J Clin Pathol* 2001 54: 417-427

doi: 10.1136/jcp.54.6.417

---

Updated information and services can be found at:

<http://jcp.bmj.com/content/54/6/417.full.html>

---

*These include:*

### References

This article cites 14 articles, 4 of which can be accessed free at:

<http://jcp.bmj.com/content/54/6/417.full.html#ref-list-1>

Article cited in:

<http://jcp.bmj.com/content/54/6/417.full.html#related-urls>

### Email alerting service

Receive free email alerts when new articles cite this article. Sign up in the box at the top right corner of the online article.

---

### Topic Collections

Articles on similar topics can be found in the following collections

[Ethics](#) (74 articles)

[Legal and forensic medicine](#) (24 articles)

---

### Notes

---

To request permissions go to:

<http://group.bmj.com/group/rights-licensing/permissions>

To order reprints go to:

<http://journals.bmj.com/cgi/reprintform>

To subscribe to BMJ go to:

<http://group.bmj.com/subscribe/>