

Detection of fastidious bacteria in cardiac valves in cases of blood culture negative endocarditis

P Bruneval, J Choucair, F Paraf, J-P Casalta, D Raoult, F Scherchen, J-L Mainardi

Abstract

The diagnosis of blood culture negative endocarditis is still a problem. Fastidious bacteria such as bartonella and coxiella are responsible for cases of blood culture negative endocarditis, the identification of which is mainly based on serological and DNA studies only available in specialised centres. Therefore, a routine technique is needed in surgical pathology laboratories to detect these bacteria in cardiac valve tissue sections. This report describes a staining technique, the Giménez stain, feasible and sensitive in detecting bartonella and coxiella in two cases of blood culture negative endocarditis.

(*J Clin Pathol* 2001;54:238-240)

Keywords: endocarditis; bartonella; coxiella

The diagnosis of endocarditis remains a problem because about 10% of cases present with negative blood cultures.¹ There are at least two different reasons for the negativity of blood cultures. First, it is most frequently caused by previous antibiotic treatment. Second, it can be the result of bacterial species that are difficult to grow in the laboratory. Among these fastidious bacteria, some such as bartonella are responsible for re-emerging diseases in homeless people² and can cause endocarditis.³⁻⁴ *Coxiella burnetii* is another bacterium implicated in blood culture negative endocarditis.⁵⁻⁷ The identification of these agents requires specific methods mainly based on serological studies, blood and valve bacterial cultures under special conditions, or the amplification and sequencing of bacterial DNA extracted from valve tissue.²⁻³⁻⁷⁻⁸ In some cases, immunofluorescence or immunohistochemistry on valve tissue sections has been found to be diagnostic.³⁻⁹ All these techniques are only available in specialised laboratories. Gram staining of valve tissue sections yields poor results. Given this background, we tested the feasibility and efficacy of Giménez staining done on valve tissue sections in a routine surgical pathology laboratory to detect bartonella and coxiella in cases of endocarditis with negative blood cultures.

Case reports

CASE 1

A 39 year old alcoholic homeless man was admitted into hospital because of fever of 38.5°C and polyarthralgia. He had an aortic diastolic murmur. Haematological laboratory values were: haemoglobin, 75 g/litre; white blood cell count, 13 000/mm³; and platelet count, 111 000/mm³. Because the fever persisted, transthoracic and transoesophageal

echocardiographies were performed. They revealed aortic vegetations associated with aortic insufficiency. Four routine blood cultures were negative. The patient was treated with 8 g amoxicillin/day and 120 mg gentamicin/day. Despite the antibiotics, he remained febrile and the aortic insufficiency worsened. Surgical aortic valve replacement using a cryopreserved aortic valve homograft was performed two weeks after the beginning of treatment. The native aortic valve showed vegetations on the anterior right cusp, tearing and prolapse of the posterior cusp, and extensive loss of tissue in the anterior left cusp. The aortic valve bacterial culture was negative. An imprint of the valve tissue was performed. The serological studies showed IgG titres of 1/1600 against *Bartonella henselae*, 1/1600 against *B henselae* serotype Marseilles, and 1/3200 against *B quintana*. The serological studies against *Afipia felis*, brucella, coxiella, and chlamydia were negative. DNA extracted from the valve tissue was submitted for amplification of the intergenic spacer (IS) region as described previously.¹⁰ A specific signal was detected for *B quintana*.

CASE 2

In February 1999, a 44 year old Italian man was admitted for fever and surgical treatment of an aortic endocarditis of unknown aetiology. His remote medical history included rheumatic heart disease, and a splenectomy for congenital microspherocytic haemolytic anaemia. In 1996, he presented with fever and myalgia. He was treated with several short courses of doxycycline. In September 1998, dyspnea and worsened aortic insufficiency appeared despite a course of intravenous ceftriaxone followed by vancomycin and gentamicin. At this time, all routine blood cultures were negative. In January 1999, an aortic vegetation and a septal abscess were detected by echocardiography. He was then transferred for replacement of the aortic valve and treatment of the septal abscess. A cryopreserved aortic valve homograft was used. The aortic cusps were thickened and mildly calcified, and a small vegetation was adherent to the anterior cusp. Therefore, an imprint of the anterior cusp was performed. Serological tests for *Legionella pneumophila*, *Chlamydia psittaci*, *B quintana*, and *B henselae* were negative. The serological test for *C burnetii* was positive, with an IgG titre of 1/12800 and an IgA titre of 1/400 against phase I of *C burnetii*.¹¹ The bacterial cultures of valve tissue performed on endothelial cell cultures and the polymerase chain reaction (PCR) with amplification of the IS 1111 gene on DNA extracted from valve tissue¹² were both positive. The patient was treated with 200 mg

Pathology Laboratory,
Broussais Hospital,
Paris, France
P Bruneval
F Scherchen

Microbiology
Laboratory, Broussais
Hospital, 96 Rue
Didot, 75014 Paris,
France
J Choucair
J-L Mainardi

Pathology Laboratory,
Dupuytren Hospital, 2
Avenue M. Luther
King, 87042-Limoges,
France
F Paraf

Unité des Rickettsies,
Faculté de Médecine,
27 Boulevard Jean
Moulin,
13385-Marseille, Cedex
5, France
J-P Casalta
D Raoult

Correspondence to:
Dr Bruneval
patrick.bruneval@
brs.ap-hop-paris.fr

Accepted for publication
7 June 2000

doxycycline/day and 200 mg hydroxychloroquine sulphate/day. Two months later the patient was well.

Methods

In case 1, a small piece of formalin fixed aortic cusp measuring $5 \times 5 \times 3$ mm, moderately thickened and fibrous, without any gross vegetation, was available for pathology. In case 2, a 13 mm length fragment of valve tissue thickened by calcified fibrosis without gross vegetation, which was decalcified in RDO (Eurobio, Les Ulis, France) for six hours, was available. For this last case, a piece of aortic fibrous ring was also available. Paraffin wax sections were cut at $2 \mu\text{m}$ and stained with haematoxylin and eosin, Gram, Giemsa, and Giménez¹³ stains. The valve imprints were also stained with Gram and Giménez stains. Giménez staining was performed as follows: (1) the dewaxed sections were incubated at room temperature for two minutes with a freshly filtered solution made from 2 ml of the stock solution of basic fuchsin in 5 ml of buffer; (2) after rinsing well in tap water, they were incubated in malachite green for nine seconds; (3) after rinsing well in tap water, they were again incubated with the malachite green solution for nine seconds; (4) after rinsing well in tap water, the sections were air dried and mounted in Eukit (Labonord, Villeneuve d'Ascq, France).

STOCK SOLUTIONS

Stock solutions of basic fuchsin were made up as follows. Solution 1: 10 g of base fuchsin (RAL, Rieux, France) in 100 ml of 95% ethanol; solution 2: 11.25 g of phenol (Sigma, St Louis, Missouri, USA) in 250 ml of distilled water at 37°C ; mix solutions 1 and 2 in 650 ml of distilled water. The 0.8% (wt/vol) solution of malachite green was made up as follows: 2 g of malachite green oxalate (Merck, Darmstadt, Germany) in 250 ml of distilled water. Buffer: 3.5 ml of 0.2 M monosodium phosphate (Sigma) plus 15.5 ml of 0.2 M disodium phosphate (Sigma) in 19 ml of distilled water.

CONTROLS

Thirteen cases of streptococcus or staphylococcus endocarditis with valve tissue sections showing full blown inflammation and many Gram positive cocci were selected from pathology files. They were cases of rapidly progressive valve incompetence necessitating surgical valve replacement after a short antibiotic treatment. An additional case of *Staphylococcus epidermidis* aortic endocarditis treated with antibiotics for four weeks was also available: it showed mild chronic inflammation and Gram stain negativity. In all these cases, valve tissue sections were stained with the Giménez stain as described above.

Results

In case 1, the valve tissue showed replacement fibrosis associated with a focus of inflammatory cells and necrosis. Inflammation consisted of mononuclear cells mixed with rare polymorphonuclear cells. In the superficial aspect of the

valve, there was a thin fibrin vegetation without inflammation. Gram and Giemsa stains were negative. Giménez stain showed many intracellular short bacilli in the inflammatory focus in the valve. The bacilli strongly stained pink/red in a blue/green background (fig 1A). The valve imprint showed the same bacilli.

In case 2, the valve tissue showed fibrosis and large inflammatory foci with necrosis, mononuclear cells, and many polymorphonuclear cells. A superficial thin, leucocyte rich fibrin vegetation was observed. Gram and Giemsa stains were negative. Giménez stain showed many intracellular thin bacilli in the inflammatory focus in the valve (fig 1B). The valve imprint showed the same bacilli with Giménez stain, whereas the Giemsa and the Gram stains were negative.

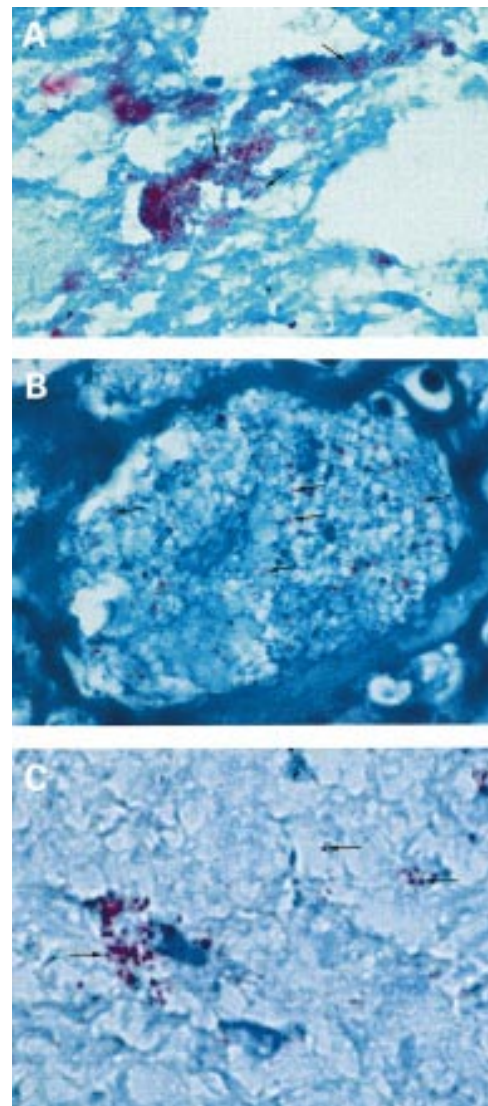


Figure 1 (A) Detection of bacteria in a case of *Bartonella quintana* endocarditis using the Giménez stain. The bacteria (arrows) appear as small intracellular rods stained pink/red. (B) Detection of bacteria in the inflammatory infiltrate in a case of *Coxiella burnetii* endocarditis using Giménez stain. The bacteria (arrows) are stained pink/red, contrasting with the background. (C) Detection of bacteria using Giménez stain in a case of Gram stain negative *Staphylococcus epidermidis* aortic endocarditis after prolonged antibiotic treatment.

Of the 13 control cases of Gram stain positive streptococcus or staphylococcus acute endocarditis, three cases were also positive with the Giménez stain showing pink/red cocci; staining was much less obvious than with the Gram stain, and 10 cases were negative. In the case of Gram stain negative *S epidermidis* aortic endocarditis after prolonged antibiotic treatment, Giménez stain showed a few positive residual intracellular bacteria in the inflammatory foci (fig 1C).

Discussion

In both cases, endocarditis was confirmed by histological examination of the valve showing inflammation. However, standard diagnostic tests such as blood and valve cultures in routine bacteriological media, Giemsa, and Gram stains of valve tissue sections failed to demonstrate the aetiology. Finally, endocarditis was related to *B quintana* or *C burnetti* by serological studies and confirmed by amplification of DNA extracted from the valves in a specialised laboratory.

Given the increasing incidence of infections with fastidious Gram negative bacteria, mainly *B quintana*,^{3,4} but also *B henselae*,^{14,15} causing endocarditis and the fact that endocarditis can result from infection with *C psittaci*¹⁶ and *C burnetti*,⁵⁻⁷ it has become a major challenge for the pathologist to detect bacteria in valve tissue sections to help in diagnoses where the usual microbiological techniques fail and where more sophisticated techniques, only available in specialised laboratories, are required.

In specialised centres where specific antibodies are available, immunofluorescence or immunohistochemistry can be performed in valve tissue sections to detect bartonella^{3,14} and *C burnetti*.⁹ Gram and Giemsa stains are not always sensitive for bartonella^{3,15} and *C burnetti*.¹⁷ The Warthin-Starry stain is difficult to perform and to analyse because of frequent heavy background staining, although it has been used to detect bartonella in tissue sections.^{15,18} Therefore, a feasible and sensitive staining technique for the detection of fastidious bacteria is needed in pathology laboratories dealing with the surgical pathology of cardiac valves. The Giménez stain has been performed in microbiology laboratories to detect such bacteria on pus and effusion drainage liquid¹⁹ smears, and on lymph node and valve imprints. We show here that it can be used successfully

on formalin fixed, paraffin wax embedded tissue sections, even after mild decalcification, as long as the sections are thin (2–3 µm). The Giménez stain yields clear cut staining of bartonella and coxiella, which appear pink/red, whereas the underlying tissue is blue/green. Furthermore, it sometimes stains usual bacteria, both Gram positive¹³ and Gram negative, after prolonged antibiotic treatment. In the latter situation, Giménez stain positivity does not assume that the bacteria are still alive. Thus, we suggest the systematic use of the Giménez stain for the pathological examination of valves in cases of endocarditis.²⁰

We thank P Kitmacher for the photographs.

- Delahaye F, Goulet V, Lacassin F, *et al.* Characteristics of infective endocarditis in France in 1991. A 1-year survey. *Eur Heart J* 1995;16:394–401.
- Brouqui P, Lascola B, Roux V, *et al.* Chronic Bartonella quintana bacteremia in homeless patients. *N Engl J Med* 1999;340:184–9.
- Drancourt M, Mainardi JL, Brouqui P, *et al.* Bartonella (Rochalimaea) quintana endocarditis in three homeless men. *N Engl J Med* 1995;332:419–23.
- Raoult D, Fournier PE, Drancourt M, *et al.* Diagnosis of 22 new cases of Bartonella endocarditis. *Ann Intern Med* 1996;125:646–52.
- Hoen B, Selton-Suty C, Lacassin F, *et al.* Infective endocarditis in patients with negative blood cultures: analysis of 88 cases from a one-year nationwide survey in France. *Clin Infect Dis* 1995;20:501–6.
- Barbari EF, Cockerill FR, 3rd, Steckelberg JM. Infective endocarditis due to unusual or fastidious microorganisms. *Mayo Clin Proc* 1997;72:532–42.
- Stein A, Raoult D. Q fever endocarditis. *Eur Heart J* 1995;16(suppl B):19–23.
- Stein A, Raoult D. Detection of Coxiella burnetti by DNA amplification using polymerase chain reaction. *J Clin Microbiol* 1992;30:2462–6.
- Brouqui P, Dumier JS, Raoult D. Immunohistologic demonstration of Coxiella burnetti in the valves of patients with Q fever endocarditis. *Am J Med* 1994;97:451–8.
- Roux V, Raoult D. Inter- and intraspecies identification of Bartonella (Rochalimaea) species. *J Clin Microbiol* 1995;33:1573–9.
- Tissot-Dupont H, Thirion X, Raoult D. Q fever serology: cutoff determination for microimmunofluorescence. *Clin Diagn Lab Immunol* 1994;1:189–96.
- Fournier PE, Marrie TJ, Raoult D. Diagnosis of Q fever. *J Clin Microbiol* 1998;36:1823–34.
- Giménez DF. Staining Rickettsiae in yolk-sack cultures. *Stain Technol* 1964;39:135–40.
- Baorto E, Payne RM, Slater LN, *et al.* Culture-negative endocarditis caused by Bartonella henselae. *J Pediatr* 1998;132:1051–4.
- Hadfield TL, Warren R, Kass M, *et al.* Endocarditis caused by Rochalimaea henselae. *Hum Pathol* 1993;24:1140–1.
- Shapiro RD, Kenney SC, Johnson M, *et al.* Chlamydia psittaci endocarditis diagnosed by blood culture. *N Engl J Med* 1992;326:1192–218.
- Muhlemann K, Matter L, Meyer B, *et al.* Isolation of Coxiella burnetti from heart valves of patients treated for Q fever endocarditis. *J Clin Microbiol* 1995;33:428–31.
- Gasquet S, Maurin M, Brouqui P, *et al.* Bacillary angiomatosis in immunocompetent patients. *AIDS* 1998;12:1793–803.
- Jourdain P, Blanchard H, Cabanes L, *et al.* Bartonella quintana endocarditis. Aortic localization and mitral valve abscess. *Arch Mal Coeur Vaiss* 1998;91:1271–5.
- Woods GL, Walker DH. Detection of infection or infectious agents by use of cytologic and histologic stains. *Clin Microbiol Rev* 1996;9:382–404.



Detection of fastidious bacteria in cardiac valves in cases of blood culture negative endocarditis

P Bruneval, J Choucair, F Paraf, et al.

J Clin Pathol 2001 54: 238-240

doi: 10.1136/jcp.54.3.238

Updated information and services can be found at:

<http://jcp.bmj.com/content/54/3/238.full.html>

These include:

References

This article cites 19 articles, 9 of which can be accessed free at:

<http://jcp.bmj.com/content/54/3/238.full.html#ref-list-1>

Article cited in:

<http://jcp.bmj.com/content/54/3/238.full.html#related-urls>

Email alerting service

Receive free email alerts when new articles cite this article. Sign up in the box at the top right corner of the online article.

Topic Collections

Articles on similar topics can be found in the following collections

[Morbid anatomy / surgical pathology](#) (71 articles)

Notes

To request permissions go to:

<http://group.bmj.com/group/rights-licensing/permissions>

To order reprints go to:

<http://journals.bmj.com/cgi/reprintform>

To subscribe to BMJ go to:

<http://group.bmj.com/subscribe/>