

Malignant mesothelioma: a comparison of biopsy and postmortem material by light microscopy and immunohistochemistry

F Roberts, A E McCall, R A Burnett

Abstract

Aims—The diagnosis of malignant mesothelioma in pleural biopsies can be difficult. Survival is short and consequently many of these cases are submitted to necropsy to assist with medicolegal claims. This study compares the histological appearances and immunohistochemical profile of nine biopsy specimens with corresponding postmortem specimens.

Methods—Archival, formalin fixed, paraffin wax embedded material was obtained from nine biopsy and corresponding postmortem cases of malignant mesothelioma. The specimens were examined by light microscopy and stained with an immunohistochemical panel of 12 commercially available antibodies including CAM5.2, HBME-1, and Ber-EP4, and antibodies to thrombomodulin, calretinin, CD44H, WT-1, carcinoembryonic antigen, Leu-M1, epithelial membrane antigen and p53.

Results—There was greater variation in the range of histological appearances of mesotheliomas in postmortem specimens compared with biopsy specimens. There was also variability in the immunohistochemical staining pattern for certain antibodies including HBME-1, and Ber-EP4 and antibodies to calretinin, CD44H, WT-1, and p53.

Conclusions—All available information should be taken into account in the histological diagnosis of malignant mesothelioma. Interpretation of the immunohistochemical profile should be regarded with some caution when only postmortem material is available. When reporting a postmortem case of suspected mesothelioma, the pathologist should seek to review all available biopsy material in conjunction with the necropsy.

(*J Clin Pathol* 2001;54:766-770)

Keywords: malignant mesothelioma; biopsy; necropsy; immunohistochemistry

Malignant mesothelioma is a tumour that arises from the surface serosal cells of the pleura, peritoneum, pericardium, or tunica vaginalis testis. The most frequent location of this tumour is the pleura. Mesothelioma is closely related to asbestos exposure. In the Clydebank district of Glasgow, where blue asbestos was widely used for lagging pipes and boilers in the shipbuilding industry, the incidence is six times higher than in the rest of Scotland.¹

The accurate diagnosis of malignant mesothelioma is important for clinical and medico-legal reasons. Early and precise diagnosis of biopsy samples will influence clinical management and avoid unnecessary invasive diagnostic procedures. Furthermore, from a legal viewpoint, compensation claims from workers exposed to asbestos demands an accurate diagnosis of malignant mesothelioma. However, the histological diagnosis of malignant tumours of the serosal surfaces can be difficult. Malignant mesothelioma can show diverse histopathological appearances. Furthermore, the pleura is a common site for metastatic disease, florid reactive fibrosis, mesothelial hyperplasia, and rarely primary sarcomas. All of these can mimic mesothelioma.

Nearly all patients with malignant mesothelioma die within 12 to 18 months of diagnosis, leaving relatives to pursue common law compensation, from former employers, through the courts. For this reason, a necropsy is usually performed, often on the instructions of the procurator fiscal, on most patients dying of malignant mesothelioma, whether or not a positive biopsy diagnosis was obtained during life.

Immunohistochemistry is generally considered to be the most useful ancillary technique for the diagnosis of malignant mesothelioma. However, no antibody is entirely sensitive or specific for mesothelioma and there is considerable variation in staining patterns between different studies.²⁻⁷

The aim of our study was to compare the histological appearance and immunohistochemical staining patterns of malignant mesotheliomas from matched biopsy and postmortem specimens. For this purpose, we used a panel of 12 commercially available antibodies. The panel included antibodies generally considered most useful as markers for differentiating adenocarcinoma (antibodies against carcinoembryonic antigen (CEA), human epithelial antigen (Ber-EP4), and Leu-M1), sarcoma (CAM5.2 and anti-vimentin), and reactive mesothelial proliferations (antibodies against epithelial membrane antigen (EMA) and p53) from mesothelioma, in addition to putative selective markers for mesothelioma (antibodies against human mesothelial cell antigen (HBME-1), thrombomodulin, calretinin, CD44H, and WT-1).

Materials and methods

MATERIALS

We retrieved biopsy and corresponding postmortem tissue from nine cases of malignant mesothelioma from the pathology files of the

Department of
Pathology, Victoria
Infirmary, Langside
Road, Glasgow
G42 9TY, UK
F Roberts

University
Department of
Pathology, Western
Infirmary Glasgow,
Glasgow G11 6NT, UK
A E McCall
R A Burnett

Correspondence to:
Dr Roberts
f.roberts@spr.co.uk

Accepted for publication
11 April 2001

Table 1 Details of antibodies used for immunohistochemistry

Antibody/antigen	Clone	Source	Dilution	Pretreatment
CAM5.2	—	Becton Dickinson	1/10	Microwave
Vimentin	Vim3B4	Dako	1/400	Trypsin
Human mesothelial cell antigen	HBME-1	Dako	1/100	Trypsin
Thrombomodulin	1009	Dako	1/50	None
Calretinin	—	Chemicon	1/4000	Microwave
CD44H	F10-44-2	Novocastra	1/75	Microwave
WT-1	6F-H2	Dako	1/100	Pepsin
Carcinoembryonic antigen	12-140-10	Novocastra	1/50	Trypsin
Leu-M1	CBD1	Dako	1/20	Microwave
Human epithelial antigen	Ber-EP4	Dako	1/100	Trypsin
Epithelial membrane antigen	E29	Dako	1/50	None
p53	DO-7	Dako	1/200	Microwave

Becton Dickinson, Oxford, UK; Dako, Ely, Cambridgeshire, UK; Chemicon, Welldstone, Harrow, UK; Novocastra, Newcastle, UK; TCS Biological, Claydon, UK; Genzyme, Cambridge, UK.

Western Infirmery and Victoria Infirmery in Glasgow. The nine cases, which all involved the pleura, were diagnosed between 1990 and 1999. In eight cases, the necropsy was performed between 24 and 48 hours of death. In one case, the necropsy was performed within 72 hours of death. The biopsy specimens comprised a mixture of needle and thoracoscopic biopsies and they had all been formalin fixed and paraffin wax embedded. The postmortem tissues were also formalin fixed and paraffin wax embedded. The needle biopsies comprised three to four cores of tissue all processed as one paraffin wax block. The thoracoscopic biopsies consisted of three to four pieces of tissue, the largest piece measuring approximately 20 mm in maximum diameter. Multiple blocks of tumour were available for each postmortem case. For both thoracoscopic biopsy and postmortem specimens, all slides were assessed and the most appropriate block showing the major features of the tumour, with limited necrosis and autolysis, was selected.

IMMUNOHISTOCHEMISTRY

Table 1 gives the details of the antibodies selected. For immunohistochemistry, 3 µm sections were cut from the paraffin wax blocks, dewaxed, and serially rehydrated in water. Sections were then immunostained using a standard avidin-biotin complex technique. Briefly, endogenous peroxidase activity was blocked

with 3% hydrogen peroxide in methanol and endogenous biotin activity was blocked using avidin and biotin. For antigen retrieval, slides were microwaved in 1mM EDTA, pH 8.0, for 10 minutes or incubated with 0.1% trypsin, pH 7.8, for 10 minutes or 0.4% pepsin, pH 2.5, for 30 minutes. Details of antigen retrieval for each antibody, dilutions of antibody used, and incubation times are also shown in table 1. Appropriate control material (according to the manufacturer's instructions) was used for each antibody. For negative controls the primary antibody was substituted with normal horse serum. Immunohistochemical staining was visualised with 3-3' diaminobenzidine.

INTERPRETATION OF RESULTS

The slides were evaluated semiquantitatively and the proportion of positive cells estimated as follows: 1, staining of 10–39% of the tumour or reactive mesothelial cells; 2, staining of 40–79% of the tumour or reactive mesothelial cells; 3, staining of 80–100% of the tumour or reactive mesothelial cells. All cases showing staining of less than 10% of the tumour cells were regarded as negative. The staining pattern was recorded as membranous, cytoplasmic, or nuclear for each antibody. The sections were assessed independently by two observers (FR and AEM). In cases where there was substantial disagreement both observers reassessed the slides and a consensus was reached.

Results

The results are summarised in table 2 and illustrated in fig 1.

LIGHT MICROSCOPY

The nine biopsy specimens comprised four epithelioid, four sarcomatoid, and one biphasic mesothelioma. Three of the four epithelioid mesotheliomas showed a solid pattern and one showed a tubulopapillary pattern. The four corresponding postmortem specimens were also of epithelioid subtype, although one case

Table 2 Comparison of immunohistochemical staining for biopsy and postmortem specimens

Specimen	Subtype	CAM5.2	VIM	HBME-1	TM	CAL	CD44H	WT-1	CEA	Leu-M1	Ber-EP4	EMA	p53
1B	Epithelioid	3C	0	1M	0	2C/N	0	1N	0	0	0	1M	2N
1P	Epithelioid	3C	0	2M	0	1C	0	0	0	0	0	2M	2N
2B	Epithelioid	3C	0	0	1M	0	1M	0	0	0	0	3M	2N
2P	Epithelioid	3C	0	2M	0	0	2M	0	1C	0	2M	2M	0
3B	Epithelioid	3C	0	1M	1M	2C/N	3M	3N	0	0	0	1M	2N
3P	Epithelioid	3C	0	2M	1M	0	2M	1N	0	0	0	1M	1N
4B	Epithelioid	3C	0	1M	1M	2C/N	2M	1N	0	0	0	2M	3N
4P	Epithelioid	3C	0	3M	1M	0	0	0	0	0	2M	2M	1N
5B	Biphasic	3C	0	2M	0	3C/N	2M	2N	0	0	0	3M	1N
5P	Epithelioid	3C	0	3M	0	2C	0	0	0	0	2M	3M	0
6B	Sarcomatoid	3C	3C	0	0	0	3M	0	0	0	0	1M	2N
6P	Sarcomatoid	3C	1C	0	0	0	2M	0	0	0	0	1M	0
7B	Sarcomatoid	2C	3C	0	0	0	2M	0	0	0	0	0	1N
7P	Sarcomatoid	3C	3C	0	0	0	0	0	0	0	0	1M	0
8B	Sarcomatoid	2C	3C	0	0	0	3M	0	0	0	0	2M	2N
8P	Sarcomatoid	3C	3C	0	0	0	3M	0	0	0	0	2M	2N
9B	Sarcomatoid	0	3C	0	0	0	3M	0	0	0	0	0	3N
9P	Sarcomatoid	0	2C	0	0	0	3M	0	0	0	0	0	1N

Specimen: B, biopsy; P, postmortem.

Staining: 0, less than 10% of tumour cells stained; 1, 10–39% of tumour cells stained; 2, 40–79% of tumour cells stained; 3, 80–100% of tumour cells stained; C, cytoplasmic staining; M, membranous staining; N, nuclear staining.

VIM, anti-vimentin; TM, anti-thrombomodulin; CAL, anti-calretinin; CEA, anti-carcinoembryonic antigen; EMA, anti-epithelial membrane antigen.

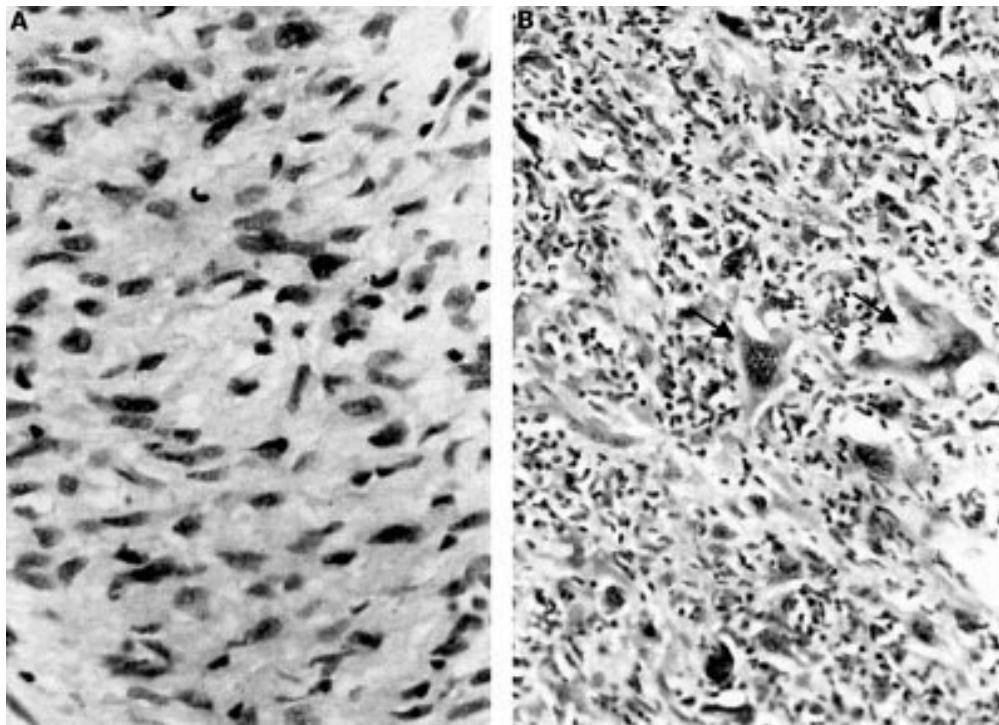


Figure 1 (A) Biopsy of sarcomatoid mesothelioma (case 8). This case shows a typical spindle cell pattern (haematoxylin and eosin; original magnification, $\times 400$). (B) Postmortem appearances of the same case. The tumour is composed of bizarre, pleomorphic cells (arrows), which are surrounded by inflammatory cells (haematoxylin and eosin; original magnification, $\times 400$).

showed more pleomorphism, with scattered multinucleated giant cells, and another case showed a tubulopapillary pattern in addition to solid areas.

Three of the four sarcomatoid mesotheliomas showed a similar spindle cell pattern in the corresponding postmortem specimen. In one case the postmortem appearances were those of an undifferentiated sarcoma with sheets of large bizarre cells (fig 1). In two sarcomatoid specimens there were areas showing prominent desmoplasia. Two cases showed extensive necrosis.

One biopsy specimen showed a biphasic pattern; however, the corresponding postmortem specimen showed an epithelioid tumour with a predominantly tubulopapillary pattern.

IMMUNOHISTOCHEMISTRY

CAM 5.2 and vimentin

In biopsy and postmortem specimens, all but one mesothelioma (of sarcomatoid subtype) showed strong cytoplasmic staining with CAM5.2.

Vimentin was expressed in four of nine mesotheliomas in both the biopsy and postmortem specimens. The positive tumours were of the sarcomatoid subtype. Fewer cells stained in postmortem specimens than in the biopsy specimens.

HBME-1, thrombomodulin, calretinin, CD44H, and WT-1

Four biopsy specimens (three epithelioid and one biphasic subtype) showed positive membranous staining with HBME-1. The postmortem specimens were also positive for HBME-1 in these cases. In addition, a further epithelioid

tumour was positive in the postmortem specimen. HBME-1 staining was stronger and more generalised in postmortem specimens than in the biopsy specimens.

Three epithelioid mesotheliomas showed weak positive membranous staining for thrombomodulin in biopsy specimens. Corresponding postmortem specimens showed similar weak positive membranous staining in two cases. The sarcomatoid and biphasic mesotheliomas were negative.

Four biopsy specimens (three epithelioid and one biphasic) showed moderate to strong nuclear and cytoplasmic staining for calretinin. The corresponding postmortem specimens showed diffuse cytoplasmic staining without nuclear staining in two cases.

Eight biopsy specimens (three epithelioid, one biphasic, and four sarcomatoid subtype) showed positive membranous staining for CD44H. Five corresponding postmortem specimens (three epithelioid and two sarcomatoid subtype) showed positive staining.

Four biopsy specimens (three epithelioid and one biphasic subtype) showed positive nuclear staining for WT-1. Only one of the corresponding postmortem specimens, of epithelioid subtype, showed weak, focal nuclear staining for WT-1.

All nine biopsy specimens stained positively with at least one of these five antibodies. Two specimens, both of epithelioid subtype were positive for all five antibodies (HBME-1 and antibodies to thrombomodulin, calretinin, CD44H, and WT-1). One specimen, of biphasic subtype, was positive with four antibodies (all but anti-thrombomodulin). The remaining two epithelioid tumours were positive with

three and two antibodies, respectively. The four sarcomatoid mesotheliomas were positive for CD44H only.

Seven of the nine postmortem specimens stained positively with at least one of these five antibodies. No specimen was positive for all five antibodies. The two biopsies that had stained positively with all five antibodies were positive for four and two antibodies in the corresponding postmortem tissue. The remaining three specimens of epithelioid subtype stained positively for two antibodies. Two sarcomatoid mesotheliomas remained positive for CD44H only and the remaining two sarcomatoid tumours were negative for all five antibodies.

CEA, Leu-M1, and Ber-EP4

All nine biopsies were negative for CEA, Ber-EP4, and Leu-M1. All postmortem mesotheliomas were also negative for Leu-M1. Focal positive staining for CEA was observed in one postmortem mesothelioma of epithelioid subtype. Three postmortem tumour samples, of the epithelioid subtype, showed focal positive membranous staining with Ber-EP4.

EMA and p53

Seven biopsy specimens showed positive membranous staining for EMA. The corresponding seven postmortem specimens were also positive.

All nine biopsy specimens showed moderate to intense nuclear staining for p53. Nuclear staining was present in five of the postmortem specimens but was more focal than in the corresponding biopsy.

Discussion

Accurate histological diagnosis of mesothelioma is vital for clinical and medicolegal purposes. In life, the clinical presentation and the radiological findings may not always be useful. Peripheral lung adenocarcinoma or metastatic adenocarcinoma to the pleura can be clinically indistinguishable from pleural mesothelioma.⁸ Even at necropsy the characteristic gross appearances can be mimicked by pleural obliteration by metastatic tumour or diffuse pleural fibrosis.⁸ Alternatively, a mesothelioma forming a more localised mass may mimic a peripheral lung cancer.⁸

However, despite the well established histological criteria for the diagnosis of malignant mesothelioma, the diagnosis of this tumour can be difficult. No two mesotheliomas are exactly alike and there is often striking variation in different portions of the same neoplasm.⁹ This heterogeneity of mesotheliomas can present problems, particularly in biopsy specimens. For example, biopsies that contain only the epithelioid component of a biphasic tumour may mimic metastatic carcinoma.¹⁰ Conversely, very occasionally, the spindle cell component of a biphasic tumour can mimic primary or secondary sarcoma or localised fibrous tumour.¹¹ Furthermore, sarcomatoid mesotheliomas can show extreme variability in cellularity. Biopsy of a desmoplastic area can show dense paucicellular areas of hyaline fibrosis that can mimic pleural plaques or pleural fibrosis.¹²

In such cases, the ability to sample the tumour extensively at necropsy may provide a fuller histological picture and thus facilitate the correct diagnosis.

In our study, the nine specimens selected had a positive diagnosis in both biopsy and postmortem material. It is noteworthy that two of the sarcomatoid mesotheliomas showed prominent desmoplastic areas in postmortem material. Furthermore, two postmortem specimens showed extensive necrosis. Needle biopsy of either desmoplastic or necrotic areas would have made firm histological diagnosis during life difficult. In one sarcomatoid case, the postmortem appearances were those of an undifferentiated sarcoma with large bizarre nuclei, considerably different from the spindle cell tumour seen in the biopsy. Similarly, dedifferentiation to a more pleomorphic tumour was seen in one of the epithelioid mesotheliomas at necropsy. Tumour dedifferentiation is not uncommon in advanced mesothelioma and consequently is not infrequently seen in postmortem specimens.⁹ We have seen cases where the diagnosis could not have been made on the postmortem findings without recourse to the original biopsy taken during life. In such dedifferentiated cases, extensive tumour sampling is recommended in an attempt to identify areas of more conventional mesothelioma. The previous biopsy appearances should also be taken into account when reporting such cases.

As previously mentioned, immunohistochemistry is generally considered to be the most useful ancillary technique for the diagnosis of malignant mesothelioma. To date, there is no single immunohistochemical marker that is both entirely specific and sensitive for distinguishing between mesothelioma, adenocarcinoma, sarcoma, and reactive mesothelial hyperplasia. Therefore, most laboratories use an immunohistochemical panel to facilitate in the diagnosis of mesothelioma. That said, although there is general agreement that a panel of antibodies should be used, there is a wide variety of opinions regarding the effectiveness of some of the antibodies used.^{5-7 13-15} The five mesothelioma associated antibodies stained mesotheliomas with an epithelioid component more consistently than purely sarcomatoid mesotheliomas. However, CD44H was positive in all sarcomatoid cases. As expected, the adenocarcinoma associated antibodies were all negative. The antibodies to EMA and p53, which can help distinguish between mesothelioma and reactive mesothelial proliferations, were positive in most of these malignant tumours.

The staining pattern in the biopsy cases was similar to an immunohistochemical study of 112 mesotheliomas performed in our laboratory.¹⁶ When comparing biopsy and postmortem cases we found generalised agreement in staining patterns for some antibodies (for example, CAM5.2 and antibodies to Leu-M1, vimentin, thrombomodulin, CEA, and EMA), but considerable variation between biopsy and postmortem material for other antibodies,

including several of the putative positive markers of mesothelioma, Ber-EP4 and anti-p53.

In particular, staining with HBME-1 was stronger and more generalised in postmortem specimens, whereas staining with antibodies to calretinin, CD44H, and WT-1 was reduced. Furthermore, staining for calretinin was cytoplasmic only, in contrast with the nuclear and cytoplasmic staining seen in biopsy specimens. There was a similar reduction in nuclear staining for p53, with only five mesotheliomas showing mild to moderate, generalised nuclear staining in postmortem tissue.

In addition to variation in histological appearances, the antigenicity of any tumour will be affected by heterogeneity and dedifferentiation, resulting in overexpression or underexpression of certain antigens. This could account for many of the discrepancies described in other studies.

Needle biopsies are more likely to be taken from the peripheral and thus better vascularised aspects of the tumour. Furthermore, they usually undergo rapid fixation, thus optimising antigenicity for immunohistochemistry. The delay in tissue fixation and in general the larger size of postmortem blocks will have significant effects on immunohistochemistry. In most of these cases, necropsy was performed within 48 hours of death and autolysis was not prominent in the blocks selected for immunohistochemistry. However, Attanoos *et al* compared WT-1 staining in biopsy and postmortem tissue and concluded that tissue fixation is crucial to the detection of WT-1.¹¹ In particular, the central parts of larger specimens gave a false negative reaction because the fixative had not penetrated and in postmortem material the antigen could not be detected. Similar problems with fixation and the size of sections have been recorded for p53.^{17 18}

In conclusion, it is important that all available information is taken into account in the diagnosis of malignant mesothelioma. The interpretation of both histological appearances and the immunohistochemical profile should be regarded with some caution when only postmortem material is available. The pathologist should seek to review all available biopsy material in conjunction with the necropsy.

We are grateful to D Cossar for his technical expertise.

- 1 Dorward A, Stack B. Diffuse malignant pleural mesothelioma in Glasgow. *Br J Dis Chest* 1981;75:397-402.
- 2 Wirth PR, Legier J, Wright G, Jr. Immunohistochemical evaluation of seven monoclonal antibodies for differentiation of mesothelioma from lung adenocarcinoma. *Cancer* 1991;67:655-62.
- 3 Ordóñez N. The value of antibodies 44-3A6, SM3, HBME-1 and thrombomodulin in differentiating epithelial pleural mesothelioma from lung adenocarcinoma. A comparative study with other commonly used antibodies. *Am J Surg Pathol* 1997;21:1399-408.
- 4 Riera JR, Astengo-Osuna C, Longmate JA, *et al*. The immunohistochemical diagnostic panel for epithelial mesothelioma: a reevaluation after heat-induced epitope retrieval. *Am J Surg Pathol* 1997;21:1409-19.
- 5 García-Prats MD, Ballestin C, Sotelo T, *et al*. A comparative evaluation of immunohistochemical markers for the differential diagnosis of malignant pleural tumours. *Histopathology* 1998;32:462-72.
- 6 Cury PM, Butcher DN, Fisher C, *et al*. Value of the mesothelium-associated antibodies thrombomodulin, cytokeratin 5/6, calretinin, and CD44H in distinguishing epithelioid pleural mesothelioma from adenocarcinoma metastatic to the pleura. *Mod Pathol* 2000;13:107-12.
- 7 Oates J, Edwards C. HBME-1, MOC-31, WT1 and calretinin: an assessment of recently described markers for mesothelioma and adenocarcinoma. *Histopathology* 2000;36:341-7.
- 8 Hasleton P. Pleural disease. In: Hasleton P, ed. *Spencer's pathology of the lung*, 5th ed. New York: McGraw-Hill, 1996:1131-10.
- 9 Attanoos RL, Gibbs AR. Pathology of malignant mesothelioma. *Histopathology* 1997;30:403-18.
- 10 Skov B, Lauritzen A, Hirsch F, *et al*. The histopathological diagnosis of malignant mesothelioma v pulmonary adenocarcinoma: reproducibility of the histological diagnosis. *Histopathology* 1994;24:553-7.
- 11 Attanoos R, Dojcinov S, Webb R, *et al*. Anti-mesothelial markers in sarcomatoid mesothelioma and other spindle cell neoplasms. *Histopathology* 2000;37:224-31.
- 12 Mangano WE, Cagle PT, Churg A, *et al*. The diagnosis of desmoplastic malignant mesothelioma and its distinction from fibrous pleurisy: a histologic and immunohistochemical analysis of 31 cases including p53 immunostaining. *Am J Clin Pathol* 1998;110:191-9.
- 13 Brown R, Clarak G, Tandon A, *et al*. Multiple-marker immunohistochemical phenotypes distinguishing malignant pleural mesothelioma from pulmonary adenocarcinoma. *Hum Pathol* 1993;24:347-54.
- 14 Betta PG, Andron A, Donna A, *et al*. Malignant mesothelioma of the pleura. The reproducibility of the immunohistological diagnosis. *Pathol Res Pract* 1997;193:759-65.
- 15 Ordóñez N. The immunohistochemical diagnosis of epithelial mesothelioma. *Hum Pathol* 1999;30:313-23.
- 16 Roberts F, Harper CM, Downie I, *et al*. Immunohistochemical analysis still has a limited role in the diagnosis of malignant mesothelioma. A study of thirteen antibodies. *Am J Clin Pathol* [In press.]
- 17 Fisher CJ, Gillett CE, Vojtesek B, *et al*. Problems with p53 immunohistochemical staining: the effect of fixation and variation in the methods of evaluation. *Br J Cancer* 1994;69:26-31.
- 18 Bassarova AV, Popov AA. Immunohistochemical detection of p53—effect of fixation and methods of antigen retrieval. *Folia Histochem Cytobiol* 1998;36:127-32.



Malignant mesothelioma: a comparison of biopsy and postmortem material by light microscopy and immunohistochemistry

F Roberts, A E McCall and R A Burnett

J Clin Pathol 2001 54: 766-770

doi:

Updated information and services can be found at:

<http://jcp.bmj.com/content/54/10/766.full.html>

These include:

References

This article cites 16 articles

<http://jcp.bmj.com/content/54/10/766.full.html#ref-list-1>

Email alerting service

Receive free email alerts when new articles cite this article. Sign up in the box at the top right corner of the online article.

Topic Collections

Articles on similar topics can be found in the following collections

[Clinical diagnostic tests](#) (637 articles)

[Respiratory cancer](#) (22 articles)

[Breast cancer](#) (378 articles)

[Ethics](#) (74 articles)

[Legal and forensic medicine](#) (24 articles)

[Immunology \(including allergy\)](#) (1279 articles)

Notes

To request permissions go to:

<http://group.bmj.com/group/rights-licensing/permissions>

To order reprints go to:

<http://journals.bmj.com/cgi/reprintform>

To subscribe to BMJ go to:

<http://group.bmj.com/subscribe/>