

# Malignant lymphoma of the urinary bladder: a clinicopathological study of 11 cases

A W Bates, A J Norton, S I Baithun

## Abstract

**Aim**—To report the clinical and histological features and outcome of primary and secondary malignant lymphomas of the urinary bladder.

**Methods**—Eleven cases of malignant lymphoma of the urinary bladder were obtained from the registry of cases at St Bartholomews and the Royal London Hospitals. The lymphomas were classified on the basis of their morphology and immunophenotype, and the clinical records were reviewed.

**Results**—There were six primary lymphomas: three extranodal marginal zone lymphomas of mucosa associated lymphoid tissue (MALT) type and three diffuse large B cell lymphomas. Of the five secondary cases, four were diffuse large B cell lymphomas, one secondary to a systemic follicular follicle centre lymphoma, and one nodular sclerosis Hodgkins disease. Four patients with secondary lymphoma for whom follow up was available had died of disease within 13 months of diagnosis. Primary lymphomas followed a more indolent course. In one case, there was evidence of transformation from low grade MALT-type to diffuse large B cell lymphoma. The most common presenting symptom was haematuria. Cystoscopic appearances were of solid, sometimes necrotic tumours resembling transitional cell carcinoma, and in one case the tumours were multiple. These cases represented 0.2% of all bladder neoplasms.

**Conclusions**—Diffuse large B cell lymphoma and MALT-type lymphoma are the most common primary malignant lymphomas of the bladder. Lymphoepithelial lesions in MALT-type lymphoma involve transitional epithelium, and their presence in high grade lymphoma suggests a primary origin owing to transformation of low grade MALT-type lymphoma. Primary and secondary diffuse large B cell lymphomas of the bladder are histologically similar, but the prognosis of the former is favourable.

(*J Clin Pathol* 2000;53:458–461)

Keywords: bladder; lymphoma; mucosa associated lymphoid tissue lymphoma

Extranodal marginal zone lymphoma of mucosa associated lymphoid tissue type (MALT-type lymphoma) of the urinary bladder, first described in 1990, is the most common primary bladder lymphoma,<sup>1</sup> and lesions that were previously described as reactive processes, “pseudolymphomas”, or low grade lymphomas of nodal type are now recognised as belonging to this group. The MALT concept provides a mechanism by which malignant lymphomas could develop in the bladder, as they do in other sites that normally possess no lymphoid tissue, after chronic inflammation.<sup>2</sup> Primary high grade B cell lymphoma of the bladder is about as common as low grade disease, constituting 50% of the 72 primary lymphomas of the bladder reported up to 1997.<sup>1</sup> Primary Hodgkin’s lymphoma of the bladder is a rarity, with only two previous reported cases.<sup>3</sup> Here, we review the clinical and histological findings in a series of 11 primary and secondary lymphomas of the bladder.

**Methods**

Cases of malignant lymphoma of the bladder were identified in the files of the institute of pathology at the Royal London Hospital and St Bartholomews Hospital. The histological appearances and clinical findings were reviewed, and the cases were classified according to the revised European-American lymphoma (REAL) classification.<sup>4</sup> Clinical information was obtained from hospital records, surgical pathology reports, and necropsy reports from 1929 to 1998 inclusive. Lymphomas were accepted as primary if they presented with symptoms as a result of bladder disease, did not involve adjacent organs, and if there was no evidence of lymphoma elsewhere at the time of diagnosis. Low grade MALT-type lymphomas were stained immunohistochemically with antibodies directed against B cell markers (CD20 and CD43), CD21 to assess follicular architecture, and  $\kappa$  and  $\lambda$  light chains to demonstrate clonality. High grade primary and secondary lymphomas were stained for CD20, CD30, and CD3.

## Methods

**Results**

Eleven cases were identified, six of which were primary and five secondary. Brief clinical details are shown in tables 1 and 2. This represented 0.2% of all bladder neoplasms reported and 1.8% of secondary tumours of the bladder. All of the examples of primary lymphoma were surgical biopsy specimens. Four of the five secondary lymphomas were postmortem cases, and in no case was a systemic lymphoma initially diagnosed in the bladder.

## Results

The primary lymphomas comprised three low grade B cell lymphomas of MALT type and three diffuse large B cell lymphomas. The MALT-type lymphomas presented in elderly women and appeared cystoscopically as well defined masses, sometimes ulcerated, resembling transitional cell carcinoma, and in one

Department of  
Histopathology and  
Morbid Anatomy, St  
Bartholomews and the  
Royal London School  
of Medicine and  
Dentistry, London  
E1 1BB, UK  
A W Bates  
A J Norton  
S I Baithun

Correspondence to:  
Dr Bates email:  
[a.w.bates@mds.qmw.ac.uk](mailto:a.w.bates@mds.qmw.ac.uk)

Accepted for publication  
29 November 1999

Table 1 Clinical and histological features and outcome of primary malignant lymphomas of the bladder

Age/Sex	Clinical history	Histological diagnosis	Immunophenotype	Follow up
66/F	Large bladder mass that clinically resembled stage T3 transitional cell carcinoma. No lymphadenopathy on physical examination or computed tomography	Low grade MALT-type lymphoma	CD20 <sup>+</sup>	Alive after 1 year
79/F	Haematuria. Multiple bladder tumours on cystoscopy. No evidence of tumour elsewhere	Low grade MALT-type lymphoma	CD20 <sup>+</sup>	No follow up
59/F	First diagnosed in 1995. Defaulted follow up. Re-presented 1998. Solid necrotic tumour anterior wall of bladder, clinically stage T2-T3	Low grade MALT-type lymphoma	CD20 <sup>+</sup> CD43 <sup>+</sup>	Alive with disease after 3 years
84/F	Presented with intermittent haematuria over the previous 2 years. Cystoscopy showed mucosal congestion but no obvious tumour. Repeat cystoscopy 3 weeks later showed tumour obscuring the right ureteric orifice, clinically stage T3. There was no lymphadenopathy and no evidence of tumour elsewhere. Macroscopically thought to be invasive transitional cell carcinoma	Diffuse large B cell lymphoma	CD20 <sup>+</sup>	Died of disease after 6 months
67/M	Painless haematuria. Irregular tumour mass in right side of bladder. Treated with radiotherapy and chemotherapy. Now has recurrent solid growth in posterior wall of bladder. No evidence of disease elsewhere	Diffuse large B cell lymphoma	CD20 <sup>+</sup> CD30 <sup>+</sup>	Alive with disease after 16 years
80/F	Presented with a 3 month history of intermittent haematuria. Impaired renal function. Cystoscopy showed a ring of tumour obstructing the right urethral meatus. Treated with radiotherapy. Bone marrow uninvolved. No evidence of lymphadenopathy or tumour elsewhere	Diffuse large B cell lymphoma	CD20 <sup>+</sup>	Alive and well after 3 years 8 months

F, female; M, male; MALT, mucosa associated lymphoid tissue.

Table 2 Clinical and histological features and outcome of secondary malignant lymphomas of the bladder

Age/Sex	Clinical history	Histological diagnosis	Immunophenotype	Follow up
65/M	Presented with faecal fistula at operation site 2 months after appendicectomy. Developed cystitis with rectovesical fistula. Laparotomy showed a mass involving the ileum. Generalised lymphadenopathy	Diffuse large B cell lymphoma secondary to systemic follicular lymphoma	CD20 <sup>+</sup>	Died of disease after 13 months
41/M	Presented with lower abdominal pain and diarrhoea. Abdominal lymphadenopathy and a caecal mass were found. Biopsy showed "malignant lymphoma". Treated with radiotherapy and chemotherapy. Bladder found to be involved at necropsy	Diffuse large B cell lymphoma	CD20 <sup>+</sup>	Died of disease after 10 months
32/M	Six weeks' history of a flu like illness. Necropsy showed an abdominal mass and lymphadenopathy	Diffuse large B cell lymphoma	CD20 <sup>+</sup>	Died of disease (necropsy)
76/F	One month history of swelling of left leg. Lymphadenopathy left groin and right axilla. Mass in lower abdomen	Diffuse large B cell lymphoma	CD20 <sup>+</sup> CD30 <sup>+</sup>	Died of disease after 1 month
81/F	Known Hodgkin's disease	Nodular sclerosis Hodgkin's disease		No follow up

F, female; M, male.

case there were multiple nodules. The two patients in this group for whom follow up was available were alive at one and three years after diagnosis. Histologically, all of the cases of MALT-type lymphoma showed lymphoepithelial lesions in transitional epithelium (fig 1) and colonisation of reactive follicles by monocytoid B cells; two cases predating 1983 had been previously diagnosed as follicular lymphomas (fig 2). Plasmacytic differentiation was promi-

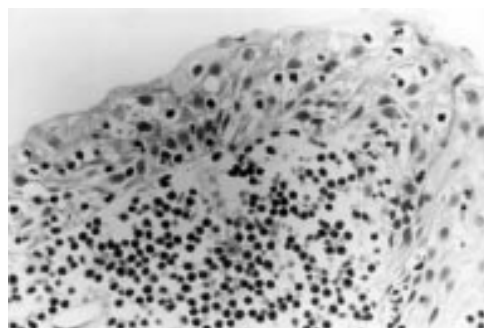


Figure 1 A lymphoepithelial lesion of transitional epithelium in mucosa associated lymphoid tissue-type lymphoma of the bladder.

nent in one of the three cases. All showed immunoglobulin light chain restriction.

Primary diffuse large B cell lymphomas typically presented in elderly patients with haematuria: one case from before the advent of immunohistochemistry was initially diagnosed as poorly differentiated carcinoma. Lymphoepithelial lesions and reactive follicles were present in conjunction with high grade lymphoma in one biopsy. One patient with diffuse large B cell

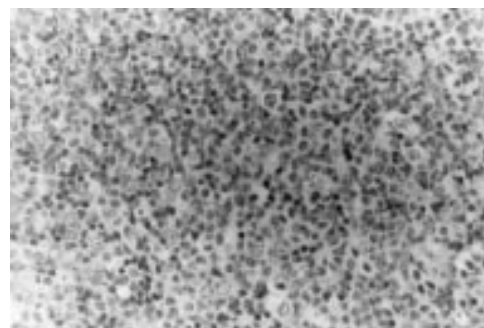


Figure 2 A diffuse infiltrate of centrocyte like cells in mucosa associated lymphoid tissue-type lymphoma of the bladder. Scattered larger cells resemble centroblasts.

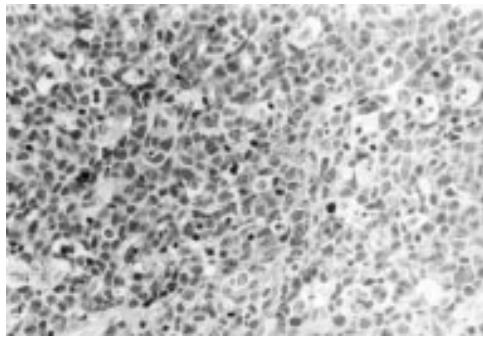


Figure 3 Secondary diffuse large B cell lymphoma of the bladder.

lymphoma died of disease six months after presentation, but two others were alive after three years and 8 months and 16 years.

Secondary lymphomas included three diffuse large B cell lymphomas (fig 3), one diffuse large B cell lymphoma secondary to systemic follicular lymphoma, and one case of nodular sclerosis Hodgkin's disease. The presenting features were lymphadenopathy, lymphoedema, abdominal pain and masses, and rectovesical fistula. In four of the five cases, the diagnosis of bladder involvement was made at postmortem examination. The prognosis was poor: all patients for whom follow up was available were dead within 13 months of presentation.

### Discussion

Although lymphoid neoplasms arising in the bladder are rare, secondary involvement of the bladder by systemic lymphoma is relatively common, having been documented in 10–20% of all patients with non-Hodgkin's lymphoma at necropsy.<sup>5</sup> The under-representation of secondary lymphomas in this series presumably indicates sampling bias: cystoscopic biopsies are unlikely to be taken from patients with systemic lymphomas who have symptoms referable to secondary involvement of the bladder, and at postmortem examination evidence of secondary lymphoma might not be sought in the bladder, unless a tumour mass that appears to merit histological investigation is noted. The incidence of primary lymphomas might have been increased because the study was carried out at a tertiary referral centre.

The concept of MALT lymphoma was proposed by Isaacson and Wright in 1983,<sup>6</sup> and the first report of a case arising in the bladder was in 1990<sup>7</sup>; however, the similarity of some bladder lymphomas to lymphoid lesions in the stomach had been noted even before MALT lymphoma was described.<sup>8</sup> Since 1990, 14 other cases of primary MALT-type lymphoma of the bladder have been published.<sup>9–12</sup> In our present study, none of the three patients with MALT-type lymphoma had a documented history of cystitis, but in no case had there been previous bladder biopsies, so the presence or absence of cystitis was difficult to ascertain. Simpson *et al* have found previously that 22% of primary lymphomas of the bladder were preceded by documented cystitis,<sup>13</sup> and Osawa and colleagues<sup>14</sup> found cystitis in only 20%,

although in many cases cystitis might have gone undiagnosed. The presence of lymphoepithelial lesions and reactive lymphoid follicles in each of our cases supports the hypothesis that cystitis is a necessary precursor of MALT lymphoma, as experience with MALT lymphomas at other sites would suggest. Lymphoepithelial lesions are not a feature of the normal bladder,<sup>9</sup> but are seen in MALT lymphoma in both transitional and glandular bladder epithelia.<sup>12</sup> We did not find glandular metaplasia in our three cases of primary MALT-type lymphoma, and in each case lymphoepithelial lesions involved transitional epithelium, so we do not regard metaplasia as a prerequisite for formation of lymphoepithelial lesions, as has been suggested previously.<sup>1</sup> Although only a small number of cases have been studied, the prognosis of MALT-type lymphoma confined to the bladder appears to be favourable,<sup>1</sup> and so far only one patient with a MALT-type lymphoma of the bladder has been reported to have died of the disease.<sup>9</sup> This suggests that MALT lymphomas of the bladder, in common with those at other sites, generally carry a good prognosis,<sup>15</sup> and have little tendency to disseminate to non-MALT lymphoid organs. In the stomach, similar expression of lymphocyte homing receptors and vascular addressins in MALT of chronic inflammation and in MALT lymphomas suggests that MALT lymphomas tend to remain confined to their site of origin because mechanisms controlling B cell trafficking in normal MALT are also operative in MALT lymphoma.<sup>16</sup> Analysis of integrin expression in acquired MALT and MALT lymphomas outside the gastrointestinal tract might help to explain the behaviour of these tumours.

High grade primary lymphomas of the bladder are almost always of diffuse large B cell type. Our finding of equal numbers of low and high grade primary lymphomas is in keeping with a recent extensive review of reported cases.<sup>1</sup> There is only one report of a primary T cell lymphoma of the bladder.<sup>17</sup> Older case reports of follicular and plasmacytic lymphomas are ambiguous because some of these cases would now be classified as MALT-type lymphomas, and it appears that primary low grade lymphomas of nodal type are rare in the bladder.<sup>18</sup> Some reports do describe plasmacytoid lymphoma,<sup>18</sup> but these might be MALT-type lymphomas with a high degree of plasmacytic differentiation. Isaacson<sup>19</sup> considered it likely that primary high grade B cell extranodal lymphomas that arise from sites where low grade MALT-type lymphomas occur are themselves MALT lymphomas, and in addition to the case described here, in which there was evidence of a preexisting low grade MALT lymphoma, there are two other cases in the literature that suggest transformation from low grade to high grade MALT.<sup>20–21</sup> However, it is not known what proportion of MALT lymphomas of the bladder undergo transformation to high grade lymphoma.

Although there is a relatively high incidence of bladder involvement in patients with systemic lymphoma, particularly in those dying of

the disease, our experience indicates that secondary lymphoma in biopsy specimens is seldom likely to pose a problem for the surgical pathologist. Involvement of the bladder by secondary tumour appears to indicate a very poor prognosis, but it is exceptionally rare for disseminated lymphoma to present with bladder involvement. The prognosis of primary high grade lymphoma of the bladder is more favourable because, by definition, they are, at the time of diagnosis, confined to a single organ, and this difference justifies investigation to exclude systemic lymphoma if a high grade lymphoma is diagnosed in a biopsy.

- 1 Kempton CL, Kurtin PJ, Inwards DJ, *et al.* Malignant lymphoma of the bladder: evidence from 36 cases that low-grade lymphoma of the MALT-type is the most common primary bladder lymphoma. *Am J Surg Pathol* 1997;**21**:1324-33.
- 2 Isaacson PG, Norton AJ. *Extranodal lymphomas*. Edinburgh: Churchill Livingstone, 1994.
- 3 Jones MW. Primary Hodgkins disease of the urinary bladder. *Br J Urol* 1989;**63**:438.
- 4 Harris NL, Jaffe ES, Stein H, *et al.* A revised European-American classification of lymphoid neoplasms: a proposal from the international lymphoma study group. *Blood* 1994;**84**:1361-92.
- 5 Sufirin G, Keogh B, Moore RH, *et al.* Secondary involvement of the bladder in malignant lymphoma. *J Urol* 1977;**118**:251-3.
- 6 Isaacson P, Wright DH. Malignant lymphoma of mucosa-associated lymphoid tissue. A distinctive type of B-cell lymphoma. *Cancer* 1983;**52**:1410-16.
- 7 Kuhara H, Tamura Z, Suchi T, *et al.* Primary malignant lymphoma of the urinary bladder. A case report. *Acta Pathol Jpn* 1990;**40**:764-9.
- 8 Pontius EE, Nourse MH, Paz L, *et al.* Primary malignant lymphoma of the bladder. *J Urol* 1963;**90**:58-61.
- 9 Pawade J, Banerjee SS, Harris M, *et al.* Lymphomas of mucosa-associated lymphoid tissue arising in the urinary bladder. *Histopathology* 1993;**23**:147-51.
- 10 Yuille FA, Angus B, Roberts JT, *et al.* Low grade MALT lymphoma of the urinary bladder. *Clin Oncol* 1998;**10**:265-6.
- 11 Gallardo J, Gamargo C, Fodor M, *et al.* Linfoma MALT de vejiga. Informe de un caso. *Rev Med Chil* 1998;**126**:199-201.
- 12 Fernandez Acenero MJ, Martin Rodilla C, Lopez Garcia-Asenjo J, *et al.* Primary malignant lymphoma of the bladder. Report of three cases. *Pathol Res Pract* 1996;**192**:160-3.
- 13 Simpson RHW, Bridger JE, Anthony PP, *et al.* Malignant lymphoma of the lower urinary tract. A clinicopathological study with review of the literature. *Br J Urol* 1990;**65**:254-60.
- 14 Ohsawa M, Aozasa K, Horiuchi K, *et al.* Malignant lymphoma of the bladder. Report of three cases and review of the literature. *Cancer* 1993;**72**:1969-74.
- 15 Cogliatti SB, Schmid U, Schumacher U, *et al.* Primary B-cell gastric lymphoma: a clinico-pathological study of 145 patients. *Gastroenterology* 1991;**101**:1159-70.
- 16 Dogan A, Du M, Koulis A, *et al.* Expression of lymphocytic homing receptors and vascular addressins in low-grade gastric B-cell lymphomas of mucosa-associated lymphoid tissue. *Am J Pathol* 1997;**151**:1361-9.
- 17 Mourad WA, Khalil S, Radwi A, *et al.* Primary T-cell lymphoma of the urinary bladder. *Am J Surg Pathol* 1998;**22**:373-7.
- 18 Biancari F, Lepidini G, D'Andrea V. Recurrent plasmacytoid lymphocytic lymphoma of the bladder secreting multiple monoclonal and bclonal proteins. *J Urol* 1998;**159**:985.
- 19 Isaacson PG. Critical commentary to primary malignant lymphoma of the bladder. *Pathol Res Pract* 1996;**192**:164-5.
- 20 Forrest JB, Saypol DC, Mills SE, *et al.* Immunoblastic sarcoma of the bladder. *J Urol* 1983;**130**:350-1.
- 21 Yang C, Motteram R, Sandeman TF. Extramedullary plasmacytoma of the bladder. A case report and review of the literature. *Cancer* 1982;**50**:146-9.

## *Journal of Clinical Pathology* - <http://www.jclinpath.com>

Visitors to the world wide web can now access the *Journal of Clinical Pathology* either through the BMJ Publishing Group's home page (<http://www.bmjpub.com>) or directly by using its individual URL (<http://www.jclinpath.com>). There they will find the following:

- Current contents list for the journal
- Contents lists of previous issues
- Members of the editorial board
- Information for subscribers
- Instructions for authors
- Details of reprint services
- Instructions for use of Pathology Interactive.

A hotlink gives access to:

- BMJ Publishing Group home page
- British Medical Association web site
- Online books catalogue
- BMJ Publishing Group books.

The web site is at a preliminary stage and there are plans to develop it into a more sophisticated site. Suggestions from visitors about features they would like to see are welcomed. They can be left via the opening page of the BMJ Publishing Group site or, alternatively, via the journal page, through "about this site".



## Malignant lymphoma of the urinary bladder: a clinicopathological study of 11 cases

A W Bates, A J Norton and S I Baithun

*J Clin Pathol* 2000 53: 458-461

doi: 10.1136/jcp.53.6.458

---

Updated information and services can be found at:

<http://jcp.bmj.com/content/53/6/458.full.html>

---

### References

*These include:*

This article cites 20 articles, 1 of which can be accessed free at:

<http://jcp.bmj.com/content/53/6/458.full.html#ref-list-1>

Article cited in:

<http://jcp.bmj.com/content/53/6/458.full.html#related-urls>

### Email alerting service

Receive free email alerts when new articles cite this article. Sign up in the box at the top right corner of the online article.

---

### Topic Collections

Articles on similar topics can be found in the following collections

[Immunology \(including allergy\)](#) (1279 articles)

[Urological cancer](#) (117 articles)

---

### Notes

---

To request permissions go to:

<http://group.bmj.com/group/rights-licensing/permissions>

To order reprints go to:

<http://journals.bmj.com/cgi/reprintform>

To subscribe to BMJ go to:

<http://group.bmj.com/subscribe/>