



## Best practice No 159

# Examination of large intestine resection specimens

S H Burroughs, G T Williams

### Abstract

**Macroscopic examination of large intestinal resection specimens by the surgical pathologist provides important diagnostic and prognostic information. This review summarises current recommended protocols and evidence based guidelines for gross description, dissection, and histological block selection in both neoplastic and non-neoplastic colorectal disease. Specific lesions discussed include colorectal cancer, polypectomies and polyposis syndromes, and inflammatory bowel disease. Microscopic examination is briefly described, with emphasis on certain pitfalls that might be encountered in routine practice. A section covering special techniques for the investigation of occult bleeding is included.**

(*J Clin Pathol* 2000;53:344–349)

Keywords: large intestine; colorectal cancer; inflammatory bowel disease

Large intestinal resections performed for neoplastic, vascular, and inflammatory disease form part of the everyday workload of many surgical histology laboratories. The importance of careful handling of colorectal cancer resections by the pathologist has received much attention recently.<sup>1</sup> Identification of lymph node and resection margin involvement by adenocarcinoma is of paramount importance in determining whether patients will receive postoperative chemotherapy and/or radiotherapy.<sup>2,3</sup> Macroscopic examination of the resection specimen also plays a major role in monitoring the quality of surgical practice.<sup>1</sup>

Gross examination of the large intestine in non-neoplastic conditions can also yield valuable diagnostic information, particularly in the classification of inflammatory bowel disease. Other conditions, such as angiodysplasia, require special preparation of the macroscopic specimen if the lesions are to be identified on subsequent microscopy.

These guidelines aim to summarise current “good practice” recommendations for macroscopic examination and dissection of colorectal resections and polypectomy specimens, including the selection of appropriate blocks for histology. Details of microscopic examination

and interpretation of biopsy specimens are beyond the remit of this paper; comprehensive guidelines for biopsy diagnosis of suspected inflammatory bowel disease have been published recently.<sup>4</sup> However, we have included a few guidelines relating to particular pitfalls in the histological assessment of large bowel lesions.

### Laboratory examination of large intestinal resections: general comments

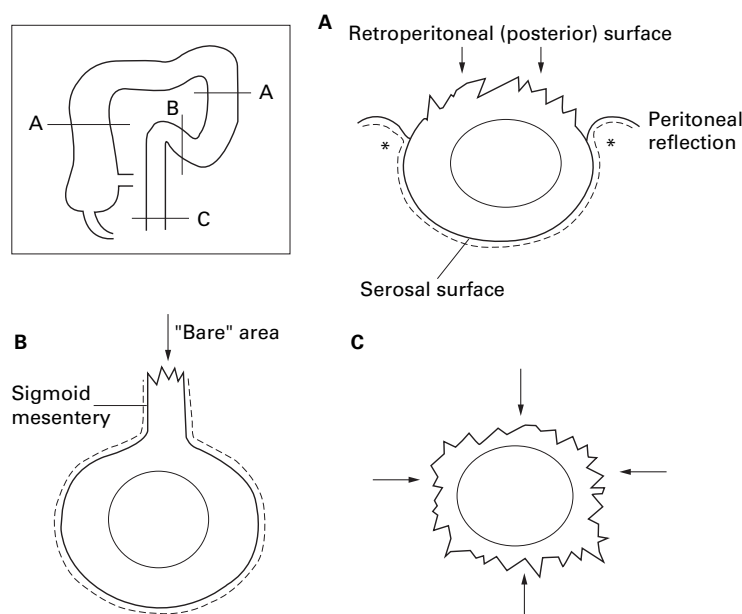
Resection specimens should be received fresh, unfixated, and unopened for optimum anatomical orientation. If the specimen is received outside laboratory hours, it can be refrigerated at 4°C overnight without risk of appreciable autolysis. Routine diagnostic immunocytochemistry and many molecular biological techniques can be applied to formalin fixed, routinely processed tissue, but receipt of fresh specimens also permits sampling for electron microscopy and research. Where receipt of fresh specimens is completely impractical, the theatre staff should be encouraged to send unopened specimens in an adequate volume of fixative—at least 10 times greater than the tissue volume.

The laboratory should ensure that the specimen is accompanied by a properly completed request form before commencing examination. A minimum amount of patient information (full name, date of birth, and hospital number) should be present on both the form and the specimen container. The pathologist needs to be aware of the clinical diagnosis, the results of any previous relevant histological investigations, and whether treatment (radiotherapy and/or chemotherapy) has been given that could affect tissue morphology and histological interpretation. Whenever possible, the pathologist who performs the macroscopic examination should also report the microscopic appearances. Routine specimen photography has been endorsed by some authors<sup>5,6</sup>; we have found that a clear gross description of the specimen and indication of the origin of tissue blocks, with a diagram if appropriate, provides a satisfactory record in most cases. However, photography can be invaluable for documentation of macroscopic lesions in resections performed for inflammatory bowel disease.

Department of  
Pathology, University  
of Wales College of  
Medicine, Heath Park,  
Cardiff CF4 4XN, UK  
S H Burroughs  
G T Williams

Correspondence to:  
Professor Williams  
email: [WilliamsGT@cf.ac.uk](mailto:WilliamsGT@cf.ac.uk)

Accepted for publication  
29 November 1999



**Figure 1** Extent of serosal covering of the large intestine. Arrows indicate the "bare" non-peritonealised areas at different levels. (A) The ascending and descending colon are devoid of peritoneum on their posterior surface. (B) The sigmoid colon is completely covered with peritoneum, which extends over the mesentery. (C) The lower rectum lies beneath the pelvic peritoneal reflection. The asterisks in (A) indicate the sites where serosal involvement by tumour is likely to occur.

### Colorectal cancer resections

#### SPECIMEN PRESERVATION AND INITIAL DISSECTION

Attention to fixation and dissection of the gross specimen is essential for accurate evaluation of lymph node and resection margin involvement by tumour. The extent to which the large intestine is covered by peritoneum varies with the anatomical site (fig 1). The transverse and sigmoid colon are completely invested by peritoneum that extends over the mesentery. The caecum is usually completely covered by peritoneum but has no mesentery. The ascending and descending colon and upper rectum have a posterior retroperitoneal surface that will constitute the surgical excision margin in resection specimens. The distal rectum lying below the pelvic peritoneal reflection has a circumferential surgical resection margin that is devoid of serosa. Identification of both serosal and non-peritoneal resection margin involvement by tumour is important because of the following points.

- (1) Serosal involvement denotes stage T4 tumour.<sup>7</sup> Local peritoneal involvement is common in colonic cancer; although local peritoneal involvement in itself does not necessarily indicate incomplete tumour resection, it does predict subsequent intra-peritoneal recurrence and is a strong independent prognostic parameter.<sup>8</sup>
- (2) Circumferential margin involvement in the rectum carries a high risk of local recurrence,<sup>9</sup> with an associated mortality rate of 90%.<sup>1</sup>

If the fresh intact surgical specimen includes any non-peritonealised surface, this should be painted with silver nitrate, India ink, or another marker before dissection. For purposes of surgical audit, photography of the intact resection

might be desirable. The unfixed specimen is opened anteriorly, apart from the area extending 1–2 cm above and below the tumour, which should be left intact. In our department, a paper towel "wick" is passed through the residual lumen at the tumour site to aid fixative permeation. The specimen is then pinned to a cork board and immersed in an adequate volume of formalin. Resections should be allowed to fix for at least 48 hours before further dissection and block taking; this not only facilitates obtaining thin transverse slices through the tumour,<sup>3</sup> but also has been shown to increase lymph node yield.<sup>10</sup> Specimens can be unpinned from the board after 24 hours and allowed to float free so as to avoid the risk of suboptimal fixation of tissue previously adjacent to the cork surface.

Once fixed, the section of bowel containing the tumour and attached mesentery is sliced transversely at 3–4 mm intervals. This protocol has been endorsed for rectal cancer specimens,<sup>1</sup> but we suggest that all large bowel cancers can be appropriately dissected by this method.

#### MACROSCOPIC DESCRIPTION

The gross description should include the specimen type (as indicated by the surgical operative description on the request form), site of tumour, and distance from closest resection margin. Tumour length and width are more difficult to measure when the specimen is dissected as described above, but these dimensions have no independent prognostic value. The position of rectal tumours in relation to the peritoneal reflection (entirely above, entirely below, or astride) and the distance from the tumour to the dentate (pectinate) line should be recorded. These data provide independent verification of the site of the tumour in the rectum and of the fact that the anal sphincter has been sacrificed, both of which are important in auditing the quality of surgery.<sup>1,2</sup> It has been suggested that the pathologist can also assess the quality of surgical dissection of the pelvis in total mesorectal excision specimens by examining the contour of the resection for its bulk, surgical defects, and the degree of "coning" in the distal portion.<sup>1</sup> The presence of perforation must be recorded because it is a poor prognostic feature, denoting stage pT4 tumour.<sup>7</sup> Any background abnormalities should also be described.

#### BLOCKS TO BE TAKEN

After transverse sectioning, the tumour slices are laid out and blocks selected for histology to include greatest depth of tumour invasion and any peritoneal (serosal) or retroperitoneal/circumferential margin involvement; at least four blocks of tumour are recommended.<sup>3</sup> We have observed that serosal involvement is especially prone to occur at or adjacent to peritoneal reflections (fig 1A), and should be suspected in any areas of serosa that appear dulled, fibrotic, or haemorrhagic. The Royal College of Pathologists' minimum data set for rectal tumours requires histological measure-

Table 1 Minimum pathological dataset for colorectal cancer reporting<sup>2</sup>

Patient details
Name, date of birth, hospital, hospital number, histology number, surgeon
Gross description
Site of tumour
Maximum tumour diameter
Distance of tumour to nearer margin (cut end)
Presence of tumour perforation (pT4)
For rectal tumours
Tumour position in relation to peritoneal reflection
Distance from the dentate line
Histology
Type (adenocarcinoma or other)
Differentiation (well/moderate or poor)
Local invasion (submucosa pT1)
(muscularis propria pT2)
(beyond muscularis propria pT3)
(peritoneum breached or invasion of adjacent organs pT4)
Margin involvement (if applicable)
Doughnut
Margin (cut end)
For rectal tumours
Circumferential margin involvement
Histological measurement from tumour to circumferential margin (in mm)
Metastatic spread
Number of lymph nodes examined
Number of positive lymph nodes (pN1: 1–3 nodes, pN2: 4+ nodes involved)
Apical node positive (Dukes's C2)
Extramural vascular invasion
Background abnormalities
Adenoma(s)
Synchronous carcinoma(s)—these require a separate minimum dataset to be completed
Ulcerative colitis
Crohn's disease
Familial adenomatous polyposis
Other
Pathological staging
Complete resection at all margins
TNM
Dukes's
Histologically confirmed liver metastases

ment of the minimum distance from the tumour to the circumferential resection margin, and an appropriate block should be taken for this purpose. We recommend a similar approach with regard to any non-peritonealised margin (see above) in colonic tumours. Lymph nodes identified in the tumour containing slices can now be harvested. If the tumour is > 30 mm from the cut end of the main specimen it is not always necessary to examine the margin (or any corresponding doughnuts) microscopically,<sup>2</sup> although the closest cut margin can be used to provide the required block of background mucosa. However, cut margins should subsequently be examined histologically if the initial tissue sections reveal the presence of extensive infiltrative tumour growth or lymphovascular invasion, and in tumours with poor prognosis histology (signet ring, small cell, or undifferentiated carcinomas).<sup>2</sup>

After block selection from the tumour, a careful search for regional lymph nodes is performed, starting with the highest node. This is the first node identified by sectioning serially and distally from the sutured vascular margin,<sup>2</sup> regardless of the actual distance between node and tie; it should be identified and blocked separately. Whereas only one vascular "high tie" is present in rectal resections, several vessels might drain colonic resections<sup>3</sup>; if the tumour lies between two major arteries it might be appropriate to examine both high tie nodes for assessment of Dukes's C stage. The TNM staging system requires the total number of positive nodes to be identified (pN1 = 1–3 nodes, pN2 = 4 or more nodes). The pN3 cat-

egory, relating to nodes lying above the bifurcations of the major colorectal vessels, has been dropped from the 1997 TNM revision<sup>7</sup> because it does not add any further prognostic data to pN2; therefore, separate identification of these nodes does not appear to be necessary.

There is no consensus view regarding the "minimum" number of lymph nodes necessary to ensure correct pathological staging.<sup>11–13</sup> We strongly advise that the pathologist should submit as many nodes as possible for histology, regardless of site or size. It is possible that the median number of lymph nodes harvested from colorectal resections will be used as a future measure of the quality of pathological reporting. It is our experience, supported by other published evidence,<sup>10, 14</sup> that careful serial sectioning of adequately fixed specimens provides a satisfactory number of lymph nodes in most cases. Fat clearance of the mesentery might be of use when very few nodes have been harvested from an apparent Dukes's B tumour.<sup>15</sup> It is uncertain as to whether multiple sections and complete embedding of lymph nodes is more effective than partial embedding or single node slices. Our practice is to embed all small nodes (< 5 mm in diameter) completely and embed half of each larger node. Lymph nodes lying close to the circumferential (non-peritoneal) resection margin should be sampled in continuity with that margin; any tumour deposit, including entirely intranodal and intravascular tumour, found within 1 mm of the surgical margin indicates margin involvement.

#### MICROSCOPIC DESCRIPTION

The minimum data set for colorectal cancer published by the Royal College of Pathologists<sup>2</sup> is shown in table 1; it can be downloaded from the college website (<http://www.rcpath.org>). The use of a proforma report to ensure completeness of data recording in every case is strongly encouraged.<sup>1, 16</sup> Tumour should be graded by predominant area<sup>17</sup>; small foci of poor differentiation at the advancing edge of tumours are insufficient to classify the carcinoma as poorly differentiated. Peritoneal involvement should only be diagnosed if tumour is present on the serosal surface or has ulcerated the serosa<sup>8</sup>; the presence of tumour close to an inflamed area of peritoneum is insufficient evidence of stage T4 (serosal involvement). Infiltration of extramural veins (but not submucosal or intramuscular veins) is associated with an increased incidence of distant metastases and death from local recurrence.<sup>18</sup> The diagnosis of vascular invasion is made when tumour is identified within an extramural endothelium lined space that is either surrounded by a rim of muscle or contains red blood cells,<sup>2, 18</sup> and should be demonstrable on routine haematoxylin and eosin stains.

#### SPECIAL TECHNIQUES

The role of multiple section levels and immunocytochemistry in the detection of lymph node micrometastases is a subject for ongoing scrutiny; it is not currently our

practice to use either technique. The prognostic relevance of micrometastases remains unknown.<sup>19-21</sup> As discussed above, there is no necessity for the routine use of immunocytochemistry in the detection of vascular invasion. Evaluation of microsatellite instability in colorectal cancers using immunocytochemical methods might become routine in the near future.<sup>22</sup> Preservation of tissue for electron microscopy is probably only necessary in suspected stromal tumours or in otherwise unusual rare lesions.

### Polypectomy specimens

#### LOCAL EXCISION OF POLYPS

Small polyps can be embedded whole. Bisection through the stalk is only recommended for lesions less than 1.0 cm in largest diameter. For lesions over 1.0 cm, the edges should be trimmed to leave a central section containing the intact stalk, and all fragments submitted for histology.

#### SUBMUCOSAL POLYPECTOMIES AND FULL THICKNESS LOCAL EXCISION SPECIMENS

Submucosal excision is usually used for large carpet-like adenomas in the rectum. Transanal full thickness local excision specimens may contain adenomas and early carcinomas, or might be performed as a palliative procedure in patients who are unsuitable for more radical surgery. Both types of specimen tend to consist of the lesion with a narrow rim of surrounding normal tissue. For satisfactory examination, the fresh specimen needs to be pinned to cork, using dressmaker's pins around the entire circumference, and fixed for at least 24 hours before dissection. Fixation of the specimen without pinning out can cause dramatic tissue shrinkage that renders anatomical orientation and assessment of resection margins very difficult. After fixation, the specimen margins should be identified with appropriate coloured markers (inks or gelatin). The whole of the specimen is transversely sectioned into 3 mm slices and submitted for histology in sequentially labelled cassettes. In cases where the margin of normal tissue is less than 3 mm, a 1 cm slice containing the relevant margin should be made and further sectioned at right angles as shown in fig 2. The multiple fragments from the margin section can be embedded in agar to maintain orientation.

#### MICROSCOPIC DESCRIPTION

We recommend examination of three section levels from all neoplastic polypectomy specimens. The pathology report should indicate polyp size, architecture, degree of dysplasia, and completeness or otherwise of excision. Adenomas are classified as "tubular" or "villous" if the lesion contains at least 80% of the respective architectural component. Tubulovillous adenomas are composed of tubular and villous structures, each contributing to more than 20% of the tumour mass.<sup>23</sup> Invasive malignancy is only diagnosed if there is infiltration beyond the muscularis mucosa. Lamina propria invasion or partial muscularis mucosa infiltration only does not indicate

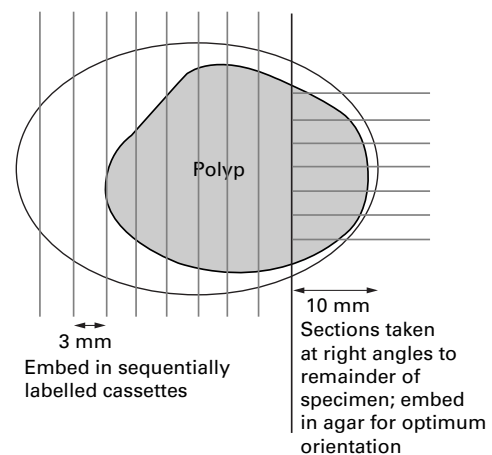


Figure 2 Sectioning technique for submucosal and full thickness polypectomy specimens.

metastatic potential, and should be reported as adenoma with severe dysplasia. Radical surgery is indicated for invasive malignancy arising in a polyp or localised resection specimen only if there is doubt regarding the completeness of excision, evidence of muscularis propria (not mucosae) invasion, or if the carcinoma is poorly differentiated<sup>24</sup>; these parameters must be recorded if present. The importance of lymphatic or vascular invasion in the polyp stalk and submucosa is more controversial, although most would regard it as an indication for further surgery, and it should also be included in the report.<sup>25</sup>

#### SAMPLING OF MULTIPLE POLYPS AND POLYPOSIS SYNDROMES

Multiple adenomatous and metaplastic polyps might be present in the background of colorectal resections performed for both neoplastic and non-neoplastic lesions, in addition to known polyposis syndromes. Invasive adenocarcinoma in colonoscopically removed adenomas is very uncommon in those measuring < 1 cm, but is present in 5.5% of lesions between 1 and 2 cm, and 26% of adenomas exceeding 2 cm.<sup>26</sup> These figures support the guideline that although all polyps under 1 cm in a colectomy specimen do not necessarily need to be sampled, all suspected adenomas above 1 cm in diameter should be submitted for histology. However, sufficient numbers of polyps should always be sampled to ensure that histological sections are representative and to allow recognition of rare mixed polyposis syndromes.

### Non-neoplastic colonic resections

Surgical resections for non-neoplastic colorectal disease may show a variety of pathologies including complicated diverticular disease, ulcerative colitis, Crohn's disease, ischaemic colitis, volvulus, angiodysplasia, motility disorders, and radiation colitis. Specimen dissection and block selection need to be tailored to the specific pathology. Severe acute colitis (including toxic megacolon) is often a manifestation of inflammatory bowel disease, but other potential causes include infection, ischaemia, and obstruction. The main role of the pathologist in

such cases is to determine the underlying disease process, although this might not always be possible.<sup>27</sup> In cases of known inflammatory bowel disease, the role of pathological examination is to confirm the diagnosis, document disease extent, and identify clinically relevant complications, including precancerous lesions.

#### SPECIMEN PRESERVATION

Fresh specimens received unopened should be examined over the serosal surface for lesions, especially fistulae or perforations that might be missed after the specimen has been incised. We prefer to open the specimen throughout its length, along the antimesenteric wall, including any areas of stricture, and remove any faeces, blood, or mucous by gentle washing in cold running water. The resection is then pinned to a cork board and fixed, for a minimum of 48 hours; the specimen can be unpinned and floated free in the fixative after the initial 24 hours. An alternative method for strictured specimens is to wash the bowel luminal content away by inserting a gently flowing water hose at one cut end, and then to tie off one resection margin, inflate the specimen with formalin, secure the opposite cut margin, and float in fixative.<sup>5</sup>

#### MACROSCOPIC DESCRIPTION

The distribution, extent, and nature of macroscopic changes in inflammatory bowel disease are frequently important diagnostic features. The following guidelines primarily relate to resections performed for Crohn's disease and ulcerative colitis. The specimen nature (extent of surgical resection) should be recorded. Care should be taken to identify and document the distribution of serosal fat wrapping, severe dilatation, mural thickening or stricture formation, ulcers, perforation, pseudopolyps, and mucosal cobblestoning. Both ulcerative colitis and Crohn's disease are associated with an increased risk of colorectal cancer, and specimens should be examined carefully for any suspicious lesions. Thorough macroscopic descriptions have a tendency to become lengthy, and specimen photography can prove extremely useful in this situation, providing an invaluable visual record for clinicopathological meetings. The appearance of fixed specimens can be improved by immersing in 70% ethyl alcohol for colour restoration before being photographed.<sup>6</sup>

#### BLOCKS TO BE TAKEN

The selection of blocks obviously depends on the lesions present. For inflammatory bowel disease, we recommend sections to be taken at each 10 cm distance from the proximal to distal resection margin, in addition to sampling of any other focal lesions. The site of the block should be recorded by stating the distance of the section from a specified resection margin. In ulcerative colitis, the resection margins need to be examined histologically for the presence of dysplasia. There is no evidence to suggest that microscopic involvement of the resection margin by Crohn's disease increases the risk of disease recurrence,<sup>28</sup> and blocking of the cut

margins or doughnuts might not be necessary unless there are obvious lesions present. Any strictures should be sampled adequately to exclude the possibility of malignancy. Lymph nodes should be sampled routinely, although it does not appear necessary to embed all nodes as suggested for colorectal cancer.

#### MICROSCOPIC DESCRIPTION

Histological features of non-neoplastic colorectal disease are well described in standard reference works,<sup>6, 29</sup> and detailed guidelines for biopsy reporting in inflammatory bowel disease have been published recently.<sup>4</sup> Pathological mimicry of chronic inflammatory bowel disease by other forms of colitis is well recognised.<sup>30, 31</sup> The presence of granulomatous inflammation is not synonymous with Crohn's disease, and the accompanying macroscopic and microscopic features must be evaluated critically before making this diagnosis. Pitfalls in the diagnosis of ulcerative colitis include rectal sparing after local steroid treatment and "skip lesion" involvement of the caecum or appendix with coexistent distal proctitis but normal intervening colon.<sup>32, 33</sup> The histological assessment of colonic tissue after diversion of the faecal stream requires special care, with review of any previous tissue sections.<sup>34</sup> Correlation of clinical, radiological, and pathological findings in all suspected cases of inflammatory bowel disease is strongly recommended.

#### Investigation of occult intestinal bleeding

Suspected cases of colonic angiodysplasia require special handling if the ectatic vessels are to be demonstrated histologically. Close cooperation between surgeon, radiologist, and pathologist is necessary to identify and appropriately prepare the macroscopic specimen. Pounder and colleagues<sup>35</sup> have described a technique of barium/gelatin vascular injection, which is cheap, reliable, and practical for routine surgical pathology laboratories. During surgery, the artery and vein supplying the affected segment of bowel are cannulated and flushed with heparinised saline. Contrast medium (5 g gelatin and 50 g barium sulphate in 100 ml water, maintained at 40°C) is injected under fluoroscopic control into first the arterial tree and then the venous system, with x rays being taken after both injections. The unopened bowel is then carefully washed out and inflated with formalin so that it is fixed in the normal distended state. After more than 24 hours flotation in formalin, the bowel is opened lengthwise and examined with a hand lens; it is not unusual for the mucosal surface to appear entirely normal, and the radiographs will be required to guide block selection. If angiodysplasia is present, the subsequent histological sections will show ectatic mucosal blood vessels filled with barium/gelatin. An alternative dissection method that does not require intravascular injection has also been described.<sup>36</sup>

Thanks to Dr B Warren for guidelines regarding the handling of transanal local excision specimens.

1 Quirke P. The pathologist, the surgeon and colorectal cancer—get it right because it matters. In: Kirkham N,

- Lemoine NR, eds. *Progress in pathology*, Vol. 4. Edinburgh: Churchill Livingstone, 1998:201–13.
- 2 The Royal College of Pathologists Working Group on Cancer Services. *Minimum data set for colorectal cancer histopathology reports*. London: Royal College of Pathologists, 1998.
  - 3 UK Co-ordinating Committee on Cancer Research Colorectal Cancer Subcommittee. *Handbook for the clinicopathological assessment and staging of colorectal cancer*, 2nd ed. London: UK Co-ordinating Committee on Cancer Research, 1997.
  - 4 Jenkins D, Balsitis M, Gallivan S, et al. Guidelines for the initial biopsy diagnosis of suspected chronic idiopathic inflammatory bowel disease. The British Society of Gastroenterology initiative. *J Clin Pathol* 1997;50:93–105.
  - 5 Sheffield JP, Talbot IC. Gross examination of the large intestine. *J Clin Pathol* 1992;45:751–5.
  - 6 Morson BC, Dawson IMP, Day DW, et al. *Gastrointestinal pathology*, 3rd ed. Oxford: Blackwell Scientific Publications, 1990.
  - 7 Sobin LH, Wittekind C, eds. Colon and rectum. In: *TNM classification of malignant tumours*, 5th ed. New York: John Wiley and Sons, 1997:66–9.
  - 8 Shepherd NA, Baxter KJ, Love SB. The prognostic importance of peritoneal involvement in colonic cancer: a prospective evaluation. *Gastroenterology* 1997;112:1096–102.
  - 9 Adam JJ, Mohamdee MO, Martin IG, et al. Role of circumferential margin involvement in the local recurrence of rectal cancer. *Lancet* 1994;344:707–10.
  - 10 Richards CJ, West KP. Rapid turnaround in histopathology is not appropriate for colorectal carcinoma resections [abstract]. *J Pathol* 1998; 186(suppl):29A.
  - 11 Caplin S, Cerotini JP, Bosman FT, et al. For patients with Dukes' B (TNM stage II) colorectal carcinoma, examination of six or fewer lymph nodes is related to poor prognosis. *Cancer* 1998;83:666–72.
  - 12 Maurel J, Launoy G, Grosclaude P, et al. Lymph node harvest reporting in patients with carcinoma of the large bowel: a French population-based study. *Cancer* 1998;82:1482–6.
  - 13 Goldstein NS, Sanford W, Coffey M, et al. Lymph node recovery from colorectal resection specimens removed for adenocarcinoma. Trends over time and a recommendation for a minimum number of lymph nodes to be recovered. *Am J Clin Pathol* 1996;106:209–16.
  - 14 Cohen SM, Wexner SD, Schmitt SL, et al. Effect of xylene clearance of mesenteric fat on harvest of lymph nodes after colonic resection. *Eur J Surg* 1994;160:693–7.
  - 15 Scott KW, Grace RH. Detection of lymph node metastases in colorectal carcinoma before and after fat clearance. *Br J Surg* 1989;76:1165–7.
  - 16 Bull AD, Biffin AHB, Mella J, et al. Colorectal cancer pathology reporting: a regional audit. *J Clin Pathol* 1997;50:138–42.
  - 17 Halvorsen TB, Seim E. Degree of differentiation in colorectal adenocarcinomas: a multivariate analysis of the influence on survival. *J Clin Pathol* 1988;41:532–7.
  - 18 Talbot IC, Ritchie S, Leighton M, et al. Invasion of veins by carcinoma of rectum: method of detection, histological features and significance. *Histopathology* 1980;5:141–63.
  - 19 Broll R, Schauer V, Schimmelpenninck H, et al. Prognostic relevance of occult tumor cells in lymph nodes of colorectal carcinomas: an immunohistochemical study. *Dis Colon Rectum* 1997;40:1465–71.
  - 20 Davidson BR, Sams VR, Styles J, et al. Detection of occult nodal metastases in patients with colorectal carcinoma. *Cancer* 1990;65:967–70.
  - 21 Jeffers MD, O'Dowd GM, Mulcahy H, et al. The prognostic significance of immunohistochemically detected lymph node micrometastases in colorectal carcinoma. *J Pathol* 1994;172:183–7.
  - 22 Cawkwell L, Gray S, Murgatroyd H, et al. Choice of management strategy for colorectal cancer based on a diagnostic immunohistochemical test for defective mismatch repair. *Gut* 1999;45:409–15.
  - 23 Jass JR, Sobin LH. *Histological typing of intestinal tumours*, 2nd ed. Berlin: Springer-Verlag, 1989:29–30.
  - 24 The Royal College of Surgeons of England, Association of Coloproctologists of Great Britain and Ireland. *Guidelines for the management of colorectal cancer*. London: Royal College of Surgeons of England, 1996.
  - 25 Compton CC, Henson DE, Hutter RVP, et al. Updated protocol for the examination of specimens removed from patients with colorectal carcinoma. A basis for checklists. *Arch Pathol Lab Med* 1997;121:1247–54.
  - 26 Gillespie PE, Chambers TJ, Chan KW, et al. Colonic adenomas—a colonoscopic survey. *Gut* 1979;20:240–5.
  - 27 Price AB. Indeterminate colitis—broadening the perspective. *Current Diagnostic Pathology* 1996;3:35–44.
  - 28 Fazio VW, Marchetti F, Church M, et al. Effect of resection margins on the recurrence of Crohn's disease in the small bowel. A randomized controlled trial. *Ann Surg* 1996;224:563–71.
  - 29 Rosai J. Large bowel. In: *Ackerman's surgical pathology*, 8th ed. St Louis: Mosby, 1996:729–99.
  - 30 Shepherd N. Pathological mimics of chronic inflammatory bowel disease. *J Clin Pathol* 1991;44:726–33.
  - 31 Price A. Pathological mimics of chronic inflammatory bowel disease. *CPD Bulletin Cellular Pathology* 1999;2:68–71.
  - 32 D'Haens G, Geboes K, Peeters M, et al. Patchy caecal inflammation associated with distal ulcerative colitis: a prospective endoscopic study. *Am J Gastroenterol* 1997;92:1275–9.
  - 33 Davison AM, Dixon MF. The appendix as a "skip lesion" in ulcerative colitis. *Histopathology* 1990;16:93–5.
  - 34 Warren BF, Shepherd NA. Iatrogenic pathology of the gastrointestinal tract. In: Kirkham N, Hall PA, eds. *Progress in pathology*, Vol. 1. Edinburgh: Churchill Livingstone, 1994:31–54.
  - 35 Pounder DJ, Rowland R, Pieterse AS, et al. Angiodysplasia of the colon. *J Clin Pathol* 1982;35:824–9.
  - 36 Thelmo WL, Vetrano JA, Wibowo A, et al. Angiodysplasia of the colon revisited: pathological demonstration without the use of intravascular injection technique. *Hum Pathol* 1992;23:37–40.



## Examination of large intestine resection specimens

S H Burroughs and G T Williams

*J Clin Pathol* 2000 53: 344-349

doi: 10.1136/jcp.53.5.344

---

Updated information and services can be found at:

<http://jcp.bmj.com/content/53/5/344.full.html>

---

### References

*These include:*

This article cites 25 articles, 8 of which can be accessed free at:

<http://jcp.bmj.com/content/53/5/344.full.html#ref-list-1>

Article cited in:

<http://jcp.bmj.com/content/53/5/344.full.html#related-urls>

### Email alerting service

Receive free email alerts when new articles cite this article. Sign up in the box at the top right corner of the online article.

---

### Topic Collections

Articles on similar topics can be found in the following collections

[Colon cancer](#) (146 articles)

[Inflammatory bowel disease](#) (37 articles)

[Morbid anatomy / surgical pathology](#) (71 articles)

---

### Notes

---

To request permissions go to:

<http://group.bmj.com/group/rights-licensing/permissions>

To order reprints go to:

<http://journals.bmj.com/cgi/reprintform>

To subscribe to BMJ go to:

<http://group.bmj.com/subscribe/>