

## HLA-DR and $\beta_2$ microglobulin expression in medullary and atypical medullary carcinoma of the breast: histopathologically similar but biologically distinct entities

Meora Feinmesser, Aaron Sulkes, Sara Morgenstern, Jaqueline Sulkes, Sidi Stern, Elimelech Okon

### Abstract

**Aims**—To examine the expression of HLA-DR and  $\beta_2$  microglobulin in medullary carcinoma and atypical medullary carcinoma of the breast to determine if the effective presentation of tumour antigens to the immune system can differentiate between these two histopathologically similar entities.

**Methods**—Expression of HLA-DR and  $\beta_2$  microglobulin was examined by immunohistochemical methods in five samples of medullary carcinoma of the breast, which has a relatively favourable prognosis, six samples of atypical medullary carcinoma of the breast, which has a prognosis closer to that of regular invasive duct carcinoma, and 20 samples of invasive duct carcinomas, 10 with an accompanying lymphocytic infiltrate.

**Results**—A positive and significant correlation was found between tumour type and both HLA-DR and  $\beta_2$  microglobulin expression. Expression was most prominent in medullary carcinoma, followed by atypical medullary carcinoma and invasive duct carcinoma with and without lymphocytic infiltrates. The mean intensity and percentage of HLA-DR tumour immunostaining were significantly higher in medullary carcinoma than in the other three tumour groups, as was the mean intensity of  $\beta_2$  microglobulin immunostaining. Mean percentage of  $\beta_2$  microglobulin immunostaining was significantly higher in medullary carcinoma than in invasive duct carcinoma without lymphocytic infiltrates, and showed a trend to increase from invasive duct carcinoma with lymphocytic infiltrates to atypical medullary carcinoma and medullary carcinoma.

**Conclusions**—Medullary carcinoma and atypical medullary carcinoma of the breast differ in their expression of HLA-DR and  $\beta_2$  microglobulin. The relatively favourable prognosis of medullary carcinoma of the breast may be related to effective tumour antigen presentation to the immune system through MHC-I and MHC-II expression. Immunotherapy aimed at MHC-I and MHC-II induction might have a beneficial effect in breast cancer.

(*J Clin Pathol* 2000;53:286–291)

Studies of the relation between the tumour and host immune systems have shown that major histocompatibility class (MHC)-I antigen expression, normally present in all nucleated cells, is reduced in malignancies.<sup>1–5</sup> This feature was related to tumour progression in experimental tumour systems.<sup>6–8</sup> Furthermore, human leucocyte antigen (HLA)-DR, a class II MHC antigen, which is normally expressed only in antigen presenting cells of the immune system,<sup>9</sup> shows variable expression in malignancies.<sup>10 11</sup>

The examination of MHC antigen expression in breast carcinoma in particular has been prompted by the observation that lymphocytic infiltrates occur in two thirds of these malignancies,<sup>12</sup> suggesting that the immune system may be active in the modulation of tumour behaviour. MHC-I expression in breast cancer was found to be heterogeneous, but usually decreased.<sup>13–16</sup> In some studies prominent MHC-I expression was related to better tumour differentiation,<sup>14 15</sup> and a favourable prognosis,<sup>17</sup> whereas in others no such correlations were found.<sup>18–21</sup> Regarding HLA-DR expression in breast cancer, most studies report intermediate values,<sup>13 15 18 22–26</sup> but the findings are variable.<sup>12 27</sup> HLA-DR expression may also be related to tumour grade: two studies reported that none of the carcinomas that were negative or only focally positive were well differentiated.<sup>24 26</sup> However, several other studies failed to support this finding.<sup>15 18 25</sup> The link between MHC-II expression and prognosis also remains unclear.<sup>13 16 19</sup>

Only a small number of medullary carcinomas of the breast have been examined for MHC expression. Medullary carcinoma is unique in that it is usually associated with a heavy lymphocytic infiltrate and a relatively good prognosis considering its ominous cytological features.<sup>28 29</sup> Natali *et al* found that the only breast cancers in their series expressing HLA-DR were medullary carcinoma (two of five samples tested) and tubular carcinoma,<sup>22</sup> and Bartek *et al* reported prominent HLA-DR positivity in five of 72 breast carcinomas, two of which were medullary carcinomas.<sup>23</sup> The most intriguing changes were reported in the study by Yazawa *et al*,<sup>30</sup> wherein all 13 medullary carcinomas examined were positive for HLA-DR; in 11 cases, more than 50% of the tumour cells showed positivity.

Our aim in this study was to examine the expression of  $\beta_2$  microglobulin and HLA-DR, components of the MHC-I and MHC-II systems, in medullary carcinoma and atypical

Department of Pathology, Rabin Medical Centre, Sackler Faculty of Medicine, Tel Aviv University, Beilinson Campus, Petah Tiqva 49100, Israel  
M Feinmesser  
S Morgenstern  
S Stern  
E Okon

Department of Oncology, Rabin Medical Centre  
A Sulkes

Epidemiology Unit, Rabin Medical Centre  
J Sulkes

Correspondence to:  
Dr Feinmesser

Accepted for publication  
5 October 1999

Keywords: medullary carcinoma of the breast;  
HLA-DR expression;  $\beta_2$  microglobulin expression

medullary carcinoma of the breast. Atypical medullary carcinoma is histologically similar to medullary carcinoma but has a prognosis similar to that of invasive duct carcinoma.<sup>28 29 31</sup> We sought to determine whether the effective presentation of tumour antigens to the immune system could differentiate between these two tumours and explain the relatively favourable prognosis of medullary carcinoma.<sup>28 29 31</sup>

### Methods

Thirty one breast carcinoma samples were retrieved from the files of the department of pathology of Rabin Medical Centre: 10 invasive duct carcinomas with an accompanying lymphocytic infiltrate; 10 invasive duct carcinomas with, at most, a minimal lymphocytic infiltrate; 10 carcinomas diagnosed as medullary carcinoma; and one tumour initially diagnosed as carcinoma of no special type. The 10 medullary carcinomas and the one carcinoma of no special type were independently reviewed by two of us (MF and SM) according to the criteria of Ridolfi *et al* and Tavassoli for medullary carcinoma and atypical medullary carcinoma of the breast.<sup>28 29</sup> The results yielded a diagnosis of medullary carcinoma in five cases and atypical medullary carcinoma in six (including the carcinoma initially diagnosed as being of no special type). Ten samples of benign breast lesions, including fibroadenomas and fibrocystic changes, and their surrounding normal breast tissue were also retrieved.

The following clinical and histopathological data were collected in most cases: patient age at diagnosis, tumour size, presence of regional (lymph node) and distant metastases, tumour stage at diagnosis,<sup>32</sup> treatment, and patient survival. The cancer patients had been followed to death or for five to 11 years.

### TISSUE PROCESSING AND IMMUNOCYTOCHEMISTRY

All specimens had been fixed in 10% neutral buffered formalin and embedded in paraffin. One representative block from each patient was sectioned at 4  $\mu$ m thick and stained with a monoclonal antibody to HLA-DR (CR3/43, M775, Dako) and a polyclonal antibody to  $\beta_2$  microglobulin (code A 072, Dako). All samples except the invasive duct carcinomas without an accompanying lymphocytic infiltrate and the benign breast controls were also stained with monoclonal antibodies to human leucocyte common antigen (clones 2B11 and PD7/26, M701, Dako), human T cell (clone UCHL 1, M742, Dako), and human B cell (clone L26, M755, Dako). Immunostaining was performed with the immunoperoxidase conjugated indirect method according to Taylor<sup>33</sup> and Mephan *et al*.<sup>34</sup> Mononuclear infiltrates were used as positive internal controls for both HLA-DR and  $\beta_2$  microglobulin. The percentage of immunoreactivity (P) was graded semiquantitatively by two independent observers (MF and SM) as follows: 0 (staining of < 5% of cells), 1+ (5–25% of cells), 2+ (25–50%), 3+ (50–75%), and 4+ (75–100%). Staining intensity (I) was graded from 1+ (weak) to 3+ (intense). Carcinomas were evaluated for both factors,

and the lymphocytic infiltrates only for percentage of immunoreactivity. The predominant location of positive staining was also noted.

### STATISTICAL ANALYSIS

Pearson correlation coefficients (*r*) and their significance (*p*) were calculated between the different variables. Analysis of variance with Duncan's multiple comparison option was used to analyse differences in mean immunostaining of HLA-DR and  $\beta_2$  microglobulin among the tumour types (medullary carcinoma, atypical medullary carcinoma, and invasive duct carcinoma with and without lymphocytic infiltration). Owing to the small size of the tumour type subgroups, non-parametric Kruskal Wallis analysis of variance was also performed, but the *p* values were almost identical to the *p* values in the parametric analysis of variance; *p* values less than or equal to 0.05 were considered significant.

### Results

#### CLINICAL DATA

The mean (SD) age of the 31 patients was 56.7 (14.5) years (range 33 to 82 years), and mean tumour size was 2.5 (1.3) cm (range 0.9 to 8 cm). Stage of disease at presentation was known in 26 patients; most (77%) had stage II disease, and the remainder were divided equally between stage I and stage III. Sixteen patients had lymph node metastases: seven invasive duct carcinoma without lymphocytic infiltrates; seven invasive duct carcinoma with lymphocytic infiltrates; one atypical medullary carcinoma; and one medullary carcinoma. Distant metastases developed in four patients: one atypical medullary carcinoma, one invasive duct carcinoma with lymphocytic infiltrates, and two invasive duct carcinoma without lymphocytic infiltrates (one of the latter also had local recurrence). Treatment methods were known in 24 patients: 10 (41.7%) received a combination of surgery, radiotherapy, and chemotherapy; five (20.8%) surgery and subsequent tamoxifen; five (20.8%) surgery and radiotherapy; three (12.5%) surgery and chemotherapy; and one surgery only.

Four patients died of disease, one with atypical medullary carcinoma and three with invasive duct carcinoma. None of the patients with medullary carcinoma died of disease.

#### HLA-DR AND $\beta_2$ MICROGLOBULIN EXPRESSION

In the benign breast tissue samples, epithelial cells of both acini and ducts were negative for HLA-DR and  $\beta_2$  microglobulin. A few perilobular lymphocytes were positive for both markers. These findings were true for normal breast tissue, fibrocystic changes, and fibroadenomas. Normal breast epithelium adjacent to carcinomas was occasionally positive for both markers. The latter positivity was invariably present in lobules surrounded by a dense lymphocytic infiltrate, as were the adjacent tumours. Immunostaining was predominantly cytoplasmic and weak overall.

All 10 invasive duct carcinomas without lymphocytic infiltrates were negative for  $\beta_2$

Table 1 HLA-DR and  $\beta_2$  microglobulin expression in invasive duct carcinoma with lymphocytic infiltration, atypical medullary carcinoma, and medullary carcinoma: clinical and immunohistological details

Pr	Tumour type	Age (y)	Tumour size (cm)	LNM	Stage at diagn	Treatment	Distant metast and/or recur	F/U (y)/ survival	Tumour immunostaining			LI immunostaining		
									HLA-DR (P)	HLA-DR (I)	$\beta_2$ mic (P)	HLA-DR (P)	HLA-DR (I)	$\beta_2$ mic (I)
1	Invasive duct + LI	62	1.5	7	-	-	0	6/NED	0	0	0	0	0	+4
2	Invasive duct + LI	65	2	1	2	Mas, chem, tam	0	5/NED	0	0	0	0	+1	+1
3	Invasive duct + LI	68	2	1	2	WE	0	5/NED	0	0	0	0	+1	+2
4	Invasive duct + LI	34	2.5	0	-	WE	0	8/NED	0	0	0	0	+2	+3
5	Invasive duct + LI	75	3	0	2	WE, rad, tam	0	9/NED	0	0	0	0	+1	+3
6	Invasive duct + LI	43	1.5	9	2	WE, chem, rad	0	5/NED	0	0	0	0	0	0
7	Invasive duct + LI	73	3	No AD	2	Mas, tam	Local rec, liver met	2/DOD	+1	+1	+4	+2	+1	+1
8	Invasive duct + LI	45	0.9	0	1	WE, chem, rad	0	6/NED	0	0	0	0	+1	+3
9	Invasive duct + LI	69	2.5	1	2	WE, rad, tam	0	5/NED	0	0	0	0	0	+2
10	Invasive duct + LI	62	1.5	4	2	Mas, rad, tam	0	5/DOD	0	0	0	0	+4	+3
11	Atypical medullary Ca	59	3	0	2	WE, chem, rad	Bone, liver	6/NED	0	0	0	0	+1	+3
12	Atypical medullary Ca	45	2.5	1	2	WE, chem, rad	0	7/NED	+2	+2	+2	+1	+1	+1
13	Atypical medullary Ca	58	2	0	2	WE, tam	0	8/NED	0	0	0	0	0	0
14	Atypical medullary Ca	45	4	-	-	-	-	10/NED	0	0	0	0	+1	+1
15	Atypical medullary Ca	30	3	0	2	WE, chem, rad	Lung, brain	3/DOD	0	0	0	0	+1	+2
16	Atypical medullary Ca	56	1	0	1	WE, chem, rad	0	11/NED	0	0	0	0	0	+2
17	Medullary Ca	50	2	No AD	2	WE, chem, rad	0	9/NED	+2	+2	+1	+1	+3	+3
18	Medullary Ca	48	1.5	No AD	2	-	0	10/NED	+4	+4	+4	+3	+1	+2
19	Medullary Ca	56	2.5	0	2	Mas, chem, tam	0	10/NED	+3	+3	+3	+2	0	+3
20	Medullary Ca	47	4.5	No AD	3	WE, chem, rad	0	11/NED	0	0	0	0	+2	+3
21	Medullary Ca	33	1.6	3	2	Mas, chem	0	9/NED	+3	+2	+4	+3	+2	+3

Patients with invasive duct carcinoma without lymphocyte infiltration were not included, as the immunohistological stains were overwhelmingly negative. AD, axillary dissection;  $\beta_2$  mic,  $\beta_2$  microglobulin; chem, chemotherapy; diag, diagnosis; DOD, dead of disease; F/U, follow up; HLA-DR, human leucocyte antigen DR; (I), intensity of immunostaining; LI, lymphocytic infiltration; LNM, lymph node metastases; mas, mastectomy; metast, metastasis; NEI, alive with no evidence of disease; (P), percentage of immunostaining; Pt, patient; rad, radiotherapy; recur, recurrence; tam, tamoxifen; WE, wide excision; y, years.

microglobulin expression. One showed focal cytoplasmic positivity for HLA-DR (P 1+, I 2+).

Five of the 10 invasive duct carcinomas with lymphocytic infiltrates (table 1) were also negative for HLA-DR and  $\beta_2$  microglobulin expression. Of the remainder, one showed mild HLA-DR positivity and prominent membranous  $\beta_2$  microglobulin positivity, and four showed moderate HLA-DR positivity. In no case did positivity seem to be spatially related to the lymphocytic infiltrates, except for one case in which the positive cells were at the periphery of the tumour, closely apposed to the infiltrates. Staining was both membranous and cytoplasmic, with a predominance of the former. In all the tumours, the lymphocytic infiltrates were positive to some degree for HLA-DR and  $\beta_2$  microglobulin. A wide range of expression was present, from 1+ to 4+.

Regarding atypical medullary carcinoma (table 1), only one of the six samples examined was positive for HLA-DR (P 2+, I 2+). Three tumours, including the one with HLA-DR positivity, showed  $\beta_2$  microglobulin positivity (P 2+, 3+, 3+; I 1+, 2+, 2+). Staining was predominantly cytoplasmic, apart from the tumour showing both HLA-DR and  $\beta_2$  microglobulin expression in which membranous staining was predominant. Positively stained areas were often closely apposed to the inflammatory infiltrates, as these tumours were relatively heavily inflamed. The lymphocytic infiltrates themselves showed minor HLA-DR positivity (0 or 1+) and variable  $\beta_2$  microglobulin positivity (0 to 3+).

Findings for medullary carcinoma (table 1) yielded HLA-DR and  $\beta_2$  microglobulin positivity in four of the five tumours examined. In three of them, staining was widespread and intense (HLA-DR, P 4+, 3+, 3+, I 3+, 2+, 2+;  $\beta_2$  microglobulin, P 4+, 3+, 4+, I 3+, 2+, 3+) (figs 1 and 2), and in one, staining was moderate for HLA-DR (P 2+, I 2+) and weak for  $\beta_2$  microglobulin (P 1+, I 1+). One tumour was negative for both. Positively stained areas did not seem to be preferentially related to the lymphocytic infiltrates, though in many areas positively staining epithelium was closely apposed to the infiltrate, as these tumours were all heavily inflamed. The accompanying lymphocytic infiltrates were positive to a variable degree for both HLA-DR and  $\beta_2$  microglobulin immunostaining, with grades ranging from negative to 3+ and from 2+ to 3+, respectively.

#### STATISTICAL FINDINGS

A positive and statistically significant correlation was found between tumour type and HLA-DR positivity with regard to both percentage ( $r = 0.62$ ,  $p = 0.0002$ ) and intensity ( $r = 0.53$ ,  $p = 0.002$ ). The most prominent HLA-DR immunostaining was found in medullary carcinoma, with lesser degrees in atypical medullary carcinoma, followed by invasive duct carcinoma with and without lymphocytic infiltration. Similar findings were noted between tumour type and  $\beta_2$  microglobulin positivity, percentage ( $r = 0.55$ ,  $p = 0.01$ ) and intensity ( $r = 0.57$ ,  $p = 0.0007$ ). Again, medullary carcinoma

showed the most marked  $\beta_2$  microglobulin expression.

There was a positive and statistically significant correlation between HLA-DR and  $\beta_2$  microglobulin tumour immunostaining.

Significant differences were found among the four tumour types in mean HLA-DR and  $\beta_2$  microglobulin immunostaining for both percentage ( $p = 0.0001$  and  $p = 0.0115$ , respectively) and intensity ( $p = 0.0006$  and

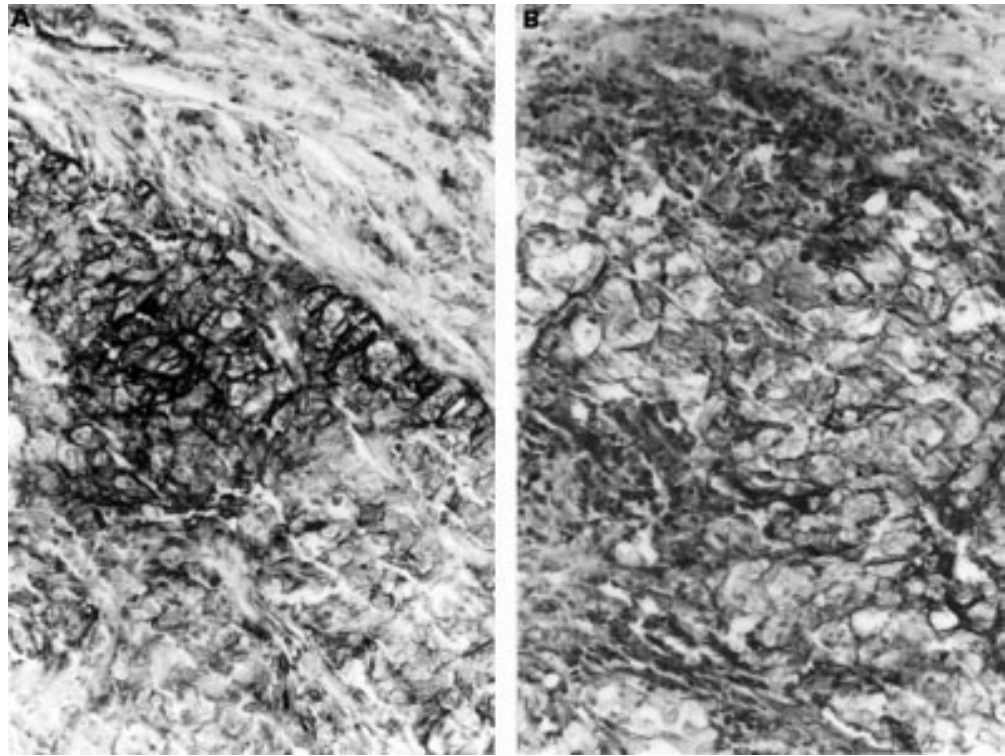


Figure 1 Prominent, predominantly membranous, immunopositivity for HLA-DR (A) and  $\beta_2$  microglobulin (B) in medullary carcinoma of the breast. Immunopositivity was also noted in some of the surrounding lymphocytes.

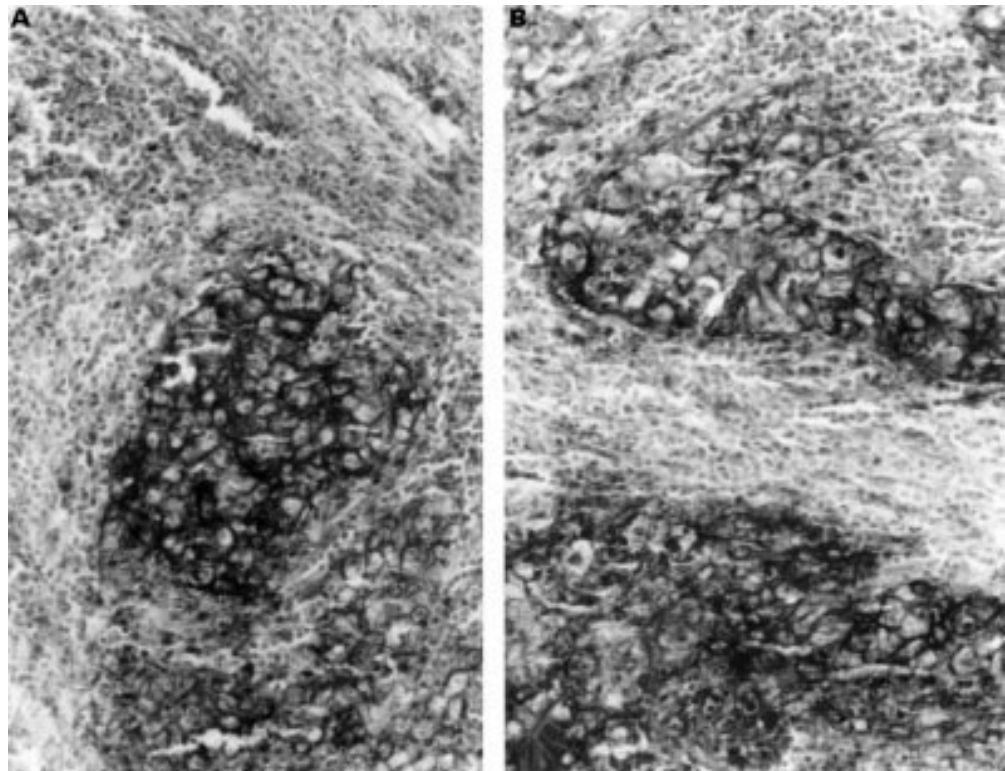


Figure 2 Widespread immunopositivity for HLA-DR (A) and  $\beta_2$  microglobulin (B) in medullary carcinoma of the breast. The surrounding lymphocytic infiltrate appears predominantly negative.

Table 2 Major histocompatibility antigen immunostaining by tumour type

Variable	Tumour type				p Value
	IDC without LI	IDC with LI	ATMC	MC	
HLA-DR in tumour (%)	0.10 <sup>A</sup>	0.10 <sup>A</sup>	0.33 <sup>A</sup>	2.4 <sup>B</sup>	0.001
HLA-DR in tumour (intensity)	0.20 <sup>A</sup>	0.10 <sup>A</sup>	0.33 <sup>A</sup>	1.80 <sup>B</sup>	0.0006
$\beta_2$ Microglobulin in tumour (%)	0.00 <sup>A</sup>	1.2	1.33	2.4 <sup>B</sup>	0.011
$\beta_2$ Microglobulin in tumour (intensity)	0.00 <sup>A</sup>	0.80 <sup>A</sup>	0.83 <sup>A</sup>	1.80 <sup>B</sup>	0.0057
HLA-DR in LI	–	1.10	0.67	1.60	0.35
$\beta_2$ Microglobulin in LI	–	2.20	1.50	2.80	0.15

Values are means. <sup>A,B</sup> Pairwise comparisons. Means with different letters are significantly different ( $p \leq 0.05$ ). ATMC, atypical medullary carcinoma; IDC, invasive duct carcinoma; LI, lymphocytic infiltrate; MC, medullary carcinoma.

$p = 0.0057$ ) (table 2). For HLA-DR, medullary carcinoma had higher values than invasive duct carcinoma with and without lymphocytic infiltrates and atypical medullary carcinoma (percentage: 2.4 v 0.10, 0.10, 0.33; intensity: 1.8 v 0.2, 0.1, 0.33;  $p \leq 0.05$  for both). For  $\beta_2$  microglobulin, medullary carcinoma showed a higher percentage of staining than invasive duct carcinoma without lymphocytic infiltrates (2.4 v 0.00;  $p < 0.05$ ), and there was a trend for increased values from invasive duct carcinoma with lymphocytic infiltrates to atypical medullary carcinoma and medullary carcinoma. Stronger  $\beta_2$  microglobulin staining was also noted in medullary carcinoma than in invasive duct carcinoma with and without lymphocytic infiltrates and in atypical medullary carcinoma (1.8 v 0.00, 0.80, 0.83;  $p \leq 0.05$ ).

No significant differences were found in mean lymphocytic HLA-DR and  $\beta_2$  microglobulin immunostaining among the four tumour types.

There were correlations between tumour size and lymph node metastasis ( $r = 0.42$ ,  $p = 0.03$ ), distant metastasis ( $r = 0.416$ ,  $p = 0.03$ ), stage of disease at diagnosis ( $r = 0.72$ ,  $p = 0.0001$ ), and survival ( $r = 0.45$ ,  $p = 0.02$ ). Larger tumours were associated with a higher incidence of lymph node and distant metastases, a higher stage at diagnosis, and decreased survival. However, none of these variables was significantly correlated with either tumour or lymphocyte HLA-DR and  $\beta_2$  microglobulin immunostaining.

## Discussion

Medullary carcinoma of the breast, one of the rare tumours of the mammary gland, is characterised by a tendency to solid and syncytial growth patterns, well circumscribed tumour margins, highly pleomorphic nuclei with many mitoses, and an accompanying lymphocytic infiltrate which is usually prominent.<sup>29</sup> These features would not, in themselves, be considered remarkable were the malignancy not associated with a relatively good prognosis.<sup>28 29</sup> Furthermore, atypical medullary carcinoma, which is histopathologically similar to medullary carcinoma, carries a prognosis closer to that of regular invasive duct carcinoma.<sup>29 31</sup> Therefore some investigators have suggested that the so called variants of medullary carcinoma are in fact part of the main body of breast carcinomas of no special type.<sup>29 31 35</sup>

Although it was originally thought that the lymphocytic infiltrates in medullary carcinoma represent a successful immune response, later studies showed that even medullary carcinoma with light infiltration has a favourable prognosis. Furthermore, in some cases, the lymphocytic infiltrates in medullary carcinoma show fewer markers of activation than those in regular invasive duct carcinoma.<sup>36</sup>

The findings in studies examining MHC expression in breast carcinomas have been controversial regarding its relation with lymphocytic infiltration.<sup>12 13 15 18 23–26 30</sup> In some studies HLA-DR expression occurred with little associated lymphocytic infiltration,<sup>25 26</sup> implying that occasionally MHC expression, which is necessary for antigen presentation to T helper and T cytotoxic lymphocytes, is an intrinsic quality of the tumour. We hypothesised that the favourable prognosis of medullary carcinoma is related primarily to this intrinsic quality. MHC expression may be a primary event, with the lymphocytic infiltrate representing a reactive phenomenon or, alternatively, medullary carcinoma may be a highly susceptible tumour wherein internal lymphocytic infiltrates induce MHC expression.

In the present study, we found that both  $\beta_2$  microglobulin and HLA-DR antigens—components of the MHC-I and MHC-II antigen systems, respectively—are predominantly expressed in medullary carcinoma of the breast. Their much weaker expression in atypical medullary carcinoma may indicate a lack of tumour antigen presentation by this tumour, thereby explaining to some degree the closer prognosis of atypical medullary carcinoma to regular invasive duct carcinoma than to medullary carcinoma.

Several studies have documented difficulties in differentiating medullary carcinoma from atypical medullary carcinoma and carcinomas of no special type.<sup>28 31 35 37</sup> When the well delineated criteria for medullary carcinoma of Ridolfi *et al* are applied,<sup>28</sup> medullary carcinomas actually account for only one half to two thirds of the cases initially considered medullary carcinoma or possible medullary carcinoma. Even in our small group, only five of the 10 cases initially diagnosed as medullary carcinoma had the same final diagnosis, and the remainder were atypical medullary carcinomas. We suggest that HLA-DR and  $\beta_2$  microglobulin immunostaining may be beneficial in differentiating these two entities. Furthermore, prominent positivity for both MHC-I and MHC-II antigens may serve not only as a marker for diagnosis but also as an indicator of biological behaviour. Our findings also lend support to the contention that atypical medullary carcinoma should not be viewed as a distinct entity.

MHC tumour expression before, during, or after immunotherapy may be a necessary step in tumour response to treatment. Breast cancer has low activity of tumour infiltrating lymphocytes,<sup>38</sup> and immunotherapy has not shown any advantage.<sup>39</sup> Studies have shown that malignancies that respond to interleukin (IL)-2 treatment express HLA-DR before

treatment,<sup>40</sup> whereas non-responding tumours do not, either before or after treatment.<sup>40</sup> Likewise, malignant melanomas transfected with MHC-I genes showed better responses to IL-2 treatment,<sup>5</sup> and MHC-I induction in a highly tumorigenic adenovirus-2 transformed cell line resulted in the complete loss of oncogenicity.<sup>41</sup> Therefore, we suggest that immunotherapy with a cocktail of cytokines known to induce MHC-I and MHC-II expression<sup>18 27 42-44</sup> may induce breast tumour cells to express MHC-I and MHC-II antigens. This could increase their immunogenicity and susceptibility to cytotoxic and helper T cells, respectively, and activate lymphocytic infiltrates to proliferate in situ.

Even though medullary carcinoma is a rare tumour, its sparsity in our centre is surprising in the light of the relatively high rate of breast cancer in Jewish women of Ashkenazi origin, and it may be a reflection of ethnic and genetic differences. Nevertheless, despite our small number of cases, our findings regarding tumour HLA-DR and  $\beta_2$  microglobulin expression are statistically significant. Larger studies may clarify some of the issues raised here. We believe the finding of prominent MHC-I and MHC-II expression in a rare but relatively favourable form of breast cancer will ultimately contribute to our understanding of and therapeutic approach to the main body of breast carcinomas.

- Doyle A, Martin JW, Funa K. Markedly decreased expression of class I histocompatibility antigens protein, and mRNA in human small cell lung cancer. *J Exp Med* 1985;161:1135-51.
- Holden CA, Sanderson AR, MacDonald DM. Absence of human leukocyte antigen molecules in skin tumors and some cutaneous appendages: evidence using monoclonal antibodies. *J Am Acad Dermatol* 1983;9:867-71.
- Lampson LA, Fisher CA, Whelan JP. Striking paucity of HLA-A, B, C and beta-2-microglobulin on human neuroblastoma cell lines. *J Immunol* 1983;130:2471-8.
- Hämmerling G, Maschek U, Sturmhöfel K, et al. Regulation and functional role of MHC expression on tumors. In: Melchers F, Albert ED, Von Boehmer AH, et al, eds. *Progress in immunology*, vol 7. Berlin: Springer-Verlag, 1989: 1071-8.
- Rubin JT, Elwood LJ, Rosenberg SA, et al. Immunohistochemical correlates of response to recombinant interleukin-2-based immunotherapy in humans. *Cancer Res* 1989;49: 7086-92.
- Vogel J, Tanaka K, Hoekzema GS, et al. Experimental strategies for modification of histocompatibility antigens in tumor cell. *Cancer Metastasis Rev* 1987;6:677-83.
- Goodenow RS, Vogel JM, Linsk RL. Histocompatibility antigens on murine tumors. *Science* 1985;230:777-83.
- Schrier PI, Bernards R, Vaessen RT, et al. Expression of class I major histocompatibility antigens switched off by highly oncogenic adenovirus 12 in transformed rat cells. *Nature* 1983;305:771-5.
- Kaufman JF, Auffray C, Korman AJ, et al. The class II molecules of the human and murine major histocompatibility complex. *Cell* 1984;36:1-13.
- Müller C, Ziegler A, Müller C, et al. Divergent expression of HLA-DC/MB, -DR and -SB region products on normal and pathological tissues as detected by monoclonal antibodies. *Immunobiology* 1985;169:228-49.
- Ghosh AK, Moore M, Street AJ, et al. Expression of HLA-D sub-region products on human colorectal carcinoma. *Int J Cancer* 1986;38:459-64.
- Hurlimann J, Saraga P. Mononuclear cells infiltrating human mammary carcinomas: Immunohistochemical analysis with monoclonal antibodies. *Int J Cancer* 1985;35: 753-62.
- Lucin K, Iternicka Z, Jonjic N. Prognostic significance of T-cell infiltrates, expression of  $\beta_2$ -microglobulin and HLA-DR antigens in breast carcinoma. *Pathol Res Pract* 1994;190:1134-40.
- Weiss MA, Michael JG, Pesce AJ, et al. Heterogeneity of  $\beta_2$ -microglobulin in human breast carcinoma. *Lab Invest* 1981;45:46-57.
- Zuk JA, Walker RA. Immunohistochemical analysis of HLA antigens and mononuclear infiltrates of benign and malignant breast. *J Pathol* 1987;152:275-85.
- Wintzer HO, Benzing M, von Kleist S. Lacking prognostic significance of B2-microglobulin, MHC class I and class II antigen expression in breast carcinomas. *Br J Cancer* 1990; 62:289-95.
- Concha A, Esteban F, Cabrera T, et al. Tumor aggressiveness and MHC class I and II antigens in laryngeal and breast cancer. *Semin Cancer Biol* 1991;2:47-54.
- Möller P, Mattfeldt T, Gross C, et al. Expression of HLA-A, -B, -C, -DR, -DP, -DQ, and of HLA-D-associated invariant chain (Ii) in non-neoplastic mammary epithelium, fibroadenoma, adenoma, and carcinoma of the breast. *Am J Pathol* 1989;135:73-83.
- Pérez M, Cabrera T, Lopez Nevot MA, et al. Heterogeneity of the expression of class I and II HLA antigens in human breast carcinoma. *J Immunogenet* 1986;13:247-53.
- Concha A, Cabrera T, Ruiz-Cabello F, et al. Can the HLA phenotype be used as a prognostic factor in breast carcinomas? *Int J Cancer* 1991;6(suppl):146-54.
- Tsuda H, Hirohashi S, Higuchi K, et al. Beta-2-microglobulin expression in relation to amplification of oncogenes and prognosis in breast carcinoma. *Histopathology* 1990;16:500-2.
- Natali PG, Giacomini P, Bigotti A, et al. Heterogeneity in the expression of HLA and tumor-associated antigens by surgically removed and cultured breast carcinoma cells. *Cancer Res* 1983;43:660-8.
- Bartek J, Petrek M, Vogtesek B, et al. HLA-DR antigens on differentiating human mammary gland epithelium and breast tumors. *Br J Cancer* 1987;56:727-33.
- Zuk JA, Walker RA. HLA class II sublocus expression in benign and malignant breast epithelium. *J Pathol* 1988;155: 301-9.
- Koretz K, Moldenhauer G, Majdic O, et al. Correlation of HLA-D/Ii antigen expression in breast carcinoma with local lymphohistiocytic infiltration reveals considerable dysregulation in a subset of tumors. *Int J Cancer* 1989;44:816-22.
- Brunner CA, Gokel JM, Riethmüller G, et al. Expression of HLA-D subloci DR and DQ by breast carcinomas is correlated with distinct parameters of favourable prognosis. *Eur J Cancer* 1991;27:411-16.
- Bernard D, Maurizis JC, Rusé F, et al. Presence of HLA-D/DR antigens on the membrane of breast tumor cells. *Clin Exp Immunol* 1984;56:215-21.
- Ridolfi RL, Rosen PP, Port A, et al. Medullary carcinoma of the breast: a clinicopathologic study with 10-year follow-up. *Cancer* 1977;40:1365-85.
- Tavassoli FA. *Pathology of the breast*. Norwalk, Connecticut: Appleton and Lange, 1992:333-9.
- Yazawa T, Kamma H, Ogata T. Frequent expression of HLA-DR antigen in medullary carcinoma of the breast. A possible reason for its prominent lymphocytic infiltration and favorable prognosis. *Appl Immunohistochem* 1993;1: 289-96.
- Wargotz ES, Silverberg SG. Medullary carcinoma of the breast: a clinicopathologic study with appraisal of current diagnostic criteria. *Hum Pathol* 1988;19:1340-6.
- Beahrs OH, Henson DE, Hutter RVP, et al. *Handbook for staging of cancer, from the manual for staging of cancer*, 4th ed. American Joint Committee on Cancer, TNM Committee of the International Union Against Cancer. Philadelphia: JB Lippincott Co, 1993:165-7.
- Taylor CR. Immunoperoxidase techniques. *Arch Pathol Lab Med* 1978;102:113-21.
- Mephan BL, Frater W, Mitchell BS. The use of proteolytic enzymes to improve immunoglobulin staining by the PAP technique. *Histochem J* 1979;11:345-7.
- Rapin V, Contesso G, Mouriesse H, et al. Medullary breast carcinoma: a reevaluation of 95 cases of breast cancer with inflammatory stroma. *Cancer* 1988;61:2503-10.
- Benezra J, Sheibani K. Antigenic phenotype of the lymphocytic component of medullary carcinoma of the breast. *Cancer* 1987;59:2037-41.
- Rubens JR, Lewandrowski KB, Kopans DB, et al. Medullary carcinoma of the breast. Over-diagnosis of a prognostically favorable neoplasm. *Arch Surg* 1990;125:601-4.
- Balch CM, Riley LB, Bae YJ, et al. Patterns of human tumor-infiltrating lymphocytes in 120 human cancers. *Arch Surg* 1990;125:200-5.
- Early Breast Cancer Trialists' Collaborative Group. Systemic treatment of early breast cancer by hormonal, cytotoxic or immune therapy. 133 randomized trials involving 31,000 recurrences and 24,000 deaths among 75,000 women. *Lancet* 1992;339:71-85.
- Cohen PJ, Lotze MT, Roberts JR, et al. The immunopathology of sequential tumor biopsies in patients treated with interleukin-2. Correlation of response with T-cell infiltration and HLA-DR expression. *Am J Pathol* 1987;129:208-16.
- Tanaka K, Isselbacher KJ, Khoury G, et al. Reversal of oncogenesis by the expression of a major histocompatibility complex class I gene. *Science* 1985;228:26-30.
- Matory YL, Chen M, Dorfman DM, et al. Antitumor activity of three mouse mammary cancer cell lines after interferon-gamma gene transfection. *Surgery* 1995;118: 251-6.
- Jabran-Ferrat N, Failla A, Loiseau P, et al. Effect of gamma interferon on class I and II transcription and protein expression in human breast adenocarcinoma cell lines. *Int J Cancer* 1990;45:1169-76.
- Bernard DJ, Courjal F, Maurizis JC, et al. Effect of epidermal growth factor in HLA class I and class II transcription and protein expression in human breast adenocarcinoma cell lines. *Br J Cancer* 1992;66:88-92.



## HLA-DR and $\beta_2$ microglobulin expression in medullary and atypical medullary carcinoma of the breast: histopathologically similar but biologically distinct entities

Meora Feinmesser, Aaron Sulkes, Sara Morgenstern, et al.

*J Clin Pathol* 2000 53: 286-291

doi: 10.1136/jcp.53.4.286

---

Updated information and services can be found at:

<http://jcp.bmj.com/content/53/4/286.full.html>

---

*These include:*

### References

This article cites 39 articles, 8 of which can be accessed free at:

<http://jcp.bmj.com/content/53/4/286.full.html#ref-list-1>

Article cited in:

<http://jcp.bmj.com/content/53/4/286.full.html#related-urls>

### Email alerting service

Receive free email alerts when new articles cite this article. Sign up in the box at the top right corner of the online article.

---

### Topic Collections

Articles on similar topics can be found in the following collections

[Breast cancer](#) (378 articles)

[Immunology \(including allergy\)](#) (1279 articles)

---

### Notes

---

To request permissions go to:

<http://group.bmj.com/group/rights-licensing/permissions>

To order reprints go to:

<http://journals.bmj.com/cgi/reprintform>

To subscribe to BMJ go to:

<http://group.bmj.com/subscribe/>