

Improved prognosis of Epstein-Barr virus associated childhood Hodgkin's lymphoma: study of 47 South African cases

M Engel, M F Essop, P Close, P Hartley, G Pallesen, C Sinclair-Smith

Abstract

Aim—To study the distribution of Hodgkin's lymphoma in South African children and report the incidence of Epstein-Barr virus (EBV) as regards age, race, sex, and histological subtype; to investigate whether EBV is relevant to survival.

Methods—Immunohistochemistry (IHC) and in situ hybridisation (ISH) to detect EBV were performed on 47 South African children with classical Hodgkin's lymphoma, ranging in age from 3 to 14 years and coming from different ethnic backgrounds. The correlation between the presence of the virus and clinical outcome was assessed.

Results—The nodular sclerosing subtype predominated, comprising 89% of cases; the remaining 11% were of the mixed cellularity subtype. EBV was present in 68%. Full clinical data were available for 36 cases; EBV positive patients presented with less aggressive symptoms at diagnosis and had a significantly longer median survival than EBV negative patients.

Conclusions—The distribution of EBV in South African childhood Hodgkin's lymphoma follows a pattern intermediate to that of industrialised and non-industrialised countries. Furthermore, our data suggest that there is an association between poor prognosis and the non-detection of EBV products in South African childhood Hodgkin's lymphoma.

(*J Clin Pathol* 2000;53:182-186)

Keywords: children; Epstein-Barr virus; Hodgkin's lymphoma

Department of
Pathology, Red Cross
Children's Hospital
and Institute of Child
Health, Private Bag,
Rondebosch 7700,
South Africa
M Engel
C Sinclair-Smith

Department of
Pediatrics, Red Cross
Children's Hospital
P Hartley

Department of
Pathology, Groote
Schoor Hospital,
University of Cape
Town, Cape Town,
South Africa
M F Essop
P Close
G Pallesen

Correspondence to:
Professor Sinclair-Smith
email:
cs-smith@ich.uct.ac.za

Accepted for publication
13 September 1999

vitro,⁷ is strongly expressed in all neoplastic cells in EBV positive Hodgkin's lymphoma.⁸

A pathogenic role for EBV in childhood Hodgkin's lymphoma has been suggested, and various factors including ethnicity and geographical location may represent biological modifiers of the association of EBV with Hodgkin's lymphoma.⁹⁻¹⁰ Studies in non-industrialised countries report a strong correlation of age of peak incidence in children with Hodgkin's lymphoma and EBV infection. Examples include Honduras (100%),⁹ Chinese (100%),¹¹ Brazilian (77%),¹² Mexican (65%),¹³ Peruvian (100%),¹⁴ and Malaysian (93%)¹⁵ paediatric cases of classical Hodgkin's lymphoma. Where lower EBV occurrences in Hodgkin's lymphoma have been reported in non-industrialised countries, there is often nonetheless a high incidence (up to 100%) in the patients younger than nine years of age included in the studies.¹⁶⁻¹⁷ This contrasts with the situation in industrialised countries, where the peak generally occurs in early adulthood with no apparent association with EBV infection,⁹⁻¹⁸⁻²⁰ although a significant association between EBV and Hodgkin's lymphoma in younger patients in the United Kingdom has been reported.²¹

With regard to histological subtype and the association with EBV, the mixed cellularity (MC) subtype shows a clear association with EBV,⁸⁻²² while the EBV incidence in the nodular sclerosing (NS) subtype usually ranges between 20% and 33% in industrialised countries,⁸⁻²²⁻²⁵ and between 45% and 100% in non-industrialised countries.⁹⁻¹¹⁻¹⁴⁻²⁰ As far as sex is concerned, there is a higher frequency of EBV in male patients developing Hodgkin's lymphoma of childhood.¹⁰⁻¹⁴

Conflicting opinions are expressed about EBV infection and prognosis in Hodgkin's lymphoma patients. A few studies investigating clinical outcome have found no significant difference in progression-free survival between LMP1 positive and LMP1 negative patients.²³⁻²⁵⁻²⁶ Oudejans *et al* reported a significantly shorter progression-free survival time in EBV positive Hodgkin's lymphoma, although there was no difference in the overall survival time.²⁷ EBV has been associated with Hodgkin's lymphoma in patients presenting with advanced stage disease¹⁴⁻²⁸ or more aggressive histological subtype.²³ In addition, aggressive histology coinciding with aggressive clinical behaviour has been reported in a study in patients with a 30 base pair deletion variant of the EBV LMP1 gene.²⁹ In contrast to these

Serological studies in the 1970s indicated that Epstein-Barr virus (EBV) infection was associated with Hodgkin's lymphoma.¹ Later, hybridisation blotting techniques showed the presence of the virus in Hodgkin's lymphoma.² Localisation of EBV to Hodgkin and Reed-Sternberg (HRS) cells was subsequently shown by in situ hybridisation (ISH).³ There is increasing evidence of the involvement of EBV in the development of Hodgkin's lymphoma; EBV genomes in Hodgkin's lymphoma are monoclonal⁴ and the virus has been shown to persist in all the sites involved in EBV positive Hodgkin's lymphoma patients.⁵⁻⁶ It has also been shown that a product of the EBV BNLF-1 gene, latent membrane protein-1 (LMP1), an integral membrane protein of known transforming ability also affecting apoptosis in

studies, Morente *et al* recently provided convincing evidence that LMP1-EBV expression is a favourable prognostic marker for overall survival.³⁰

The demographic diversity in South Africa provides a rich epidemiological background for studying the various factors relating to the association between EBV and Hodgkin's lymphoma. In this study, we report the pattern of Hodgkin's lymphoma in South African children under the age of 15 years. In an attempt to assess the role of EBV in Hodgkin's lymphoma, the incidence of EBV was investigated and correlated with age, racial classification, sex, histological subtype, and clinical outcome.

Methods

PATIENTS AND SAMPLES

In all, 47 paraffin wax embedded archival biopsies comprising mixed race (n = 24), blacks (n = 15), and whites (n = 8), spanning 1983–1995, were retrieved from the departments of pathology at Red Cross Children's and Groote Schuur Hospitals, University of Cape Town. The mixed race (also referred to as "Cape coloureds") is a heterogeneous group which evolved over the past 300 years by probable combinations of predominantly Khoi San, Xhosa, Cape Malays, and Europids. The consecutively selected cases were all from patients under the age of 15 years diagnosed as having childhood Hodgkin's lymphoma. A single case of lymphocyte predominance subtype was excluded so as to confine the study to classic Hodgkin's lymphoma (only MC and NS histological subtypes). Haematoxylin and eosin stained sections were reviewed by at least two pathologists to confirm the diagnosis and histological subtype, in accordance with standard criteria. Patient demographics and follow up data were obtained from the clinical files in collaboration with the department of oncology, Red Cross Children's Hospital. Patients were treated following the conventional therapeutic approaches. Treatment decisions were not based on knowledge of EBV status. The follow up data period varied from four to 150 months from the time of presentation.

DETECTION OF EBV BY IMMUNOHISTOCHEMISTRY AND EBER-ISH

The techniques of immunohistochemistry (IHC) and ISH were employed to detect EBV in tumour cells in our patients. Microwave antigen retrieval was used as an adjunct to IHC.³¹ Briefly, 5 µm sections mounted on slides coated with APES (aminopropyltriethoxysilane) were dewaxed and endogenous peroxidase activity blocked in 0.5% H₂O₂/methanol, transferred to 0.01 M sodium citrate solution, pH 6.0, and then irradiated for 2 × 5 minutes. Sections were stained with a pool of four mouse monoclonal antibodies (CS1–4) specific for LMP1 (diluted 1:50) (Dako), and diaminobenzidine was used as a chromogen.³² To exclude false negatives, LMP1 negative cases were submitted for EBER-ISH, a technique known to be sensitive and reliable for the detection of EBV.^{33 34} EBER-ISH was performed as previously described with RNase-

free precautions being observed. A known EBV positive LMP1-expressing Hodgkin's lymphoma sample was used as the external control.

STATISTICAL METHODS

Associations were analysed using Fisher's exact two tailed test. Survival curves were generated using Kaplan-Meier's method and the resulting survival distributions were compared using a log rank test.

Results

HISTOLOGICAL SUBTYPE

The age of the patients in this study ranged from three to 14 years (mean = 8.4 years; median = 8.0 years). The race and sex distribution with regard to histological subtype is indicated in table 1. The peak incidence of Hodgkin's lymphoma was seen between the ages of seven and 11 years. There was an overall male predominance, with 81% male and 19% female patients (4.2:1). Forty two patients (89%) were classified as NS, while only five (11%) were of the MC subtype. Of the NS patients, 24 were of mixed race, 10 black, and eight white, while all five MC patients were black (p = 0.006). Thirty six of the 42 NS cases (86%) and three of the five MC cases were male (p = 0.04), giving a male to female ratio in NS and MC of 6.1:1 and 1.5:1, respectively. All the mixed race (24/24) and white (8/8) patients included in this study were of the NS subtype. The black patients consisted of 10 cases (67%) with the NS and five (33%) with the MC subtype. The five black MC cases consisted of two boys and three girls (p = 0.04).

EBV GENE EXPRESSION

Results of the EBV investigation are given in table 2. EBV products were detected in the HRS cells of 32 Hodgkin's lymphoma cases (68%). Three cases which were LMP1 negative

Table 1 Racial distribution of South African childhood Hodgkin's lymphoma, n (%)

	Race			Total
	Mixed	Black	White	
Total	24 (51)	15 (32)	8 (17)	47 (100)
Sex				
Male	20 (83)	11 (73)	7 (87)	38 (81)
Female	4 (17)	4 (27)	1 (13)	9 (19)
Subtype				
NS	24 (100)	10 (67)	8 (100)	42 (89)
MC	0 (0)	5 (33)	0 (0)	5 (11)

MC, mixed cellularity; NS, nodular sclerosing.

Table 2 EBV distribution in South African childhood Hodgkin's lymphoma

	EBV positive (%) (n=32)	Totals (n=37)
Race		
Mixed	18 (75)	24
Black	10 (65)	15
White	4 (50)	8
Sex		
Male	26 (68)	38
Female	6 (67)	9
Histological subtype		
Nodular sclerosing	28 (67)	42
Mixed cellularity	4 (80)	5

EBV, Epstein-Barr virus.

Table 3 EBV results and correlation with disease status in South African childhood Hodgkin's lymphoma

	EBV positive (n=24) (%)	EBV negative (n=12) (%)	p Value
Stages I and II	14 (58)	5 (42)	
Stages III and IV	10 (42)	7 (58)	0.30
"B" symptoms	3 (13)	6 (50)	0.008
Median survival (months)	63	47	0.004
Median relapse-free survival (months)	63	63	0.03
Alive, disease-free	23 (96)	7 (58)	0.01
Alive with disease/died of disease	1 (4)	5 (42)	0.03

EBV, Epstein-Barr virus.

by IHC showed EBER positivity by ISH. The ethnic distribution of EBV association in Hodgkin's lymphoma was 18 of 24 (75%) in mixed, 10 of 15 (67%) in black, and four of eight (50%) in white patients ($p = 0.4$). There was an equal sex distribution, with 68% of boys and 67% of girls showing expression of the virus. With regard to the subtypes, there was a trend for the MC cases to be EBV positive: four of five (80%), compared with 28/42 (67%) of the NS subtype. Of the MC cases, one of the black boys and all three black girls were positive. There was no overall difference in the age of the patients with respect to their EBV status. Further analysis showed a significant difference in age in the mixed race and black patients, the EBV negative patients being older by a median of three years ($p = 0.048$), while the white patients did not show any significant age difference.

CORRELATION WITH DISEASE STATUS

Clinical follow up data were available for 36 of the 47 cases in our study. Of the EBV positive patients ($n = 24$), 14 presented with early stage disease and 10 with late stage; among the EBV negative patients ($n = 12$), five presented with early stage disease and seven with late stage (table 3). Three of the 24 EBV positive patients and six of the 12 EBV negative patients presented with "B" symptoms. Of the EBV positive cases, 23 (96%) were alive without disease compared with seven (58%) of the EBV negative cases ($p = 0.0102$). In addition, a significantly longer median survival was observed in EBV positive cases (log rank p value = 0.0040) (fig 1). There was one death among the EBV positive group, the remainder being free of disease, while five of the 12 patients in the EBV negative group had either died or still had evidence of disease.

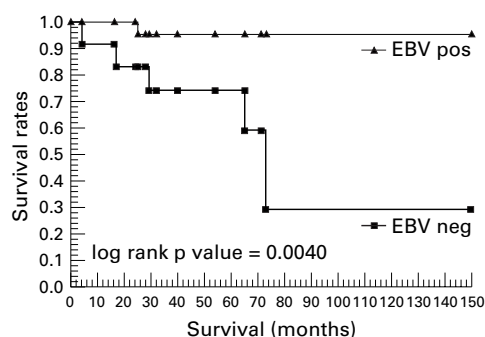


Figure 1 Survival rates in South African children with Hodgkin's lymphoma according to Epstein-Barr virus (EBV) status.

Discussion

There have been contrasting epidemiological results with respect to the incidence of EBV and its association with Hodgkin's lymphoma subtypes in different parts of the world.^{10 24 35} In addition, studies have reported variations in the prevalence of EBV associated Hodgkin's lymphoma occurring in populations with different ethnic, geographical, and socioeconomic backgrounds.^{9 14} For example, Peh *et al* reported a predilection among Indians to develop Hodgkin's lymphoma in comparison with non-Indians in Malaysia.¹⁵ South Africans vary considerably in their race, socioeconomic status, access to health care, and nutritional status. We undertook this study to investigate the interplay of some of these factors in an attempt to understand the role of EBV in South African children with Hodgkin's lymphoma and to determine correlation, if any, with clinicopathological features.

Compared with previously published data, our results followed no single pattern found in either the industrialised or the non-industrialised countries.³⁶ In our study, the spread of Hodgkin's lymphoma among the race groups largely reflected the institution's (Western Cape) population, (black 21%, mixed race 54%, white 21%. Source: Statistics South Africa, 1996 census). The age distribution of Hodgkin's lymphoma, with its peak around eight years of age and the male predilection of 4.2:1, is in agreement with studies conducted in developing countries.^{9 16 37} NS was the predominant histological subtype. In contrast to the distribution of Hodgkin's lymphoma subtypes in children from developing countries, our results follow the pattern found in the USA and Europe more closely, although with not as high a frequency.²⁴

EBV has been implicated in the neoplastic process. The virus has been shown to be monoclonal in this disease and its presence has been observed in EBV positive Hodgkin's lymphoma patients throughout the course of the disease.^{4 21 28} Strong expression of LMP1 has also been observed in all neoplastic cells.^{4 8 28} The LMP1 molecule mimics members of the tumour necrosis factor (TNF) receptor family which are embedded in the cell membranes of human cells, with one end of the molecule facing the extracellular and the other the intracellular aspect of the cell. The cytoplasmic tail interacts with intracellular TNF receptor associated factors, thereby activating nuclear factor- κ B transcription factor, which in turn promotes cell proliferation.^{38 39}

In our study, the demonstration of LMP1 and/or EBERs in HRS cells was regarded as indicating EBV infection. The overall EBV positivity was 68% in our Hodgkin's lymphoma cases, which is lower than the incidence reported in children from developing countries,^{9 23} but higher than from developed countries.¹² Infection among the white population was notably lower, similar to the infectivity rate in the Western world.^{9 34 35} Concerning Hodgkin's lymphoma subtype, a high degree of positivity was observed within the MC subtype, consistent with findings previously

reported in other paediatric studies.^{13 14 16 19 34 40}

Unfortunately, our small numbers for the MC subtype and for female patients did not allow meaningful statistical analysis. The correlation of EBV with the age of occurrence of Hodgkin's lymphoma in South African children supports the hypothesis of an aetiological role for EBV in the development of Hodgkin's lymphoma. Given that South Africa has a unique blend of developed and developing living standards, the intermediate nature of our results—characteristic of neither industrialised nor non-industrialised countries—is not too unexpected. Data have previously been reported showing a high prevalence of EBV sequences in Hodgkin's lymphoma patients from a predominantly low socioeconomic level, a factor which predisposes to viral infection.⁴¹ Our results support the view that an association of EBV with childhood Hodgkin's lymphoma may vary as a function of histological subtype, geography, ethnic background, and socioeconomic status. Geographical or ethnically determined variations in other EBV associated malignancies are well known features.⁴²

Purely paediatric studies including clinical data are uncommon. In this series, 11 patients were lost to follow up. The roughly even distribution of EBV positive and EBV negative cases between early and late stages mitigates against bias due to late stage. It is known that EBV is more often associated with the MC subtype,²³ whereas clinical correlations with EBV status show conflicting results with regard to severity of disease and outcome.^{25 43} Our results show that EBV appears to be associated with a more favourable course and outcome of Hodgkin's lymphoma, with significantly fewer EBV positive patients having "B" symptoms or dying of the disease. Furthermore, although there was no difference in the median relapse-free survival, the median survival was significantly longer in the EBV positive cases. Thus our results are in agreement with those of Morente *et al*, who found that EBV-LMP1 was an indicator of favourable prognosis in Hodgkin's lymphoma patients.³⁰

HRS cells in EBV positive Hodgkin's lymphoma cases express significantly higher levels of major histocompatibility complex (MHC) class I heavy and light chain molecules, accompanied by infiltration with larger numbers of activated cytotoxic T lymphocytes. It is not understood why, despite this increase, the immune system cannot effectively remove the HRS LMP1 expressing cells. One suggestion is local inhibition of cytotoxic T lymphocyte function by the HRS cells themselves or by reactive cells in the vicinity of the HRS cells.²⁷ Children in Africa are continuously exposed from an early age to a wide spectrum of infectious agents and thus patients with EBV positive Hodgkin's lymphoma could have a more efficient immune response. Our results may indicate that recognition of the presence of EBV may play a role in the ability of the immune system to limit progression of the disease. This could explain why the EBV negative patients in our study fared worse. Our findings are analogous to those in a recent study assess-

ing the risk of relapse in 106 patients with early stage invasive cervical carcinoma, where an association was found between poor prognosis and absence of human papilloma virus DNA.⁴⁴ The correlation of the clinical outcome with EBV status in our study provides another dimension in the hypothesis that EBV negative Hodgkin's lymphoma may be a biologically distinct disease from EBV positive Hodgkin's lymphoma.

Our grateful thanks to Mrs Francesca Little MSc, Department of Statistical Sciences, University of Cape Town, for valued assistance with the statistical analysis and to Professor Howard Henderson PhD, Department of Chemical Pathology, University of Cape Town, for his critical evaluation of the manuscript. The study was supported by the National Cancer Association of South Africa.

- 1 Lange BB, Arbeter A, Hewitson J. Longitudinal study of Epstein-Barr virus antibody titres and excretion in pediatric patients with Hodgkin's disease. *Int J Cancer* 1978;22:521-7.
- 2 Weiss LM, Strickler JG, Warnke RA, *et al*. Epstein-Barr viral DNA in tissues of Hodgkin's disease. *Am J Pathol* 1987;129:86-91.
- 3 Weiss LM, Movahed LA, Warnke RA, *et al*. Detection of Epstein-Barr viral genomes in Reed-Sternberg cells of Hodgkin's disease. *N Engl J Med* 1989;320:502-6.
- 4 Anagnostopoulos I, Herbst H, Niedobitek G, *et al*. Demonstration of monoclonal Epstein-Barr virus genomes in Hodgkin's disease and Ki-1-positive anaplastic large cell lymphoma by combined Southern blot and in situ hybridization. *Blood* 1989;74:810-16.
- 5 Vasef MA, Kamel OW, Chen YY, *et al*. Detection of Epstein-Barr virus in multiple sites involved by Hodgkin's disease. *Am J Pathol* 1995;147:1408-15.
- 6 Brousset P, Schlaifer D, Meggetto F, *et al*. Persistence of the same viral strain in early and late relapses of Epstein-Barr virus-associated Hodgkin's disease. *Blood* 1994;84:2447-51.
- 7 Wang D, Liebowitz D, Kieff E. An Epstein-Barr virus membrane protein expressed in immortalised lymphocytes transforms established rodent cells. *Cell* 1985;43:831-40.
- 8 Pallesen G, Hamilton-Dutoit SJ, Rowe M, *et al*. Expression of Epstein-Barr virus latent gene products in tumour cells of Hodgkin's disease. *Lancet* 1991;337:320-2.
- 9 Ambinder RF, Browning PJ, Lorenzana I, *et al*. Epstein-Barr virus and childhood Hodgkin's disease in Honduras and the United States. *Blood* 1993;81:462-7.
- 10 Glaser SL, Lin RJ, Stewart SL, *et al*. Epstein-Barr virus-associated Hodgkin's disease: epidemiologic characteristics in international data. *Int J Cancer* 1997;70:375-82.
- 11 Zhou X, Hamilton-Dutoit S, Yan Q, *et al*. The association between Epstein-Barr virus and Chinese Hodgkin's disease. *Int J Cancer* 1993;55:359-63.
- 12 Armstrong AA, Alexander FE, Pinto Paes R, *et al*. Association of Epstein-Barr virus with pediatric Hodgkin's disease. *Am J Pathol* 1993;142:1683-8.
- 13 Zarate-Osorno A, Roman L, Kingma D, *et al*. Hodgkin's disease in Mexico: prevalence of Epstein-Barr sequences and correlation with histologic subtype. *Cancer* 1995;75:1360-6.
- 14 Chang KL, Albuja PF, Chen Y, *et al*. High prevalence of Epstein-Barr virus in the Reed-Sternberg cells of Hodgkin's disease occurring in Peru. *Blood* 1993;81:496-501.
- 15 Peh SC, Looi LM, Pallesen G. Epstein-Barr virus (EBV) and Hodgkin's disease in a multi-ethnic population in Malaysia. *Histopathology* 1997;30:227-33.
- 16 Preciado MV, De Matteo E, Diez B, *et al*. Epstein-Barr virus (EBV) latent membrane protein (LMP) in tumor cells of Hodgkin's disease in pediatric patients. *Med Pediatr Oncol* 1995;24:1-5.
- 17 Andriko JA, Aguilera NS, Nandedkar MA, *et al*. Childhood Hodgkin's disease in the United States: an analysis of histologic subtypes and association with Epstein-Barr virus. *Mod Pathol* 1997;10:366-71.
- 18 Libetta CM, Pringle JH, Angel CA, *et al*. Demonstration of Epstein-Barr viral DNA in formalin-fixed, paraffin-embedded samples of Hodgkin's disease. *J Pathol* 1990;161:255-60.
- 19 Weinreb M, Day PJR, Murray PG, *et al*. Epstein-Barr virus (EBV) and Hodgkin's disease in Children: incidence of EBV latent membrane protein in malignant cells. *J Pathol* 1992;168:365-9.
- 20 Trovato R, Di Lollo S, Calzolari A, *et al*. Detection of human herpesvirus-6 and Epstein-Barr virus genome in childhood Hodgkin's disease. *Pathologica* 1994;86:500-3.
- 21 Jarret RF, Gallagher A, Jones DB, *et al*. Detection of Epstein-Barr virus genomes in Hodgkin's disease: relation to age. *J Clin Pathol* 1991;44:844-8.
- 22 Pallesen G, Hamilton-Dutoit SJ, Zhou X. The association of Epstein-Barr virus (EBV) with T-cell lymphoproliferations and Hodgkin's disease: two new developments in the EBV field. *Adv Cancer Res* 1993;62:179-239.
- 23 Khan G, Norton AJ, Slavin G. Epstein-Barr virus in Hodgkin disease. Relation to age and subtype. *Cancer* 1993;71:3124-9.

- 24 Colby T, Happe R, Warnke R. Hodgkin's disease: a clinicopathologic study of 659 cases. *Cancer* 1982;**99**:1848-58.
- 25 Vestlev PM, Pallesen G, Sandvej K, et al. Prognosis of Hodgkin's disease is not influenced by Epstein-Barr virus latent membrane protein. *Int J Cancer* 1992;**50**:670-1.
- 26 Oudejans JJ, Jiwa NM, Meijer CJLM. Epstein-Barr virus in Hodgkin's disease: more than just an innocent bystander. *J Pathol* 1997;**181**:353-6.
- 27 Oudejans JJ, Jiwa NM, Kummer JA, et al. Analysis of major histocompatibility complex class I expression on Reed-Sternberg cells in relation to the cytotoxic T-cell response in Epstein-Barr virus-positive and -negative Hodgkin's disease. *Blood* 1996;**87**:3844-51.
- 28 Weinreb M, Day PJR, Niggli F, et al. The consistent association between Epstein-Barr virus and Hodgkin's disease in children in Kenya. *Blood* 1996;**87**:3828-36.
- 29 Knecht H, Bachmann E, Brousset P, et al. Deletions within the LMP1 oncogene of Epstein-Barr virus are clustered in Hodgkin's disease and identical to those observed in nasopharyngeal carcinoma. *Blood* 1993;**82**:2937-42.
- 30 Morente MM, Piris MA, Abaira V, et al. Adverse clinical outcome in Hodgkin's disease is associated with loss of retinoblastoma protein expression, high Ki67 proliferation index, and absence of Epstein-Barr virus-latent membrane protein 1 expression. *Blood* 1997;**90**:2429-36.
- 31 Cuevas EC, Bateman AC, Wilkins BS, et al. Microwave antigen retrieval in immunocytochemistry: a study of 80 antibodies. *J Clin Pathol* 1994;**47**:448-52.
- 32 Rowe M, Evans HS, Young LS, et al. Monoclonal antibodies to the latent membrane protein of Epstein-Barr virus reveal heterogeneity of the protein and inducible expression in virus-transformed cells. *Gen Virol* 1987;**68**:1575-86.
- 33 Kahn G, Coates PJ, Kangro HO, et al. Epstein-Barr virus (EBV) encoded small RNAs: targets for detection by in situ hybridisation with oligonucleotide probes. *J Clin Pathol* 1992;**45**:616-20.
- 34 Hamilton-Dutoit SJ, Pallesen G. Detection of Epstein-Barr Virus small RNAs in routine paraffin sections using non-isotopic RNA/RNA in situ hybridization. *Histopathology* 1994;**25**:101-11.
- 35 Weinreb M, Day P, Niggli F, et al. The role of Epstein-Barr virus in Hodgkin's disease from different geographical areas. *Arch Dis Child* 1996;**74**:27-31.
- 36 Smith-Morris M, ed. *The Economist book of vital world statistics*. New York: Random House, 1990.
- 37 Gutensohn N, Cole P. Epidemiology of Hodgkin's disease in the young. *Int J Cancer* 1977;**19**:595-604.
- 38 Liebowitz D. Epstein-Barr Virus and a cellular signaling pathway in lymphomas from immunosuppressed patients. *N Engl J Med* 1998;**338**:1413-21.
- 39 Mosialos G, Birkenbach M, Yalamanchili R, et al. The Epstein-Barr virus transforming protein LMP1 engages signalling proteins for the tumor necrosis factor receptor family. *Cell* 1995;**80**:389-99.
- 40 Weiss LM, Chen YY, Liu XF, et al. Epstein-Barr virus and Hodgkin's disease: a correlative in situ hybridisation and polymerase chain reaction study. *Am J Pathol* 1991;**139**:1259-65.
- 41 Gutensohn N, Cole P. Childhood social environment and Hodgkin's disease. *N Engl J Med* 1981;**304**:135-41.
- 42 Wright DH. Pathogenesis of non-Hodgkin's lymphomas: clues from geography. In: Magrath IT, ed. *The non-Hodgkin's lymphomas*. Baltimore: Williams and Wilkins, 1990:122-34.
- 43 Fellbaum C, Hansmann ML, Niedermeyer H, et al. Influence of Epstein-Barr virus genomes on patient survival in Hodgkin's disease. *Am J Clin Pathol* 1992;**98**:319-23.
- 44 Riou G, Favre M, Jeannel D, et al. Association between poor prognosis in early-stage invasive cervical carcinomas and non-detection of HPV DNA. *Lancet* 1990;**335**:1171-4.



Improved prognosis of Epstein-Barr virus associated childhood Hodgkin's lymphoma: study of 47 South African cases

M Engel, M F Essop, P Close, et al.

J Clin Pathol 2000 53: 182-186

doi: 10.1136/jcp.53.3.182

Updated information and services can be found at:

<http://jcp.bmj.com/content/53/3/182.full.html>

References

These include:

This article cites 41 articles, 13 of which can be accessed free at:

<http://jcp.bmj.com/content/53/3/182.full.html#ref-list-1>

Article cited in:

<http://jcp.bmj.com/content/53/3/182.full.html#related-urls>

Email alerting service

Receive free email alerts when new articles cite this article. Sign up in the box at the top right corner of the online article.

Topic Collections

Articles on similar topics can be found in the following collections

[Paediatric oncology](#) (99 articles)

Notes

To request permissions go to:

<http://group.bmj.com/group/rights-licensing/permissions>

To order reprints go to:

<http://journals.bmj.com/cgi/reprintform>

To subscribe to BMJ go to:

<http://group.bmj.com/subscribe/>