



Best Practice No 155

Guidelines for handling oesophageal biopsies and resection specimens and their reporting

Nassif B N Ibrahim

Keywords: oesophagus; reporting guidelines

The importance of the role of the histopathologist in the management of patients with oesophageal disease cannot be overemphasised. Pathological examination of specimens from these patients provides:

- Essential diagnostic and prognostic information for optimal clinical management.
- Material for research and audit.
- A database for epidemiological studies.

A close liaison between the surgeon, gastroenterologist, and histopathologist is of paramount importance, particularly in the evaluation of dysplasia or early carcinoma in Barrett's oesophagus and, generally, to maximise diagnostic yield in any situation. The extent and usefulness of pathological information that can be conveyed to the clinicians is determined by the adequacy of clinical information, biopsy sampling, handling, laboratory processing, and any special studies that may be required. It is also influenced by the awareness of the histopathologist of the normal anatomy and histology of the oesophagus. There should be regular meetings between the surgeon, gastroenterologist, and histopathologist to discuss clinical and pathological findings.

Collection and preservation of specimens

The endoscopist should ensure that a separate container is used for biopsies taken from different sites so that the precise location of each biopsy can be identified. Containers should be properly labelled, including the number and site of the biopsy (for example, biopsy No 2 at 33 cm). Interpretation of the biopsy is considerably enhanced if it is taken with a large forceps and oriented¹ (with its mucosal surface, if it is identifiable, upwards on small squares of porous non-soluble paper tissue) and placed immediately in an appropriate fixative (usually buffered 10% formalin or 10% formol saline). Biopsies should then be processed, embedded, and cut correctly oriented, having their luminal surface on one side of the section and the submucosal surface on the other. This is particularly important for the assessment of epithelial dysplasia or stromal invasion. However, small fiberoptic biopsies

and those for malignant disease usually do not require orientation.

The histopathologist should ensure that the clinicians are well aware of the importance of completing the request forms with all the patient's identification data, the endoscopic appearances, and the site of the biopsy. Details of previous biopsies and their laboratory reference numbers should be provided.

It is advisable that all oesophageal resection specimens are sent to the laboratory fresh in a sealed plastic bag placed in a leak proof container. Histopathology departments should ensure that there are appropriate arrangements in place for dealing with specimens arriving outside their normal working hours (this is especially important for taking tissues for research).

Precancerous glandular and squamous epithelial changes

BARRETT'S OESOPHAGUS AND BARRETT'S DYSPLASIA

There is confusion regarding the definition of Barrett's oesophagus. This is partly because of lack of clarity regarding important anatomical landmarks and partly because of disagreement on precise diagnostic criteria.² In this article, the widely but not universally accepted definition of Barrett's as a *columnar lined oesophagus* is used. Within this definition, three epithelial types are recognised³: (1) gastric cardiac type; (2) gastric fundic type; and (3) intestinal metaplasia, sometimes referred to as specialised intestinal metaplasia. The latter is a columnar type of epithelium with goblet cells, identical to gastric intestinal metaplasia of the incomplete type.

Because the squamocolumnar junction is usually irregular and does not always coincide with the anatomical gastro-oesophageal junction, it has been argued by some workers that the distal 2-3 cm of the oesophagus may be lined normally by columnar cardiac or fundic type mucosa, and they reserve the term Barrett's oesophagus only to cases showing "specialised" intestinal metaplasia.^{4 5} The latter is the most important but by no means specific marker for Barrett's oesophagus. It may show a

Department of
Histopathology,
Frenchay Hospital,
Bristol BS16 1LE, UK
N B N Ibrahim

Correspondence to:
Dr Ibrahim
email:
nassif.ibrahim@dial.pipex.com

Accepted for publication
13 September 1999

flat or villous configuration. This goblet cell containing metaplastic columnar epithelium is considered abnormal regardless of its length, and its presence indicates an increased risk of malignancy when it occurs anywhere in the oesophagus.⁴ The diagnostic histological criteria for Barrett's oesophagus in adults are also applied in children, although it should be pointed out that intestinal metaplasia appears to be an age related change, and it is less commonly found in children.⁵

The histopathologist can only definitively identify Barrett's/columnar lined oesophagus in an oesophageal biopsy when columnar mucosal epithelium is seen overlying submucosal oesophageal glands or gland ducts opening onto the surface epithelium. Otherwise, the findings should be regarded as consistent with Barrett's oesophagus if the biopsy was taken from a site more than 3 cm proximal to the anatomical gastro-oesophageal junction.

In considering the length of the Barrett's segment,⁶ two types are recognised: *short segment Barrett's oesophagus* (SSBO), a columnar lined mucosa with evidence of intestinal metaplasia extending for less than 3 cm into the distal oesophagus; and *long segment Barrett's oesophagus* (LSBO), a columnar lined mucosa extending for more than 3 cm into the distal oesophagus with or without intestinal metaplasia. However, more recently the term *ultra-short segment Barrett's oesophagus* has been applied to cases in which intestinal metaplasia is confined to the gastro-oesophageal junction (at the cardia). There appears to be a close relation between carditis, intestinal metaplasia of the cardia, and *Helicobacter pylori* infection.^{7,8}

Dysplasia associated with Barrett's oesophagus is defined as unequivocal neoplastic transformation that is distinguishable from reactive and regenerative changes, and is classified histologically according to the guidelines for inflammatory bowel disease described by Riddell *et al.*⁹ Based on the severity of the architectural and cytological changes, dysplasia is graded as follows.

Low grade dysplasia—There is increased nucleus to cytoplasm ratio, nuclear hyperchromasia, and pleomorphism, but the gland/crypt architecture is preserved; the cytological changes are present throughout the crypt and generally the nuclei maintain a basal orientation; mitoses can be seen in the upper half of the crypts and there is loss of mucus secretion. There may also be some crowding and stratification of the nuclei which is confined to the basal half of the cells.

High grade dysplasia—There is severe disruption of the gland/crypt architecture with more severe cytological and nuclear atypia and loss of nuclear polarity, and often there is crowding and stratification of the nuclei that extends into the luminal parts of the cells.

Indefinite—This grading is applied when distinction between neoplastic transformation and regenerative changes cannot be made, or in the presence of active inflammation or in case of misorientation of the biopsy material when only the crypt bases are seen.⁸

Generally, there is good interobserver agreement on the diagnosis of high grade dysplasia/intramucosal carcinoma, but there is significant disagreement on low grade dysplasia, which reflects the difficulty of differentiating dysplasia from reparative epithelial changes associated with active inflammation or ulceration.¹⁰

The management of patients with Barrett's oesophagus associated with high grade dysplasia is somewhat controversial. Some have recommended early surgical resection,¹¹ while others advocate repeated endoscopic surveillance with biopsies.¹² Those who advocate early surgery point out that when endoscopic biopsies show high grade dysplasia, approximately 50% of resected specimens show evidence of invasive carcinoma.¹² It is recommended that high grade dysplasia should be confirmed by immediate re-endoscopy with multiple biopsies, or the diagnosis is agreed upon by two histopathologists experienced in reporting oesophageal biopsies before considering oesophagectomy.¹¹ There are, as yet, no available markers that differentiate, with confidence, high grade dysplasia from carcinoma or predict progression of dysplasia to frank malignancy. The field of molecular biology is rapidly expanding and there are promising research developments in this area^{13,14} which may prove in future to be of practical significance. Currently, however, these cannot be recommended in routine practice. Most published series reported the presence of dysplasia in over 80% of cases of Barrett's oesophagus complicated by carcinoma.¹¹ A five tier classification for the various histological diagnoses associated with Barrett's oesophagus is shown in table 1 and a suggested clinicopathological collaborative plan for the management of Barrett's oesophagus¹² is shown in table 2.

SQUAMOUS DYSPLASIA AND IN SITU MALIGNANCY
Neoplastic transformation in the oesophageal squamous epithelium, which should be distinguished from reactive and regenerative changes, can be classified as follows.^{15,16}

Mild dysplasia—Cytological and nuclear atypia confined to the lower third of the epithelium.

Table 1 Histological findings in endoscopic biopsies from Barrett's oesophagus

1. Negative for dysplasia
2. Indefinite/low grade dysplasia
3. High grade dysplasia/in situ adenocarcinoma
4. Intramucosal adenocarcinoma*
5. Adenocarcinoma extending into the submucosa

*Intramucosal adenocarcinoma denotes unequivocal breach of the gland basement membrane but not the muscularis mucosae.

Table 2 Suggested clinico-pathological collaborative plan for the management of Barrett's oesophagus

1. *Negative for dysplasia*: yearly endoscopic surveillance
2. *Indefinite/low grade dysplasia*: repeat biopsy in 3–6 months until two consecutive negative biopsies or until dysplasia progresses
3. *High grade dysplasia*: confirm by immediate rebiopsy or the diagnosis is confirmed by another experienced pathologist; oesophagectomy may be considered

Moderate dysplasia—Cytological and nuclear atypia confined to the lower two thirds of the epithelium.

Severe dysplasia—Cytological and nuclear atypia involves almost the full thickness of the epithelium.

Carcinoma in situ—The full thickness of the epithelium is abnormal, being composed of neoplastic cells.

Gross examination and laboratory investigation

BIOPSY SPECIMENS

- The number of biopsies in each container should be documented. Biopsies must be handled with care to avoid crush artefacts.
- Biopsies should be step sectioned at three different levels and stained routinely with haematoxylin and eosin. The unstained intervening sections should be kept for any special stains that might be required later.

SURGICAL RESECTION SPECIMENS

Fresh specimens should be carefully examined, and the outer (circumferential) resection margin painted with Indian ink or other marking dye. This is important for the assessment of completeness of excision and measurement of distance of tumour from the circumferential resection margin.¹⁷ The specimen should then be opened longitudinally, pinned to a cork board, and fixed by immersion in a fixative (usually buffered 10% formalin or 10% formol saline) for 48–72 hours to ensure adequate fixation and facilitate obtaining thin slices. It should be noted that after resection the oesophagus undergoes shrinkage, which affects the upper more than the lower margin, with tumour tissue changing little in length. Even if the oesophagus is immediately pinned and fixed after resection it shrinks by more than 10%, and if pinning and fixation are delayed it shrinks by more than 50%, which accounts for the discrepancy between surgeons' and histopathologists' measurements.¹⁸

After fixation, it is advisable to have a photograph or diagrammatic representation of the specimen made to illustrate pathological findings and indicate sites of blocks selected for histological examination.

The gross description should include:

- (1) The length and maximum diameter of the oesophagus, and for oesophago-gastrectomy specimens, the length of the gastric segment along both the lesser and greater curve.
- (2) The presence of any abnormalities such as achalasia, cysts, webs, rings, diverticula, strictures, or ulcers, and these should be described, measured, and sampled adequately.
- (3) In tumour containing specimens: the presence or absence of Barrett's mucosa or any other area of background mucosal abnormality should be accurately described, measured, and adequately sampled.
- (4) The gross appearance of the tumour (polypoid, fungating, flat, ulcerated), as well as its length and width.
- (5) Site of tumour and its relation to the gastro-oesophageal junction.
- (6) Distance of the tumour from the proximal and, in oesophagectomy specimens, distal surgical lines of excision.
- (7) Extent of invasion of the oesophageal wall.
- (8) Relation of the tumour to the overlying serosa/outer fibrofatty tissue.
- (9) Lymph nodes which are clearly replaced by tumour should be sampled. All other lymph nodes should be completely embedded.
- (10) Tumour should be adequately sampled; this is important for the assessment of various prognostic features and for the evaluation of tumour heterogeneity. It is recommended that the whole tumour is serially sectioned with a sharp knife. First, the bulk of the tumour should be sectioned transversely, to allow assessment of the circumferential resection margin, then the proximal and distal parts sectioned longitudinally, to allow demonstration of the junction between tumour and adjacent non-neoplastic mucosa (fig 1, A, B and C). Sections should be laid flat and examined to assess maximum tumour infiltration. Photographs may be taken at this stage as a permanent record. As a minimum, four blocks should be taken from the tumour, two to include maximum circumferential infiltration and two to include tumour and adjacent non-neoplastic mucosa; one proximally and the other distally. One transverse section should be taken from the oesophagus above the tumour and, depending on tumour site, one distal to the tumour (mainly to demonstrate sub-mucosal vascular invasion). Sections should also be taken to include the proximal and distal resection margins, and if applicable, the gastro-oesophageal junction/presumed junction. Abnormal background mucosa should be adequately sampled.

If no obvious tumour is seen on macroscopic examination of oesophagectomy specimens carried out following a diagnosis of in situ squamous carcinoma or high grade dysplasia/carcinoma in Barrett's mucosa, the entire segment of oesophagus lined by abnormal mucosa should be serially sectioned in longitudinal bands²⁰ (fig 1D). Before sectioning the specimen, the demonstration of squamous dysplasia/in situ squamous carcinoma may be facilitated by the application of Lugol's solution to the oesophageal mucosa, at a concentration of 1% for one to two minutes and observing the colour change¹⁶ (normal squamous epithelium stains dark brown while severe dysplasia/in situ carcinoma shows no colour change). Representative blocks of tissue (individually numbered and their sites marked on the specimen photograph or diagram), 25 mm in length and 3–4 mm width (painted along their proximal margin with Indian ink or other marking dye), should be taken for histology. If these fail to show malignancy, further blocks should be taken. As multifocal disease is often

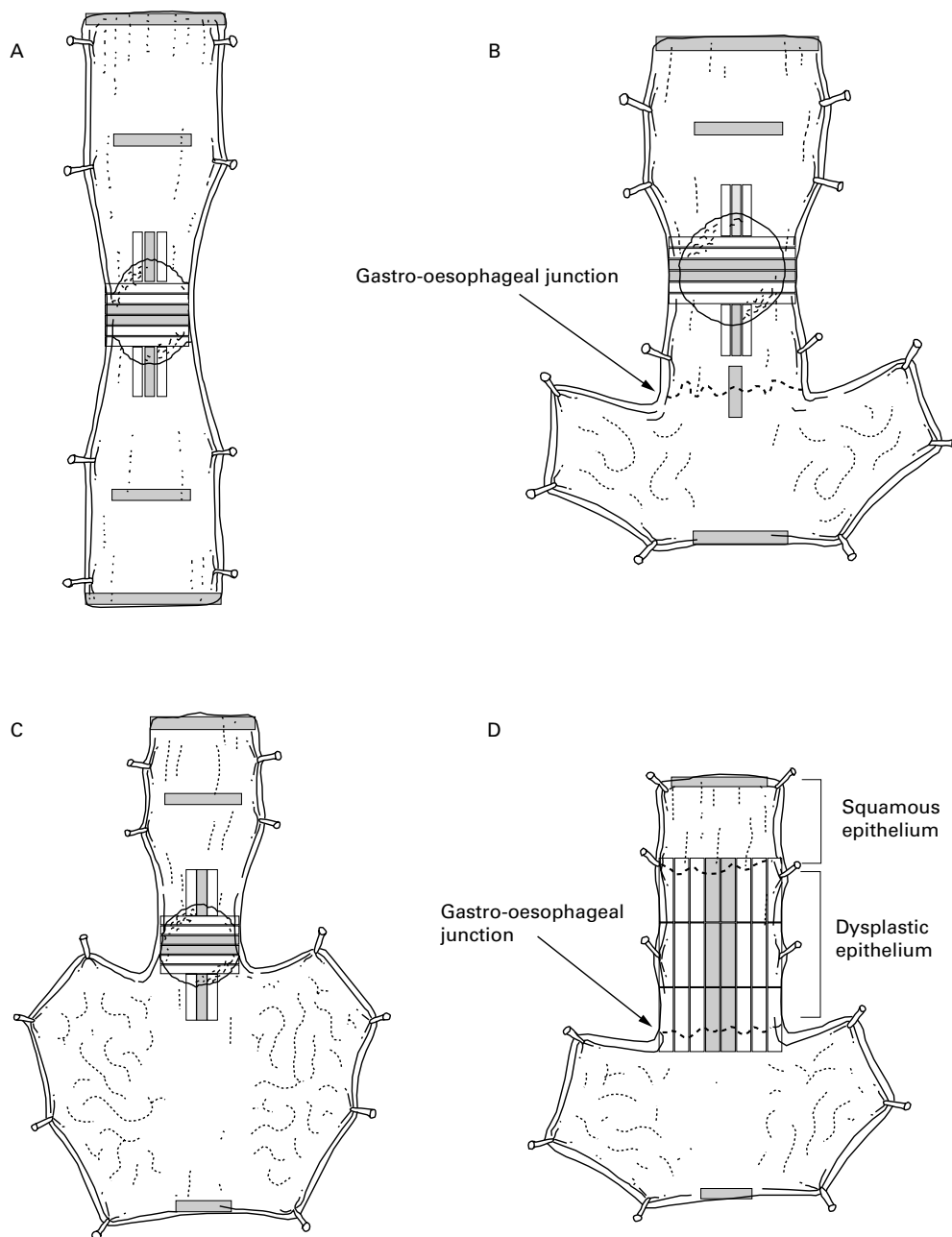


Figure 1 Recommended blocks for histology in resected oesophageal neoplasms. (A) Oesophagectomy specimen. (B) Oesophago-gastrectomy specimen containing tumour above the gastro-oesophageal junction. (C) Oesophago-gastrectomy specimen containing tumour at the gastro-oesophageal junction. (D) Resected specimen for high grade dysplasia/in situ carcinoma. Shaded blocks represent the recommended minimum number to be sampled (see text). (A) and (C) adapted from Ackerman's surgical pathology.¹⁹

seen in early/superficial squamous cell carcinomas,²⁰ these specimens should be thoroughly sampled.

HISTOLOGY

Non-neoplastic diseases

Haematoxylin and eosin (H&E) sections are often sufficient to establish the diagnosis. However, in biopsies of columnar type mucosa sections should be stained with periodic-acid-Schiff (PAS) and alcian blue at pH 2.5 as an aid for the recognition of intestinal metaplasia in Barrett's oesophagus. The columnar cells in Barrett's epithelium differ from normal gastric surface cells in that they contain alcian blue positive mucus but stain less intensely than

goblet cells. In rare cases where there is a suggestion of infective oesophagitis, particularly in immunocompromised patients, a search for viral inclusions and stains for acid fast bacilli and fungi should be carried out, and these may be supplemented by immunohistochemical techniques.

Neoplastic diseases

In oesophageal malignancy, the histopathology report should incorporate all data that are regarded as having prognostic significance. Residual disease at surgery, depth of invasion, and lymph node status are the most important, *independent* prognostic indicators, while other histopathological variables such as tumour his-

tological type, tumour grade, vascular invasion, and even the status of microscopic resection margin, appear to lose their prognostic significance in multivariate analysis.²¹⁻²⁴ However, it is recommended that detailed histopathological data (see below) should be recorded, as they may prove useful in predicting response to future therapeutic regimens and for epidemiological studies.

H&E sections are often sufficient to establish the diagnosis. Nevertheless, histochemical techniques (such as mucin stains, Grimelius technique, and so on) and immunohistochemical methods such as neuroendocrine markers (for example, NSE, PGP9.5, and chromogranin) can be useful in establishing the precise tumour type. Techniques such as DNA studies cannot yet be recommended for routine use.

The histopathology report should incorporate:

- (1) *Tumour type*—Tumours should be classified according to a widely used nomenclature such as the WHO classification.²⁵
- (2) *Tumour differentiation*—This should be recorded according to the predominant area as well differentiated, moderately differentiated, or poorly differentiated.
- (3) *Local invasion and the depth of infiltration of the wall*^{21 22 24}—The text of the histopathology report should clearly state whether the tumour is a high grade dysplasia/in situ carcinoma or an invasive malignancy. The depth of invasion (mucosa/muscularis mucosae, submucosa, muscularis propria, serosa/outer fibrofatty tissue, or adjacent structures) should be documented.
- (4) *Background mucosal abnormality*—It has been suggested that the presence of concomitant Barrett's epithelium in distal oesophageal adenocarcinoma improves prognosis.²⁶
- (5) *Vascular/lymphatic invasion*—Studies have shown that vascular (venous/lymphatic) invasion is an important prognostic factor in univariate analysis.^{22 24}
- (6) *Lymph node metastasis and number of lymph nodes involved by tumour*^{21 22 24}—These are among the most important, and *independent* prognostic indicators. The site of lymph nodes involved by tumour (paraoesophageal, gastric lesser curve, gastric greater curve, and others if received separately and identified as to site) may be useful to document, though there is evidence to suggest that this may not be of prognostic significance.²⁴
- (7) *Other histological variables*—Features that may be recorded but appear to be of little independent prognostic significance include: pattern of advancing margin (pushing or infiltrating), lymphocytic reaction, and intramural metastasis.²⁷ Infiltration of perinodal fibrofatty tissue by tumour was suggested to be an important prognostic factor in patients with curative resection for oesophageal carcinoma, but this needs to be supported by further studies.
- (8) *Adequacy of excision*—Carcinoma involving the circumferential, proximal, or distal

resection margins and clearance (in mm) should be documented. The status of resection margins has been shown in univariate analysis to be an important prognostic factor.^{22 28 29} Dysplasia or Barrett's metaplasia at the proximal or distal resection margin should also be documented.

Adenocarcinoma at the gastro-oesophageal junction

The distinction between adenocarcinoma associated with Barrett's oesophagus and adenocarcinoma of the "gastric cardia" secondarily involving the oesophagus is difficult and may be impossible. Current evidence suggests that many carcinomas involving the gastro-oesophageal junction actually arise in Barrett's epithelium. Short segment and ultrashort segment Barrett's mucosa may be completely overrun by the adenocarcinoma at presentation. Adenocarcinoma at the gastro-oesophageal junction can be classified as follows.³⁰

- (1) *Barrett's adenocarcinoma*—If adjacent Barrett's epithelium with dysplasia is seen or if non-dysplastic Barrett's epithelium is present adjacent to an adenocarcinoma where more than 50% of the tumour mass is present in the oesophagus.
- (2) *Gastric adenocarcinoma*—If dysplasia is seen in the gastric epithelium immediately adjacent to the tumour distally or more than 50% of the bulk of the tumour is present in the stomach and is not associated with dysplasia in Barrett's epithelium.
- (3) *Oesophageal adenocarcinoma not otherwise specified*—Where origin from Barrett's epithelium cannot be demonstrated and the tumour lies predominantly in the oesophagus and there is no associated gastric dysplasia. It can be assumed that tumour arose from Barrett's mucosa and has been overgrown by it. In oesophagogastrctomy specimens containing tumours straddling the gastro-oesophageal junction where mucosal landmarks are no longer identifiable, the *anatomical gastro-oesophageal junction* should be used as the landmark. This is best recognised at the site of the "notch" or the peritoneal reflection at the junction of the oesophagus and greater curve.

STAGING OF OESOPHAGEAL CANCER

The TNM (tumour, node, metastasis) staging system is the most important prognostic indicator (table 3).³¹ However, this does not differentiate between tumours confined to the mucosa and those involving the submucosa, a distinction that has been shown to be of considerable prognostic significance. Several studies have demonstrated that oesophageal tumours which are confined to the epithelial lining (in situ carcinomas) are always curable, and invasive tumours that are confined to the mucosa are nearly always curable. However, submucosal oesophageal cancer (unlike its gastric counterpart) has been shown to be a relatively advanced disease which is associated with a significant risk of vascular invasion and

Table 3 TNM clinical classification³¹**T: Primary tumour**

T1	Tumour invades lamina propria or submucosa
T2	Tumour invades muscularis propria
T3	Tumour invades adventitia
T4	Tumour invades adjacent structures

N: Regional lymph nodes

NX	Regional lymph nodes cannot be assessed
N0	No regional lymph node metastasis
N1	Regional lymph node metastasis

M: Distant metastasis

MX	Distant metastasis cannot be assessed
M0	No distant metastasis
M1	Distant metastasis

For tumours of the lower thoracic oesophagus

M1a	Metastasis in coeliac lymph nodes
M1b	Other distant metastasis

For tumours of the upper thoracic oesophagus

M1a	Metastasis in cervical lymph nodes
M1b	Other distant metastasis

For tumours of the mid-thoracic oesophagus

M1a	Not applicable
M1b	Non-regional lymph node or other distant metastasis

pTNM pathological classification

The pT, pN, and pM categories correspond to the T, N, and M categories

lymph node metastasis, particularly in the case of squamous cell carcinoma. Lymph node metastasis has been reported to occur in 30–50% of squamous tumours involving the submucosa, a figure which is similar to advanced carcinoma.²⁴ It is recommended that if the term “superficial carcinoma” is used in histopathology reporting, it should be qualified by the depth of invasion and, if applicable, the lymph node status.

As TNM is the most widely used prognostic indicator, it is recommended that the histopathology report should include a conclusion that incorporates the pTNM staging system (TNM staying with histopathological evaluation). Additionally, the use of a proforma³² for uniformity in reporting, which is important for accurate comparison of results of treatments at different centres, is also recommended.

I wish to thank Dr David Day, Dr Howard Rigby, Professor Neil Shepherd, and Dr Bryan Warren for reading the manuscript and for helpful comments, and Dr Masaki Mori for advice on Lugol's staining.

- Day DW, Dixon MF. *Biopsy pathology of the oesophagus, stomach and duodenum*, 2nd ed. London: Chapman and Hall, 1995:1–8.
- Spechler SJ, Goyal RK. The columnar-lined esophagus, intestinal metaplasia, and Norman Barrett. *Gastroenterology* 1996;110:614–21.
- Paull A, Trier JS, Dalton MD. The histologic spectrum of Barrett's esophagus. *N Engl J Med* 1976;295:476–81.
- Haggitt R. Barrett's esophagus, dysplasia, and adenocarcinoma. *Hum Pathol* 1994;25:982–93.
- Hassal E. Barrett's esophagus: new definitions and approaches in children. *J Paediatr Gastroenterol Nutr* 1993;15:345–64.

- Ifthikar SY, James PD, Steele RJC, et al. Length of Barrett's oesophagus: an important factor in the development of dysplasia and adenocarcinoma. *Gut* 1992;33:1155–8.
- Morales TG, Sampliner RE, Bhattacharyya A. Intestinal metaplasia of the gastric cardia. *Am J Gastroenterol* 1997;92:414–18.
- Shepherd NA, Biddlestone LR. The histopathology and cytopathology of Barrett's oesophagus. *CPD Bull Cell Pathol* 1999;1:39–43.
- Riddell RH, Goldman H, Ranschoff DF, et al. Dysplasia in inflammatory bowel disease: standardized classification with provisional clinical application. *Hum Pathol* 1983;14:931–68.
- Reid BJ, Haggitt RC, Rubin CE, et al. Observer variation in the diagnosis of dysplasia in Barrett's esophagus. *Hum Pathol* 1988;19:166–78.
- Wright TA. High grade dysplasia in Barrett's oesophagus. *Br J Surg* 1997;84:760–6.
- Levine DS, Haggitt RC, Blount PL, et al. An endoscopic biopsy protocol can differentiate high grade dysplasia from early adenocarcinoma in Barrett's esophagus. *Gastroenterology* 1993;105:40–50.
- Castella E, Ariza A, Fernandez-Vasalo A, et al. Expression of CD44H and CD44v3 in normal oesophagus, Barrett mucosa and oesophageal carcinoma. *J Clin Pathol* 1996;49:489–92.
- Polkowski W, Baak JPA, van Lanschot JJB, et al. Clinical decision making in Barrett's oesophagus can be supported by computerized immunoquantitation and morphometry of features associated with proliferation and differentiation. *J Pathol* 1998;184:161–8.
- Enterline H, Thompson J. *Pathology of the esophagus*. New York: Springer-Verlag, 1984:145–63.
- Mori M, Adachi Y, Matsuushimi T, et al. Lugol staining pattern and histology of esophageal lesions. *Am J Gastroenterol* 1993;88:701–5.
- Sagar PM, Johnston D, McMahon MJ, et al. Significance of circumferential resection margin involvement after oesophagectomy for cancer. *Br J Surg* 1993;80:1386–8.
- Siu KF, Cheung HC, Wong J. Shrinkage of the esophagus after resection of carcinoma. *Ann Surg* 1986;203:173–6.
- Rosai J. *Ackerman surgical pathology*, 8th ed. St Louis: CV Mosby, 1996:2646–7.
- Anani PA, Gardiol D, Savary M, et al. An extensive morphological and comparative study of clinically early and obvious squamous cell carcinoma of the esophagus. *Path Res Pract* 1991;187:214–19.
- Lieberman MD, Shriver CD, Bleckner S, et al. Carcinoma of the esophagus. Prognostic significance of the histologic type. *J Thorac Cardiovasc Surg* 1995;109:130–9.
- Paraf F, Flejou JF, Pignon JP, et al. Surgical pathology of adenocarcinoma arising in Barrett's esophagus. Analysis of 67 cases. *Am J Surg Pathol* 1995;19:183–91.
- Patil P, Redkar A, Patel SG, et al. Prognosis of operable squamous cell carcinoma of the esophagus. *Cancer* 1993;72:20–4.
- Ide H, Nakamura T, Kazuhiko H, et al. Esophageal squamous cell carcinoma: pathology and prognosis. *World J Surg* 1994;18:321–30.
- Watanabe H, Jass JR, Sobin LH. *Histological typing of oesophageal and gastric tumours*. World Health Organisation. International histological classification of tumours, 2nd ed. Berlin: Springer-Verlag, 1990.
- Johansson J, Johnsson F, Walther B, et al. Adenocarcinoma in the distal esophagus with and without Barrett esophagus. *Arch Surg* 1996;131:708–13.
- Lam K, Ma LT, Wong J. Measurement of extent of spread of oesophageal squamous carcinoma by serial sectioning. *J Clin Pathol* 1996;49:124–9.
- Gall CA, Rieger NA, Wattoo DA. Positive proximal resection margins after resection for carcinoma of the esophagus and stomach: effect on survival and symptom recurrence. *Aust NZ J Surg* 1996;66:734–7.
- Tsutsui S, Kuwano H, Watanabe M, et al. Resection margin for squamous cell carcinoma of the esophagus. *Ann Surg* 1995;222:193–202.
- Petrus RE, Sivak MV, Rice TW. Barrett's esophagus. A review of the pathologist's role in diagnosis and management. *Pathol Ann* 1991;26:1–32.
- Sobin L, Wittekind Ch. eds. *TNM classification of malignant tumours*, 5th ed. New York: Wiley-Liss, 1997:54–8.
- Mapstone N. *Minimum dataset for oesophageal carcinoma histopathology*. London: The Royal College of Pathologists, November 1998.

Letters

Necropsy organ weights are largely useless

In 1993 the Royal College of Pathologists published *Guidelines for Post Mortem Reports*.¹ The guidelines may well have led to improvements in necropsy practice but were unreferenced and their evidence base was unstated. They have been used as a gold standard for audit of necropsy reports,² and reiterated in an editorial in this journal.³

Most of the guidelines are sensible but I question the recommendation, in adult necropsies, of routine weighing of organs. Excluding the heart, the weighing of which can provide important information (particularly when the ventricles are weighed separately), organ weights are of little or no value.

The apparent weight of an organ depends on dissection technique and on the accuracy of the weighing balance. In common with other branches of pathology, a numerical result should always be accompanied by the normal range, corrected for the patient's sex, age, and body size. I suspect very few of us comply with this basic rule. However, even if we were to provide reproducibly accurate and referenced weights, they would not be of use to our clinical colleagues, who are accustomed to clinical evaluation of organs, supplemented by imaging techniques in which, at most, a single linear measurement of an organ is given. To be of use, our necropsy practice should reflect these assessments.

The purpose of the necropsy report is to communicate the findings of the necropsy to others, be they clinicians, coroners, or others. We should stop this ritualistic, pseudoscientific practice and concentrate on providing a relevant, meaningful service to our colleagues.

T H W BARKER

*Department of Histopathology and Cytopathology,
Norfolk and Norwich Hospital, Brunstwick Road,
Norwich, Norfolk*

- 1 The Royal College of Pathologists. *Guidelines for post mortem reports*. London: RCPATH, 1993.
- 2 Williams JO, Goddard MJ, Gresham GA, et al. Audit of necropsy reporting in East Anglia. *J Clin Pathol* 1997;50:691-4.
- 3 Start RD, Cross SS. Practice guidelines for necropsy: time for action. *J Clin Pathol* 1996;49:867-9.

We obtained the following comments on this letter:

From Dr R D Start

Dr Barker is correct in his statement that the Royal College of Pathologists' publication *Guidelines for Post Mortem Reports* has led to improvements in necropsy reporting.¹ This is clearly evident within recent reports of the National Confidential Enquiry into Perioperative Deaths (NCEPOD).² The necropsy report guidelines currently provide the only national audit standard for the quality of necropsy reports and I would agree that an appropriate evidence base is desirable. This was one reason behind my suggestion for national practice guidelines for necropsy.³

I am surprised that the routine weighing of organs is in question. Normal organ weight

ranges, corrected for patient sex, age, and body size, are available and can be used if necessary. Some variation may occur with dissection technique but this would be consistent for individual pathologists and could be addressed in any national practice guidelines. Facilities for weighing bodies and organs are fundamental requirements for any mortuary and accuracy is simple to achieve. The suggestion that we stop this "ritualistic, pseudoscientific practice" in order to communicate relevant findings to our colleagues by way of other variables such as a single linear organ measurement is illogical and unacceptable. Linear measurements of focal abnormalities complement gross necropsy findings and allow comparative audit of modern imaging techniques, many of which now give measurements in three dimensions. Supplementary information can also be provided by the dissection of organs in the planes of examination typically seen in modern imaging techniques.

Most clinicians, coroners, and (possibly more importantly) relatives are able to comprehend the concept that organs are abnormal when organ weights are put in the context of normal ranges, particularly if the organ is several times the average normal weight for an individual of similar size, sex, and weight. Although I am unable to provide a specific evidence base to support the use of organ weights, the reasoning behind not providing them is difficult to comprehend, particularly when the most recent major regional audit of necropsy reporting in East Anglia (including Norwich?) found "all pathologists agreed the value of routine weighing of heart, lungs and brain."⁴ I hesitate to suggest that organ weights may be an indirect measure of necropsy quality because through personal experience I have found not only that high quality necropsy reports can be generated from appalling necropsies but also that seemingly accurate organ weights can be determined without removal from cadavers.

More questionable than organ weight measurement is the reported desirability of histological examination in all necropsy cases. There is an increasingly vocal body of opinion within the profession which disagrees with this requirement and the same audit of necropsy reporting in East Anglia provided useful data in relation to the sensible use of histology in necropsy practice.⁵ Such evidence must be incorporated into any future national guidelines for necropsy practice in order that the guidelines reflect the views of most practising pathologists, rather than those of a few interested individuals who perform few, if any, necropsies.

Our principal aim should not be for more necropsies but for better quality necropsies, which are fully supported by a system of formal quality assurance. The Royal College of Pathologists has a major part to play in this process and in recent years has overlooked the necropsy in favour of diagnostic histopathology and cytopathology. The intermittent production of necropsy related guidelines has been useful but a complete reappraisal of all necropsy related matters is urgently required at a national level. Other countries have already addressed these issues⁶ and this is presumably one reason for the commissioning of a Royal College of Pathologists Working Party to examine the current status of necropsy in the United Kingdom.

R D START

*Pathology Directorate, Royal Hospital, Calow,
Chesterfield, Derbyshire*

- 1 The Royal College of Pathologists. *Guidelines for post mortem reports*. London: RCPATH, 1993.
- 2 The Royal College of Surgeons of London. *National enquiry into perioperative deaths (NCEPOD)*. London: RCS, 1998.
- 3 Start RD, Cross SS. Practice guidelines for necropsy: time for action. *J Clin Pathol* 1996;49:867-9.
- 4 Williams JO, Goddard MJ, Gresham GA, et al. Audit of necropsy reporting in East Anglia. *J Clin Pathol* 1997;50:691-4.
- 5 Williams JO, Goddard MJ, Gresham GA, et al. The use of histopathology in the practice of necropsy. *J Clin Pathol* 1997;50:695-8.
- 6 Hutchins GM, Glenn GC. Practice guidelines for autopsy pathology. *Arch Pathol Lab Med* 1994;118:19-25.

From Dr M J Goddard

In our paper,¹ we included the measurements of major organ weights (heart, lungs, brain, liver, and kidneys) as one of the audit criteria. We do not consider this a gold standard but set this audit standard on the basis of the guidelines of the Royal College of Pathologists, together with a consensus view of the pathologists whose reports were used in the audit.

It is interesting to note that in the audit, this was the area of the internal examination which was done least well, with only 73% of reports recording all five weights in the initial audit, improving to 84% at the time of re-audit. This could be taken to suggest that at least a proportion of pathologists are unwilling to record data that they perceive as meaningless.

As one of the pathologists who reviewed the necropsy reports at the time of the audit, I would have to say that there were very few if any instances where the weight of the organ other than the heart contributed to the quality of the report. I would have to agree that from my own personal viewpoint, together with my impressions gleaned from the audit, the routine weighing of organs serves no useful purpose, provides no information to clinical colleagues, and should cease.

M J GODDARD

*Department of Histopathology, Papworth Hospital,
Cambridge University Teaching Hospitals Trust,
Papworth Everard, Cambridge*

- 1 Williams JO, Goddard MJ, Gresham GA, et al. Audit of necropsy reporting in East Anglia. *J Clin Pathol* 1997;50:691-4.

Book reviews

The Science of Laboratory Diagnosis. Edited by J Crocker and D Bumett. (£59.95.) Isis Medical Media, 1998. ISBN 1899066 62 4.

The editors have done a marvellous job, more than fulfilling their stated aim of producing a volume describing the multidisciplinary state of modern pathology which will be of interest to a wide range of readers. The book is beautifully produced with excellent colour photographs and line diagrams which clearly explain the practicalities described in the text. I was particularly

impressed by the many tables and flow charts, which can be used as aids to decision making.

All aspects of pathology are covered and it is very easy to find the specific information one needs; the first page of each chapter has its own index, there are summaries of topics at the top of each page, and the general index is detailed and comprehensive. Each subject is clearly introduced with relevant background information. Practical details are easy to follow and alternative methods discussed. Attention is paid to the interpretation of results and to the use of quality controls. At the end of each chapter future directions are covered and there is a useful further reading list. The unifying theme to the book is the application of similar methods to different disciplines. Microscopy and molecular techniques are referred to frequently and it is obvious that a common language is developing between pathologists. This welcome situation will be helped considerably by this work, which should be on the bookshelf of every laboratory. The availability of a version on CD-ROM will increase its appeal.

D M BARNES

Oxford Handbook of Clinical Immunology. By G Spickett. (£19.95.) Oxford University Press, 1999. ISBN: 0 19 262721 X.

Immunologists may well wonder whether there is any need for another volume to complement the many excellent texts that already exist on clinical immunology. Gavin Spickett explains why he wrote the book, saying it was for selfish reasons in that the book that he would like to have had was not available when he was a trainee. Therefore the volume has to be assessed from two points of view: first, does it fill a need in the market, and second, does it meet Dr Spickett's own requirements?

In my opinion the answer to both questions is yes. The volume is up to date, comprehensive, and easily referenced. The text includes information on both clinical and laboratory

immunology and has useful appendices on quality and managerial issues which laboratory trainees will find particularly valuable. Skipping through the volume, I find it is generally very up to date, for example the section on X linked lymphoproliferative disease identifies the cloned gene, information about which was only published in *Nature* in October 1998.

In a volume such as this, one's attention tends to get drawn to areas of one's own particular interest and not surprisingly not all contributions are similarly up to date. I found it surprising that the section on HIV infection did not mention combination antiretroviral therapy, particularly protease inhibitor therapy, or viral load testing in any detail, and also indicated that there was no value in sequential monitoring of CD4 counts once they had fallen below 0.05—information that is clearly incorrect following the advent of new treatments.

However, such criticisms are minor in what is otherwise an excellent volume, and I applaud Dr Spickett's omission of fundamental immunology which has little or no place in such a book. I think that immunology trainees will find this volume invaluable, as will most of their trainers, but whether the market will be larger than the 150 or so individuals that this group comprises remains to be seen. I certainly cannot see many SHOs in general medicine carrying this book alongside the many other small slim volumes that currently sit in RMO's pockets, but I may be proved wrong on this too.

GRAHAM BIRD

Correction

Because of an error in the publishing process, Dr Ibrahim's Best Practice article in the February issue (Guidelines for handling oesophageal biopsies and resection speci-

mens and their reporting, vol 53, no 2, pp 89–94) has been numbered 155 instead of 156. Reprints of this article will be numbered correctly, as will references to the article in our in-house Best Practice advert that appears at the end of each issue. We apologise for this error.

Notice

St Mary's Hospital Campus of ICSM, London

Haematology Courses, Spring 2000

1. Two day course in haematology morphology

St Mary's Hospital, 3–4 April 2000
Suitable for consultants and career grade post holders in haematology. Also valuable for trainees in haematology. CME approved (6+7 CME credits)
Cost £140 including light lunch

2. One day course in histopathology of the bone marrow

St Mary's Hospital, 5 April 2000
Suitable for consultants, career grade post holders, and trainees in haematology and histopathology. CME approved (7 CME credits)
Cost £85 including light lunch

Inquiries in writing or by fax only, to:
The Postgraduate Course Organiser
Academic Surgical Unit
10th Floor, QEOM Wing
St Mary's Hospital
London W2 1NY
Fax No +44 (0)171 886 6314.

Instructions for Authors

Papers for publication should be sent to the Editor, *Journal of Clinical Pathology*, BMA House, Tavistock Square, London WC1H 9JR (tel: 020 7383 6209/6154; fax: 020 7383 6668; email: ndavies@bmjgroup.com). Receipt of manuscripts will be acknowledged by the editorial office.

Submission of a paper will be held to imply that it contains original work not being offered elsewhere or published previously. Manuscripts should be prepared in accordance with the Vancouver style.¹ The Editor retains the right to shorten the article or make changes to conform with style and to improve clarity. All authors must sign the electronic licence form after acceptance.

Failure to adhere to any of these instructions may result in delay in processing the manuscript and it may be returned to the authors for correction before being submitted to a referee.

General

- Authors must submit four copies of the original manuscript typed in double line spacing plus covering letter signed by all authors, consenting to publication. Revised manuscripts should be submitted as printed copy and on disk. A guide to submitting an article on disk will be sent when requesting a revision or on notification of an acceptance. Authors should not submit the original paper on disk.
- The names of the authors, with initials, should be followed by the name of the institution where the work was carried out. An indication of the position held by each author should be given in an accompanying letter to the Editor, and manuscripts should bear the name of one author to whom correspondence should be addressed. If available, a fax number and an email address should be supplied.
- Identifying information should not be published in written descriptions, photographs, or pedigrees unless the information is essential for scientific purposes and the patient (or parent or guardian) gives written informed consent for publication; but patient data should never be altered or falsified in an attempt to attain anonymity. Informed consent should be obtained if there is any doubt. Masking the eyes in photographs of patients is inadequate protection of anonymity (for the full statement see the *BMJ*²).
- Authors should include the names and addresses of four experts whom the authors consider suitable to peer review their work.
- When submitting original manuscripts authors should send a copy of any of their other papers on a similar subject to assure the editors that there is no risk of duplicate publication.
- If requested, authors should produce the data upon which the manuscript is based for examination by the Editor.
- The number of authors should be kept to a minimum and should include only those who have made a contribution to the research: justification should be made for more than five authors. Acknowledgments should be limited to workers whose courtesy or assistance has extended beyond their paid work, and to supporting organisations.
- Please inform us of any grant, business interest, or consultancy that could lead to a conflict of interest.
- Authors should provide up to four keywords/phrases for the index.
- All measurements must be in SI units apart from blood pressure measurements, which

should be in mm Hg, and drugs in metric units.

- Abbreviations should be used rarely and should be preceded by the words in full before the first appearance.
- In the statistical analysis of data 95% confidence intervals should be used wherever appropriate.
- Any article may be submitted to outside peer review and for statistical assessment.
- Animal studies will be considered only if the clinical implications are significant.
- Research studies should have stated local ethical committee approval.
- No free offprints will be provided; reprints may be ordered when the proof is returned.

Original articles

- Papers should be no more than 2000 words long and should report original research of relevance to the understanding and practice of clinical pathology. They should be written in the standard form: abstract; introduction; methods; results; and discussion.
- The journal uses a structured form of abstract in the interests of clarity. This should be short (no more than 250 words) and include four headings: *Aims*—the main purpose of the study; *Methods*—what was done, and with what material; *Results*—the most important results illustrated by numerical data with p values or confidence intervals; and *Conclusions*—the implications and relevance of the results.

Leaders/Editorials

- Leaders and Editorials are published by editorial invitation; unsolicited reviews or commentaries are unlikely to be accepted, though the Editor is always pleased to receive suggestions.

Short reports

- Single case reports of outstanding interest or clinical relevance, short technical notes, and brief investigative studies are welcomed and usually published in the form of a Short/Technical report.
- Length must not exceed 1000 words, including a structured abstract of less than 150 words (unstructured for case reports), up to two figures (together occupying half a column of space) or tables (or one of each) and up to 10 references. If more illustrations are required the text must be reduced accordingly.

Letters

- Letters must be typed in double line spacing, should normally be no more than 500 words, have no more than five references, and must be signed by all authors. Two copies should be provided.

Tables and illustrations

Tables should be presented separately in double line spacing without ruled lines; when presented on disk they should be in a separate file from the text.

- Letters and other marks which are to appear on the face of a photomicrograph should be made on a photocopy: they will be added in the Journal style in the editorial office when the manuscript is accepted.
- Legends for illustrations should be typed with double spacing on a separate sheet. The staining technique used should be stated. Magnifications should be given for electron micrographs but not for light micrographs except in cases where this is important.
- Photographs and photomicrographs should be on glossy paper for half tone reproduction. The printing process requires that prints are unmounted and unbacked, and of high quality, with full tonal scale. Illustrations that will not reproduce well will be returned and this may delay

publication. Areas in which tissue does not appear ("background") should be as near white as possible. Three sets of prints must be supplied with each manuscript. Only salient features should be included to preserve detail.

- Colour reproduction of figures in papers is encouraged and is heavily subsidised by the Journal. Advice on costs and material to be submitted for colour work should be sought from the editorial office. The journal can accept colour images as TIFF files in the following media: zipped or unzipped files on floppy disks, compact disks, or optical disks. A hard copy of the image should be provided.
- If any tables or illustrations submitted have been published elsewhere, written consent to republication should be obtained by the author from the copyright holder (usually the publisher) and the authors. A copy of the letter giving consent must be included.

Descriptions of laboratory methods

- When a manufacturer's method is used in a study with a particular item of equipment or kit of reagents, the source of this method and reference to the scientific literature on which it was based should be given.
- For quantitative methods, information on the sensitivity, precision, and accuracy in the hands of the authors should always be provided. When a well recognised method is used, these requirements could be met simply by providing the references to the methodology and discussing the performance in a recognised current quality assurance scheme. Modifications to methods that have not been previously published should be detailed in the text and supported by evidence of their efficacy.
- It is useful to indicate, either from personal observations or by reference, the working range of an assay and the normal reference range. When information is expressed as mean \pm 2SD, the distribution of the range (normal, skew, or logarithmic) should be stated.

References

- References must be numbered in the order they appear in the text and include all information (Vancouver style; references with more than three authors should give only the first three followed by *et al*):
 - 1 Fletcher CDM, McKee H. Sarcomas - a clinicopathological guide with particular reference to cutaneous manifestations. I. Dermatofibrosarcoma protuberans, malignant fibrous histiocytoma and the epithelial sarcoma of Enzinger. *Clin Exp Dermatol* 1984;**9**:451-65.
 - 2 Washington JA. Conventional approaches to blood culture. In: Washington JA, ed. *The detection of septicemia*. West Palm Beach, Florida: CRP Press, 1978:41-87.
- References in the text should be identified by arabic numerals in brackets—for example, [1] [2].
- Information from manuscripts not yet accepted, or personal communications may be cited only in the text and not included in the references. References are not checked by us; authors must verify references against the original documents before submitting the article.
 - 1 International Committee of Medical Journal Editors. Uniform requirements for manuscripts submitted to biomedical journals. *BMJ* 1991;**302**: 338-41.
 - 2 International Committee of Medical Journal Editors. Protection of patients' rights to privacy. *BMJ* 1995;**311**:1272.

Manuscript checklist:

- Is there an abstract?
- Are the abbreviations spelt out?
- Are the measurements in SI units?
- Are the references in Vancouver style?

Revised Mar 2000



Best Practice articles (formerly "Broadsheets") prepared by the Association of Clinical Pathologists

Just published

156 Handling oesophageal biopsies and resection specimens and their reporting 2000 NBN IBRAHIM

Recent Publications

155 Pathological investigation of deaths following surgery, anaesthesia, and medical procedures 1999

RD START, SS CROSS

154 *Helicobacter pylori* 1999 CAM McNULTY, JI WYATT (with correction in June issue)

Other Best Practice articles are still available for purchase

153 The laboratory investigation of vaginal discharge 1998 KF MACSWEEN, GL RIDGWAY

152 Clinical implications of plasma homocysteine measurement in cardiovascular disease 1998

RA STILL, IFW MCDOWELL

151 Investigation of dyslipidaemias 1997 AF WINDER, W RICHMOND, DT VALLANCE

150 Antenatal serological testing and prevention of haemolytic disease of the newborn 1997 JKM DUGUID

149 Serological diagnosis of gluten sensitive enteropathy 1996 DJ UNSWORTH

148 Laboratory diagnosis of malaria 1996 DC WARHURST, JE WILLIAMS

147 Mycological techniques 1996 KG DAVEY, CK CAMPBELL, DW WARNOCK

146 Macroscopic examination of prostatic specimens 1995 P HARNDEN, MC PARKINSON

145 Investigation of patients with autoimmune haemolytic anaemia and provision of blood for transfusion 1995 RJ SOKOL, DJ BOOKER, R STAMPS

Earlier Broadsheets may still be available from the author. A full list can be obtained from the Publications Secretary, Association of Clinical Pathologists, 189 Dyke Road, Hove, East Sussex BN3 1TL.

Prices

INLAND One copy, £2.50; 2-10 copies (of any one broadsheet or reprint), £2.00 each; 11-100 copies (of any one), £1.75 each; 101 plus copies (of any one), price to be agreed; authors (over 50 free copies), £1.25 each.

OVERSEAS One copy, \$6.75; 2-10 copies (of any one broadsheet or reprint), \$5.25; 11-100 copies (of any one), \$3.75; 101 plus copies (of any one), price to be agreed.

Authors \$2.25. Prices include postage but air mail will be charged extra. Trade discount 10%. All orders (and all changes of address of regular subscribers) should be sent to the Publishing Manager • *Journal of Clinical Pathology*, BMJ Publishing Group, BMA House, Tavistock Square, London WC1H 9JR.



ACP Best Practice No. 155. Guidelines for handling oesophageal biopsies and resection specimens and their reporting

Nassif B N Ibrahim

J Clin Pathol 2000 53: 89-94
doi: 10.1136/jcp.53.2.89

Updated information and services can be found at:
<http://jcp.bmj.com/content/53/2/89.full.html>

-
- These include:*
- References** This article cites 23 articles, 5 of which can be accessed free at:
<http://jcp.bmj.com/content/53/2/89.full.html#ref-list-1>
- Article cited in:
<http://jcp.bmj.com/content/53/2/89.full.html#related-urls>
- Email alerting service** Receive free email alerts when new articles cite this article. Sign up in the box at the top right corner of the online article.

-
- Topic Collections** Articles on similar topics can be found in the following collections
- [Clinical diagnostic tests](#) (637 articles)
 - [Oesophageal cancer](#) (44 articles)
 - [Oesophagus](#) (28 articles)
 - [Histopathology](#) (87 articles)

Notes

To request permissions go to:
<http://group.bmj.com/group/rights-licensing/permissions>

To order reprints go to:
<http://journals.bmj.com/cgi/reprintform>

To subscribe to BMJ go to:
<http://group.bmj.com/subscribe/>