

## Short reports

# Histiocytic lymphoma presenting as a testicular tumour and terminating in acute monoblastic leukaemia

D R Hull, H D Alexander, G M Markey, R W Lyness, T C M Morris

### Abstract

**A 58 year old man presented in 1995 with a swollen testicle. After orchidectomy, a diagnosis of poorly differentiated lymphoma was made. Lymphoid, epithelial, and seminoma markers were all negative. Six months later he developed a buccal lesion, which was biopsied and reported as a high grade non-Hodgkin's lymphoma. It responded completely to chemotherapy but within a year he developed a forearm swelling, which was biopsied and imprints made before fixation of the material. Immunocytochemistry on the imprints showed positivity with antibodies to CD4, CD68, and muramidase, and the non-specific esterase cytochemical stain was strongly positive, leading to a diagnosis of true histiocytic lymphoma. Despite further treatment, the patient entered a terminal acute leukaemic phase, the blasts marking as monoblasts. Review of all the biopsies, including molecular investigations and further immunohistochemistry studies performed retrospectively on the original biopsy, demonstrated that this was the same malignant cell line throughout, and we conclude that this is a case of histiocytic lymphoma, initially presenting as a testicular tumour and terminating in acute monoblastic leukaemia. A diagnosis of histiocytic lymphoma should be considered when lymphoid markers are negative in an apparent lymphoma, but should not be made without recourse to appropriate immunophenotypic and molecular studies.**

(*J Clin Pathol* 2000;53:788–790)

Keywords: histiocytic lymphoma; testicular tumour; acute monoblastic leukaemia

For some time, the existence of histiocytic lymphoma as a distinct entity has been disputed. The condition has also been called malignant histiocytosis or monocytic/histiocytic sarcoma, but the term true histiocytic lymphoma persists, albeit without formal consensus. The use of monoclonal antibodies and immunohistochemistry has shown that some cases previously diagnosed as histiocytic lymphoma are in fact large cell B or T cell

non-Hodgkin's lymphomas. However, those cases reported in the literature as true histiocytic lymphoma appear to be associated with aggressive disease and a poor prognosis. We report the case of a patient who presented with a testicular tumour and his immunophenotypic and cytochemical markers led us to a diagnosis of true histiocytic lymphoma.

### Case history

A 58 year old Irish sea fisherman presented in November 1995 with a swollen right testicle. Ultrasound scan suggested a homogenous tumour and orchidectomy was performed. Histological examination showed diffuse interstitial infiltration by sheets of cells with large nuclei and nucleoli and a small rim of cytoplasm. Lymphoid, epithelial, and seminoma markers were all negative. Granulocytic/monocytic markers were not included in the original panel of antibodies. The tumour was reported as a poorly differentiated lymphoma with the outside possibility that it was a leukaemic infiltrate.

On referral to the oncology department, Belfast City Hospital, the patient was constitutionally well. Full blood picture (FBP), differential white cell count (DWCC), and biochemistry results were all normal. The erythrocyte sedimentation rate (ESR) was 1 mm after one hour. Computed tomography (CT) scan of chest, abdomen, and pelvis was normal. No further treatment was indicated.

In April 1996, the patient reported a swollen left cheek of four weeks duration. This was biopsied and reported as a high grade non-Hodgkin's lymphoma. The patient was referred to the department of haematology, Belfast City Hospital, where he was found to be constitutionally well with no peripheral adenopathy. FBP, DWCC, and biochemistry were once again normal as was CT scan of chest, abdomen, and pelvis. A bone marrow aspirate in June 1996 showed no morphological or immunophenotypic evidence of a monoclonal infiltrate, and the trephine biopsy was normal. He was entered in the BNLI trail for stage II–IV histologically aggressive non-Hodgkin's lymphoma and treated with CIOP (cyclophosphamide, 750 mg/m<sup>2</sup> intravenously (iv) day 1; idarubicin, 10 mg/m<sup>2</sup> iv day 1; oncovin, 2 mg iv

Department of  
Haematology, Belfast  
City Hospital, Belfast,  
BT9 7AD, Northern  
Ireland, UK  
D R Hull  
H D Alexander  
G M Markey  
T C M Morris

Department of  
Histopathology, Belfast  
City Hospital  
R W Lyness

Correspondence to:  
Prof Alexander  
[hd.alexander@bch.n-i.nhs.uk](mailto:hd.alexander@bch.n-i.nhs.uk)

Accepted for publication  
20 January 2000

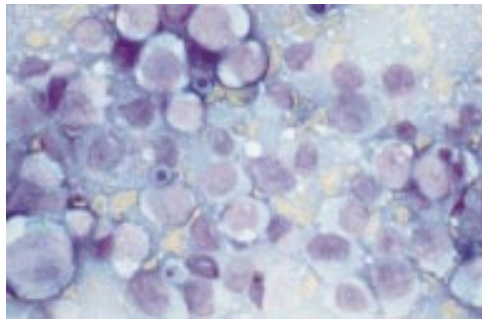


Figure 1 Touch preparation of forearm lesion. Wright's stain showing large mononuclear cells with basophilic vacuolated cytoplasm.

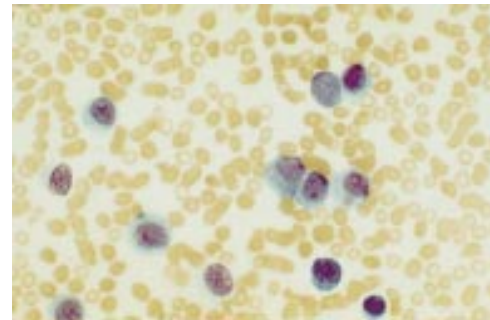


Figure 2 Peripheral blood. Wright's stain showing terminal leukaemic phase.

day 1; prednisolone, 100 mg peroral (po) days 1–5) and intrathecal methotrexate (12.5 mg) for five courses. The cheek lesion regressed completely and all cerebrospinal fluid samples were clear of malignant infiltrate. Treatment was stopped in September 1996.

In February 1997, the patient presented with a painful swelling of his left forearm. This was biopsied and reported as a tumour with sheeted growth pattern infiltrating bone, muscle, and soft tissue. Immunohistochemistry showed equivocal CD3 positivity and the tumour was reported as a high grade T cell non-Hodgkin's lymphoma, with positivity for histiocytic marker CD68. Imprints were made of the tumour tissue before fixation and marker studies carried out on this material by the alkaline phosphatase anti-alkaline phosphatase (APAAP) technique in the department of haematology. Modified Wright's stain showed the tumour cells to be large/very large mononuclear cells with moderately basophilic, vacuolated cytoplasm (fig 1). Reactivity was observed with epithelial, T cell, and B cell antibodies, but was strongest with anti-CD4. A strong positive reaction was obtained with anti-CD68 and moderately strong with anti-muramidase. The cells were Ki67 positive and a non-specific esterase stain (*α* naphthyl acetate esterase; ANAE) was strongly positive, with a diffuse monocyte pattern of staining obtained. The case was reported as "true histiocytic lymphoma". The bone marrow aspirate and trephine showed no clearcut evidence of infiltration. Occasional (1.5%) large mononuclear cells with very basophilic cytoplasm were identified on the aspirate smear and the trephine was reported as normal. Immunohistochemistry subsequently carried out on the original testicular biopsy specimen showed identical reactivity (strong positivity with antibody to CD68 and muramidase) and, in addition, moderately strong positivity with antibody to CD15. Antigen receptor gene rearrangement studies, also carried out by the polymerase chain reaction on the original biopsy sample at this stage, showed no clonal rearrangement of the T cell receptor (TCR) or immunoglobulin heavy chain (IgH) genes.<sup>1</sup>

The patient was unwell with sweating and arm pain. The FBP was normal but lactate dehydrogenase was 6440 U/litre (normal range, 360–720). CT scan showed fatty liver only and the patient was treated with further

CIOP in doses as before, which resulted in some clinical improvement.

In April 1997, there was clinical deterioration with increasing arm pain and swelling, and pyrexia, with heavy sweating. Evidence of coagulopathy was present and the leucocyte count rose rapidly from  $3.8$  to  $76.0 \times 10^9$ /litre in eight days. Peripheral blood examination showed 96% blasts with moderately basophilic, often vacuolated, cytoplasm, and the nuclei had conspicuous nucleoli (fig 2). APAAP staining showed positivity of variable strength with antibodies to CD13, CD33, CD68, and CD14. Cytochemistry showed strong ANAE positivity and it was reported as acute monoblastic leukaemia (FAB M5)/leukaemic phase of histiocytic lymphoma. Cytogenetic studies demonstrated tetrasomy 8, with no evidence of abnormalities that might suggest a secondary, chemotherapy induced, leukaemia. The patient was treated with DHAP (dexamethasone, 40 mg po day 1–4; ARA-C, 2 gm/m<sup>2</sup> bd iv day 1; cisplatin, 100 mg/m<sup>2</sup> day 1) but his condition deteriorated and he died on 3 May 1997.

### Discussion

In our opinion, the patient presented is appropriately classified as true histiocytic non-Hodgkin's lymphoma with a terminal leukaemic phase, and the aggressive course of his disease is in keeping with the concept of this condition as high grade lymphoma. The classification M5c to distinguish the leukaemic phase of malignant histiocytosis from de novo acute monoblastic leukaemia (M5a or M5b) has been proposed.<sup>2</sup> The analogy of our case with granulocytic sarcoma preceding acute myeloid leukaemia is self evident.

This is a rare condition but should be considered when lymphoid markers are negative using immunohistochemistry on formaldehyde fixed tissue. Touch preparations made before fixation are a diagnostically useful material for immunophenotyping using the APAAP technique. Histiocytes express CD4 and may show weak non-specific positivity with other epithelial, T cell, and B cell antibodies. However, typically, the reactivity with antibodies to CD4 and myeloid/monocytic antigens such as CD13, CD33, CD68, and CD14, and the expression of strong non-specific esterase positivity, make the diagnosis relatively straightforward. In formaldehyde fixed tissue, if a possible diagnosis of non-Hodgkin's lymphoma is not confirmed by reactivity with

lymphoid markers, antibodies to myeloid/monocytic antigens should be tested and, if available, molecular studies should be carried out to exclude clonal rearrangements of antigen receptor genes (IgH and TCR). The demonstration of tetrasomy 8 by cytogenetic studies is an uncommon finding, but the few cases reported in the literature have usually been associated with non-lymphoid haematological malignancies.

Re-evaluation of cases, originally diagnosed as true histiocytic lymphoma without recourse to immunophenotypic and molecular studies, when carried out, has always resulted in most cases being reclassified as high grade B or T cell non-Hodgkin's lymphoma.<sup>3</sup> Conversely, occasional cases do prove to be true histiocytic lymphomas.

The presentation of our case as a testicular tumour is interesting, and we suggest that a diagnosis of histiocytic lymphoma should be considered when lymphoid, epithelial, and seminoma markers are negative in such cases.

The authors wish to acknowledge the contributions of Mr M Humphries for cytogenetic studies and Mrs H Foster for the immunohistochemistry.

- 1 Ryan DK, Alexander HD, Morris TCM. Routine diagnosis of large granular lymphocytic leukaemia by Southern blot and polymerase chain reaction analysis of clonal T cell receptor gene rearrangements. *Mol Pathol* 1997;50:77-81.
- 2 Laurennet FM, Chapuis B, Renx-Lombart P. Malignant histiocytosis in the leukaemic stage: a new entry (M5c-AML) in the FAB classification? *Leukemia* 1994;8:502-6.
- 3 Egeler RM, Schmitz L, Sonneveld P, *et al.* Malignant histiocytosis: a reassessment of cases formally classified as histiocytic neoplasms and review of the literature. *Med Pediatr Oncol* 1995;25:1-7.



## Histiocytic lymphoma presenting as a testicular tumour and terminating in acute monoblastic leukaemia

D R Hull, H D Alexander, G M Markey, et al.

*J Clin Pathol* 2000 53: 788-790  
doi: 10.1136/jcp.53.10.788

---

Updated information and services can be found at:  
<http://jcp.bmj.com/content/53/10/788.full.html>

---

*These include:*

### References

This article cites 3 articles, 1 of which can be accessed free at:  
<http://jcp.bmj.com/content/53/10/788.full.html#ref-list-1>

### Email alerting service

Receive free email alerts when new articles cite this article. Sign up in the box at the top right corner of the online article.

---

### Topic Collections

Articles on similar topics can be found in the following collections

[Immunology \(including allergy\)](#) (1279 articles)  
[Urological cancer](#) (117 articles)  
[Clinical diagnostic tests](#) (637 articles)

---

### Notes

---

To request permissions go to:  
<http://group.bmj.com/group/rights-licensing/permissions>

To order reprints go to:  
<http://journals.bmj.com/cgi/reprintform>

To subscribe to BMJ go to:  
<http://group.bmj.com/subscribe/>