

A case of sudden death caused by fibromuscular dysplasia

Department of
Pathology, Kuopio
University Hospital
and University of
Kuopio, FIN-70211
Kuopio, Finland
K M Ropponen

K M Ropponen, I Alafuzoff

Department of
Neurosciences,
University of Kuopio
I Alafuzoff

Correspondence to:
Dr Ropponen.
email:
Kirsi.Ropponen@uku.fi

Accepted for publication
16 March 1999

Abstract

After sudden unexpected death in a previously healthy 42 year old woman, necropsy examination showed myocardial infarction caused by occlusion of a vital coronary artery by fibromuscular dysplasia. This is a rare arterial disease with a clinical onset usually in the third or fourth decades of life. The aetiology is not fully understood but since it affects vital (cer-

bral and coronary) blood vessels it often has fatal consequences.

(*J Clin Pathol* 1999;52:541-542)

Keywords: coronary artery; fibromuscular dysplasia

Fibromuscular dysplasia (synonyms: arterial fibrodysplasia, fibromuscular hyperplasia, intimal fibroplasia) is a condition of unknown aetiology first described by Leadbetter and Burkland in 1938.¹ The disorder may affect arteries of all sizes.² It is said to be commonest in women of childbearing age,³ but it can affect people of all ages, including children.^{4,5} Fibromuscular dysplasia is classified histologically according to the dominant layer of arterial involvement⁶ as *intimal fibroplasia*, *medial fibromuscular dysplasia* (medial fibroplasia, medial hyperplasia, perimedial fibroplasia), or *periarterial fibroplasia*. Intimal fibroplasia consists of a circumferential or eccentric protuberant intimal proliferation of loose, moderately cellular fibrous tissue with no lipid component.

Case report

A 42 year old woman was found unconscious outdoors in October 1998. On arrival at the emergency department she had ventricular fibrillation and was defibrillated. Q waves and ST elevation in the anteroseptal leads were seen on an ECG. Coronary angiography was performed immediately and 80% stenosis was found in the main left coronary artery occluding the first marginal coronary branch. She rapidly became hypotonic, suffered ventricular fibrillation, and died three hours after admission. Her previous clinical history contained only mild skin complaints (psoriasis), and no evidence of angina pectoris or hypertension. There was no knowledge of any previous drug treatment or drug abuse.

Pathological findings

Necropsy examination revealed macroscopical thickening of the inner arterial wall of the left ascending coronary artery bulging towards the lumen. The protrusion was about 1.5 cm long and was occluding the left coronary artery and its first marginal branch. There were no macroscopically demonstrable congenital anomalies and the coronary arteries arose normally from the aorta. There were no atherosclerotic lesions. The heart weighed 195 g, and the heart muscle showed grossly visible acute and chronic ischaemic lesions. The size of septal infarct was 4 × 3 cm and consisted of areas of haemorrhage and scar. Secondary changes from circulatory failure were also noted, such

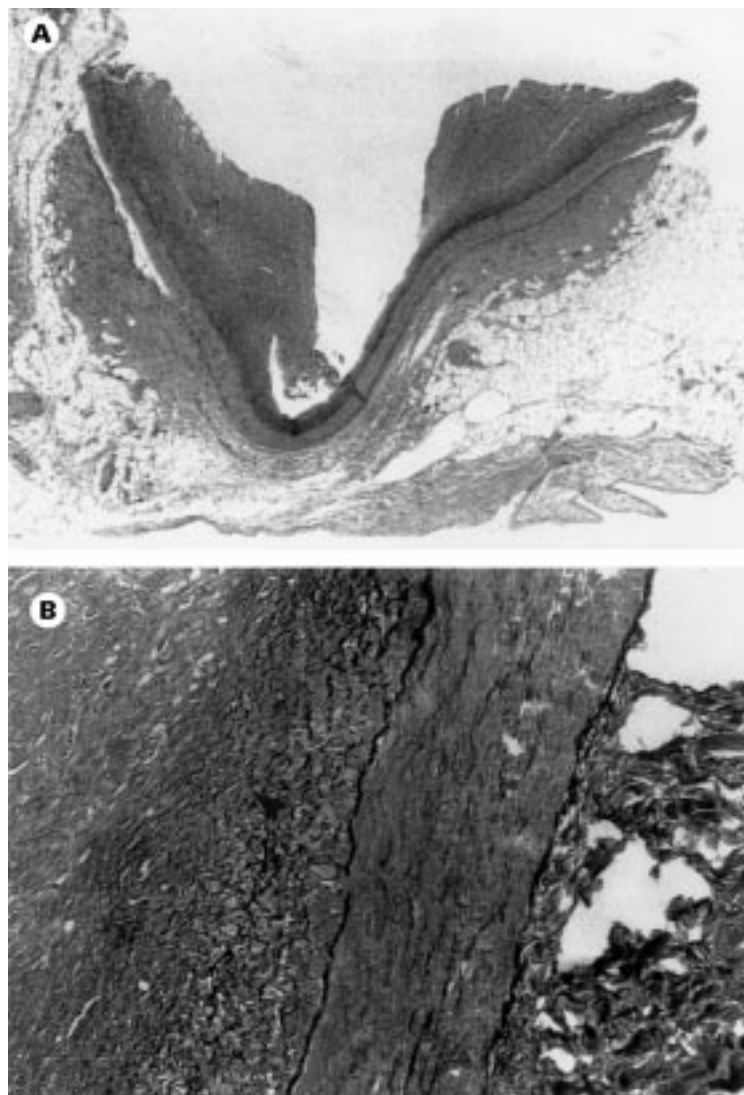


Figure 1 (A) Anterior descending branch of the left coronary artery from a 42 year old woman with arterial fibromuscular dysplasia. This shows two extremely thick intimal cushions rich in smooth muscle. The artery is cut open. Luminal occlusion was almost total. (B) Detail of same section, showing accumulations of irregularly arranged subendothelial mesenchymal cells, surrounded by a loose matrix of fibrous connective tissue, projecting into the vessel lumen (arrowhead). The medial and adventitial architecture is well preserved. *Elastica van Gieson* stain.

as pulmonary oedema and hepatic stasis. The aorta and its main branches, the renal arteries, and the right coronary arteries showed no obvious lesions.

Light microscopic examination of paraffin embedded sections of the coronary vessels showed accumulations of irregularly arranged subendothelial mesenchymal cells, surrounded by loose matrix of fibrous connective tissue, projecting into the vessel lumen. The medial and adventitial architecture were well preserved (fig 1). In the septal area of the heart muscle, fibrosis representing old changes and acute heart muscle damage were both seen. The inflammatory infiltrate consisted of neutrophils, eosinophils, and lymphocytes. Immunohistochemical staining showed that the lymphocytes in the infarct area were labelled with antibodies against leucocyte common antigen, T cell marker UCHL1, and CD8. There were also some UCHL1 and CD8 positive T lymphocytes in the area of fibromuscular dysplasia.

Discussion

Since the entity of fibromuscular dysplasia was first described more than 35 years ago,¹ the clinical importance of this disease as a cause of renovascular hypertension⁷ and intracerebral circulatory dysfunction⁸ has been emphasised. Dysplastic lesions not involving renal and cerebral vessels are uncommon and considered to be of less clinical importance.⁹

The aetiological basis of fibromuscular dysplasia is still unknown. It has been suggested that long, irregular, tubular stenoses caused by fibromuscular dysplasia—which may be seen in infants—are the aftermath of arteritis. Rubella has been implicated in such cases.⁹ Tuberosus sclerosis has also been implicated in the aetiology of fibromuscular dysplasia,¹⁰ as have hormonal influences on the medial tissues of the vessel wall, mechanical stresses, and arterial trauma. However, the precise relation of these factors to each other or to unrecognised pathogenic mechanisms remains unknown. Fibromuscular dysplasia predominantly affects hormonally active women. Pregnancy or anti-ovulant drugs are thought to be contributory

factors to the dysplastic changes. Experimental studies have shown that certain smooth muscle cells and fibroblasts respond to oestrogen stimulation by increasing their synthesis of proteinaceous substances, including collagen.⁹ Furthermore, many growth factors—including transforming growth factors α and β , interleukin-1, macrophage derived growth factor, and fibroblast growth factor—have been shown to contribute to the smooth muscle cell proliferation that can result from mechanical stress on arterial walls.¹¹

Our patient was typical of those affected by fibromuscular dysplasia, being a woman of premenopausal age, though to the best of our knowledge there are few previously reported cases of this disorder involving the coronary arteries.²⁻⁵ Although the number of published cases is very limited, a characteristic clinical pattern is emerging.⁵ Fibromuscular dysplasia is usually fatal when it occludes the main coronary artery branch, causing heart muscle ischaemia and arrhythmias.

Fibromuscular dysplasia should be considered in the differential diagnosis of a premenopausal woman presenting with sudden vascular symptoms. The often fatal occlusion of a coronary vessel can be treated by emergency coronary angioplasty when the correct diagnosis is made.

- 1 Leadbetter WF, Burkland CE. Hypertension in unilateral renal disease. *J Urol* 1938;**39**:611–26.
- 2 Hill LD, Antonius JL. Arterial dysplasia. An important surgical lesion. *Arch Surg* 1965;**90**:585–95.
- 3 Claiborne TS. Fibromuscular hyperplasia. Report of a case with involvement of multiple arteries. *Am J Med* 1970;**49**:103–5.
- 4 Price RA, Vawter GF. Arterial fibromuscular dysplasia in infancy and childhood. *Arch Pathol* 1972;**93**:419–26.
- 5 Arey JB, Segal R. Fibromuscular dysplasia of intramyocardial coronary arteries. *Pediatr Pathol* 1987;**7**:97–103.
- 6 Silver MD, ed. *Cardiovascular pathology*, 2nd ed. Edinburgh: Churchill Livingstone, 1991:410–13.
- 7 McCormack LJ, Poutasse EF, Meaney TF, et al. A pathologic-arteriographic correlation of renal arterial disease. *Am Heart J* 1966;**72**:188–98.
- 8 Ehrenfeld WK, Wylie EJ. Fibromuscular dysplasia of the internal carotid artery: surgical management. *Arch Surg* 1974;**109**:676–81.
- 9 Stanley JC, Gewertz BL, Bove EL, et al. Arterial fibrodysplasia. Histopathologic character and current etiologic concepts. *Arch Surg* 1975;**110**:561–6.
- 10 Rolfes DB, Towbin R, Bove K. Vascular dysplasia in a child with tuberous sclerosis. *Pediatr Pathol* 1985;**3**:359–73.
- 11 Malley MK. Intimal hyperplasia. *Eur J Vasc Surg* 1992;**6**:343–5.



A case of sudden death caused by fibromuscular dysplasia.

K M Ropponen and I Alafuzoff

J Clin Pathol 1999 52: 541-542

doi: 10.1136/jcp.52.7.541

Updated information and services can be found at:

<http://jcp.bmj.com/content/52/7/541>

Email alerting service

These include:

Receive free email alerts when new articles cite this article. Sign up in the box at the top right corner of the online article.

Notes

To request permissions go to:

<http://group.bmj.com/group/rights-licensing/permissions>

To order reprints go to:

<http://journals.bmj.com/cgi/reprintform>

To subscribe to BMJ go to:

<http://group.bmj.com/subscribe/>