

Endometrial pathology in postmenopausal tamoxifen treatment: comparison between gynaecologically symptomatic and asymptomatic breast cancer patients

Ilan Cohen, Eran Perel, Dov Flex, Ron Tepper, Marco M Altaras, Mario Cordoba, Yoram Beyth

Abstract

Aims—To evaluate whether endometrial pathology is more likely to be diagnosed in gynaecologically symptomatic rather than in gynaecologically asymptomatic postmenopausal breast cancer patients with tamoxifen treatment; and to evaluate the possible influence of various clinical factors on the incidence of endometrial pathology.

Methods—Endometrial histological findings, transvaginal ultrasonographic endometrial thickness, demographic characteristics, health habits, and risk factors for endometrial cancer were compared between 14 gynaecologically symptomatic (group I) and 224 gynaecologically asymptomatic (group II) postmenopausal breast cancer patients with tamoxifen treatment.

Results—Overall, 28.6% of the study population had endometrial pathology. The incidence of overall positive endometrial histological findings was significantly higher in group I than in group II (92.9% *v* 24.6%, $p < 0.0001$). Atrophic endometrium was more common in group II than in group I (75.3% *v* 7.1%, $p < 0.0001$). Most other endometrial pathology was significantly more common in group I than in group II (endometrial hyperplasia, 35.7% *v* 5.6%, $p < 0.0001$; endometrial polyps, 35.7% *v* 13.4%, $p < 0.0111$; endometrial carcinoma, 21.5% *v* 0.9%, $p < 0.0001$). Endometrial pathology appeared considerably later in the gynaecologically asymptomatic patients than in gynaecologically symptomatic patients ($p = 0.0002$). Vaginal bleeding or spotting occurred exclusively in group I. The incidence of endometrial pathology in the entire study population was consistent with that reported elsewhere, and higher than that reported for healthy postmenopausal women.

Conclusions—Endometrial pathology is more likely to be diagnosed in gynaecologically symptomatic postmenopausal breast cancer patients with tamoxifen treatment, and after a shorter duration of time, than in gynaecologically asymptomatic patients.

(*J Clin Pathol* 1999;52:278–282)

Keywords: tamoxifen; endometrial pathology

Tamoxifen is a non-steroidal antioestrogen that is considered to be the antihormonal treatment of choice for advanced breast cancer in postmenopausal patients with positive oestrogen receptor proteins.¹ It is known to be safe, effective, and to have minimal side effects.¹

Over the past decade, tamoxifen has been reported to be associated with various endometrial pathologies, such as endometrial hyperplasia,^{2–17} endometrial polyps,^{2–19} and endometrial carcinoma.^{2–4–6–8–10–14–15–17–20–40}

Many studies have compared the incidence of these endometrial pathologies between tamoxifen treated postmenopausal breast cancer patients and similar untreated patients.^{22–24–26–28–33–35–37} Others have compared asymptomatic tamoxifen treated postmenopausal patients and similar untreated patients.^{6–8–10–12–15}

To the best of our knowledge, there have only been three studies that have compared the histological findings in gynaecologically symptomatic and similar gynaecologically asymptomatic postmenopausal tamoxifen treated patients.^{12–14–15} However, two of these^{12–15} did not show any significant difference in the occurrence of endometrial pathology between the two groups, while the third¹⁴ did show a difference. No studies have examined the different factors that may influence the incidence of endometrial pathology between gynaecologically symptomatic and gynaecologically asymptomatic postmenopausal breast cancer patients on tamoxifen.

In this study we compared endometrial histology and transvaginal ultrasonographic measurement of endometrial thickness, demographic characteristics, health habits, and risk factors for endometrial cancer between gynaecologically symptomatic and gynaecologically asymptomatic postmenopausal breast cancer patients given tamoxifen treatment. This study was designed to evaluate whether endometrial pathology is more likely to develop in gynaecologically symptomatic than in gynaecologically asymptomatic patients, and to evaluate the possible impact of various factors on the incidence of endometrial pathology.

Methods

Since 1 September 1989 all postmenopausal breast cancer patients who were under medical supervision or treatment in our institutions were followed up in the gynaecological outpatient clinic, using an investigative protocol.

Department of Obstetrics and Gynaecology, Sapir Medical Centre, Kfar Saba 44281, Israel
I Cohen
E Perel
R Tepper
Y Beyth

Department of Pathology, Sapir Medical Centre
M Cordoba

Gynaecological Oncology Unit, Sapir Medical Centre
M M Altaras

Department of Oncology, Rabin Medical Centre, Petah Tikva, affiliated with Sackler Faculty of Medicine, Tel Aviv University, Israel
D Flex

Correspondence to:
Dr Ilan Cohen.

Accepted for publication
27 October 1998

Table 1 Demographic characteristics and health habits of gynaecologically symptomatic (group I) and gynaecologically asymptomatic (group II) postmenopausal breast cancer patients treated with tamoxifen

| Demographic characteristics | Group I (n=14) | Group II (n=224) | p Value |
|-----------------------------|----------------|------------------|---------|
| Age, years (mean (SD)) | 61.64 (10.65) | 64.34 (9.68) | NS |
| Parity (mean (SD)) | 2.14 (0.86) | 2.83 (2.41) | 0.0197 |
| Gravidity (mean (SD)) | 3.07 (1.77) | 4.43 (3.42) | NS |
| Smoking (n (%)) | 1 (7.1) | 40 (17.9) | NS |

Table 2 Risk factors for endometrial cancer in gynaecologically symptomatic (group I) and gynaecologically asymptomatic (group II) postmenopausal breast cancer patients treated with tamoxifen

| Characteristic | Group I (n=14) | Group II (n=244) |
|--|----------------|------------------|
| Age at menarche, years (mean (SD)) | 12.88 (1.43) | 13.22 (1.24) |
| Age at first delivery, years (mean (SD)) | 26.00 (9.08) | 22.21 (7.73) |
| Age at menopause, years (mean (SD)) | 45.85 (13.84) | 64.75 (23.87) |
| Weight, kg (mean (SD)) | 66.89 (21.62) | 67.69 (12.09) |
| Diabetes mellitus (n (%)) | 1 (7.1) | 34 (15.0) |
| Hypertension (n (%)) | 5 (35.7) | 78 (34.5) |

None of the variables was significantly different between the groups.

Informed consent was obtained from each patient after the nature of the study was fully explained.

According to our investigative protocol, all patients were referred to us by the medical oncologist as soon as they were diagnosed as having malignant breast disease. Some patients were referred later, as they were initially followed in other institutions. Most were gynaecologically asymptomatic on referral. Others, however, were referred while already gynaecologically symptomatic (that is, complaining of vaginal bleeding or spotting).

Evaluation of the patients included gynaecological examination, PAP smears, transvaginal ultrasonographic evaluation, microhysteroscopy with endometrial biopsy and serum 17 oestradiol.

Transvaginal ultrasound was performed using a 5.0 mHz Aloka 500 system initially, and for the last three years using an Accuson 128 XP10 system, with a 5–7 mHz EV7 high resolution endovaginal transducer.

Recently 75 patients with ultrasonographic endometrial thickness of > 8 mm were also evaluated by transvaginal sonohysterography.

Following the ultrasonographic imaging, endometrial sampling was obtained using suction curettage in 51 patients (21.4%). Later in the study, endometrial tissue was sampled during diagnostic hysteroscopy in 124 patients (52.1%) or by operative hysteroscopy in 30 patients (12.6%), who were diagnosed by sonohysterography as having an endometrial echogenic mass. Thirty three patients (13.9%) underwent abdominal or vaginal hysterectomy for various indications such as recurrent vaginal bleeding, ovarian mass or tumour,

Table 3 Distribution of transvaginal ultrasonographic endometrial thickness and clinical factors related to the primary breast cancer in gynaecologically symptomatic (group I) and gynaecologically asymptomatic (group II) postmenopausal breast cancer patients treated with tamoxifen

| Characteristic | Group I (n=14) | Group II (n=224) |
|---|----------------|------------------|
| Endometrial thickness, mm (mean (SD)) | 18.35 (17.47) | 13.27 (8.12) |
| Duration of breast disease, months (mean (SD)) | 69.78 (63.01) | 38.01 (44.33) |
| Duration of tamoxifen treatment, months (mean (SD)) | 37.00 (34.32) | 30.69 (39.22) |
| Chemotherapy (n (%)) | 4 (28.8) | 67 (29.7) |
| Radiotherapy (n (%)) | 9 (64.3) | 147 (61.3) |

None of the variables tested was significantly different between the groups.

endometrial hyperplasia with atypia, uterine prolapse, or progressive growth of the uterus. Overall, 238 tamoxifen treated patients were followed.

The study patients were subdivided into the following groups: 14 (5.9%) gynaecologically symptomatic patients (group I) and 224 (94.1%) gynaecologically asymptomatic patients (group II).

Eleven patients in group I were referred to us while already suffering from postmenopausal bleeding. Only three other patients developed postmenopausal bleeding while under our surveillance.

The two groups were compared for endometrial histological findings as well as for transvaginal sonographic endometrial thickness. Comparison was also made for demographic characteristics, health habits, and the following risk factors for endometrial cancer: age at menarche, age at first delivery, age at menopause, weight, hypertension, diabetes mellitus, serum oestradiol,³⁰ duration of tamoxifen treatment, and various treatments for the primary breast cancer.

When insufficient tissue for histological diagnosis was obtained the finding was classed as negative. A positive histological finding was defined in any case where enough tissue was obtained from endometrial sampling for histological evaluation.

All patients in this study were treated with 20–30 mg of tamoxifen daily (Abic, Chemical and Pharmaceutical Industries, Netanya, Israel).

None of the women in the study had ever received any postmenopausal oestrogen replacement therapy.

STATISTICS

Statistical analysis was performed using the two sample *t* test, analysis of variance with multiple comparisons, and Fisher's exact test. The log rank test was used to test the probability of freedom from endometrial pathologies with respect to the length of tamoxifen treatment between the two groups, which is expressed in a Kaplan–Meier curve.

Significant statistical differences were assumed at a *p* value of < 0.05.

Results

Demographic characteristics and health habits are compared between the two study groups in table 1. A comparison of risk factors for endometrial cancer between the two study groups is shown in table 2 and distribution of transvaginal sonographic endometrial thickness and clinical factors related to the primary breast cancer in the two study groups is given in table 3.

There were no significant differences in any of the variables tested in tables 1, 2, and 3 between the two study groups, except for a higher rate of parity in group II compared with group I (*p* = 0.0197). The duration of tamoxifen treatment and the duration of breast disease were longer in group I patients than in group II patients, but this difference was not significant. Endometrial thickness evaluated by

Table 4 Distribution of endometrial histological findings detected in gynaecologically symptomatic (group I) and gynaecologically asymptomatic (group II) postmenopausal breast cancer patients treated with tamoxifen

| Endometrial histological findings | Group I (n=14) | Group II (n=224) | p Value |
|--|----------------|------------------|---------|
| Atrophic and/or "no tissue obtained" | 1 (7.1) | 169 (75.3) | <0.0001 |
| Proliferative | 0 (0.0) | 11 (4.8) | NS |
| Hyperplasia | 5 (35.7) | 12 (5.6) | <0.0001 |
| Polyps | 5 (35.7) | 30 (13.4) | <0.0111 |
| Carcinoma | 3 (21.5) | 2 (0.9) | <0.0001 |
| Overall positive histological findings | 13 (92.9) | 55 (24.6) | <0.0001 |

Values are n (%).

transvaginal sonography was greater in group I patients than in group II patients, but this difference was also not significant (mean (SD), 18.35 (17.47) mm *v* 13.27 (8.12) mm, NS).

Overall, 68 (28.6%) of the entire study population had endometrial pathology and 170 (71.4%) had either an atrophic endometrium or else insufficient tissue was obtained for histological evaluation on endometrial sampling. Proliferative endometrium was diagnosed in 11 patients (4.6%), endometrial hyperplasia in 17 (7.1%), endometrial polyps in 35 (14.7%), and endometrial carcinoma in five (2.1%). A comparison of endometrial histological findings detected in the two groups is given in table 4.

The overall incidence of positive histological endometrial findings was greater in group I than in group II (92.9% *v* 24.6%, $p < 0.0001$). Atrophic endometrium or no tissue obtained was more common in group II than in group I (75.3% *v* 7.1%, $p < 0.0001$). Most of the other endometrial pathologies were significantly more common in group I than in group II: endometrial hyperplasia, 35.7% *v* 5.6%, $p < 0.0001$ (in group II, simple endometrial hyperplasia without atypia was found in two patients, complex endometrial hyperplasia without atypia in one, simple endometrial hyperplasia with atypia in one, and complex endometrial hyperplasia with atypia in one); in group I, simple endometrial hyperplasia without atypia was diagnosed in eight patients, complex endometrial hyperplasia without atypia in two, simple endometrial hyperplasia with atypia in one, and complex endometrial hyperplasia with atypia in one); endometrial polyps, 35.7% *v* 13.4%, $p < 0.0111$; and endometrial carcinoma, 21.5% *v* 0.9%, $p < 0.0001$.

On hysterectomy specimens we identified atrophic endometrium in five patients (15.2%), endometrial hyperplasia in nine

(27.3%), endometrial polyps in 15 (45.5%), and endometrial carcinoma in four (12.0%).

Figure 1 shows the probability of freedom from overall endometrial pathology with respect to length of tamoxifen treatment in the gynaecologically symptomatic and gynaecologically asymptomatic breast cancer patients ($p = 0.0002$).

All patients in the study except one had serum 17 oestradiol levels in the normal postmenopausal range (< 20 pg/ml; < 73.25 pmol/litre).

Discussion

There is accumulating evidence of an association between postmenopausal tamoxifen exposure and the development of various endometrial pathologies.²⁻⁴⁰ Such an association was based on the observation that the incidence rates of proliferative endometrium, endometrial hyperplasia, endometrial polyps, and endometrial carcinoma were higher among gynaecologically asymptomatic postmenopausal breast cancer patients treated with tamoxifen than in similar untreated patients, although the difference was not statistically significant.^{9-11 15 16}

Other studies comparing the incidence of endometrial cancer among gynaecologically symptomatic and asymptomatic postmenopausal breast cancer patients treated with tamoxifen with similar untreated controls have shown a significant higher risk of endometrial cancer in the tamoxifen treated patients.^{24 26 28 32-33 35}

However, most of these reports were retrospective and described pathological findings in patients who were already gynaecologically symptomatic (complaining of postmenopausal vaginal bleeding or blood stained discharge). None compared the incidence of endometrial pathology between gynaecologically asymptomatic and gynaecologically symptomatic postmenopausal breast cancer patients treated with tamoxifen.

In this study we found that the overall incidence of endometrial pathology detected in the gynaecologically symptomatic tamoxifen treated patients (group I) was higher than in comparable gynaecologically asymptomatic patients (group II) (92.9% *v* 24.6%, $p < 0.0001$). The incidence of endometrial hyperplasia, endometrial polyps, and endometrial cancer was also significantly higher in group I than in group II.

The various endometrial pathologies identified appeared considerably later among the gynaecologically asymptomatic patients than in the gynaecologically symptomatic patients ($p = 0.0002$; fig 1).

The 92.9% incidence of endometrial pathology detected in the gynaecologically symptomatic patients is higher than that reported overall for all postmenopausal breast cancer patients treated with tamoxifen,^{2-37 38-40} or for similar gynaecologically asymptomatic patients.^{6 8-11}

Although the incidence of overall endometrial pathology of 24.6% detected in the gynaecologically asymptomatic tamoxifen treated

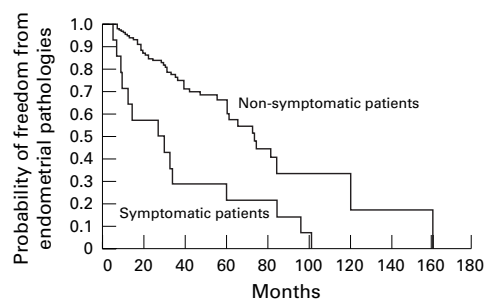


Figure 1 Probability of freedom from overall endometrial pathologies with respect to length of tamoxifen treatment in gynaecologically symptomatic and gynaecologically asymptomatic postmenopausal breast cancer patients ($n = 224$ and $n = 14$, respectively).

patients was lower than that found in similar gynaecologically symptomatic patients, it is similar to that reported in our previous studies with smaller numbers of patients,^{5 8 9 13 16} as well as that reported by others.^{2 4 6 10-12 15 18 19 24 29 31 33 37 38}

There are only three published reports, on relatively small numbers of patients, comparing endometrial histology between these two types of patients.^{12 14 15}

Borenstein *et al* found no endometrial abnormalities in any of 15 gynaecologically asymptomatic postmenopausal breast cancer patients treated with tamoxifen.¹² In seven similar gynaecologically symptomatic patients they identified two endometrial polyps.

Hann *et al* retrospectively reviewed clinical data of 91 postmenopausal breast cancer patients with tamoxifen treatment.¹⁵ Histological evaluation of endometrial specimens was, however, available in only 46 patients. Of these, 20 had postmenopausal bleeding. In the gynaecologically asymptomatic patients there were seven cases of endometrial polyps and two of endometrial hyperplasia. Fourteen of the 20 gynaecologically symptomatic patients had endometrial biopsies which revealed six cases of endometrial polyps, one case of endometrial hyperplasia, and two cases of endometrial carcinoma. Thus the only two cases of endometrial cancer were associated with bleeding. The frequency of endometrial findings reported in these two studies, both in the asymptomatic and in the symptomatic postmenopausal breast cancer patients, is less than we found in our study. Moreover, in contrast to the findings of Hann *et al*, we also identified endometrial cancer among asymptomatic patients.

Gibson *et al* reported the results of a retrospective review of endometrial pathology diagnosed by dilatation and curettage performed on 50 gynaecologically symptomatic breast cancer patients on tamoxifen treatment and on 22 similar gynaecologically asymptomatic patients.¹⁴ Among asymptomatic tamoxifen users the incidence of endometrial polyps was 15%, endometrial hyperplasia 2%, and endometrial carcinoma 11%, compared with an incidence of 9%, 0%, and 0%, respectively, in the asymptomatic tamoxifen users. All endometrial cancer cases in this study were associated with abnormal vaginal bleeding. We found higher rates of all types of endometrial pathology among both symptomatic and asymptomatic tamoxifen treated patients. Again, in contrast to the results of Gibson *et al*,¹⁴ in our study there were two asymptomatic patients with endometrial cancer. This observation suggests the need to perform transvaginal sonographic follow up in asymptomatic postmenopausal tamoxifen treated patients.

Since the exact incidence of endometrial pathology in the postmenopausal female population is difficult to determine,⁴¹ the incidence rates identified in our study among the gynaecologically asymptomatic women, as well as among the entire study patients, is remarkably high.⁵ Archer *et al* found distinctly fewer pathological endometrial findings among 801 healthy postmenopausal women.⁴²

In this study we also compared transvaginal sonographic endometrial thickness, demographic characteristics, health habits, and risk factors for endometrial cancer between the two study groups. No difference was found in any of these variables except for a higher parity rate in group II. The relevance of this finding to the significant difference in the incidence of endometrial pathologies between the two study groups is uncertain.

The number of gynaecologically symptomatic patients was much smaller than the number of gynaecologically asymptomatic patients. This is because of the nature of our follow up. We recruited all breast cancer patients for surveillance as soon as the diagnosis of the primary breast cancer was made, and continued to follow them thereafter. When thick endometrium was diagnosed by transvaginal sonography, hysteroscopy and endometrial biopsy were performed. When precancerous lesions were identified the patients were referred for hysterectomy. This follow up management considerably reduced the number of patients with postmenopausal bleeding and probably also the number of patients with endometrial cancer. In fact, only three of the patients who were under our surveillance had this gynaecological symptom, and all had benign endometrial lesions. Moreover, the incidence of endometrial cancer was significantly lower among the gynaecologically asymptomatic than among the gynaecologically symptomatic patients.

It must be emphasised that we might have identified more endometrial polyps after we adopted sonohysterographic evaluation in patients with transvaginal sonographic endometrial thickness of > 8 mm.⁴³

CONCLUSIONS

A high incidence of overall endometrial pathology, including endometrial hyperplasia, endometrial polyps, and endometrial carcinoma, was detected among gynaecologically symptomatic postmenopausal breast cancer patients treated with tamoxifen. The incidence was significantly higher than that found in similar gynaecologically asymptomatic patients. The endometrial pathologies appeared considerably earlier in the symptomatic than in the asymptomatic patients. The incidence of endometrial pathology in the latter group, as well as in the entire study population, is consistent with figures previously reported by ourselves and others, and is higher than rates reported for healthy postmenopausal women.

Except for postmenopausal bleeding or blood stained discharge, no other clinical factor was found to be associated with the different incidence of endometrial pathology found between the two groups.

We thank Mrs Ruth Sheridan for her editorial assistance.

1 Early Breast Cancer Trialists' Collaborative Group. Systemic treatment of early breast cancer by hormonal, cytotoxic, or immune therapy. *Lancet* 1992;339:1-15, 71-85.

2 Neven P, De Muylder X, Van Belle Y, *et al*. Tamoxifen and the uterus and endometrium. *Lancet* 1989;ii:375.

- 3 Gal D, Kopel S, Bashevkin M, et al. Oncogenic potential of tamoxifen on endometrium of postmenopausal women with breast cancer: a preliminary report. *Gynecol Oncol* 1991;42:120-3.
- 4 De Muylder X, Neven P, De Somer M. Endometrial lesions in patients undergoing tamoxifen therapy. *Int J Gynecol Pathol* 1991;36:127-9.
- 5 Cohen I, Rosen DJD, Shapira J, et al. Endometrial changes in postmenopausal women treated with tamoxifen for breast cancer. *Br J Obstet Gynecol* 1993;100:567-70.
- 6 Lahti E, Blanco G, Kauppila A, et al. Endometrial changes in postmenopausal breast cancer patients receiving tamoxifen. *Obstet Gynecol* 1993;81:660-4.
- 7 Uziely B, Lewin A, Braufman G, et al. The effect of tamoxifen on the endometrium. *Breast Cancer Res Treat* 1993;26:101-5.
- 8 Cohen I, Rosen DJD, Shapira J, et al. Endometrial changes with tamoxifen: comparison between tamoxifen-treated and non-treated asymptomatic breast cancer patients. *Gynecol Oncol* 1994;52:185-90.
- 9 Cohen I, Tepper R, Rosen DJD, et al. Continuous tamoxifen treatment in asymptomatic, postmenopausal breast cancer patients does not cause aggravation of endometrial pathologies. *Gynecol Oncol* 1994;55:138-43.
- 10 Ismail SM. Pathology of endometrium treated with tamoxifen. *J Clin Pathol* 1994;47:827-33.
- 11 Kedar RP, Bourne TH, Powels TJ, et al. Effects of tamoxifen on uterus and ovaries of postmenopausal women in a randomized breast cancer prevention trial. *Lancet* 1994;343:1318-21.
- 12 Borenstein J, Auslender R, Pascal B, et al. Diagnostic pitfalls of ultrasonographic uterine screening in women treated with tamoxifen. *J Reprod Med* 1994;39:674-8.
- 13 Cohen I, Altaras MM, Shapira J, et al. Time-dependent effect of tamoxifen therapy on endometrial pathologies in asymptomatic, postmenopausal breast cancer patients. *Int J Gynecol Pathol* 1996;15:152-7.
- 14 Gibson LE, Barakat RR, Venkatraman ES. Endometrial pathology at dilatation and curettage in breast cancer patients: comparison of tamoxifen users and nonusers. *Cancer J* 1996;2:35-8.
- 15 Hann LE, Geiss CS, Bach AM, et al. Endometrial thickness in tamoxifen-treated patients: correlation with clinical and pathologic findings. *Am J Radiol* 1997;168:657-61.
- 16 Cohen I, Altaras MM, Shapira J, et al. Different coexisting endometrial histological features in asymptomatic, postmenopausal breast cancer patients treated with tamoxifen. *Obstet Gynecol Invest* 1997;43:60-5.
- 17 Cheng W-F, Lin H-H, Torng P-L, et al. Comparison of endometrial changes among symptomatic tamoxifen treated and nontreated premenopausal and postmenopausal breast cancer patients. *Gynecol Oncol* 1997;66:233-7.
- 18 Nouvo MA, Nouvo GJ, McCaffrey RM, et al. Endometrial polyps in postmenopausal patients receiving tamoxifen. *Int J Gynecol Pathol* 1989;8:125-31.
- 19 Corley D, Rowe J, Curtis MJ, et al. Postmenopausal bleeding from unusual endometrial polyps in women on chronic tamoxifen therapy. *Obstet Gynecol* 1992;79:111-16.
- 20 Killackey MA, Hakes TB, Pierce VK. Endometrial adenocarcinoma in breast cancer patients receiving antiestrogens. *Cancer Treat Rep* 1985;69:237-8.
- 21 Ribeiro GM, Swindell R. The Christie Hospital adjuvant tamoxifen trial—status at 10 years. *Br J Cancer* 1988;50:601-3.
- 22 Hardell L. Tamoxifen as a risk factor for carcinoma of corpus uteri. *Lancet* 1988;iii:562.
- 23 Stewart H, Knight GM. Tamoxifen and the uterus and endometrium. *Lancet* 1989;i:375-6.
- 24 Fornander T, Cedermark B, Mattson A, et al. Adjuvant tamoxifen in early breast cancer: occurrence of new primary cancers. *Lancet* 1989;i:117-20.
- 25 Malfetano JH. Tamoxifen-associated endometrial carcinoma in postmenopausal breast cancer patients. *Gynecol Oncol* 1990;39:82-4.
- 26 Andersson M, Storm HH, Mouridsen HT. Incidence of new primary cancers after adjuvant tamoxifen therapy and radiotherapy for early breast cancer. *J Natl Cancer Inst* 1991;83:1013-17.
- 27 Segna RA, Dottino PR, Deligdisch L, et al. Tamoxifen and endometrial cancer. *Mr Sinai J Med* 1992;59:416-18.
- 28 Magriples U, Naftolin F, Schwartz PE, et al. High grade endometrial carcinoma in tamoxifen-treated breast cancer patients. *J Clin Oncol* 1993;11:485-90.
- 29 Seoud MA-F, Johnson J, Weed JC. Gynecologic tumors in tamoxifen-treated women with breast cancer. *Obstet Gynecol* 1993;82:165-9.
- 30 Fornander T, Hellstrom A-C, Moberger R. Descriptive clinicopathologic study of 17 patients with endometrial cancer during or after adjuvant tamoxifen in early breast cancer. *J Natl Cancer Inst* 1993;85:1850-5.
- 31 Fisher B, Costantino JP, Redmond CK, et al. Endometrial cancer in tamoxifen-treated breast cancer patients: findings from the National Surgical Adjuvant Breast and Bowel Project (NSABP) B-14. *J Natl Cancer Inst* 1994;86:527-37.
- 32 van Leeuwen FB, Benraad J, Coebergh JWW, et al. Risk of endometrial cancer after tamoxifen treatment for breast cancer. *Lancet* 1994;343:448-52.
- 33 Barakat RR, Wang G, Curtin J, et al. Tamoxifen use in breast cancer patients who subsequently develop corpus cancer is not associated with a higher incidence of adverse histologic features. *Gynecol Oncol* 1994;55:164-8.
- 34 Silva EG, Tornos CS, Fallen-Mitchell M. Malignant neoplasm of the uterine corpus in patients treated for breast carcinoma: the effects of tamoxifen. *Int J Gynecol Pathol* 1994;13:248-58.
- 35 Rutquist LE, Johnson H, Signomaklo T, et al. Adjuvant tamoxifen therapy for early breast cancer and second primary cancer. *J Natl Cancer Inst* 1995;87:645-51.
- 36 Cook LS, Weiss NS, Schwartz SM, et al. Population-based study of tamoxifen and subsequent ovarian, endometrial and breast cancer. 1995;87:1359-64.
- 37 Robinson DC, Bloss JD, Schiano MA. A retrospective study of tamoxifen and endometrial cancer in breast cancer patients. *Gynecol Oncol* 1995;59:186-90.
- 38 Cuenca RE, Giachino J, Arredondo MH, et al. Endometrial carcinoma associated with breast carcinoma: low incidence with tamoxifen use. *Cancer* 1996;77:2058-63.
- 39 Sasco AJ, Chaplain G, Amoros E, et al. Endometrial cancer following breast cancer: effect of tamoxifen and castration by radiotherapy. *Epidemiology* 1996;7:9-13.
- 40 Curtis RE, Boice JD, Shiner DA, et al. Second cancers after adjuvant tamoxifen therapy. *J Natl Cancer Inst* 1996;88:832-4.
- 41 Creasman WT. Endometrial cancer: incidence, prognostic factors and treatment. *Semin Concol* 1997;24(suppl):140-50.
- 42 Archer DF, McIntyre-Seltman K, Wilborn WW, et al. Endometrial morphology in asymptomatic postmenopausal women. *Am J Obstet Gynecol* 1991;165:317-22.
- 43 Tepper R, Beyth Y, Altaras MM, et al. Value of sonohysterography in asymptomatic postmenopausal tamoxifen-treated patients. *Gynecol Oncol* 1997;64:386-91.



Endometrial pathology in postmenopausal tamoxifen treatment: comparison between gynaecologically symptomatic and asymptomatic breast cancer patients.

I Cohen, E Perel, D Flex, et al.

J Clin Pathol 1999 52: 278-282

doi: 10.1136/jcp.52.4.278

Updated information and services can be found at:

<http://jcp.bmj.com/content/52/4/278>

References

These include:

Article cited in:

<http://jcp.bmj.com/content/52/4/278#related-urls>

Email alerting service

Receive free email alerts when new articles cite this article. Sign up in the box at the top right corner of the online article.

Notes

To request permissions go to:

<http://group.bmj.com/group/rights-licensing/permissions>

To order reprints go to:

<http://journals.bmj.com/cgi/reprintform>

To subscribe to BMJ go to:

<http://group.bmj.com/subscribe/>