

# Adrenocortical oncocytoma

P A Kitching, V Patel, H Ruben Harach

Department of  
Histopathology, North  
Middlesex Hospital,  
London N19, UK  
P A Kitching

Department of  
Medicine, North  
Middlesex Hospital  
V Patel

Department of  
Histopathology, St  
Bartholomew's  
Hospital, London EC1,  
UK  
H R Harach

Correspondence to:  
Dr P A Kitching,  
Department of Cellular  
Pathology, Royal United  
Hospital, Combe Park, Bath  
BA1 3NG, UK.  
email:  
[paul.kitching@lineone.net](mailto:paul.kitching@lineone.net)

Accepted for publication  
11 August 1998

## Abstract

**The histopathology and ultrastructural features of an adrenocortical oncocytoma are reported. The tumour was discovered incidentally during investigation for hypertension in a 72 year old female. Oncocytic tumours of the adrenal cortex are rare, with only 20 examples described in English language reports. Most have been non-functioning and benign, like the present example. Molecular studies may help assess the significance of oncocytic change in the pathogenesis and behaviour of oncocytic neoplasms.**

(*J Clin Pathol* 1999;52:151-153)

Keywords: adrenal cortical neoplasms; oncocytoma

Oncocytic neoplasms are well recognised in organs such as the kidney, thyroid, and salivary glands. They are also seen more rarely in other sites such as the adrenal cortex. We report the histopathology and ultrastructure of an adrenocortical oncocytoma discovered incidentally during investigation of hypertension, and compare the findings with the 20 other cases described in English language reports.

## Case report

A 72 year old female with a one year history of hypertension and previous right sided stroke presented with symptoms of transient left sided weakness and numbness, headache, and visual disturbance.

Physical examination showed a supine systemic blood pressure of 230/120 mm Hg, with a fall to 180/90 mm Hg on standing. No abdominal mass was palpable. There were no features to suggest Cushing's syndrome or virilisation. No abnormal neurological signs were evident.

Routine laboratory studies were normal, including full blood count and urea and electrolytes. Plasma cortisol and successive urinary catecholamine estimations were in the normal range. Computed tomography of the abdomen performed to exclude an adrenal lesion showed a right adrenal mass 10 cm in diameter (fig 1), which was then removed and submitted for histopathological examination.

The immediate postoperative course was uneventful. However, the patient was readmitted with symptoms similar to those before the operation, probably attributable to postural hypotension. She continued to have episodic hypertension as well, with systolic blood pressures at times over 200 mm Hg despite treatment. Plasma steroids and urinary catecholamines remained within normal limits. However, a small 1 cm nodule was identified within the remaining left adrenal. This lesion has only been kept under observation, and the patient remains relatively well 12 months after surgery.

## Histopathology

An en bloc resection of the right kidney and adrenal was received. Gross examination of the specimen showed a solid tumour arising in the adrenal gland, distinct from the kidney. The tumour weighed 330 g and measured 90×85×65 mm. It was surrounded by an intact fibrous capsule which was attached to normal adrenal tissue. The cut surface of the tumour was soft and yellow in colour with streaks of haemorrhage. The adjacent kidney appeared normal. Ten representative samples from the tumour and its capsule and some from the kidney were taken for histology.

The tumour was composed of polygonal cells with abundant, granular, intensely eosinophilic cytoplasm and moderately atypical, sometimes pleomorphic nuclei with central nucleoli (fig 2). The tumour cells were arranged in nested and diffuse patterns of growth. There were no broad fibrous bands, mitotic figures, or necrosis, and no evidence of capsular or vascular invasion. The tumour cells were negative for the Grimelius argyrophil stain and did not show immunoreactivity for CAM 5.2, chromogranin A, or S100. Immunostaining of tumour cells was positive for vimentin. Tissue previously formalin fixed was resin embedded and examined by electron microscopy, which showed that the tumour cells were

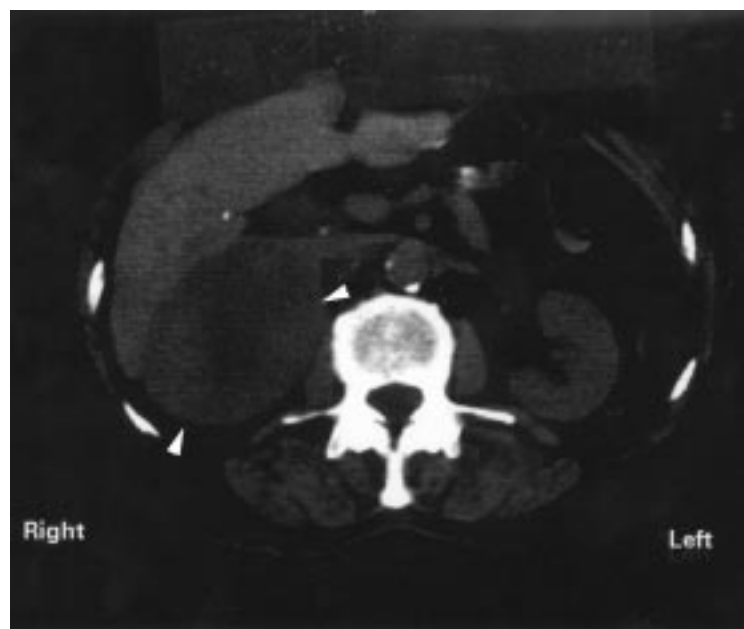


Figure 1 Computerised axial tomogram showing a tumour (arrowed) arising in the right adrenal gland.

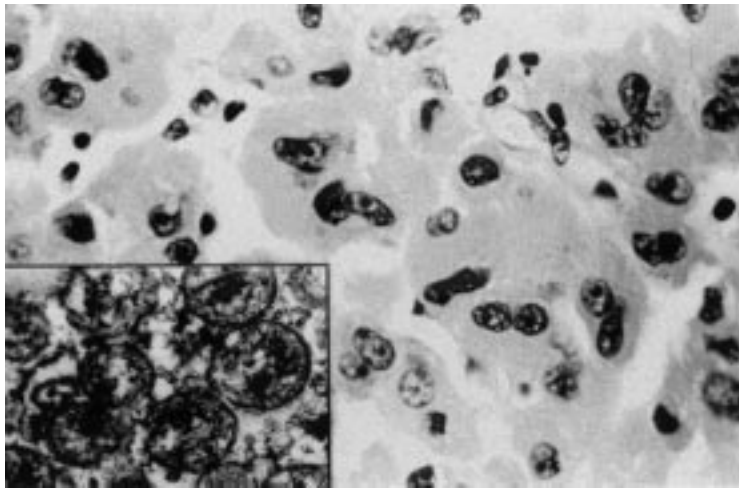


Figure 2 Photomicrograph showing tumour cells with abundant granular cytoplasm and moderately pleomorphic nuclei (haematoxylin and eosin stain). Inset: The tumour cell cytoplasm is packed with mitochondria (electron microscopy,  $\times 15\ 640$ )

packed with mitochondria (fig 2, inset). On the basis of these observations our final diagnosis was that of an adrenocortical oncocytoma.

### Discussion

Neoplasms composed entirely of oncocytes are well described in the kidney, thyroid, and salivary glands, but have also been seen more rarely in other sites, including the pituitary and parathyroid glands, lacrimal gland, respiratory tract, and choroid plexus.<sup>1</sup> Oncocytic adrenal cortical neoplasms are also rare, with only 20 cases described to date in English language reports.<sup>2-10</sup> Including the present case, these tumours have arisen in patients ranging in age from 27 to 72 years (mean 50.9), with 12 female and nine male patients affected. In all cases but one, the tumours were detected incidentally during investigation of symptoms not attributable to the tumour. In one case,<sup>3</sup> the tumour had infiltrated the adjacent vena cava and liver, which may have caused the abdominal pain which led to its discovery. The tumour described here was essentially an incidental finding and its removal had no effect on the patient's symptoms. The nature of the small nodule in the contralateral adrenal is uncertain but such lesions are common incidental findings in elderly patients investigated for hypertension<sup>11</sup> and it is likely to be benign owing to its size.

Evidence of endocrine overactivity was detected in only one tumour.<sup>8</sup> In that case, the female patient showed virilisation, with raised urinary 17-ketosteroids, which fell to normal on resection of the neoplasm. In the three cases described by Sasano,<sup>5</sup> the enzymes responsible for steroid biosynthesis were undetectable by immunohistochemistry. In one case, the tumour was present in an extra-adrenal location adjacent to the normal right adrenal gland,<sup>9</sup> but in all others the tumour arose within the gland. The tumours described have varied in size from 3 to 15 cm and in weight from 30 to 865 g. Fibrous encapsulation appears characteristic and was present, if partially, even in the one locally infiltrative lesion.<sup>3</sup>

A definite diagnosis of adrenocortical oncocytoma was made by demonstrating the presence of numerous mitochondria in the tumour cell cytoplasm at electron microscopy. The cytoarchitectural features of adrenocortical oncocytomas may show a close resemblance to the following: *phaeochromocytoma*, which was excluded in this case by the negative chromogranin A immunoreactivity and the absence of neurosecretory granules on electron microscopy; *adrenocortical adenoma*, where the tumour cell cytoplasm is not packed with mitochondria; *renal oncocytoma*; and *metastatic oncocytic carcinoma*, which were excluded as no primary was found in the right kidney or in other organs on clinical and radiological examination of the patient.

No single histological feature can predict the behaviour of adrenocortical neoplasms. However, studies have shown that a combination of clinical, biochemical, and histological features can provide some useful discrimination of benign from malignant lesions, including size, mitotic count, and the presence of invasion.<sup>12</sup> These features are difficult to extrapolate to oncocytic adrenocortical tumours as few cases have been described. However, 19 of 20 cases have behaved in a benign fashion after a follow up (where stated) of 8-99 months (mean 31), while one<sup>3</sup> showed local infiltration but did not metastasise (length of follow up not stated). Two cases were designated as oncocytic neoplasms of uncertain malignant potential because of the presence of necrosis and mitotic counts of 2 and 6 per 50 high power fields, although neither showed evidence of metastatic spread after follow up periods of 12 and 19 months.<sup>10</sup> It would seem, therefore, that this small sample of oncocytic tumours has behaved as one would have predicted from the criteria Weiss derived from his studies of non-oncocytic tumours.<sup>12</sup>

Molecular biological techniques may help to interpret the aetiology and pathogenesis of this morphologically distinct type of adrenocortical tumour and to differentiate it from the other commoner non-oncocytic neoplasms of the adrenal cortex. Knowledge of the mechanisms that lead to oncocytosis in general and in adrenocortical cells in particular is scanty.<sup>1</sup> One plausible view is that mitochondria proliferate owing to a process analogous to neoplasia, with a mutation in a gene conferring an increase in mitochondrial number. Another possibility is that mitochondria multiply as a compensatory response to an epigenetic functional impairment. Nevertheless, the behaviour of oncocytic neoplasms of the adrenal cortex should be assessed by validated clinical, pathological, and molecular biological criteria using large series. This may help to characterise the oncocytic morphology as a possible separate morphological variable.

- 1 Chang A, Harawi SJ. Oncocytes, oncocytosis and oncocytic tumours. *Pathol Annu* 1992;27:263-304.
- 2 Kakimoto S, Yushita Y, Sanefuji T, et al. Non-hormonal adrenocortical adenoma with oncocytoma-like appearances. *Acta Urol Jpn* 1986;32:757-63.
- 3 El-Naggar AK, Evans DB, Mackay B. Oncocytic adrenal cortical carcinoma. *Ultrastruct Pathol* 1991;15:549-56.

- 4 Gandras EJ, Schwartz LH, Panicek DM, *et al.* Adrenocortical oncocytoma: CT and MRI findings. *J Comput Assist Tomogr* 1996;20:407-9.
- 5 Sasano H, Suzuki T, Sano T, *et al.* Adrenocortical oncocytoma—a true non-functioning adrenocortical tumour. *Am J Surg Pathol* 1991;15:949-56.
- 6 Waters PR, Haselhuhn GD, Gunning WT, *et al.* Adrenocortical oncocytoma: two case reports and review of the literature. *Urology* 1997;49:624-8.
- 7 Begin LR. Adrenocortical oncocytoma: case report with immunocytochemical and ultrastructural study. *Virchows Arch A Pathol Anat* 1992;421:533-7.
- 8 Erlandson RA, Reuter VE. Oncocytic adrenal cortical adenoma. *Ultrastruct Pathol* 1991;15:539-47.
- 9 Nguyen GK, Vriend R, Ronaghan D, *et al.* Heterotopic adrenocortical oncocytoma. *Cancer* 1992;70:2681-4.
- 10 Lin B, Bonsib S, Mierau G, *et al.* Oncocytic adrenocortical neoplasms. *Am J Surg Pathol* 1998;22:603-14.
- 11 Abecassis M, McLaughlin MJ, Langer B, *et al.* Serendipitous adrenal masses: prevalence, significance and management. *Am J Surg* 1985;149:783-8.
- 12 Weiss LM. Comparative histologic study of 43 metastasizing and nonmetastasizing adrenocortical tumors. *Am J Surg Pathol* 1984;8:163-9.

## *Journal of Clinical Pathology* - <http://www.jclinpath.com>

Visitors to the world wide web can now access the *Journal of Clinical Pathology* either through the BMJ Publishing Group's home page (<http://www.bmjpub.com>) or directly by using its individual URL (<http://www.jclinpath.com>). There they will find the following:

- Current contents list for the journal
- Contents lists of previous issues
- Members of the editorial board
- Information for subscribers
- Instructions for authors
- Details of reprint services.

A hotlink gives access to:

- BMJ Publishing Group home page
- British Medical Association web site
- Online books catalogue
- BMJ Publishing Group books.

The web site is at a preliminary stage and there are plans to develop it into a more sophisticated site. Suggestions from visitors about features they would like to see are welcomed. They can be left via the opening page of the BMJ Publishing Group site or, alternatively, via the journal page, through "about this site".



## Adrenocortical oncocytoma.

P A Kitching, V Patel and H R Harach

*J Clin Pathol* 1999 52: 151-153

doi: 10.1136/jcp.52.2.151

---

Updated information and services can be found at:

<http://jcp.bmj.com/content/52/2/151>

---

### References

*These include:*

Article cited in:

<http://jcp.bmj.com/content/52/2/151#related-urls>

### Email alerting service

Receive free email alerts when new articles cite this article. Sign up in the box at the top right corner of the online article.

---

### Notes

---

To request permissions go to:

<http://group.bmj.com/group/rights-licensing/permissions>

To order reprints go to:

<http://journals.bmj.com/cgi/reprintform>

To subscribe to BMJ go to:

<http://group.bmj.com/subscribe/>