

# Metastatic endometrial stromal sarcoma masquerading as pulmonary lymphangioliomyomatosis

Ravi Mahadeva, Susan Stewart, John Wallwork

## Abstract

**A 39 year old female presented with bilateral pneumothoraces and interstitial shadowing on chest x ray. A diagnosis of lymphangioliomyomatosis was made following an open lung biopsy. Over the next eight years she developed respiratory failure leading to single lung transplantation but she died in the immediate postoperative period. Necropsy examination and review of the previous open lung biopsy revealed multiple pulmonary metastases from a low grade endometrial stromal sarcoma of the uterus. This case highlights the importance of an accurate diagnosis before transplantation.**

(*J Clin Pathol* 1999;52:147-148)

Keywords: lymphangioliomyomatosis; endometrial stromal sarcoma; lung transplantation

## Case history

A 39 year old woman presented with breathlessness owing to bilateral pneumothoraces which required intercostal tube drainage. Her chest radiograph also showed interstitial shadowing suggestive of parenchymal disease. The air leaks persisted and she underwent median sternotomy and bilateral pleurodesis. At surgery, the lung was noted to be macroscopically abnormal and a lung biopsy was reported as lymphangioliomyomatosis (LAM). HMB45 staining was negative. Over the next eight years, her dyspnoea worsened despite treatment with tamoxifen, buserelin, and medroxyprogesterone acetate, leading to referral to Papworth hospital for single lung

transplantation. At the time of listing, her chest radiograph showed hyperinflated lung fields, fine reticular shadowing, and small bilateral pleural reactions. Her pulmonary function tests showed the following: forced expiratory volume in 1 second, 0.45 litre (predicted 2.89 litre); forced vital capacity 1.3 litre (3.35 litre); residual volume 4.30 litre (1.64 litre); total lung capacity 5.25 litre (4.99 litre); gas transfer factor could not be obtained.

Immediately after transplantation she developed donor lung failure leading to refractory hypotension and death. Consent was obtained to use her vital organs for transplantation.

Subsequent examination of both her own lungs revealed total disruption of the pulmonary architecture because of irregular cystic spaces. These were predominantly 1-2 cm in diameter with normal intervening parenchyma. Macroscopically there was little evidence of fibrosis.

Microscopic examination (figs 1 and 2) showed cysts and hyalinised cellular nodules composed of spindle cells without atypia, and extremely rare mitoses. Densely packed tumour cells infiltrated beneath the respiratory epithelium of airways and cysts, tending to invade bronchovascular bundles. The tumour was positive for cytokeratin AE1/AE3, smooth muscle actin and vimentin, but negative for Cam 5.2, desmin and HMB45. In addition, a firm partly cystic mass up to 2 cm in diameter with identical histological features was found in the subserosal uterine myometrium. The appearances were those of a low grade metastatic endometrial stromal sarcoma. No other tumour deposits were found, though her heart, liver, kidneys, and long bones had been removed for organ donation before necropsy. Subsequent review of the original open lung biopsy revealed identical tumour.

Our patient's transplanted left lung was airless and congested, consistent with adult respiratory distress syndrome.

The only surviving recipient of our patient's organs was a male kidney transplant patient who elected to keep his graft in view of the extremely low risk of neoplasia from an apparently normal organ in a male hormonal milieu.

The original lung donor was a victim of a tri-cyclic overdose and the recipient of the other lung (at another centre) also developed primary organ failure and died following retransplantation.

Department of Chest Medicine, Papworth Hospital, Papworth Everard, Cambridge CB3 8RE, UK  
R Mahadeva

Department of Pathology, Papworth Hospital  
S Stewart

The Transplant Unit, Papworth Hospital  
J Wallwork

Correspondence to:  
Dr Mahadeva, Department of Chest Medicine, Clinic 2A, Box 40, Addenbrooke's Hospital, Hills Road, Cambridge CB2 2QQ, UK.  
email: rm232@cam.ac.uk

Accepted for publication  
11 August 1998

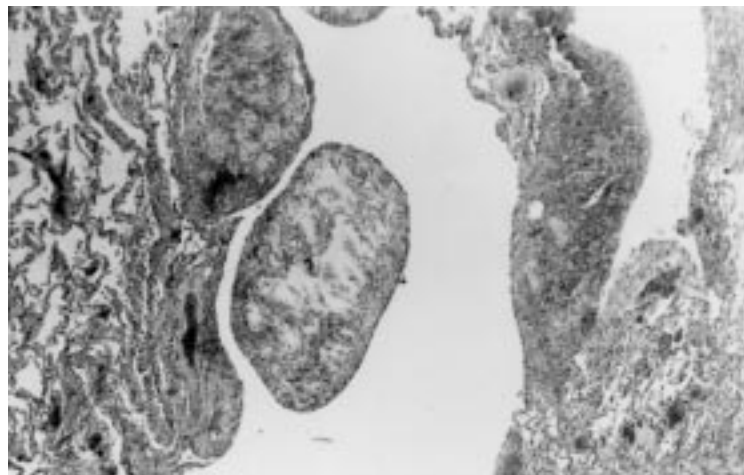


Figure 1 Haematoxylin and eosin medium power showing a cellular nodule projecting into cystic spaces.

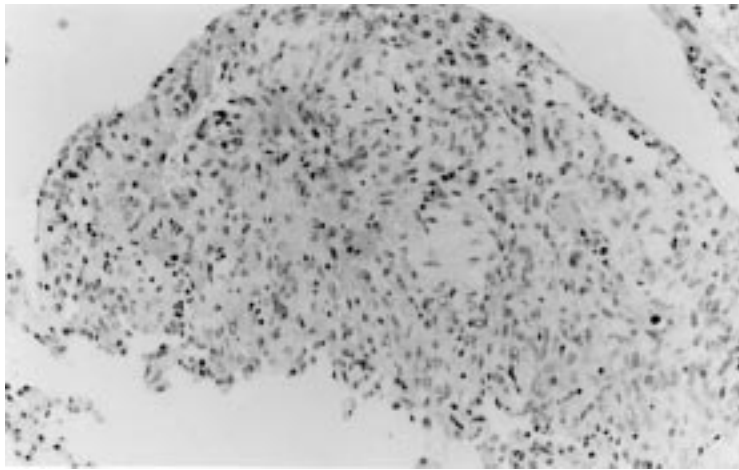


Figure 2 Haematoxylin and eosin high power showing conspicuous hyalinisation of metastatic stromal sarcoma with columns of bland cells without mitoses, round to ovoid in shape.

### Discussion

Endometrial stromal sarcoma represents 0.2% of all uterine malignancies.<sup>1</sup> It is histologically divided into high and low grades, depending primarily on the mitotic index (more or less than 10 mitoses per 10 high power fields, respectively). Low grade tumours are relatively indolent, as shown retrospectively by this case, with at least eight years survival with pulmonary metastases. Lung metastases occur commonly and have been noted at initial diagnosis of the uterine tumour, and many years after removal of the primary.<sup>1,2</sup> However, they are only rarely described as the presenting feature. Histologically, the tumours are characterised by sheets of densely packed, uniform, small spindle or ovoid cells, often with prominent hyalinisation within stromal vessels. The tumour's indolence, rarity, and bland cytological appearance are thought to account for misdiagnoses of pulmonary metastases as benign metastasising hamartoma, solitary pleural mesothelioma, other spindle cell tumours, and mesenchymal cystic hamartoma.<sup>2,3</sup> In our patient, the confusion with lymphangiomyomatosis arose because the dense cellularity and distribution of the tumour nodules was not recognised as a malignant process. The proliferating cells in LAM resemble immature epithelioid or spindle shaped smooth muscle cells with variable amounts of cytoplasm. Characteristically they form cellular collections (sometimes with clefts) in the walls of cystic spaces, often in a bronchovascular distribution. Hyalinisation is not a recognised feature. The lung architecture is preserved away from the affected areas. However, individual patholo-

gists will see few lung biopsies of LAM and may not readily appreciate the various possible pathological mimics. Immunohistochemical staining for HMB45, a marker for LAM, was negative, but at the time of the open lung biopsy it was not known whether this excluded the diagnosis. A recent study reported HMB45 positivity in all five LAM cases and negativity in other cystic pulmonary conditions.<sup>4</sup> However, it has also been noted that epithelioid tumour cells in LAM are strongly positive but spindle cells are negative for this marker.<sup>5</sup> Thus, though HMB 45 is a very useful marker in most cases, it may not be totally reliable in the diagnosis of LAM, particularly in small biopsies. Interestingly, a recent report<sup>6</sup> describes the association between a low grade uterine leiomyosarcoma and cystic pulmonary disease diagnosed as LAM. Although the authors cite the lack of invasiveness or mitotic figures as factors against metastatic leiomyosarcoma, HMB45 staining was not reported.

Despite reports of recurrence of LAM in the graft, single lung transplantation was thought appropriate in this case. Lymphoproliferative disorders and pulmonary smooth muscle proliferation have been reported as result of immunosuppressive treatment following lung transplantation.<sup>7,8</sup>

The importance of an accurate diagnosis before transplantation is emphasised by this case, where immunosuppression would probably have been disastrous. In addition, following the patient's death, her organs which may have had metastatic disease were transplanted into four recipients, thus potentially exacerbating the consequences of the initial misdiagnosis.

We thank Dr M Griffiths for providing us with the original histology.

- 1 Koss LG, Spiro RH, Brunschwig A. Endometrial stromal sarcoma. *Surg Gynecol Obstet* 1965;121:531-7.
- 2 Abrams J, Talcott J, Corson JM. Pulmonary metastases in patients with low-grade endometrial stromal sarcoma. *Am J Surg Pathol* 1989;13:133-40.
- 3 Aaro LA, Symmonds RE, Dockerty MB. Sarcoma of the uterus: clinical and pathologic study of 177 cases. *Am J Obstet Gynecol* 1966;94:101-9.
- 4 Tanaka H, Imada A, Morikawa T, et al. Diagnosis of pulmonary lymphangiomyomatosis by HMB 45 in surgically treated spontaneous pneumothorax. *Eur Respir J* 1995;8:1879-82.
- 5 Bonetti F, Chiodera PL, Pea M, et al. Transbronchial biopsy in lymphangiomyomatosis of the lung. HMB45 for diagnosis. *Am J Surg Pathol* 1993;17:1092-102.
- 6 Dormans TPJ, Verrips A, Bulten J, et al. Pulmonary lymphangiomyomatosis and cerebrotendinous xanthomatosis. Is there a link? *Chest* 1997;112:273-4.
- 7 Stewart S. Pathology of lung transplantation. *Semin Diagn Pathol* 1992;9:210-19.
- 8 Flint A, Lynch JP, Martinez FJ, et al. Pulmonary smooth muscle proliferation occurring after lung transplantation. *Chest* 1997;112:283-4.



## Metastatic endometrial stromal sarcoma masquerading as pulmonary lymphangiomyomatosis.

R Mahadeva, S Stewart and J Wallwork

*J Clin Pathol* 1999 52: 147-148

doi: 10.1136/jcp.52.2.147

---

Updated information and services can be found at:

<http://jcp.bmj.com/content/52/2/147>

---

### References

*These include:*

Article cited in:

<http://jcp.bmj.com/content/52/2/147#related-urls>

### Email alerting service

Receive free email alerts when new articles cite this article. Sign up in the box at the top right corner of the online article.

---

### Notes

---

To request permissions go to:

<http://group.bmj.com/group/rights-licensing/permissions>

To order reprints go to:

<http://journals.bmj.com/cgi/reprintform>

To subscribe to BMJ go to:

<http://group.bmj.com/subscribe/>