

# Differential expression of the cancer associated antigens T (Thomsen-Friedenreich) and Tn to the skin in primary and metastatic carcinomas

Jean Kanitakis, Issam Al-Rifai, Michel Faure, Alain Claudy

## Abstract

**Aim**—To study the immunohistochemical expression of the Thomsen-Friedenreich antigen (T) and its precursor, Tn, in the skin in various cancers.

**Methods**—T and Tn antigens were studied with monoclonal antibodies in 91 primary premalignant and malignant lesions, 13 cases of Paget's disease, and 26 carcinomas metastatic to the skin. The material had been collected over a 10 year period, formalin fixed, and paraffin embedded. Diagnoses had been made after examination of standard histological sections, supplemented when needed by appropriate immunohistochemical staining.

**Results**—21% and 29% of the primary cutaneous premalignant and malignant epithelial tumours expressed the Tn and T antigens, respectively. By contrast, 81% of metastatic carcinomas to the skin were Tn positive, while only 23% of them expressed the T antigen. All cases of Paget's disease were Tn positive but only 15% of them expressed the T antigen. The 21 non-epithelial tumours (including melanomas) were as a rule unreactive.

**Conclusions**—The accumulation of the precursor (Tn) antigen in tumours metastasising to the skin highlights the incomplete glycosylation of carbohydrate antigens occurring in these tumours. The predominant Tn versus T antigen expression appears to be a useful immunohistochemical feature which may aid in the

## differentiation of primary cutaneous carcinomas from metastatic tumours.

(*J Clin Pathol* 1998;51:588-592)

Keywords: Thomsen-Friedenreich antigen; skin carcinomas; metastatic carcinomas

Changes in glycoconjugate metabolism (incomplete or abnormal glycosylation) is one of the features accompanying malignant cell transformation. The expression of glycoproteins is modified because of depression of genes encoding for glycosyltransferases, and this leads to decreased cell-cell adhesiveness, conferring to cancer cells an advantage for metastatic spread.<sup>1-3</sup> Two such carbohydrate antigens are the Thomsen-Friedenreich (T) antigen (Gal $\beta$ (1-3)GalNac $\alpha$ (1-O)-Ser/Thr) and its immediate precursor, the Tn antigen (GalNac $\alpha$ (1-O)-Ser/Thr). These are core disaccharides of O-glycosylated complex carbohydrates, thought to be cryptic in normal post-fetal tissues but expressed in carcinomas of several organs, thereby being considered as "general pancarcinoma" antigens.<sup>4-6</sup> Interestingly, the expression of the T or Tn antigens has been found to correlate with tumour aggressiveness in terms of local invasion, metastasis, and poor survival in carcinomas of the pancreas,<sup>7</sup> colon,<sup>8-10</sup> breast,<sup>11</sup> uterine cervix,<sup>12 13</sup> stomach,<sup>14</sup> urinary bladder,<sup>15 16</sup> and ovary.<sup>17</sup> The T/Tn antigens can be detected with lectins and polyclonal antibodies, but these reagents are less specific than the monoclonal antibodies that are now available.<sup>18 19</sup>

Table 1 Expression of T/Tn antigens in cutaneous malignancies

Diagnosis	Total No	T+ (%)	Tn+ (%)
<b>Laboratory of Dermatopathology, Department of Dermatology, Hôpital Edouard Herriot, Lyon, France</b>			
J Kanitakis			
I Al-Rifai			
M Faure			
A Claudy			
Premalignant dermatoses	18	5 (28)	11 (61)
Actinic keratosis	5	1/±	2/± to +
Bowen's disease	13	4/± or +	9/± or +
Primary carcinomas	52	10 (19)	9 (17)
Basal cell carcinoma	26	1/±	0
Squamous cell carcinoma	22	7/± to ++	8/±
Neuroendocrine skin carcinoma	4	2/±	1/±
Paget's disease	13	2 (15)	13 (100)
Mammary	8	1/±	8/+ to ++
Extramammary*	5	2/+	5/+ to ++
Metastatic skin carcinomas (origin)	26	6 (23)	21 (81)
Breast	8	2/±	7/+ to ++
Lung	4	2/±	4/± to ++
Larynx	1	0	1/±
Kidney	2	0	1/+
Unknown	11	2/+ to ++	8/± to ++
Non-epithelial malignancies	21	0 (0)	1 (5)
Malignant melanoma (primary)	9	0	0
Malignant melanoma (metastatic)	5	0	0
Leukaemia/lymphoma	4	0	0
Langerhans cell histiocytosis	1	0	0
Kaposi sarcoma	1	0	0
Angiosarcoma (Stewart-Treves)	1	0	1/±

Correspondence to:  
Dr Jean Kanitakis,  
Laboratory of  
Dermatopathology,  
Department of Dermatology,  
Hôpital Edouard Herriot,  
69437 Lyon cedex 03,  
France; email:  
kanitak@lyon151.inserm.fr

Accepted for publication  
16 April 1998

\*3 vulvar, 1 scrotal, 1 perianal.

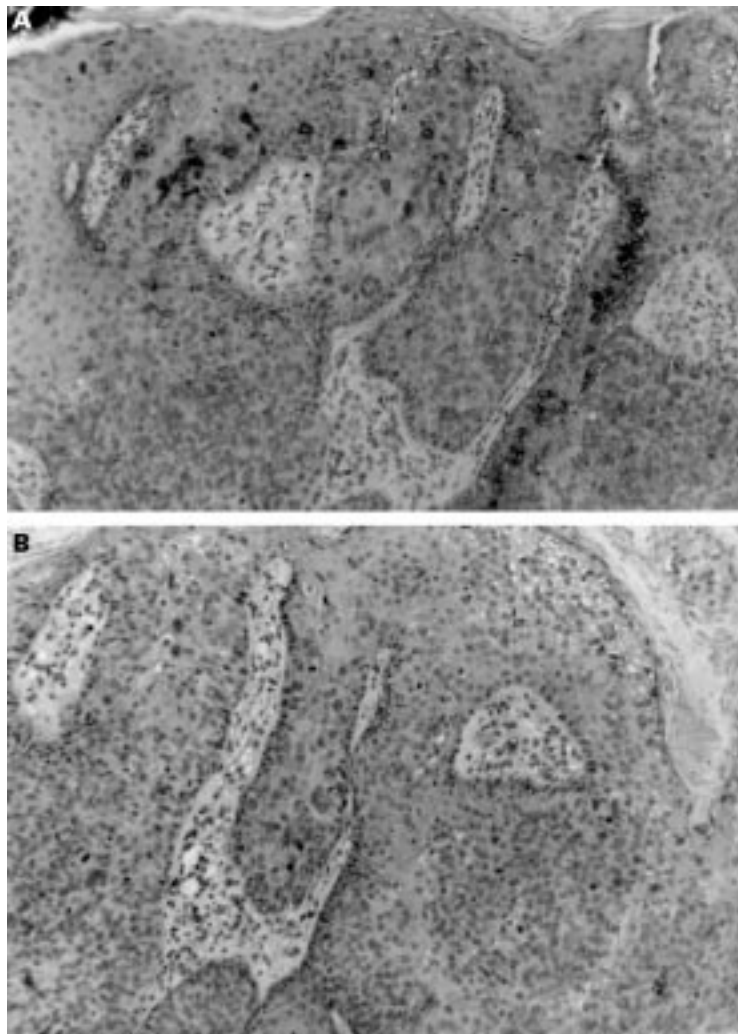


Figure 1 Actinic keratosis (bowenoid type): the T antigen is expressed within the cytoplasm of around 30% of atypical keratinocytes (A); no Tn expression is seen (B).

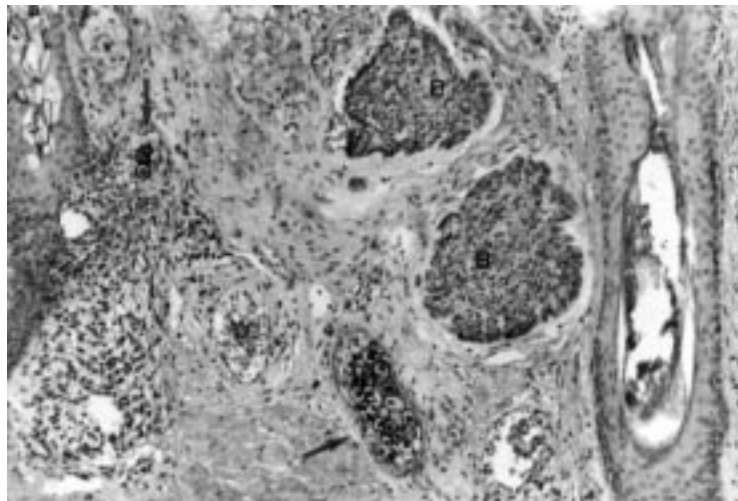


Figure 2 In basal cell carcinoma no T antigen expression is seen (note normal sebaceous glands, arrowed, expressing strong immunoreactivity).

Up to now there have been few data on the expression of T/Tn antigens detected by monoclonal antibodies in normal and neoplastic skin.<sup>20 21</sup> Recently we found that in adult human skin the T and Tn antigens are expressed within sebaceous (and occasionally

sweat) glands and benign proliferations arising from these<sup>21a</sup>); furthermore, demodex mites colonising hair follicles express the Tn (but not the T) antigen.<sup>22</sup> However, normal epidermis and benign epidermal tumours are unreactive. Because of the scarcity of relevant data in published reports, and in view of the potential involvement of T/Tn antigens in carcinogenesis, we screened their expression in primary and metastatic malignancies of the skin.

## Methods

### TISSUE SAMPLES

These included biopsy or excision specimens of epithelial premalignant tumours (18) and malignant cutaneous tumours (52 primary and 26 metastatic of various origins), 13 cases of Paget's disease (eight mammary and five extramammary), and 21 mesenchymal malignant tumours (table 1). The diagnosis of metastatic (*v* primary cutaneous) carcinoma in cases with no known primary was supported by the following histological features: tumour masses dispersed in the mid- and lower dermis, no connection with the overlying epidermis or the surrounding adnexa, and Indian file infiltration of collagen bundles by tumour cells. The material had been collected in our laboratory over the previous 10 years, formalin fixed, and paraffin embedded. The diagnosis had been made after examination of standard histological sections, supplemented when needed by appropriate immunohistochemical staining (keratin, S100 protein, HMB45 antigen, carcinoembryonic antigen, and epithelial membrane antigen).

### IMMUNOHISTOCHEMISTRY

Sections 4  $\mu$ m thick, placed on aminopropyltriethoxysilane coated glass slides, were deparaffinised and rehydrated, then immunolabelled according to a streptavidin-biotin-peroxidase technique (LSAB kit, Dako, Copenhagen, Denmark). This included the following steps:

- (1) Inhibition of endogenous peroxidase with 1% H<sub>2</sub>O<sub>2</sub> in phosphate buffered saline.
- (2) Incubation of the sections with blocking (non-immune) serum.
- (3) Incubation with the primary antibodies for 15 minutes in moist chambers at room temperature; primary antibodies used were: (a) clone HB-T1, a mouse IgMk anti-T antigen produced against the terminal  $\beta$ Gal-1-3 $\alpha$ GalNAc-carrying glycosphingolipid isolated from human blood group A erythrocytes; (b) clone HB-Tn1, a mouse IgMk produced with asialo-ovine submaxillary mucin as immunogen and recognising the Tn antigen. Both reagents were purchased from Dako and used at a dilution of 1:40.
- (4) Incubation with biotin conjugated antiserum to mouse immunoglobulins (10 minutes).
- (5) Incubation with peroxidase conjugated streptavidin (10 minutes).

The reaction was revealed with aminoethylcarbazole as chromogen. The intensity of immu-

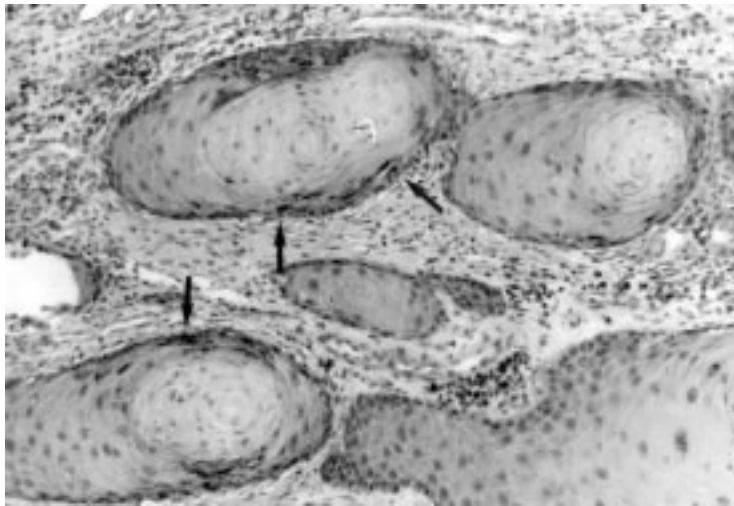


Figure 3 Primary cutaneous squamous cell carcinoma: weak cytoplasmic T antigen immunoreactivity is seen within the most differentiated cells (arrows).

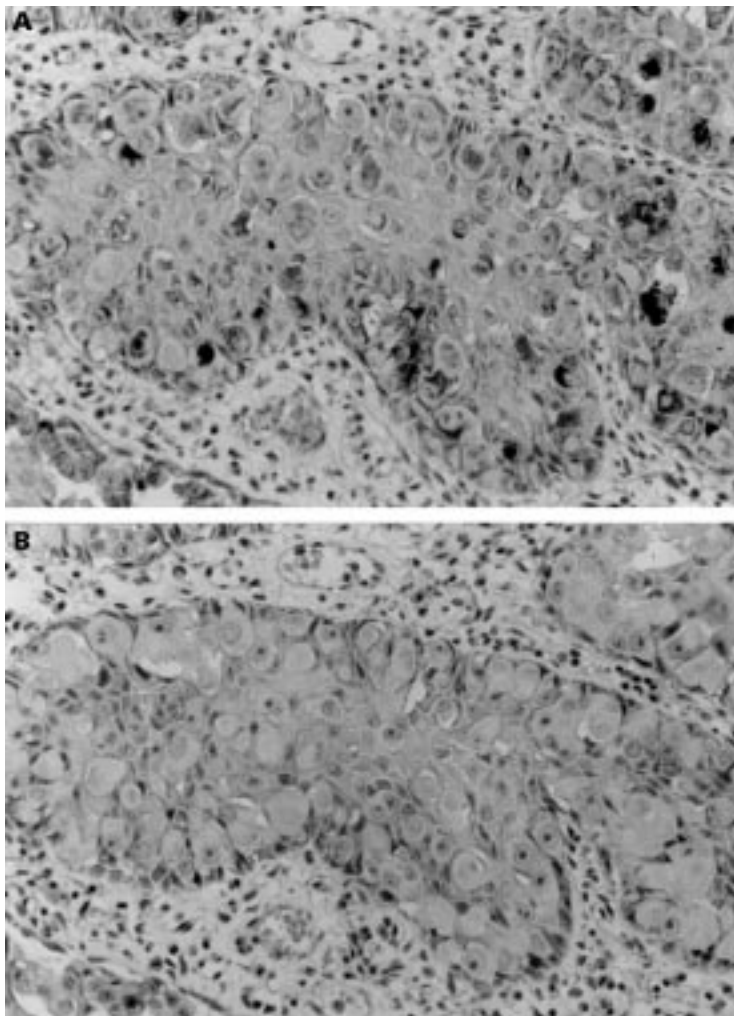


Figure 4 Extramammary Paget's disease: the T antigen is not expressed (B) whereas the Tn antigen is expressed within the cytoplasm of most Paget's cells (A).

nolabelling was scored according to the percentage of immunoreactive cells as follows: 0 (no labelling),  $\pm$  (< 10%), + (10–30%), and ++ (> 30%). Negative controls were performed by omitting the first layer antibody and proved consistently negative.

## Results

The results are summarised in table 1. The normal looking epidermis overlying the tumours studied was unreactive for both antigens. T (and more weakly Tn) cytoplasmic immunoreactivity was consistently seen in adjacent sebaceous glands, and this served as an internal positive control.

### EPITHELIAL TUMOURS

#### Primary tumours

Overall, Tn and T immunoreactivity was seen in only 20 (29%) and 15 (21%), respectively, of the 70 primary cutaneous premalignant and malignant lesions. In more detail, in 18 premalignant conditions of the epidermis (actinic keratoses and Bowen's disease), T and Tn expression was found in five (28%) and 11 cases (61%), respectively. The labelling intensity was low, with less than 30% of epidermal cells stained in each case (figs 1, panels A and B). The immunoreactivity was cytoplasmic and present in medium and upper layer keratinocytes.

The 26 basal cell carcinomas (including superficial, solid, adenoid, and morphea-like) were unreactive (fig 2), with the exception of a single (adenoid) basal cell carcinomas where about 20% of T antigen positive cells were found within the deepest tumour masses.

Fourteen of 22 primary squamous cell carcinomas (64%), including the poorly differentiated ones, were completely unreactive. Of the remaining squamous cell carcinomas, all eight cases (36%) were Tn+ and of these, seven (36%) were T+ and one was T-; all these cases comprised more T- than Tn-immunoreactive cells, found mainly around areas of keratinisation (fig 3). Two of four cases of primary neuroendocrine skin carcinoma ("Merkel cell tumour") comprised a few (less than 5%) T antigen positive cells and another case comprised a low percentage of Tn positive cells; one case was completely unreactive.

#### Paget's disease

All cases of mammary (n = 8) and extramammary (n = 5) Paget's disease showed cytoplasmic Tn immunoreactivity within Paget cells; conversely, only one and two cases respectively of mammary and extramammary Paget's disease expressed the T antigen (fig 4).

#### Metastatic tumours

Overall, cytoplasmic Tn and T immunoreactivity was detected in 21 (81%) and six (23%) of the 26 metastatic tumours, respectively. All metastatic carcinomas of the breast, larynx, and kidney (n = 11) were Tn positive/T negative (fig 5); in this group, low T antigen expression was seen only in two cases of metastatic breast carcinoma. In the remaining cases, expression of the Tn and T antigens was seen respectively in 4/4 and 2/4 lung carcinomas, and in 8/11 and 2/11 metastatic carcinomas of unknown primary origin. In all positive cases, the expression of the Tn antigen was greater than that of the T antigen, both in terms of percentage of cells immunolabelled and of individual cell staining intensity.

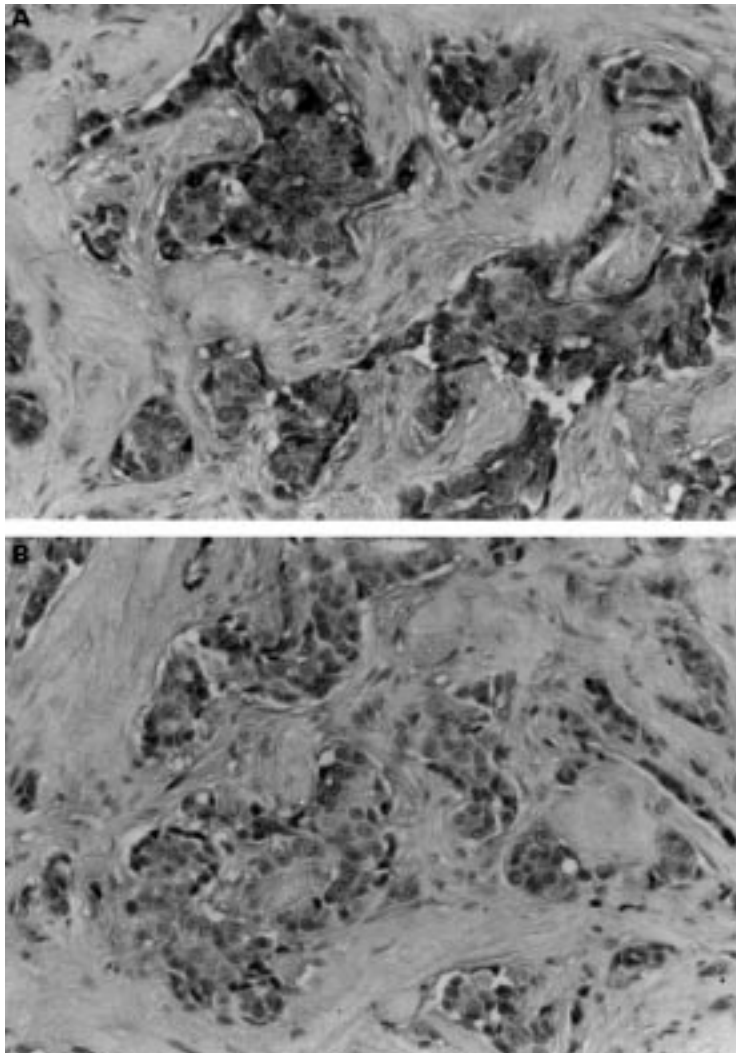


Figure 5 Mammary adenocarcinoma metastatic to the skin: malignant cells express strong cytoplasmic Tn immunoreactivity (A) but no T antigen immunoreactivity (B).

#### NON-EPITHELIAL TUMOURS

All these tumours (that is, primary and metastatic melanomas of the skin) were T/Tn negative. The only exception was a case of postmastectomy (Stewart-Treves) angiosarcoma which comprised 5% T positive cells.

#### Discussion

The Thomsen-Friedenreich antigen (T) and its precursor, Tn, are complex mucin-type carbohydrate antigens, the expression of which has been studied extensively in visceral carcinomas and has been found in some cases to correlate with the course of these tumours. As far as we know, no study has reported in detail the expression of T and Tn antigens detected with monoclonal antibodies in skin tumours. The T and Tn antigens can be recognised using plant lectins (*Arachis Hypogaea*-PNA and *Vicia Villosa* Agglutinin-VVA, respectively) but these reagents are not absolutely specific. For instance, PNA also recognises N-acetylglucosamine (LacNac; Galbeta1-4GlcNac) present at the termini of several cell surface glycoproteins. This accounts for the much wider reactivity pattern of PNA in normal and neoplastic skin than we obtained

with the monoclonal antibodies used in this study. For instance, PNA invariably labels the surface of keratinocytes of the upper epidermal and hair follicle layers,<sup>23</sup> the epithelial component of hair follicle tumours,<sup>24</sup> a variable proportion of histiocytic cells in xanthogranulomas and Langerhans cell histiocytoses,<sup>25</sup> keratoacanthomas, squamous<sup>26</sup> and basal cell carcinomas,<sup>27</sup> and some malignant melanomas.<sup>28</sup> In our study we never detected such reactivities either on normal or in diseased skin. Therefore the results of studies with lectins are not comparable with those obtained with specific antibodies, at least in the specific case of T/Tn antigens. Very recently, a leucine mutant of PNA was described (L212N) which is specific for the T antigen<sup>29</sup>; however, this has not yet been used for the study of skin tumours.

In a preliminary study, we found consistent T/Tn antigen expression in tumours arising from sebaceous glands and (much less often and in a surface rather than a cytoplasmic pattern) from sweat glands.<sup>21a</sup> With the exception of these cases, where the T/Tn immunoreactivity obviously reflects tumour derivation from structures (sebaceous and sweat glands) normally expressing these antigens, benign epidermal tumours expressed much less—if any—immunoreactivity compared with the primary cutaneous carcinomas studied here. These results are in agreement with those reported earlier in relation to tumours of the ovary<sup>17</sup> and the breast,<sup>30</sup> and suggest that in normal epidermis and its benign tumours the T/Tn antigens are cryptic, masked by further glycosylation, whereas in malignant tumours deficient glycosyltransferase activity leads to their exposure.

The results we obtained on T/Tn antigen expression in primary cutaneous carcinomas and tumours metastatic to the skin agree with published data showing a predominance of Tn over T expression in poorly differentiated carcinomas of the colon,<sup>9</sup> breast,<sup>11</sup> and uterine cervix.<sup>12</sup> Indeed, even though we could not study the primary tumours corresponding to our metastatic carcinomas, we found the latter to express the Tn antigen much more commonly (81%) than the T antigen (23%). Remarkably, primary cutaneous (squamous and basal cell) carcinomas expressed generally low T/Tn immunoreactivity. It is tempting to speculate that the low T/Tn immunoreactivity observed in primary cutaneous tumours reflects their lower biological aggressiveness (metastatic potential) as compared with carcinomas metastasising to the skin.

Our results on mammary and extramammary forms of Paget's disease provide interesting information concerning Paget cells. Mammary Paget's disease is considered to reflect the presence of an underlying mammary adenocarcinoma, but the extramammary form is associated with an underlying malignancy in no more than 25% of cases.<sup>31</sup> The precise nature of intraepidermal Paget cells is not unequivocally settled (intraepidermal spread of cells from the underlying tumour along lactiferous ducts in the mammary form or along apocrine ducts in the extramammary form, or in situ malignant transformation of intraepidermal undifferentiated

ated keratinocytes). The clearly predominant Tn over T antigen immunoreactivity in both mammary and extramammary Paget's disease—that is, a pattern similar to that shown by metastatic carcinomas—favours the first hypothesis; indeed, keratinocytic malignancies arising within the epidermis from keratinocytes (for example, Bowen's disease) seem to express small amounts of the T and Tn antigens.

From a diagnostic point of view, the predominance of Tn over the T antigen may assist in the histopathological distinction between primary cutaneous carcinomas and carcinomas metastasising to the skin. Whereas the differential diagnosis is usually easy, individual cases of squamous cell carcinomas may pose a diagnostic challenge to the pathologist (for example, when no connection of tumour masses with the surface epidermis is seen). Some organ specific antigens exist (such as prostate specific antigen or thyroglobulin) which may identify the organ of origin of the secondary cutaneous tumour and thereby definitely establish its metastatic nature.<sup>32</sup> From our present results, the predominant expression of the Tn over the T antigen favours a metastatic origin of the tumour. This feature seems to be particularly helpful in undifferentiated lesions and in metastases of unknown origin, since in these cases the Tn is also more strongly expressed than the T antigen. According to our preliminary data on benign sweat gland tumours, sweat gland carcinomas could also express the T/Tn antigens; however, we speculate that in these cases the labelling would be localised on the surface rather than in the cytoplasm of tumour cells. This hypothesis needs confirmation.

#### CONCLUSION

In conclusion, we found that primary cutaneous premalignant and malignant epithelial tumours show weak T or Tn antigen immunoreactivity, or both, in contrast to carcinomas metastasising to the skin, which show a greater expression of predominantly precursor (Tn) over T antigen immunoreactivity. This differential expression seems interesting from a pathogenic point of view, and offers a useful criterion for the histopathological diagnosis of these lesions, particularly since T and Tn antigens are readily detectable on formalin fixed, paraffin embedded specimens. The value of the T/Tn antigens as prognostic indicators in primary cutaneous carcinomas is currently under investigation.

We thank Drs A Réano and O Berthier (INSERM U346) for fruitful discussions and D Bouchany and J Soum for technical assistance.

- 1 Dall'Olio F. Protein glycosylation in cancer biology: an overview. *J Clin Pathol Mol Pathol* 1996;49:M126–35.
- 2 Kemmer W, Morgenthaler J, Brossmer R. Alterations in the cell surface carbohydrate composition of a human colon carcinoma cell line affect adhesion to extracellular matrix components. *Biochimie* 1992;74:117–22.
- 3 Gessner P, Riedl S, Quentmaier A, et al. Enhanced activity of CMP-NeuAc:Galb1-4GlcNAc:α2,6-sialyltransferase in metastasizing human colorectal tumor tissue and serum of tumor patients. *Cancer Lett* 1993;75:143–9.
- 4 Springer G, Desai P. Pancarcinoma T and Tn epitopes: autoimmunogens and diagnostic markers that reveal incipient carcinomas and help establish prognosis. In: Herberman R, Mercer D, eds. *Immunodiagnosis of cancer*, 2nd ed. New York: Marcel Dekker, 1990:587–612.
- 5 Springer G, Desai P, Ghazizadeh M, et al. T/Tn pancarcinoma autoantigens: fundamental, diagnostic and prognostic aspects. *Cancer Detect Prev* 1995;19:173–82.
- 6 Hanish FG, Baldus SE. The Thomsen-Friedenreich (TF) antigen: a critical review on the structural, biosynthetic and histochemical aspects of a pancarcinoma-associated antigen. *Histol Histopathol* 1997;12:263–81.
- 7 Schuessler M, Pintado S, Welt S, et al. Blood group and blood-group-related antigens in normal pancreas and pancreas cancer: enhanced expression of precursor type 1, Tn and sialyl-Tn in pancreas cancer. *Int J Cancer* 1991;47:180–7.
- 8 Campbell B, Finnie I, Hounsell E, et al. Direct demonstration of increased expression of Thomsen-Friedenreich antigen in colonic adenocarcinoma and ulcerative colitis mucin and its concealment in normal mucin. *J Clin Invest* 1995;95:571–6.
- 9 Itzkowitz S, Yuan M, Montgomery C, et al. Expression of Tn, sialosyl-Tn, and T antigens in human colon cancer. *Cancer Res* 1989;49:197–204.
- 10 Orntoft T, Harving N, Langkilde N. O-linked mucin-type glycoproteins in normal and malignant colon mucosa: lack of T-antigen expression and accumulation of Tn and sialosyl-Tn antigens in carcinomas. *Int J Cancer* 1990;45:666–72.
- 11 Springer G. Tn epitope (N-acetyl-D-galactosamine-O-serine/threonine) density in primary breast carcinoma: a functional predictor of aggressiveness. *Mol Immunol* 1989;26:1–5.
- 12 Hamada S, Furumoto H, Kamada M, et al. High expression rate of Tn antigen in metastatic lesions of uterine cervix cancers. *Cancer Lett* 1993;74:167–73.
- 13 Hirao T, Sakamoto Y, Kamada M, et al. Tn antigen, a marker of potential for metastasis of uterine cervix cancer cells. *Cancer* 1993;72:154–9.
- 14 Chung Y, Yamashita Y, Kato Y, et al. Prognostic significance of T antigen expression in patients with gastric carcinoma. *Cancer* 1996;77:1768–73.
- 15 Blasco E, Torrado J, Belloso L, et al. T-antigen: a prognostic indicator of high recurrence index in transitional carcinoma of the bladder. *Cancer* 1988;61:1091–5.
- 16 Langkilde N. T antigens in primary non-invasive and superficially invasive human urinary bladder tumours: the correlation to tumor recurrence and tumor progression: a mini-review. *Scand J Urol Nephrol* 1995;172:45–9.
- 17 Ghazizadeh M, Oguro T, Sasaki Y, et al. Immunohistochemical and ultrastructural localization of T antigen in ovarian tumors. *Am J Clin Pathol* 1990;93:315–21.
- 18 Longenecker M, Willans D, McLean G, et al. Monoclonal antibodies and synthetic tumor-associated glycoconjugates in the study of the expression of Thomsen-Friedenreich-like and Tn-like antigens on human cancers. *J Natl Cancer Inst* 1987;78:489–96.
- 19 Sell S. Cancer-associated carbohydrates identified by monoclonal antibodies. *Hum Pathol* 1990;21:1003–19.
- 20 Barr N, Taylor C, Toung T, et al. Are pancarcinoma T and Tn differentiation antigens? *Cancer* 1989;64:834–41.
- 21 Cao Y, Stosiek P, Springer G, et al. Thomsen-Friedenreich-related carbohydrate antigens in normal adult human tissues: a systematic and comparative study. *Histochem Cell Biol* 1996;106:197–207.
- 21a Kanitakis J, Al Rifai I, Faure M, et al. Thomsen-Friedenreich and its precursor (Tn) antigen expression in normal skin and in benign cutaneous tumours. *Acta Derm Venereol* 1998;78:173–6.
- 22 Kanitakis J, Al Rifai I, Faure M, et al. Demodex mites of human skin express Tn but not T (Thomsen-Friedenreich) antigen immunoreactivity. *J Cutan Pathol* 1997;24:454–5.
- 23 Reano A, Faure M, Jacques Y, et al. Lectins as markers of human epidermal cell differentiation. *Differentiation* 1982;22:205–10.
- 24 Tsubura A, Fujita Y, Sasaki M, et al. Lectin-binding profiles for normal skin appendages and their tumors. *J Cutan Pathol* 1992;19:483–9.
- 25 Kanitakis J, Roche P, Thivolet J. The expression of PNA-lectin binding sites and S100 protein in histiocytic lesions of the skin. *Acta Derm Venereol* 1988;68:1–7.
- 26 Kannon G, Park K. Utility of peanut agglutinin (PNA) in the diagnosis of squamous cell carcinoma and keratoacanthoma. *Am J Dermatopathol* 1990;12:31–6.
- 27 Vigneswaran N, Haneke E, Peters K. Peanut agglutinin immunohistochemistry of basal cell carcinoma. *J Cutan Pathol* 1987;14:147–53.
- 28 Zebda N, Bailly M, Brown S, et al. Expression of PNA-binding site specific glycoproteins by human melanoma cells is associated with a high metastatic potential. *J Cell Biochem* 1994;54:161–4.
- 29 Sharma V, Vijayan M, Suroli A. Imparting exquisite specificity to peanut agglutinin for the tumor-associated Thomsen-Friedenreich antigen by redesigning its combining site. *J Biol Chem* 1996;271:21209–13.
- 30 Springer G, Desai P, Banatwala I. Blood group MN antigens and precursors in normal and malignant human breast glandular tissues. *J Natl Cancer Inst* 1975;54:335–9.
- 31 Kanitakis J, Cozzani E. La maladie de Paget mammaire et extramammaire. In: *Encyclopedie medico-chirurgicale*. Paris: Ed. Techniques, Dermatologie, 1994:12-755-A10.
- 32 Kanitakis J. Solid cutaneous tumours. In: Kanitakis J, Vassileva S, Woodley D, eds. *Diagnostic immunohistochemistry of the skin*. London: Chapman and Hall, 1998:279–99.



## Differential expression of the cancer associated antigens T (Thomsen-Friedenreich) and Tn to the skin in primary and metastatic carcinomas.

J Kanitakis, I al-Rifai, M Faure, et al.

*J Clin Pathol* 1998 51: 588-592

doi: 10.1136/jcp.51.8.588

---

Updated information and services can be found at:

<http://jcp.bmj.com/content/51/8/588>

---

### References

*These include:*

Article cited in:

<http://jcp.bmj.com/content/51/8/588#related-urls>

### Email alerting service

Receive free email alerts when new articles cite this article. Sign up in the box at the top right corner of the online article.

---

### Notes

---

To request permissions go to:

<http://group.bmj.com/group/rights-licensing/permissions>

To order reprints go to:

<http://journals.bmj.com/cgi/reprintform>

To subscribe to BMJ go to:

<http://group.bmj.com/subscribe/>