

Letters

Pseudomyxoma ovariilike posttherapeutic alteration in prostate adenocarcinoma

Montironi and Schulman recently provided in this journal a comprehensive review of the histological changes in the prostate after androgen manipulation.¹ We wish to document the occurrence of an additional striking but unusual alteration in prostate adenocarcinoma following antiandrogen treatment.

Case report

An eighty year old man presented with bladder outflow obstruction and haemorrhoids. Ten years previously he had undergone a transurethral resection of the prostate (TURP) for benign hyperplasia. Rectal examination revealed an enlarged prostate with a malignant feeling nodule in the left lobe. His serum prostate specific antigen was 95 ng/ml and a bone scan was negative. A biopsy was not performed, but he was started on monthly subcutaneous goserelin (Zoladex) injections which were stopped four months later at the patient's request. At that stage a channel TURP was performed at which 4 g of chippings were removed and bilateral orchidectomy was undertaken. The chippings showed extensive poorly differentiated adenocarcinoma and the testes showed signs of hormonal suppression. The adenocarcinoma was PSA positive immunohistochemically and had features suggesting hormone treatment, with shrunken acini, cytoplasmic clearing, and nuclear shrinkage with cell degeneration. In one chipping there were microscopic pools of mucin which were PAS positive, diastase resistant (fig 1). No epithelial lining was seen to these foci and apart from very sparse single degenerating cells, the mucin was acellular.

These pathological findings were recently characterised for the first time in a published report.² The authors coined the term "pseudomyxoma ovariilike posttherapeutic alteration" because of the resemblance to the more commonly recognised finding in ovarian mucinous neoplasms. Previously, such fea-

tures have been only briefly alluded to in association with hormone treatment for prostate carcinoma.^{3,4}

Distinction from rare mucinous adenocarcinomas of the prostate is afforded by the lack of cellular elements within the mucin. The prognostic significance of pseudomyxoma ovariilike posttherapeutic alteration is not clear, but it appears to be an uncommon manifestation of androgen ablation therapy.

This condition adds to the spectrum of androgen associated changes in prostate adenocarcinoma. Recognition of the appearance enables pathologists to avoid an erroneous diagnosis of mucinous adenocarcinoma and to be aware of its significance as a marker of treated adenocarcinoma, especially if it is the only pathological change remaining in the prostate.

TREVOR W BEER

Department of Pathology, Royal Hospital Haslar, Gosport, Hampshire, UK

JEFFREY M THEAKER

Department Histopathology, Southampton General Hospital, Southampton, Hampshire, UK

DAVID N TULLOCH

Department of Urological Surgery, Royal Hospital Haslar, Gosport, Hampshire, UK

- 1 Montironi R, Schulman CC. Pathological changes in prostate lesions after androgen manipulation. *J Clin Pathol* 1998;51:5-12.
- 2 Tien-Anh T, Jennings TA, Ross JS, et al. Pseudomyxoma ovariilike posttherapeutic alteration in prostate adenocarcinoma. *Am J Surg Pathol* 1998;22:347-54.
- 3 Civantos F, Marcial MA, Banks ER, et al. Pathology of androgen deprivation therapy in prostate carcinoma: a comparative study of 173 patients. *Cancer* 1995;75:1634-41.
- 4 Civantos F, Soloway MS. Prostatic pathology after androgen blockade: effects on prostatic carcinoma and on nontumor prostate. *Adv Anat Pathol* 1996;3:259-65.

Inexpensive and reliable haemoglobin colour scale

As judged by years of African village surveys and therapeutic trials, it is possible to reduce perhaps 10-fold the prevalence of moderate and severe anaemia due to iron deficiency or to infections sensitive to available chemoprophylaxis or chemotherapy. The advent of the inexpensive and reliable haemoglobin colour scale^{1,2} may make it possible for such repeated haemoglobin estimations to be made at the village level.

The suitably trained village health worker, always making the tests under appropriate supervision, will be able to diagnose moderate and severe anaemia early, follow up to sustained recovery, provide health education to reduce the prevalence of preventable anaemia, and keep an eye on those villagers in whom the anaemia is likely to recur.³

The referral of the anaemic villager only once or twice to a clinic where there is a more precise estimate of the haemoglobin will check the validity of the haemoglobin test performed in the village.

Referral will also make possible other laboratory tests indicated as part of the primary health care of anaemic patients in remote villages.

E TOPLEY

1 Wickens Place, High Street, West Malling, Kent ME19 6NB, UK

- 1 Goodall HB. Inexpensive and reliable haemoglobin colour scale [letter]. *J Clin Pathol* 1998;51:416.
- 2 Lewis SM. Reply [letter]. *J Clin Pathol* 1998;51:416.
- 3 Topley E. *Anaemia in rural Africa: community support for control activities where malaria is common*. Cambridge, UK: FSG MediMedia, 1998.

Adenocarcinoma of the small bowel, coeliac disease, and lymphocytic gastritis

In recent correspondence in this journal, Mason and Dunk¹ reported one such case and referred to two others reported by MacGowan *et al.*² A few years ago, we described a similar case,³ which we summarise as follows.

A 49 year old woman had suffered from abdominal cramps for eight months without relief from homeopathic treatment. In November 1991, gastroscopic biopsies were done in another institution and a diagnosis of ulcerative gastritis was made. In March 1992, gastroduodenal biopsies examined in the same laboratory were considered to show chronic duodenitis and lymphocytic gastritis. Despite anti-H₂ histamine treatment, the patient's course worsened (14 kg weight loss in nine months). On admission in April 1992 a circumferential jejunal mass was found on computed tomography and small bowel contrast. This segment was resected and showed a circumferentially ulcerated 4x5 cm tumour invading the mesentery. Histologically it was a poorly differentiated adenocarcinoma extending into the mesentery without lymph node metastasis. The intestinal mucosa at a distance from the tumour showed subtotal and total villous atrophy, highly suggestive of coeliac disease. The presence of antigliadin antibodies strengthened the diagnosis. Review of the slides of the biopsies examined elsewhere in March 1992 revealed subtotal to total villous atrophy of the duodenal villi consistent with coeliac disease, associated with lymphocytic gastritis. After a few weeks on a gluten-free diet the condition of the patient improved.

Since that time she has moved to Paris where follow up showed her to be in good health, without signs of recurrence of the tumour. Repeat biopsies showed partial villous atrophy with increased intraepithelial lymphocytes in 1994, and a nearly normal histological appearance with a localised slight to moderate increase in intraepithelial lymphocytes in 1996 (kindly reported to us by

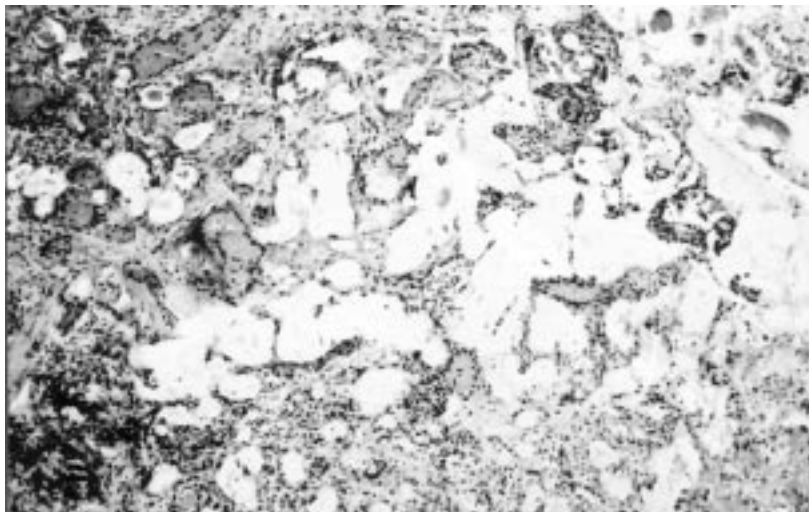


Figure 1 Pools of acellular mucin dissecting through the prostate stroma.

Prof J C Rambaud and Dr A Lavergne, Hôpital Lariboisière, Paris).

Thus our case showed similarities with the one described by Mason and Dunk (that is, an association with lymphocytic gastritis). As with MacGowan's two patients, coeliac disease was also diagnosed in our case on the operative specimen but, in contrast to those cases, the problem here was not the unmasking of coeliac disease but a misdiagnosis, and the error on behalf of both clinician and pathologist resulted in a delay of more than one year after the onset of symptoms before suitable treatment was begun.

SVEN WIDGREN

*Institut neuchâtelois d'anatomie pathologique, Les
Cadolles 4, CH 2000 Neuchâtel, Switzerland*

SERGE LEYVRAZ

*Centre Pluridisciplinaire d'Oncologie, CHUV-Niveau
10, CH 1011 Lausanne, Switzerland*

- 1 Mason CH, Dunk AA. Duodeno-jejunal adenocarcinoma and coeliac disease [letter]. *J Clin Pathol* 1997;50:619.
- 2 MacGowan DJL, O'B Hourihane D, Tanner WA, O'Morain C. Duodeno-jejunal adenocarcinoma as a first presentation of coeliac disease. *J Clin Pathol* 1996;49:602-4.
- 3 Gander M, Leyvraz S, Widgren S. Adenocarcinoma of the small bowel associated with coeliac disease. *Bull Suisse Cancer* 1993;13:141-3.

Book reviews

Intra-operative Diagnosis of CNS Tumours. T H Moss, J A R Nicoll, J W Ironside. (£145.00.) Oxford University Press, 1997. ISBN 0 340 67737 6.

This is a splendid book. Not just because of its extensive coverage of this area, but more especially because of the first general chapters that precisely place the role of smear preparations and frozen sections and address the logistics of both procedures—easy to overlook this, but so important in practice. In addition, a wealth of clinical information is thrown in, to help interpret slides. It could be argued that most neuropathologists (for whom this book is intended) ought to know most of this, but to see all this information assembled and placed in perspective is helpful for anyone, not just registrars or pathologists who deal with neuropathological samples on a less than regular basis.

I have only two small points to raise. One concerns the small number of high magnifications among the otherwise high quality illustrations. It is a little surprising that, for a technique that focuses on cellular detail, not more (very) high magnifications were included.

Second, the categorised layout of the book is very clear, but suggests more differences between some entities than exist in reality. The astrocytic tumours are a case in point. It can be notoriously difficult to distinguish between astrocytoma and anaplastic astrocytoma on smear preparations. Also, there is a difference in the ease with which mitotic figures are identified in smears and in sections. Whether this influences grading of such tumours has not been investigated. The authors do mention some of these potential problems, but the point could have been

made a little more forcibly, as it concerns a very important and frequently occurring problem. These reservations are, however, minor points and this eminently practical book can be warmly recommended to (neuro)pathologists, who are called upon to make intraoperative diagnoses.

PAUL VAN DER VALK

Russell & Rubinstein's Pathology of Tumors of the Nervous System (6th edition). Edited by D D Bignar, R E McLendon, J M Bruner. (£265.00; two volume set.) Edward Arnold, 1998. ISBN 0 340 58113 1.

This title has been a classic in the neuropathology literature for many decades—the previous edition in 1989 was a single author textbook, and with the death of Professor Rubinstein the title has been taken over by a multi-author team headed by three distinguished North American neuropathologists. Their task has not been easy since there have been enormous advances in the pathology of brain tumours over the past decade, encompassing major changes in the classification and, inevitably, the explosion of data from molecular biological studies. These changes have been wholeheartedly embraced by the editors and this title is now contained in two volumes, comprising 23 chapters ranging from epidemiology to cell biology and molecular genetics, immunology and detailed chapters on individual tumour groups. The chapter titles have substantially altered from the previous edition to encompass recent changes in classification, and it is interesting to see how some of Professor Rubinstein's war horses—for example, the angioblastic meningioma—have vanished without trace.

These volumes contain a wealth of information that will be of great interest to all neuropathologists and to those with an interest in brain tumours including neurosurgeons, oncologists, radiotherapists, and basic neuroscientists. In our department, which has a major commitment to brain tumour diagnosis, the book has proven invaluable as a reference text and as stimulation for further reading and research. The text is usefully supplemented by illustrations and tables with occasional line diagrams in the earlier chapters. Some of the illustrations are of poor quality and this is acknowledged in the copy sent for review in an apology from the publishers. The problems with reproduction in my copies particularly involved volume 2, where some of the colour images (for example Fig 15.23) were uninterpretable. However, it is anticipated that this error will be rapidly corrected and in volume 1 the figures were of a satisfactory standard, including many colour illustrations of macroscopic and microscopic pathology and good reproductions of neuroradiology. The index is excellent but the references are not subdivided in line with the subdivision of chapters, making it rather difficult to locate references in the lengthier chapters.

This major work is not primarily intended as a bench book for diagnostic neuropathologists and indeed it is not always helpful in this respect. However, as a comprehensive and authoritative source of information on virtually all aspects of brain tumours, from genetics to therapeutics, it is an essential purchase for any department involved with brain tumour diagnosis.

JAMES IRONSID

The Cambridge Encyclopedia of Human Paleopathology. A C Auterheide, C Rodriguez-Martin. (£75.00.) Cambridge University Press, 1998. ISBN 0 521 552023 6 (HB).

Humanity has lived with disease for all of our existence. Injuries and diseases have changed bones and teeth since prehistoric times. However, the birth of paleopathology is attributed to the German naturalist Johann Friederich Esper, who correctly diagnosed an osteosarcoma in a cave bear's femur in 1774. Human paleopathology is the study of disease in ancient populations by the examination of human remains. Physicians and anthropologists have now practised paleopathology for more than a century. This superbly produced book deals with the subject of human paleopathology and is likely to become a major reference work for those interested in the identification of human remains. The quality of the specimen photographs is very high and the specimens selected for illustration are all good examples, coming from museums in the United States, Spain, and Chile. The book covers almost all diseases that produce macroscopic changes in bones, teeth, and soft tissues and survive in archaeological specimens. Soft tissues are included because they are commonly present in mummified remains. The book also includes sections on other conditions relevant to the study of ancient populations. For example, it explains how the unique geographical population pattern of gene frequencies of Duffy red blood cell antigens becomes comprehensible when the role of these antigens in the vivax malarial life cycle is understood. Clearly paleopathology has become a highly specialised field and few British pathologists are ever likely to view such material. However, as a book to be read for the sake of interest alone, I would wholeheartedly recommend this volume.

J R SALISBURY

CD-ROM

Haematology Library: Basic Principles and Practice, 2nd ed (CD-ROM). R Hoffman, E J Benz Jr, S J Shattil, B Furie, H J Cohen, L E Silberstein, eds. Churchill Livingstone, 1996. (£199.00.) ISBN 0 443 07669 3.

Medical knowledge has expanded so fast that textbooks now require one to have Arnold Schwarzenegger's physique to lift them off the shelf. Furthermore even with the best indexes, multivolumed books of several thousand pages are difficult to use, and take so long to get published they are partly out of date by the time they appear.

A solution to these problems is the CD-ROM. Large "books" presented as CD-ROMs are familiar to anyone who has a computer—even very large texts like the *Encyclopaedia Britannica* comfortably fit onto one or two disks. Other advantages of CD-ROMs are that some degree of multimedia can be included (such as video clips), and they should be cheaper to produce and more capable of being updated regularly.

Churchill Livingstone's haematology offering is part of a library of CD-ROM texts on various subjects. The haematology CD-ROM includes the entire 1995 edition of the haematology textbook edited by Hoffman *et al.* In addition all Medline records since 1990 from 16 general medical and haematology journals are included, as well as hypertext links from every reference in the "textbook" to Medline, so they can be viewed. It is claimed there are nearly 89 000 Medline records in total.

I ran the CD-ROM on a Pentium 90 PC, with 4x CD player, and 16 MB of RAM, running Windows 3.11. (The instruction manual says it will run on a 486 machine with 4 MB of RAM.) I also ran it on a P166 with 32 MB RAM, running Windows 95, with no problems.

Installation is easy, but reading the written manual and doing the quick-start tutorial lasting 15 to 20 minutes are essential to make good use of the facilities. The search screens for the book and for Medline are icon based, and for anyone familiar with PCS and Windows, straightforward and intuitive to use. Searches happened quickly enough with my P90/Windows 3.11, but were appreciably faster using the P166/Windows 95 combination.

Searches are performed using key words and search operators like "and," "or," and "not." As you begin to type, the computer prompts you by providing a list of likely words, including misspellings, so you rarely need to finish typing, and you choose from the list by clicking with the mouse. As you add more words to your search, a box appears showing how you are narrowing this down, and how many references are available. This is useful as it allows backtracking if you are not turning up any references using the initial keywords.

Searches are done either in the textbook or in Medline and transfer is straightforward between them. If you wish to view references from the textbook, a simple click with the mouse allows appropriate text to be displayed from Medline; the same is true for diagrams and pictures. There is also a bookmark facility to allow you to return to specific pages quickly, and you can highlight particular parts of the text which then can be searched for as a group. Notes can be added to the textbook and saved, and any part of the text including notes, diagrams, and pictures is easily printed.

There are caveats. This version of the "textbook" is three years old, and I would be interested to know how often it will be updated, and if in future updates will happen more quickly than with conventional books. (There are CD-ROM updates for Medline provided on an annual basis which you pay for, but why not provide updates on-line?) Additionally many people will find looking at a VDU screen rather tiring, and although there is a zoom facility for pictures and diagrams, there is no facility to change text font or size which could usefully be added.

However, I firmly believe that digitally stored information is the way forward for reference material. Whether in future this will be on CD-ROM or its successor the DVD-ROM, or whether it will be by expansion of

on-line services (too slow at present, but will improve), only time will tell. For the time being this offering is a versatile tool which I enjoyed using, and will continue doing so. The only thing to lament will be my muscle atrophy from not having to lift haematology textbooks from shelves!

ALLISTAIR N STARK

Notices

Medical decision making: intuition or analysis?

*University of Sheffield
Medical School, UK*

18 November 1998

A one day symposium on many aspects of medical decision making including the cytology diagnosis of breast cancer, quality control of decision making and computer decision support. Aimed at all medical doctors including pathologists. Cost £50 including coffee, lunch and tea. 5 CME points.

For more information and registration contact Carole Stenton, Short Course Office, Faculty of Medicine, University of Sheffield Medical School, Beech Hill Road, Sheffield S10 2RX. Tel +44 (0)114 271 3439; fax +44 (0)114 276 8490; email: c.stenton@sheffield.ac.uk

Symposium on Breast Pathology

London, 27-28 November 1998

Symposium on Pulmonary Pathology

Swansea, 16-17 April 1999

Symposium on Gynaecological Pathology

Sheffield, 10-11 September 1999

Symposium on Urological Pathology

London, 26-27 November 1999

British Division of the International Academy of Pathology. Further details from: Mrs C Harris, PO Box 73, Westbury on Trym, Bristol BS9 1RY. Tel +44 (0)117 907 7940; fax +44 (0)117 907 7941; email: bdiap@cablenet.co.uk

An Introduction to Evidence-Based Medicine for Haematologists

*Association of Clinical Pathologists,
Portland Place, London*

2 December 1998

A one day workshop for up to 16 participants. Areas to be covered include framing a clinical question, developing a research strategy, and numbers needed to treat. Registration fee £120 for ACP members, £130 for non-members.

Further details from: Dr M J Galloway, Consultant Haematologist, Bishop Auckland Hospital, County Durham DL14 6AD. Tel 01388 454061; fax 01388 454128

1st International Congress on the Sentinel Node in Diagnosis and Treatment of Cancer

Amsterdam, The Netherlands

7-10 April 1999

Further details from: Congrex Holland bv, PO Box 302, 1000 AH Amsterdam, The Netherlands. Tel +31 20 5040 200; fax +31 20 5040 225; email: sennode99@congrex.nl

Practical Pulmonary Pathology

*Imperial College School of
Medicine, London*

14-15 April 1999

Further details from: Professor B Corrin, Brompton Hospital, London SW3 6NP, UK. Fax +44 (0)171 351 8293; email: b.corrin@ic.ac.uk

Cellular and Molecular Pathology Update

University of Liverpool, UK

16-19 June 1999

Further details from: Professor C S Foster, Department of Cellular and Molecular Pathology, University of Liverpool, Duncan Building, Daulby St, Liverpool L69 3GA. Tel +44 (0)151 706 4480; fax +44 (0)151 706 5883; email: christopher.foster@liv.ac.uk



Inexpensive and reliable haemoglobin colour scale.

E Topley

J Clin Pathol 1998 51: 878

doi: 10.1136/jcp.51.11.878b

Updated information and services can be found at:

<http://jcp.bmj.com/content/51/11/878.2.citation>

Email alerting service

These include:

Receive free email alerts when new articles cite this article. Sign up in the box at the top right corner of the online article.

Notes

To request permissions go to:

<http://group.bmj.com/group/rights-licensing/permissions>

To order reprints go to:

<http://journals.bmj.com/cgi/reprintform>

To subscribe to BMJ go to:

<http://group.bmj.com/subscribe/>