

## Pancreatic cancer and fibrinogen storage disease

J M Radhi, B E Lukie

### Abstract

**Background**—Ductal adenocarcinoma is the most common type of pancreatic carcinoma while squamous, carcinosarcoma, sarcoma, giant cell carcinoma, and clear cell types are all rare. Hepatocellular fibrinogen storage disease is also an uncommon disorder which may be associated with hepatocellular carcinoma. Two cases of pancreatic carcinoma were encountered in a family with fibrinogen storage disease, further raising the possibility of a predilection to malignancy in this unusual disorder. The tumour in one case was of the rare clear cell type. These two cases are the basis for this report.

**Methods**—Sections were cut from retrieved paraffin embedded tissue and stained for routine histology. Immunohistochemistry using the avidin-biotin technique was applied for the expression of the markers p53 (D07), carcinoembryonic antigen (CEA), c-erbB-2, epithelial membrane antigen (EMA), and  $\alpha$ -fetoprotein (AFP).

**Results**—Both cases were adenocarcinoma of pancreatic ductal origin. The tumour in one case showed features of a clear cell carcinoma. The tumour cells expressed p53, CEA, and EMA immunoreactivity and were negative for c-erbB-2 and AFP.

**Conclusions**—Hepatocellular fibrinogen storage disease is rare and has been described in association with chronic hepatitis, cirrhosis, and rarely with hepatocellular carcinoma. This represents the first report of its association with carcinoma outside of the liver.

(*J Clin Pathol* 1998;51:865-867)

Keywords: carcinoma; pancreas; fibrinogen storage disease

The aetiology of pancreatic carcinoma is unknown, although some important associations have been recognised. Cases have been described in families,<sup>1</sup> in patients with Peutz-Jeghers syndrome,<sup>2</sup> and in workers exposed to  $\beta$  naphthylamine or benzidine.<sup>3</sup> Diet and cigarette smoking appear to be major risk factors for the development of pancreatic cancer.<sup>4</sup>

In this report we describe a family we recently discovered with fibrinogen storage disease, a rare disorder of hepatic endoplasmic reticulum storage. Although our knowledge of this disorder is limited, affected individuals may be at increased risk of developing hepatitis, cirrhosis, and hepatocellular carcinoma.<sup>5</sup> The presence of an extrahepatic carcinoma in fibrinogen storage disease is unusual and we have not encountered any other

reports of this association. However, it further supports our concern that fibrinogen storage disease may carry a significant risk of malignancy.

### Methods

Tissues were obtained at necropsy or operation, fixed in 10% buffered formalin, and processed routinely. Sections were cut at 5  $\mu$  and stained with haematoxylin and eosin, periodic acid-Schiff (PAS) with and without diastase digestion, and oil red O. Oil red O stain was performed on formalin fixed tissue by frozen sectioning technique.<sup>6</sup> Immunohistochemical stainings were performed with the avidin-biotin technique<sup>7</sup> using standard procedures and the following antibodies: monoclonal cytokeratin low and high molecular weight, carcinoembryonic antigen (CEA), and c-erbB2 from Dako; p53 suppressor gene (D07), which identifies both wild and mutant type, from Novacastra Vector Labs. Breast tissue, skin, and gut tissue were used as positive controls for p53, c-erbB2, cytokeratin, and CEA. Negative controls, in which the primary antibody was withheld, were also run simultaneously.

### Clinical results

A family was recently encountered with hyaline hepatic inclusions affecting at least four of its members (fig 1). These inclusions were PAS negative and were confirmed to be fibrinogen by immunohistochemistry in two cases. The father had died earlier at age 67 years from infective endocarditis and was found to have an unsuspected pancreatic carcinoma at necropsy. One son developed deep jaundice, abdominal pain, and weight loss at 37 years of age. Investigations showed a haemoglobin of 136 g/litre (normal 120-145), bilirubin 171  $\mu$ mol/litre (2-18), alkaline phosphatase 776 IU/litre (normal 30-110), and aspartate transaminase 110 IU/litre (10-40); hepatitis B surface antigen was negative. On abdominal ultrasonography there was a dilated intrahepatic and extrahepatic biliary tree, while percutaneous transhepatic cholangiography showed obstruction at the lower common bile duct. At laparotomy the tumour appeared to involve the pancreas and duodenum. A cholecystojejunostomy was performed. Following surgery the patient developed major abdominal bleeding. Ligation of the hepatic artery was performed but his condition deteriorated and he died after the surgery.

### Pathological findings

A necropsy performed on the proband revealed vegetations on the mitral and aortic valves with systemic embolisation to brain, bone, spleen,

College of Medicine,  
University of  
Saskatchewan,  
Saskatoon,  
Saskatchewan, Canada  
Department of  
Pathology  
J M Radhi

Department of  
Medicine  
B E Lukie

Correspondence to: Dr J M Radhi, Department of Pathology, College of Medicine, University of Saskatchewan, Royal University Hospital, 103 Hospital Drive, Saskatoon, Saskatchewan S7N 0W8, Canada.

Accepted for publication  
10 December 1997

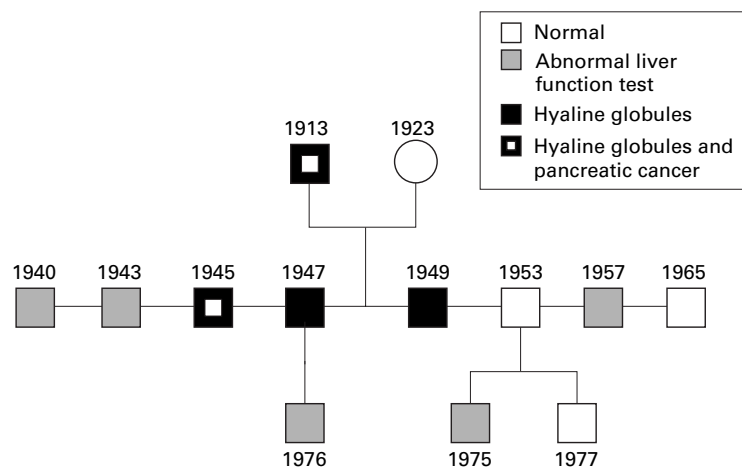


Figure 1 Pedigree of family with fibrinogen storage disease and pancreatic carcinoma.

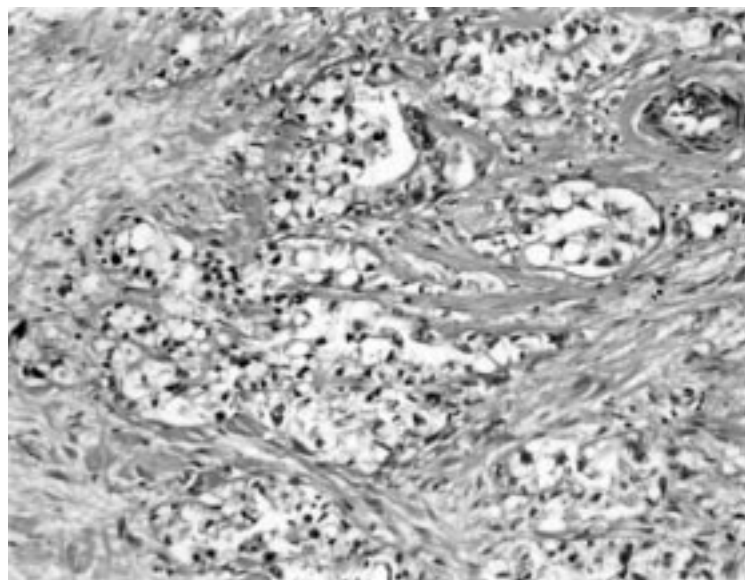


Figure 2 Photomicrograph of pancreatic clear cell carcinoma.

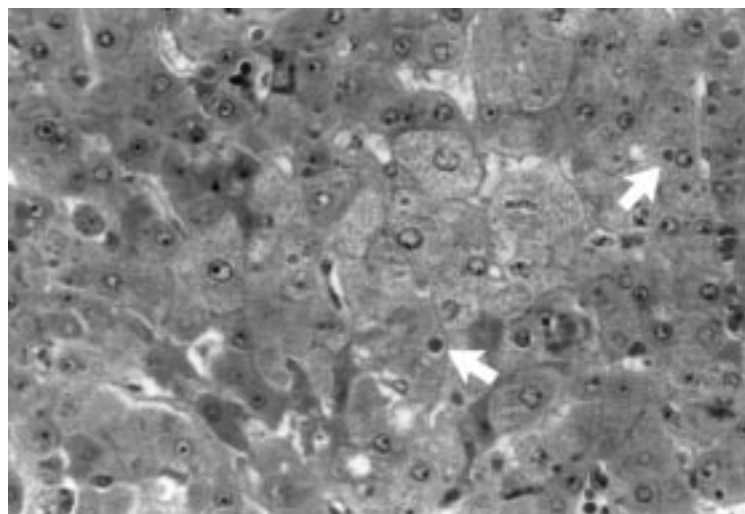


Figure 3 Photomicrograph showing intracellular hyaline globules (arrows).

thyroid, and kidneys. The pancreas was involved in a hard diffuse white mass that also involved the peripancreatic lymph nodes.

The major finding at the necropsy of the son was deep jaundice with a pancreatic tumour

extending to the common bile duct. There was thrombosis of the hepatic artery and infarction of the liver. The cholecystojejunostomy was patent.

#### Microscopic examination and immunohistochemistry

Both cases showed moderately differentiated adenocarcinoma of pancreatic ductal origin associated with ductal hyperplasia and carcinoma in situ changes. In the son, the tumour was composed of cells with empty looking cytoplasm and small nuclei. The cells were arranged in solid trabeculae and showed a pseudoacinar pattern (fig 2). These cells contained glycogen, as demonstrated by PAS stain, and were negative for mucin and fat. The tumour cells expressed immunoreactivity to CEA, epithelial membrane antigen (EMA), and low molecular weight keratin. Moderate nuclear staining for p53 was expressed in 20–30% of tumour cells. Immunoreactivity for c-erbB-2, a neomarker of poor prognosis, and  $\alpha$ -fetoprotein (AFP) were negative. The liver showed intracytoplasmic hyaline globules (fig 3) which were negative or weakly positive for PAS after diastase. These globules were positive for fibrinogen marker and negative for  $\alpha$ 1-antitrypsin, immunoglobulins, and complements.

#### Discussion

Pancreatic carcinoma accounts for 22% of deaths from gastrointestinal cancer. Its prognosis is poor, with fewer than 20% of patients surviving one year after diagnosis. Considerable progress has been made in our understanding of the pathogenesis, diagnosis, and staging of this disease.<sup>4,8</sup> The efficacy of surgical and non-surgical approaches to its treatment and palliation are well recognised. The incidence of pancreatic carcinoma peaks in the seventh decade, with a slight male predominance. Pain and jaundice are often the presenting symptoms. Unfortunately, initial symptoms such as abdominal discomfort, weight loss, nausea, and vomiting are not specific, and may not lead to early diagnosis. A recent onset of diabetes or migratory superficial thrombophlebitis may be helpful clues if present. Most carcinomas of the pancreas are of ductal origin and are commonly located in the head of the pancreas and less commonly in the body or tail.<sup>4</sup>

The aetiology of pancreatic cancer remains unknown. There may be a hereditary factor, as the disease has been described in families,<sup>1,8–11</sup> and in patients with Peutz–Jeghers syndrome.<sup>2</sup> Cigarette smoking has been shown to be a major risk factor in many epidemiological studies and the risk increases with the amount smoked. Several studies have suggested a relation between meat and fat consumption and the development of pancreatic carcinomas.<sup>4</sup> Dietary protein and fat have also been shown to promote pancreatic carcinogenesis in experimental animals. The role of alcohol and coffee consumption in the aetiology of pancreatic cancer is controversial. Occupational exposures have been implicated as a risk factor for

pancreatic cancer. An increased incidence has been reported in metal, mine, sawmill, and coke plant workers and in workers exposed to solvents, petroleum compounds,  $\beta$  naphthylamine, benzidine, and transformer fluid containing polychlorinated biphenyls.<sup>8</sup> There is a higher risk in patients with chronic familial pancreatitis and chronic calcific pancreatitis. Although the association of pancreatic cancer and diabetes mellitus is also well known, this may reflect endocrine insufficiency as a result of the tumour itself. A possible diabetogenic factor associated with pancreatic cancer is suggested by improved glucose tolerance after tumour resection.<sup>4</sup>

Hepatocellular fibrinogen storage disease is quite analogous to  $\alpha$ 1-antitrypsin deficiency and fulfils the criteria for an endoplasmic reticulum storage disease. The pathogenesis of the disease suggests a molecular abnormality hindering the translocation of the abnormal protein from the rough to the smooth endoplasmic reticulum.<sup>12-13</sup> We discovered a family with this disorder when one member underwent liver biopsy for the investigation of a persistently raised transaminase. Four members of the family were found to have intracytoplasmic hyaline inclusions within their hepatocytes. The natures of these globules in two members were confirmed by immunohistochemistry as fibrinogen. Both the father and one son were found to have pancreatic carcinoma. This is the first report of a possible association between this disorder and pancreatic carcinoma. This may of course be familial and have no relation to the fibrinogen storage disease. However, such unusual associations may be significant and it is important to draw attention to them.

These cancers expressed keratin of simple epithelia, epithelial membrane antigen, and carcinoembryonic antigen. P53 immunoreactivity was detected in 20–30% of tumour cell nuclei. Mutations in p53 tumour suppressor gene are the most common genetic alterations identified in human neoplasia. Mutations or accumulation of p53 are detected in about half of pancreatic cancer cases. Mutant p53 may cooperate with activated ras oncogenes in neoplastic transformation.<sup>14-15</sup> Staining for c-erbB-2 oncoprotein was negative. The presence of this oncoprotein had been regarded as a useful indicator of the prognosis of carcinoma of breast, ovary, uterus, and gastrointestinal tract.<sup>16-17</sup> Pancreatic cancer in the second case was widely disseminated and involved the duodenum and the common bile duct. The tumour was of clear cell type. Variants of pancreatic carcinomas include adenosquamous carci-

noma, oncocytic carcinoma, signet ring carcinoma, mucinous carcinoma, anaplastic carcinoma, and clear cell carcinoma.<sup>18</sup> Clear cell pancreatic carcinoma is a distinct but rare carcinoma and needs to be differentiated from metastatic renal cell carcinoma and other carcinomas with clear cell changes (such as hepatic, pulmonary, and prostatic carcinomas), and from melanoma and clear cell sarcoma. The lack of other primary sites on thorough necropsy examination and the presence of ductal pancreatic hyperplasia and neoplasia are in favour of a primary pancreatic origin in this case. The behaviour of clear cell carcinoma is unknown as only a few cases have been reported. However, this case had a poor outcome.

In conclusion, the two cases of pancreatic carcinoma we encountered in a family with fibrinogen storage disease raise the possibility that this disorder of hepatic protein secretion may be associated with a significant malignant risk. Owing to the rarity of the condition, proving such an association will be difficult.

- Ehrenthal D, Haeger L, Griffin T, *et al.* Familial pancreatic adenocarcinoma in three generations. A case report and review of the literature. *Cancer* 1987;59:1661–4.
- Bowlby LS. Pancreatic adenocarcinoma in an adolescent male with Peutz-Jeghers syndrome. *Human Pathol* 1986;17:97–9.
- Longnecker DS. Pathology and pathogenesis of disease of the pancreas. *Am J Pathol* 1982;107:103–21.
- Warshaw AL, Castillo CF. Pancreatic carcinoma. *N Engl J Med* 1993;326:455–65.
- Ng IOL, Ng M, Lai ECS, *et al.* Endoplasmic storage disease of the liver: characterization of intracytoplasmic hyaline inclusions. *Histopathology* 1986;10:73–6.
- Sheehan DC, Hrapchuk BB. *Theory and practise of histotechnology*, 2nd ed. St Louis: CV Mosby, 1980:205.
- Hsa SM, Raine L, Fanger H. Use of avidin–biotin peroxidase complex (ABC) in immunoperoxidase techniques: a comparison between ABC and unlabelled antibody (PAP) procedure. *J Histochem Cytochem* 1981;29:577–80.
- Wanebo HJ, Vezeridis MP. Pancreatic carcinoma in perspective. *Cancer* 1996;78:580–91.
- Lynch H, Fitzsimmons, Smyrk TC, *et al.* Familial pancreatic cancer: clinicopathologic study of 18 nuclear families. *Am J Gastroenterol* 1990;85:1054–60.
- Dat NM, Sontag SJ. Pancreatic carcinoma in brothers. *Am Intern Med* 1982;97:282.
- Reimer RR, Fraumeni JF, Ozols RF, *et al.* Pancreatic cancer in father and son [letter]. *Lancet* 1977;i:911.
- Callea F, Brisigotti M, Fabgretti G, *et al.* Hepatic endoplasmic storage diseases. *Liver* 1992;12:357–62.
- Pfeifer U, Ormanns W, Oklinge O. Hepatocellular fibrinogen storage in familial hypofibrinogenemia. *Virchows Arch (Cell Pathol)* 1981;36:247–55.
- Digiuseppe JA, Hruban RH, Goodman SN, *et al.* Overexpression of p53 protein in a adenocarcinoma of the pancreas. *Am J Clin Pathol* 1994;101:684–8.
- Boschman CR, Stryker S, Reddy JK, *et al.* Expression of p53 protein in precursor lesions and adenocarcinoma of human pancreas. *Am J Pathol* 1994;145:1294–5.
- Fukushige SL, Matsubara KL, Yoshida M, *et al.* Localization of a novel v-erb B-related gene, c-erbB-2, on human chromosome 17 and its amplification in a gastric cancer cell line. *Mol Cell Biol* 1986;6:955–8.
- Wright C, Angus B, Nicholson S, *et al.* Expression of c-erbB-2-oncoprotein: a prognostic indicator in human breast cancer. *Cancer Res* 1984;44:2087–90.
- Kanai N, Nagaki S, Tanaka T. Clear cell carcinoma of the pancreas. *Acta Pathol Jpn* 1987;37:1521–6.



## Pancreatic cancer and fibrinogen storage disease.

J M Radhi and B E Lukie

*J Clin Pathol* 1998 51: 865-867  
doi: 10.1136/jcp.51.11.865

---

Updated information and services can be found at:  
<http://jcp.bmj.com/content/51/11/865>

---

	<i>These include:</i>
<b>References</b>	Article cited in: <a href="http://jcp.bmj.com/content/51/11/865#related-urls">http://jcp.bmj.com/content/51/11/865#related-urls</a>
<b>Email alerting service</b>	Receive free email alerts when new articles cite this article. Sign up in the box at the top right corner of the online article.

---

### Notes

---

To request permissions go to:  
<http://group.bmj.com/group/rights-licensing/permissions>

To order reprints go to:  
<http://journals.bmj.com/cgi/reprintform>

To subscribe to BMJ go to:  
<http://group.bmj.com/subscribe/>