

An unusual cutaneous manifestation of myelodysplastic syndrome: “pseudo-Koebner phenomenon”

R DasGupta, S A Fairham, C Womack, C Burton, M Sivakumaran

Abstract

An unusual and hitherto unreported complication of myelodysplastic syndrome is reported: the “pseudo-Koebner phenomenon.” The skin lesions were characterised by exuberant “fleshy” masses at the sites of intravenous cannulation and skin trauma, and by histological evidence of chronic inflammation with focal necrosis and abscess formation. No evidence of dermal infiltration by malignant haemopoietic cells was seen. The exact aetiopathology of the phenomenon is unclear but an inappropriate and exaggerated inflammatory response owing to aberrant mediator mechanisms that are known to occur in some cases of myelodysplastic syndrome may be implicated.

(*J Clin Pathol* 1998;51:860–861)

Keywords: myelodysplastic syndrome; cutaneous manifestation, pseudo-Koebner phenomenon

Various dermatopathic conditions including cutaneous vasculitis, pyoderma gangrenosum, neutrophilic dermatosis (Sweet’s syndrome), panniculitis, and erythema nodosum have been reported in association with myelodysplastic syndrome.^{1, 2} The cutaneous manifestations of this disorder may be broadly subdivided into specific and non-specific groups.¹ Specific lesions (“leukaemia cutis”), characterised by a dermal infiltrate of malignant haemopoietic cells, may be a herald sign of acute transformation and associated with poor prognosis.¹ Non-specific lesions have been well described, and usually result from infections, vasculitis, or neutrophilic dermatoses (for example, pyo-

derma gangrenosum, Sweet’s syndrome, erythema elevatum diutinum). We present the case of a patient with myelodysplastic syndrome who developed an unusual skin manifestation characterised by exuberant “fleshy” mass lesions at the sites of intravenous cannulation and skin trauma. We postulate that these lesions may have been caused by an inappropriate and exaggerated inflammatory response owing to aberrant mediator mechanisms that are known to occur in some cases of myelodysplastic syndrome.

Case history

A 55 year old man presented with symptoms of anaemia. Clinical examination revealed marked pallor but was otherwise unremarkable. A full blood count on admission showed pancytopenia (haemoglobin 5.5 g/dl, total white cell count 2.1×10^9 /litre with an absolute neutrophil count of 1.2×10^9 /litre, platelet count 47×10^9 /litre). A bone marrow aspirate and trephine biopsy confirmed the diagnosis of trilineage myelodysplastic syndrome. Myeloblasts constituted 10% of the nucleated bone marrow cells. The patient was initially treated with blood transfusion. He subsequently developed a large ulcerating mass in the centre of his sternal area at the site of previous sternal puncture. The mass lesion separated from the underlying muscles of the anterior chest wall during an attempt at wound debridement. He required further blood transfusions and it was noted that at each site of venous cannulation he grew large exuberant fleshy mass lesions (fig 1) following removal of the cannulas. Biopsies of the lesions on the chest wall and right forearm one month apart showed similar histological appearances (fig 2, A and B), being composed of unremarkable, non-specific inflammatory granulation tissue. Apart from some Gram positive cocci, assumed to be staphylococci, no specific organisms were identified and there were no malignant haemopoietic cells in the infiltrate. His condition deteriorated and he died of bronchopneumonia. Necropsy examination was not performed.

Discussion

Our case is unusual in that the cutaneous lesions were only produced in response to a traumatic injury (venous cannulation), akin to a Koebner phenomenon. This isomorphic response has been well described in psoriasis,³ lichen sclerosus,⁴ and lupus erythematosus⁵—all of which produce lesions similar to the primary condition in either apparently normal skin following trauma or exposure to strong sunlight

District Hospital,
Peterborough, UK:
Department of
Haematology
R DasGupta
S A Fairham
C Burton
M Sivakumaran

Department of
Histopathology
C Womack

Correspondence to:
Dr M Sivakumaran,
Department of Haematology,
District Hospital,
Peterborough PE3 6DA, UK.

Accepted for publication
14 July 1998

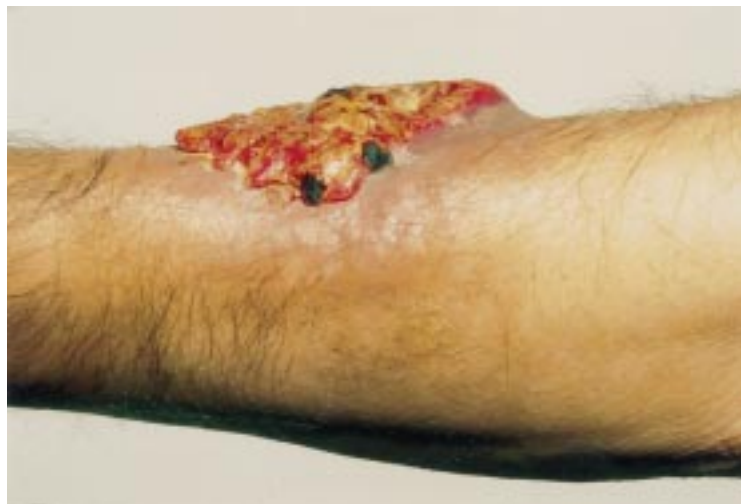

Figure 1 Lesion on the forearm at the site of intravenous cannulation.

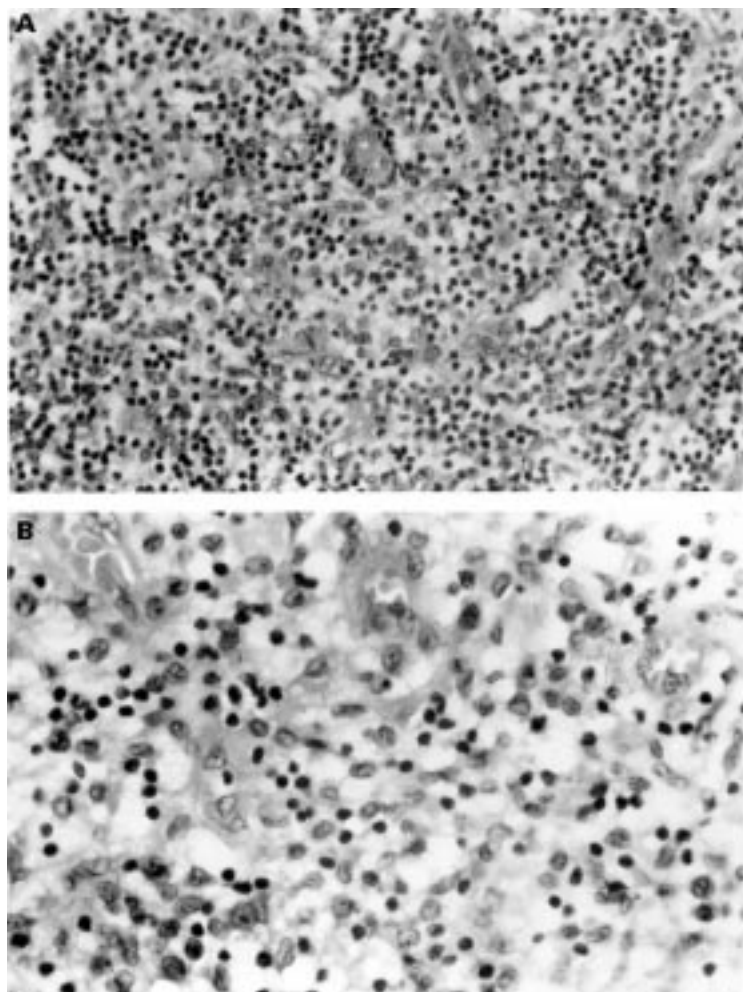


Figure 2 (A) Lesion from the chest wall; inflammatory granulation tissue with no specific features. (Haematoxylin and eosin; $\times 225$.) (B) Same lesion as in (A). Capillaries separated by macrophages, small mature lymphocytes, plasma cells, and neutrophils. No blast cells seen. (Haematoxylin and eosin; $\times 360$.)

or in areas of contact dermatitis, scars, and so on. However, this is the first report describing a Koebner-like phenomenon in a patient with myelodysplastic syndrome. The nature of the response cannot be called a true Koebner reaction because the tissue biopsies showed no evidence of haemopoietic cells; however, the typical production of a cutaneous lesion at the sites of trauma follows the pattern of an isomorphic response.

The lesions resemble grossly exuberant inflammatory masses, microscopy revealing characteristic features of an inflammatory response, with no evidence of infection by fungi or mycobacteria or infiltration by myeloblasts. Although no obvious blast cells were seen, it is possible that the myeloid cells, including mature granulocytes, present in the lesion were "aberrant," since these cells could be progeny of the clonogenic cell found in the myelodysplastic syndrome and thus be intrinsically abnormal. The absence of blast cells, however, rules out granulocytic sarcomata. In this respect, the lesions resemble the granulomatous eruptions in the two patients with myelodysplastic syndrome described by Vestey *et al*,⁶ the difference being that our patient's eruptions were in response to a trigger.

There is good evidence that upregulation of certain cytokines occurs in myelodysplastic syndrome, specifically interleukin (IL)-1, IL-6, tumour necrosis factor α (TNF- α), and granulocyte colony stimulating factor (G-CSF).⁷ Of these, IL-1 and TNF- α (and to an extent IL-6) are among those cytokines secreted by macrophages late in acute inflammation, their action being to upregulate adhesion molecules such as E-selectin, and to be chemotactic for further monocyte infiltration of the inflammatory site. In a report on a case of Sweet's syndrome, Reuss-Borst *et al* allude to the possible role of cytokines in the manifestation of cutaneous lesions in myelodysplastic syndrome.⁸ Indeed, the nature of this exaggerated localised response seems to draw together mediators characteristically seen in inflammation and cytokines shown to be increased in patients with myelodysplastic syndrome. The disordered monocyte/macrophage function seen in myelodysplastic syndrome may lead to a background of persistent immune stimulation, on which endogenous or exogenous triggers can precipitate a cutaneous response; hence the macrophage could play a pivotal role, as suggested by Hamblin,² in coordinating the response to foreign stimuli.

The role of the complement cascade in inflammation is well established, and the normal regulation of inflammatory responses involves a series of complement regulatory proteins (for example, C1 inhibitor, C4 binding protein), transforming growth factor β , and prostaglandin E2 among others. The deposition of IgG, IgM, C3, and C1q in the epidermis of a patient with bullous pemphigoid associated with myelodysplastic syndrome⁹ further points to the inflammatory nature of the cutaneous reactions seen in this condition.

How these cytokines and inflammatory mediators interact and effect their responses to produce the cutaneous lesions remains unclear, however. Detailed analysis of the cytokine profiles of the cutaneous lesions in myelodysplastic syndrome may provide valuable insights into the mechanisms involved in the pathogenesis of various extramedullary manifestations of this condition.

- Aractingi S, Bachmeyer C, Miclea J, *et al*. Unusual specific cutaneous lesions in MDS. *J Am Acad Derm* 1995;33:187-91.
- Hamblin TJ. Immunological abnormalities in myelodysplastic syndromes. *Semin Hematol* 1996;33:150-62.
- Eyre RW, Krueger GG. The Koebner response in psoriasis. In: Roenigk HH, Maibach HI, eds. *Psoriasis*. New York: Marcel Dekker, 1985:105.
- Todd P, Halpern S, Kirby J, *et al*. Lichen sclerosis and the Koebner phenomenon. *Clin Exp Dermatol* 1994;19:262-3.
- Ueki H. Koebner phenomenon in lupus erythematosus. *Hautarzt* 1994;45:154-60.
- Vestey JP, Turner M, Biddlestone L, *et al*. Disseminated cutaneous granulomatous eruptions associated with MDS and acute myeloid leukaemia. *Clin Exp Dermatol* 1993;18:559-63.
- Koike M, Ishiyama T, Tomoyasu S, *et al*. Spontaneous cytokine overproduction by peripheral blood mononuclear cells from patients with myelodysplastic syndromes and aplastic anaemia. *Leukaemia Res* 1995;19:639-44.
- Reuss-Borst MA, Pawelec G, Saal JG, *et al*. Sweet's syndrome associated with myelodysplasia: the possible role of cytokines in the pathogenesis of the disease. *Br J Haematol* 1993;84:356-8.
- Modiano P, Reichert S, Barbaud A, *et al*. Bullous pemphigoid in association with cutaneous lesions specific to a myelodysplastic syndrome. *Br J Dermatol* 1997;136:402-5.



An unusual cutaneous manifestation of myelodysplastic syndrome: "pseudo-Koebner phenomenon".

R DasGupta, S A Fairham, C Womack, et al.

J Clin Pathol 1998 51: 860-861
doi: 10.1136/jcp.51.11.860

Updated information and services can be found at:
<http://jcp.bmj.com/content/51/11/860>

Email alerting service

These include:

Receive free email alerts when new articles cite this article. Sign up in the box at the top right corner of the online article.

Notes

To request permissions go to:
<http://group.bmj.com/group/rights-licensing/permissions>

To order reprints go to:
<http://journals.bmj.com/cgi/reprintform>

To subscribe to BMJ go to:
<http://group.bmj.com/subscribe/>