

Detection of cytomegalovirus in upper gastrointestinal biopsies from heart transplant recipients: comparison of light microscopy, immunocytochemistry, in situ hybridisation, and nested PCR

S W Muir, J Murray, M A Farquharson, D J Wheatley, A R McPhaden

Abstract

Aim—To establish the diagnostic value of in situ hybridisation and the nested polymerase chain reaction (PCR) in detecting clinically relevant cytomegalovirus (CMV) infection in upper gastrointestinal biopsies from heart transplant patients.

Methods—Test sensitivity and specificity for detection of CMV early gene RNA by in situ hybridisation and CMV intermediate early gene by PCR were established and then compared with haematoxylin and eosin (H&E) and immunocytochemical detection of CMV in order to establish the best pathological diagnostic approach. All investigations were carried out on formalin fixed, paraffin embedded tissue.

Results—Nested PCR had the highest test sensitivity, followed by in situ hybridisation and immunocytochemistry with the same sensitivity; H&E had the lowest. H&E and immunocytochemistry were the most specific but both had a significant false negative rate which was less of a problem with PCR. However, PCR gave no other diagnostic information, and in situ hybridisation was no better than immunocytochemistry. Both in situ hybridisation and PCR were technically complex and more expensive.

Conclusions—H&E and immunocytochemistry represent the best initial screen for CMV and other diseases in upper gastrointestinal biopsies from heart transplant patients. If H&E and immunocytochemistry were negative, nested PCR could significantly increase the diagnostic yield of clinically relevant CMV infection. In situ hybridisation appeared to have no advantages and some drawbacks compared with immunocytochemistry and PCR.

(*J Clin Pathol* 1998;51:807-811)

Keywords: cytomegalovirus; polymerase chain reaction; heart transplantation

Cytomegalovirus (CMV) is one of the most important pathogens in solid organ transplantation patients, including orthotopic heart transplant recipients, particularly during the early post transplant period.^{1 2} Possible sources of infection include the graft, transfused blood

or blood products, and infection of the recipient before transplantation. Clinically the presence of end organ disease is an important criterion for instigating antiviral treatment in heart transplant patients, whose upper gastrointestinal tract is commonly involved.³ This site is easily investigated by endoscopy; however, since the gross appearances of CMV infection are not diagnostic, histopathological detection of CMV in biopsies is often undertaken. This diagnostic activity, comprising light microscopic examination of haematoxylin and eosin (H&E) stained sections and immunocytochemistry, has a significant false negative detection rate.⁴ Polymerase chain reaction (PCR) for detection of CMV DNA and in situ hybridisation for detection of intracellular CMV RNA are two techniques that can be applied to upper gastrointestinal biopsies in a histopathology laboratory to increase the diagnostic yield. Several recent studies of liver, kidney, bone marrow, and intestinal transplant patients have shown that PCR is more sensitive than other techniques in detecting CMV.⁴⁻⁷ However, there is also evidence that nested PCR may be overly sensitive as a clinical diagnostic tool, particularly when used to detect viruses that can establish latency.⁴ CMV RNA detection by in situ hybridisation could help to overcome this drawback.⁸ Furthermore, in situ hybridisation may detect CMV infection at an earlier stage than light microscopy and immunocytochemistry. We therefore undertook this study of heart transplant recipients to try to establish the diagnostic value of nested CMV PCR and CMV in situ hybridisation in the context of upper gastrointestinal disease.

Methods

PATIENTS AND SEROLOGY

We studied 30 men (mean age 47 years) and eight women (mean age 56 years) who had undergone orthotopic heart transplantation during the previous two years for ischaemic heart disease (27 men, seven women) or dilated cardiomyopathy (three men, one woman). All recipients and donors underwent pretransplant assessment of CMV serology using a standard complement fixation test (table 1). Maintenance immunosuppression following transplantation was triple therapy with prednisolone, cyclosporin A, and azathioprine.

After the transplantation, CMV status could be monitored using a combination of serology

Glasgow Royal Infirmary, Glasgow, UK:

Department of Pathology

S W Muir

J Murray

M A Farquharson

A R McPhaden

Scottish Cardiopulmonary Transplant Centre

D J Wheatley

Correspondence to:
Dr A R McPhaden,
Department of Pathology,
Glasgow Royal Infirmary, 84
Castle Street, Glasgow G4
0SF, Scotland, UK.

Accepted for publication
7 July 1998

Table 1 Cytomegalovirus serological status of cardiac transplant recipients and donors

	Donor IgG	Recipient IgG pre-transplant	Recipient IgM seroconversion post-transplant	Rising recipient IgG post-transplant
Positive patients	9	8	16	7
Negative patients	29	30	22	31

No donor or pre-transplant recipient was IgM positive. Recipient post-transplant data were at time of upper gastrointestinal biopsy.

(table 1), immunofluorescence detection of CMV early antigen in peripheral blood or urine, and detection of cytopathic effect in cell culture.⁹ Clinically relevant CMV infection was defined as CMV IgM seroconversion, a significant rise in serum CMV IgG concentrations, or a positive biopsy in a symptomatic transplant patient who showed at least a partial response to acyclovir or ganciclovir treatment. All patients underwent endoscopic biopsy of the oesophagus, gastric body, gastric antrum, and the first part of the duodenum, mainly on the basis of clinical or serological suspicion of active CMV infection. Although detection of CMV early antigen in the peripheral blood may identify clinical infection earlier than conventional serology, the retrospective nature of this study and the incomplete data available for this test in the patient group precluded its inclusion here.

Control biopsies were taken from the same sites in 38 patients; these controls had an identical male to female ratio and were of similar age. The controls had undergone upper gastrointestinal biopsy for dyspepsia or upper abdominal pain and had no clinical suspicion of CMV infection. The CMV serological status of these patients was unknown.

The ability of nested PCR to detect latent CMV infection was assessed by amplifying the DNA of postmortem tissues from patients who had serological evidence of pretransplant CMV infection but no active CMV disease after transplantation.

Throughout this study, all patient and control samples were independently analysed by two investigators who were blinded to the patients' identity and to all other laboratory results.

LIGHT MICROSCOPY AND IMMUNOCYTOCHEMISTRY

All biopsies were formalin fixed and paraffin embedded, after which 4 µm thick sections were cut at three histological levels and stained with H&E according to normal departmental protocols.

A biopsy was regarded as positive by light microscopy for CMV if a single cell showed a characteristic intranuclear Cowdry A inclusion, cytoplasmic inclusions, and cytomegaly following examination of H&E stained sections of each biopsy at three levels.

Immunocytochemical detection of CMV early antigen was carried out at three levels in all biopsies using an indirect streptavidin-biotin immunoperoxidase technique¹⁰ employing the mouse monoclonal antibody CCH2 at a dilution of 1:50 (Dako). Positivity was interpreted as nuclear or cytoplasmic staining in epithelial or endothelial cells. Staining of neutrophils or plasma cells was not interpreted as true positivity.

DNA PREPARATION

Six 10 µm thick sections from three levels of each biopsy were placed in a sterile 1.5 ml centrifuge tube. The samples were deparaffinised by extraction twice in 1 ml of xylene, then twice in 1 ml of industrial alcohol. Following vacuum desiccation, each sample was incubated overnight at 37°C with proteinase K (500 µg/ml) in 100 µl of 50 mM Tris pH 8.5, 1 mM EDTA, and 0.5% (wt/vol) Tween 20. Proteinase K was then heat inactivated at 95°C for 10 minutes, the specimen centrifuged at 600 *g* for five minutes, and the supernatant stored at 4°C until required for PCR. Section preparation, DNA extraction, and PCR took place in physically separate work areas, and scrupulous precautions were taken during handling to ensure there was no cross contamination.

NESTED POLYMERASE CHAIN REACTION

First round CMV PCR was carried out in a 25 µl reaction volume containing 10 µl of proteinase K digested supernatant, 0.2 µl (1 unit) of Taq polymerase (Perkin Elmer Cetus), 0.15 µl (1 µM) each of primers CMV A1 and CMV A2, 2 µl of mixed deoxyribonucleotide triphosphates (dATP, dCTP, dGTP, dTTP present at 200 µM each), 2.5 µl of 10× reaction buffer, and 10 µl of sterile distilled water.

One drop of paraffin oil was overlaid on to each reaction which now underwent 40 cycles of amplification using one minute of denaturation at 94°C, one minute of annealing at 60°C, and one minute of elongation at 72°C. The primers recognised a highly conserved region of the CMV intermediate-early gene (a gift of Dr A K Foulis, Department of Pathology, Glasgow Royal Infirmary) and had the following sequences: CMV A1, 5' TGGCACGGG-GAATCCGCCT 3' and CMV A2, 5' GGT-AGGCGTGTACGGTGGG3'. First round amplification yielded a 167 base pair product. Second round amplification used 1 µl of the first round amplification reaction in a 25 µl final reaction volume, the components of which were the same as in the first round except for the different sequence of the internal nested primers CMV B1 and CMV B2. Amplification conditions were the same as in the first round except that only 30 cycles were employed. The primer sequences were as follows: CMV B1, 5' GCAGAGCTCGTT-TAGTGAACCG3' and CMV B2, 5' ATC-CGCGTTCCAATGCACCGTT 3'. Second round amplification yielded a 125 base pair product. Positive and negative control biopsies were included in each PCR run.

β GLOBIN POLYMERASE CHAIN REACTION

PCR amplification of a 110 base pair segment of the β globin gene was performed on every DNA sample before carrying out CMV PCR in order to ensure DNA integrity and suitability as a substrate for PCR. Reaction conditions were identical to first round CMV PCR apart from primer annealing for 30 seconds at 60°C. The primer sequences were as follows: βGLO 1, 5' ACACAACTGTGTTCACTAGC 3' and βGLO 2, 5' CAACTTCATCCACGTTCCACC 3'. Positive and negative controls were included in each PCR run.

Characterisation of CMV and β globin PCR products was carried out using ethidium bromide stained 2% agarose and 10% polyacrylamide gel electrophoresis.

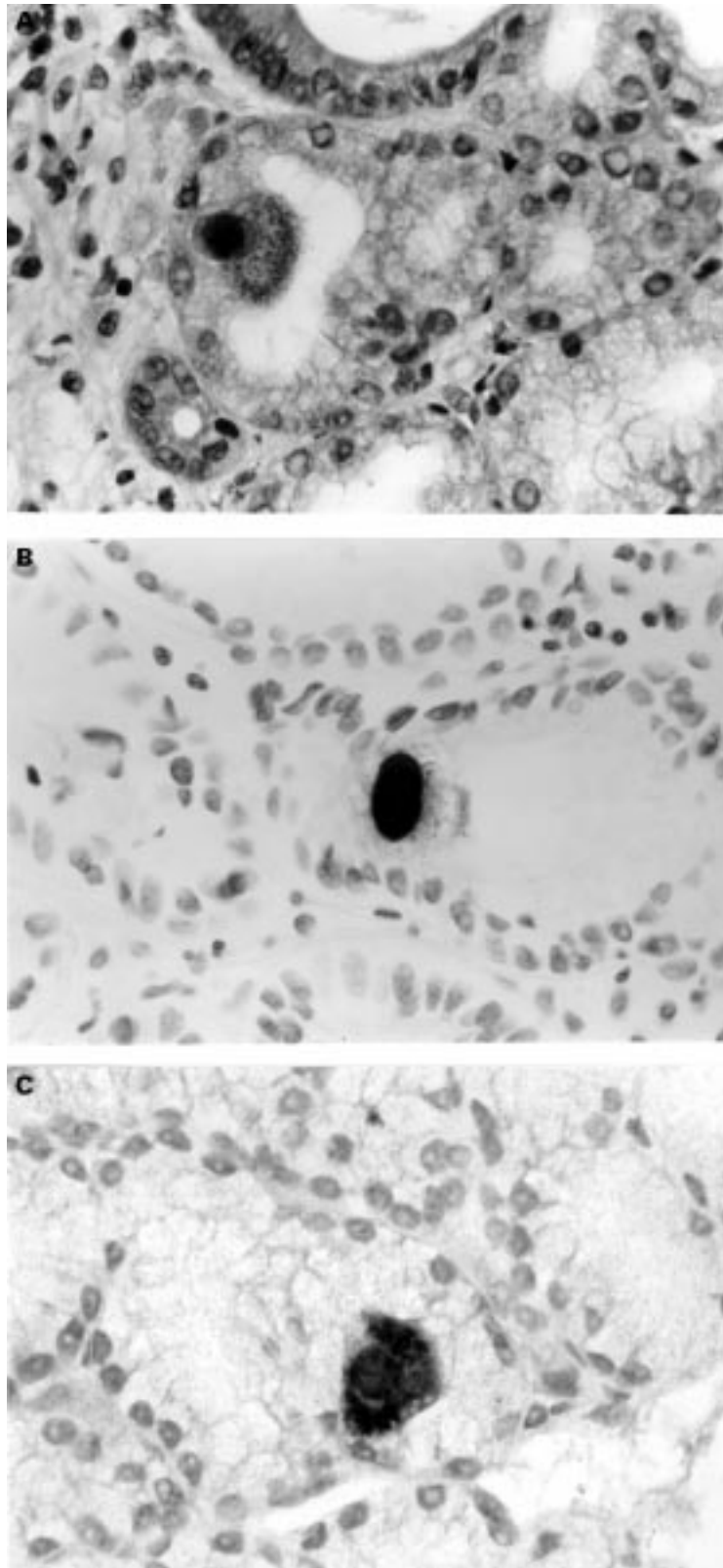


Figure 1 High power photomicrographs of duodenal Brunner's glands showing (A) a haematoxylin and eosin stained cytomegalovirus (CMV) positive epithelial cell, (B) a CMV immunocytochemical positive epithelial cell, and (C) a CMV in situ hybridisation positive epithelial cell, all from the same patient. (Magnification $\times 325$).

IN SITU HYBRIDISATION

Paraffin sections (4 μ m) mounted on silane coated slides were rehydrated and incubated in 40 μ g/ml proteinase K in 0.05 M Tris/HCl pH 7.6 (30 minutes at 37°C), followed by 0.2% glycine (20 seconds). After dehydration in methylated spirits (five minutes), each section was overlaid with 10 μ l of CMV oligonucleotide probe in hybridisation solution (Novocastro), placed under a coverslip, and incubated (three hours at 37°C). The oligonucleotide probe was directed against the CMV early gene RNA transcript (Novocastro). The slides were then washed in Tris buffered saline (TBS) containing 0.1% Triton X100 (10 minutes), followed by incubation in normal rabbit serum diluted 1 in 5 in TBS containing 3% bovine serum albumin (BSA) and 0.1% Triton X100 (10 minutes at room temperature). Finally, they were incubated in rabbit anti-FITC conjugated to alkaline phosphatase (Dako) and diluted 1 in 80 in TBS containing 3% BSA and 0.1% Triton X100 (30 minutes at 37°C). Then, after two washes in TBS and a wash in alkaline phosphatase substrate buffer, pH 9 (five minutes), the slides were placed in detection solution consisting of alkaline phosphatase substrate buffer containing 5 bromo-4-chloro-3 indolyl phosphate (16 μ g/ml), nitroblue tetrazolium (33 μ g/ml), and levamisole (24 μ g/ml) overnight in the dark at room temperature. The next day they were washed in water, lightly counterstained with haematoxylin, and mounted in aqueous mounting solution.

Positive and negative controls were prepared for each in situ hybridisation run. The negative control was stained using an identical protocol except that an unrelated control probe was used.

DATA ANALYSIS

Calculation of sensitivity, specificity, false positive rate, false negative rate, positive predictive value, and negative predictive value was performed as follows: let a represent the number of positive test results when the disease is present; let b represent the number of positive test results when the disease is absent; let c represent the number of negative test results when the disease is present; let d represent the number of negative test results when the disease is absent. Sensitivity is $a/(a + c)$; specificity is $d/(b + d)$; false positive rate is $b/(b + d)$; false negative rate is $c/(a + c)$; positive predictive value is $a/(a + b)$; negative predictive value is $d/(c + d)$.

Results

LIGHT MICROSCOPY AND IMMUNOCYTOCHEMISTRY
Light microscopic changes diagnostic of CMV were present in the biopsies of 12 of the 38 patients, all of whom were thought to have CMV clinically (fig 1). However, light microscopy was negative in eight patients who were clinically thought to have CMV infection. Importantly, light microscopy led to the diagnosis of other significant pathologies which merited treatment, including oesophageal candidiasis and helicobacter gastritis/duodenitis. Immunocytochemistry for CMV was positive

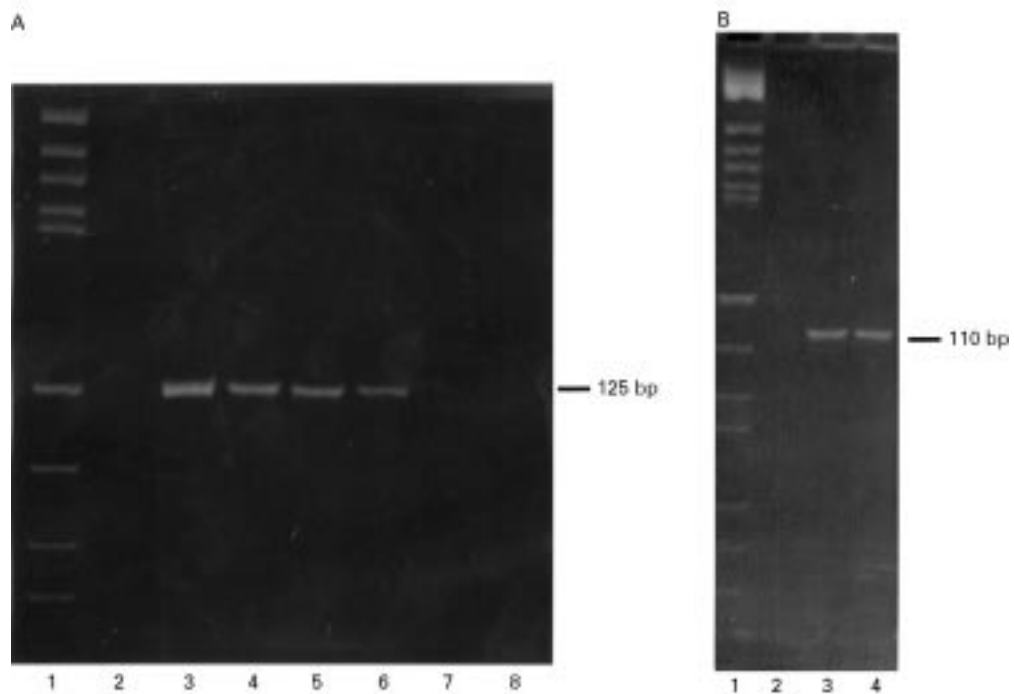


Figure 2 Ethidium bromide stained 2% agarose gels. Gel (A) shows the 125 base pair (bp) second round cytomegalovirus (CMV) polymerase chain reaction (PCR) product from three patients in lanes 4, 5, and 6. Lane 3 represents a positive control. Lane 2 is a negative control and lanes 7 and 8 are CMV PCR negative patient samples. Lane 1 represents molecular weight markers (pBR322 DNA Hae III). Gel (B) shows the 110 bp β globin PCR product in lanes 3 and 4 from one patient and one control sample. Lane 2 is a negative control. Lane 1 represents molecular weight markers (pBR322 DNA Hae III).

in 15 of the 38 patients, all of whom were thought to have CMV clinically (fig 1). Five clinically positive patients were negative by immunocytochemistry. Immunocytochemistry was positive in three patients who were CMV negative by light microscopy. No light microscopic or immunocytochemical positivity for CMV was seen in the control biopsies.

POLYMERASE CHAIN REACTION

β Globin PCR yielded a 110 base pair reaction product from all the patient and control DNA extracts, thereby validating DNA integrity and suitability as a substrate for PCR before carrying out CMV PCR. Three patient samples had to be diluted 10-fold before successful amplification, most probably because of the presence of an inhibitor of PCR in these three specimens.

Nested CMV PCR detected CMV DNA in the biopsies from 18 of the 38 patients tested (fig 2). All results were repeated on three separate occasions. PCR was positive in only one patient who was thought to have no clinically relevant CMV infection at the time of biopsy, although this patient became seropositive one week later. PCR was negative in two patients with clinical evidence of CMV disease. PCR was positive in all light microscopy and immunocytochemistry positive patients. None of the 38 control patients showed CMV PCR positivity.

Detection of latent CMV infection by nested PCR is a potential pitfall. This was addressed by application of the nested CMV PCR technique to paraffin embedded tissues derived from five necropsies on heart transplant patients. PCR was negative in 27 tissues from

two patients who had serological evidence of exposure to CMV before transplantation but no active CMV disease subsequently. PCR was only positive in tissues from the three necropsies of patients with known active CMV disease at the time of death.

IN SITU HYBRIDISATION

CMV in situ hybridisation was positive in the biopsies of 15 of the 38 patients (fig 1), all of whom were thought to have CMV infection clinically. However, in situ hybridisation was negative in five patients who were thought to have clinically relevant CMV infection, an identical result to CMV immunocytochemistry. In situ hybridisation was negative in all patients who were thought to have no clinically relevant CMV infection. No CMV in situ hybridisation positivity was identified in any of the 38 control biopsies.

CLINICAL CORRELATION

Twenty of the 38 transplant patients biopsied had clinically relevant CMV infection as defined earlier. CMV PCR detected the greatest number of clinically relevant cases of CMV infection compared with light microscopy, immunocytochemistry, and in situ hybridisation; however, since this was a retrospective study no patient who was only PCR positive was treated for CMV on PCR evidence alone. The test sensitivities, specificities, false positive and negative rates, positive predictive values, and negative predictive values of light microscopy, immunocytochemistry, in situ hybridisation, and PCR in detecting clinically relevant CMV infection are shown in table 2.

Table 2 A comparison of haematoxylin and eosin (H&E), immunocytochemistry (ICC), in situ hybridisation (ISH), and polymerase chain reaction (PCR) in the detection of clinically relevant CMV infection

Test method	Sensitivity	Specificity	False positive rate	False negative rate	Positive predictive value	Negative predictive value
H&E	60%	100%	0%	40%	100%	69%
ICC	75%	100%	0%	25%	100%	78%
ISH	75%	100%	0%	25%	100%	78%
PCR	90%	94%	6%	10%	95%	89%

Discussion

In this study we have shown that in upper gastrointestinal biopsies from heart transplant patients, nested PCR is the most sensitive test for CMV detection, followed by immunocytochemistry and in situ hybridisation, and finally light microscopy, in decreasing order of sensitivity. This is in agreement with several other studies involving patients with liver, bone marrow, or small intestinal transplants, and in immunodeficient HIV positive patients.^{4 6 7 11} However, in contrast to another study⁴ which showed a nested PCR specificity as low as 43%, our specificity was 94%, reflecting the very low false positive rate shown in table 2.

This low false positive detection rate was supported by the negative nested PCR analysis of 27 postmortem tissues from heart transplant patients who had serological evidence of old CMV infection but no CMV activity around the time of death. DNA PCR could, in theory, detect the latent phase of CMV infection, but our study has shown that PCR positivity was only present in the postmortem tissues from patients with known active CMV disease at the time of death. Furthermore, none of the 38 control biopsies was CMV PCR positive, despite the fact that it is likely that latent CMV was present in some of these patients. Our low false positive rate reflects not only the scrupulous care that was taken to avoid cross contamination between test samples from the stage of section cutting through to final PCR analysis, but also primer design and the reaction being nested.

In the one PCR positive patient who was thought to have no clinically relevant CMV infection at the time of biopsy but became seropositive one week later, detection of CMV early antigen in the peripheral blood may have been a better indication of clinical infection than conventional serology.

In situ hybridisation was successful in detecting CMV infected cells in formalin fixed, paraffin embedded upper gastrointestinal biopsies from heart transplant patients. Sensitivity and specificity of in situ hybridisation were the same as for CMV immunocytochemistry, with only those cases that were positive by immunocytochemistry being positive by in situ hybridisation. Therefore, despite the theoretical possibility that CMV early gene RNA detection by in situ hybridisation could lead to earlier detection of CMV infection than immunocytochemistry, no additional in situ hybridisation positive cases were identified. However, considering the greater technical complexity and expense of in situ hybridisation compared with immunocytochemistry, we felt that the value of in situ hybridisation in this diagnostic context was inferior to immunocytochemistry.

We should emphasise that in this study the comparisons made between PCR and in situ hybridisation are in terms of diagnostic value rather than scientific sensitivity and specificity, which would have required the use of RT-PCR and not DNA PCR. Furthermore, examination of an adequate volume of tissue is essential in any biopsy based detection system when the disease process being sought, such as CMV, may be focal rather than diffuse.

H&E light microscopy showed several significant pathologies—including oesophageal candidiasis and helicobacter gastritis/duodenitis—that would not have been readily apparent on the immunocytochemistry and in situ hybridisation, and which would not have been addressed by PCR.

Our findings suggest that nested CMV PCR is a useful adjunct to light microscopy and immunocytochemistry in the investigation of upper gastrointestinal biopsies from heart transplant patients. It will be most useful in those patients whose biopsies are CMV negative by light microscopy and immunocytochemistry, but in whom there is a strong clinical suspicion of active CMV infection. However, a negative PCR result does not exclude CMV infection since its negative predictive value was 89%. In this diagnostic context, in situ hybridisation had no advantage over immunocytochemistry and was inferior to PCR. Overall, CMV PCR represents an exciting additional diagnostic technique for the histopathologist involved in transplant pathology.

- Rubin RH. Impact of cytomegalovirus infection on organ transplantation recipients. *Rev Infect Dis* 1990;12:754–66.
- Stratta RJ. Clinical patterns and treatment of cytomegalovirus infection after solid organ transplantation. *Transplant Proc* 1993;25:15–21.
- Chetty R, Roskell DE. Cytomegalovirus infection in the gastrointestinal tract. *J Clin Pathol* 1994;47:968–72.
- Brainard JA, Greenon JK, Vesey CJ, *et al.* Detection of cytomegalovirus in liver transplant biopsies. *Transplantation* 1995;57:1753–7.
- Chen Y-T, Mercer JO, Cheigh JS, *et al.* Cytomegalovirus infection of renal allografts: detection by polymerase chain reaction. *Transplantation* 1992;53:99–103.
- Einsele H, Steidle M, Vallbracht A, *et al.* Early occurrence of human cytomegalovirus infection after bone marrow transplantation is demonstrated by the polymerase chain reaction technique. *Blood* 1991;77:1104–8.
- Kusne S, Manes R, Frye BL, *et al.* Use of DNA amplification for diagnosis of cytomegalovirus enteritis after intestinal transplantation. *Gastroenterology* 1997;112:1121–8.
- McNicol AM, Farquharson MA. In-situ-hybridization and its diagnostic applications in pathology. *J Pathol* 1997;182:250–61.
- Hodinka RL, Friedman HM. Human cytomegalovirus. In: Murray PR, Baron EJ, Pfaller MA, *et al.*, eds. *Manual of clinical microbiology*. Washington DC: ASM Press, 1995: 884–94.
- Miller K. Immunocytochemical techniques. In: Bancroft JD, Stevens A, eds. *Theory and practice of histological techniques*. Edinburgh: Churchill Livingstone, 1996:435–70.
- Cotte L, Drouet E, Bissuel F, *et al.* Diagnostic value of amplification of human cytomegalovirus DNA from gastrointestinal biopsies from human immunodeficiency virus infected patients. *J Clin Microbiol* 1993;31:2066–9.



Detection of cytomegalovirus in upper gastrointestinal biopsies from heart transplant recipients: comparison of light microscopy, immunocytochemistry, in situ hybridisation, and nested PCR.

S W Muir, J Murray, M A Farquharson, et al.

J Clin Pathol 1998 51: 807-811
doi: 10.1136/jcp.51.11.807

Updated information and services can be found at:
<http://jcp.bmj.com/content/51/11/807>

	<i>These include:</i>
References	Article cited in: http://jcp.bmj.com/content/51/11/807#related-urls
Email alerting service	Receive free email alerts when new articles cite this article. Sign up in the box at the top right corner of the online article.

Notes

To request permissions go to:
<http://group.bmj.com/group/rights-licensing/permissions>

To order reprints go to:
<http://journals.bmj.com/cgi/reprintform>

To subscribe to BMJ go to:
<http://group.bmj.com/subscribe/>